

## Case Report

# Pull straighten and push technique: A simple solution for guidewire realignment to facilitate stent and device delivery in coronary angioplasty

Byju Kachery, Biju Ephrem, Sreeram Gopalakrishnan

From Department of Cardiology, H M S Hospital, Kottakkal, Kerala, India

**Correspondence to:** Dr. Byju Cheriya Kachery, Department of Cardiology, HMS Hospital, N H Palathara, Kottakkal - 676510, Kerala, India. Phone: +91-9495022550. E-mail: [byjukachery@gmail.com](mailto:byjukachery@gmail.com)

Received - 26 July 2017

Initial Review - 26 August 2017

Published Online - 20 September 2017

### ABSTRACT

Coronary guidewire bias prevents easy passage of interventional devices such as stents and balloons during percutaneous coronary intervention (PCI). Realignment guidewire into the central part of the lumen, away from the coronary wall helps the tracking devices in situations with significant guidewire bias. There are several available techniques to facilitate stent delivery in tortuous vessel; however, these techniques have their own limitations and can be expensive and time-consuming. A new maneuver for easy passage of stents and balloons in these situations by guidewire realignment is described in this report. This maneuver namely “pull straighten and push technique” demonstrated an easy procedure to successfully execute stents or devices deployment in challenging PCIs.

**Key words:** Balloon angioplasty, Coronary artery disease, Percutaneous coronary intervention, Pull straighten and push technique, Stenting technique

Delivery failure of cardiac stents during percutaneous coronary interventions (PCI) is one of the major causes of procedural failure [1]. Stent and device delivery through tortuous coronary segments poses a significant problem in 3.7-5% of coronary angioplasties [2]. Coronary tortuosity produces wire bias directing the distal edge of the stent or devices to point toward the wall of the vessel rather than allowing them to pass through the central part of the vessel lumen. In long tortuosities, multiple areas of stent surface get in contact with the vessel wall leading to significant friction for distal delivery. The second common scenario is wire bias preventing entry of non-compliant (NC) balloon into the proximal part of a newly deployed stent. Some common techniques are available to overcome this limitation which includes coaxial alignment of the guide, deep inspiration or expiration, mother and child technique, use of guide catheters with higher support, buddy wire technique, and deep intubation of the guide catheter [3]. This report describes a simple maneuver for guidewire realignment which involves existing guide catheter and guidewire to assist deployment of stent and device delivery in coronary tortuosities and proximal edge of newly deployed stents.

### CASE REPORTS

#### Case 1

The patient was a 48-year-old diabetic male who presented with an acute coronary syndrome (ACS). The patient had a history of three-vessel coronary artery bypass grafting at left anterior descending artery (LAD), obtuse marginal artery, and right

posterior descending artery (RPDA) 7 years ago. Subsequently, he had angioplasty with drug-eluting stents to saphenous vein grafts (SVG) to RPDA (4 years ago) and LAD (1 year ago) for ACS.

The initial laboratory results showed a high serum troponin I level (13.5 ng/mL). An echocardiogram showed hypokinesia of the apex with a 50% left ventricular ejection fraction. Coronary angiogram demonstrated culprit lesion with 90% discrete stenosis in SVG to LAD proximal to the previously stented segment (Fig. 1a).

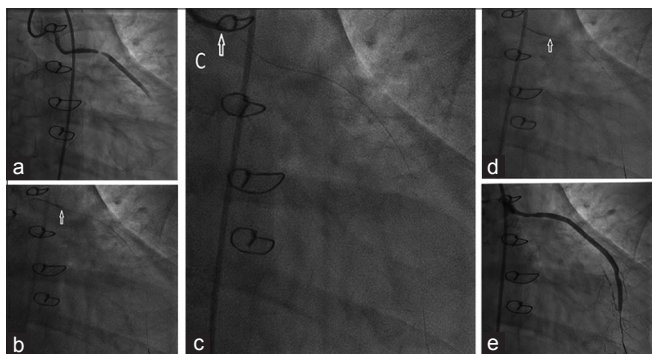
The patient underwent PCI for SVG to LAD. A 6 F Judkins Right (JR) 3.5 (Medtronic Inc., Minneapolis, USA) catheter introduced through the right femoral artery sheath was used to engage the graft. After crossing the lesion with 0.014 Sion guidewire (Asahi Intecc, Aichi, Japan), pre-dilatation was done with 1.5 × 10 mm Sapphire balloon (OrbusNeich, Shenzhen, China). A 3 × 19 mm sirolimus-eluting BioMime stent (Meril Life Sciences Pvt., Ltd., Vapi, India) was deployed toward the lesion but could not be delivered beyond the tortuosity in the proximal part of the graft. It was observed that the stent was touching the upper wall of the graft at the site of bend, which prevented further advancement (Fig. 1b). This made the guide catheter to back out making it difficult to advance the stent into the lumen. Therefore, new technique PSP technique was employed. Stent was withdrawn into the guide catheter and was kept proximal to the tip of the guide catheter. Subsequently, guide catheter was pulled back and disengaged, straightening the guidewire course. This took the guidewire away from the upper wall of the proximal vein graft toward the central part of the lumen (Fig. 1c). Stent was

gently pushed forward and easily delivered through the tortuous segment to the lesion site (Fig. 1d). Stent was deployed with an excellent final result (Fig. 1e) (Movie 1).


## Case 2

A 46-year-old female presented with stable angina for the past 6 months. Treadmill test was positive at moderate workload. Echocardiogram showed normal left ventricular systolic function. Coronary angiogram showed diffuse 90% stenosis of proximal LAD and 70% discrete stenosis of proximal left circumflex (LCx) (Fig. 2a). Subsequently, the patient underwent PCI to LCx following successful PCI to LAD. Through a 6 F EBU3 (Medtronic Inc., Minneapolis, USA) guide catheter,

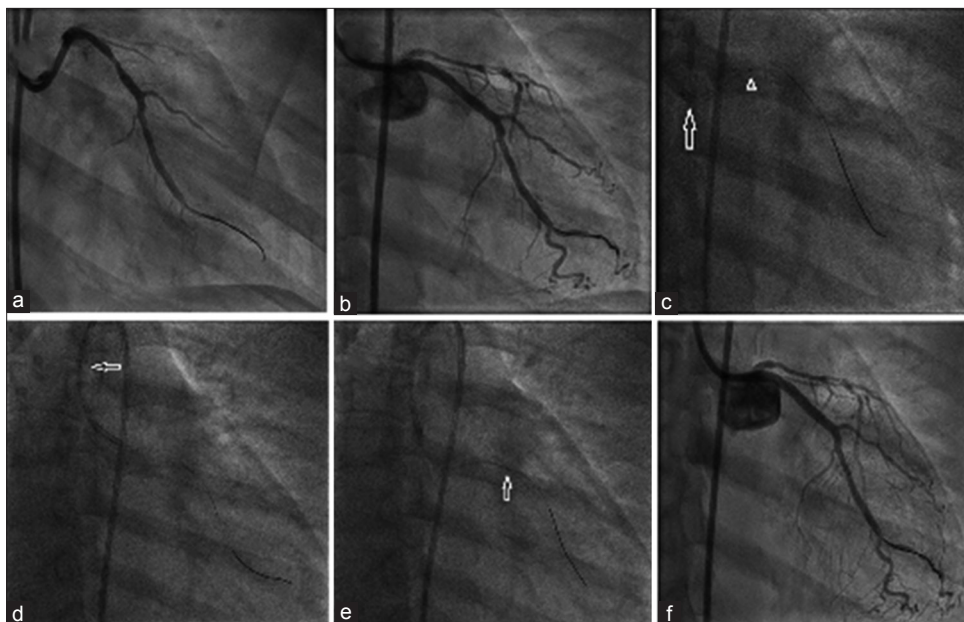
0.014 Sion guidewire (Asahi Intecc, Aichi, Japan) was used to cross the lesion. Pre-dilatation was performed with a  $2 \times 10$  mm Sapphire balloon followed by deployment of  $3 \times 19$  mm sirolimus-eluting BioMime stent at a pressure of 10 atm. There was no difficulty in the advancement of stent delivery to the lesion. To minimize the mild residual stenosis (Fig. 2b), post-dilatation was performed with a  $3 \times 12$  mm NC Sapphire balloon, but this balloon could not pass through the stent as the distal edge of the balloon was abutting the inferior rim of the proximal stent edge (Fig. 2c, arrow). Hence, PSP technique was applied to overcome this difficulty. Balloon was pulled back into the guide catheter and kept proximal to the distal tip of the guide catheter (Fig. 2d). Furthermore, the guide catheter was pulled back and disengaged allowing the guidewire to straighten and realign its course toward the center of vessel lumen away



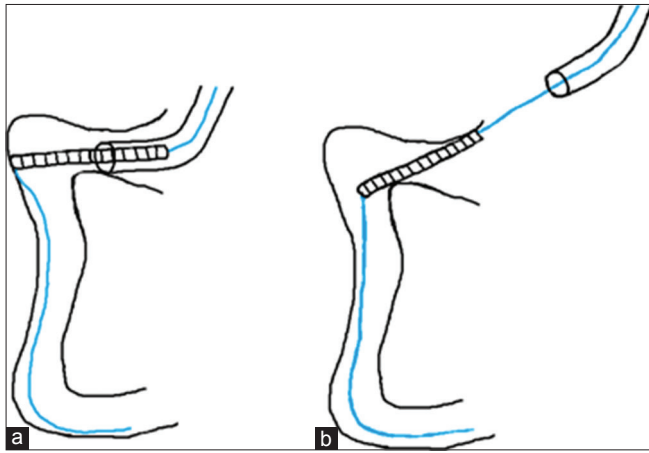
**Figure 1:** Coronary angiogram in Case 1 showing stenosis in saphenous vein graft to left anterior descending artery (a), stent touching the upper wall of the graft at the bend (arrow) preventing further advancement (b), pull straighten and push (PSP) technique: Stent being withdrawn into the guide catheter followed by pulling the guide catheter (arrow) and straightening the guidewire (c), stent gently pushed and delivered (arrow) through the tortuous segment (d), successful deployment of the stent with a PSP technique (e)




**Movie 1**



**Figure 2:** Coronary angiogram in patient 2 showing stenosis in left circumflex artery (a), post-stenting angiogram showing mild residual stenosis (b), non-compliant balloon abutting the inferior rim of the proximal stent edge (arrow head c), Guide catheter backing out with advancement of balloon (arrow c), pull straighten and push (PSP) technique: Balloon being pulled back into the guide catheter (arrow d), Guide catheter being pulled back and disengaged, straightening and realigning the guidewire (d), balloon being pushed gently toward the stent allowing easy delivery till the proximal half of stented segment (arrow e), post-dilatation was done with an excellent final result (f)



**Figure 3: Illustration demonstrating pull straighten and push (PSP) technique: Stent touching the upper wall of the vessel at the site of bend preventing further advancement, (a) Guidewire realignment by PSP technique facilitating distal delivery of the stent (b)**



**Movie 2**

from stent edge. The balloon was pushed gently towards the stent and could be easily delivered inside the proximal half of the stented segment (Fig. 2e). At this point, there was some resistance, which could be overcome by re-engaging the guide catheter and pushing with little force to the balloon. Finally, post-dilatation was executed at 14 atm with desirable outcome (Fig. 2f) (Movie 2).

## DISCUSSION

Coronary vessel tortuosity and proximal edge of newly deployed stents originate difficulty in distal delivery of device due to significant guidewire bias [4]. Currently available techniques to overcome this complexity include deep inspiration, deep expiration, coaxial alignment of the guide catheter, use of guide catheters with more support, deep intubation of the guide, use of a buddy wire, buddy balloon technique, anchor balloon, and selecting a different device, mother and child technique [1,3,5-8]. Most of these techniques except respiratory maneuver and coaxial guide alignment require the use of additional hardware and time consuming for

PCI [9]. In this report, we describe a simple PSP technique to deflect the guidewire away from the vessel wall, overcoming the difficulty in delivery of devices through tortuous coronary segments (Fig. 3a) and proximal stent edges. This involves pulling back the device into the guide catheter followed by partially disengaging the guide catheter to straighten the guidewire course in the proximal vessel (Fig. 3b). We keep the device well inside the guide catheter to allow a reasonable free length of guidewire to self-align in the distal guide catheter and proximal vessel toward the central part of the lumen. It is advisable to gentle push as rapid movement of the device and use of higher force would again align the guidewire toward the wall of the vessel or stent edge.

In the former case, the distal edge of stent was touching to the upper part of the vessel wall. After the guidewire was straightened and realigned by PSP technique, distal edge of the stent easily negotiated this part of the vessel due to more central position of the guidewire. However, when the stent encounters resistance, further forward push causes the guide to back out. To overcome this problem, currently available techniques to increase guide support such as deep intubation of the guide catheter, use of guides with increased support such as Amplatz curve, use of mother and child technique, and balloon anchoring can be employed [10]. These techniques require additional hardware and are associated with increased risk of vessel trauma. Hence, PSP technique is an appropriate method than these methods as it does not involve any additional hardware and risk of vessel trauma.

In the later case, resistance due to contact of distal edge of the NC balloon with the inferior rim of the proximal stent edge was again overcome easily by wire realignment applying PSP technique. Dottering technique using repeated gentle push and pull of the balloon to realign its course by bouncing action of the guidewire was described to overcome this situation and specifically useful when the proximal lumen is large enough to allow for the bounce [8]. Though dottering technique can be performed safely with balloons, this is not advisable in cases of difficult stent delivery since it may cause damage to the external surface of the stent or lead to dislodgement of the stent, especially when the vessel is calcified. Moreover, other methods, namely, partial inflation and deflation of the balloon proximal to the stented segment, use of a short NC balloon, gentle rotation of the balloon, and passing the guidewire into a different distal branch allowing to realign its course may be employed in difficult stent delivery [8]. Major consideration during all maneuvers is to prevent the damage to the struts of the newly deployed stent.

PSP technique is majorly effective in the right coronary artery and vein grafts because straightening of the guidewire occurs easily in these vessels, especially with a JR guide catheter. It is also useful for crossing the bend from left main (LM) to LAD and more specifically LCx. However, PSP technique may not be suitable for mid or distal part of coronary arteries as it is difficult to perform during aligning the guidewire by guide catheter manipulation. In summary, PSP

technique can be effectively used to deliver stents or devices such as NC balloons through bends in proximal part of coronary arteries and vein grafts or to negotiate proximal edge of newly deployed stents by simple realignment of guidewire toward the center of coronary lumen.

## CONCLUSION

Coronary guidewire bias poses considerable challenge for stent delivery and devices such as non-compliant balloons. Various techniques are described to overcome this problem though it involves additional hardware and time for PCI. Hence, PSP technique provides a new approach of re-alignment of guidewire to allow easy delivery of devices through tortuosity in proximal part of coronary vessels and proximal edge of newly deployed stents.

## REFERENCES

- Mamas MA, Fath-Ordoubadi F, Fraser DG. Distal stent delivery with guideliner catheter: First in man experience. *Catheter Cardiovasc Interv.* 2010;76(1):102-1.
- Nikolsky E, Gruberg L, Pechersky S, Kapeliovich M, Grenadier E, Amikam S, et al. Stent deployment failure: Reasons, implications, and short-and long-term outcomes. *Catheter Cardiovasc Interv.* 2003;59(3):324-8.
- Feldman T. Tricks for overcoming difficult stent delivery. *Catheter Cardiovasc Interv.* 1999;48(3):285-6.
- Reisman M, Harms V. Guidewire bias: Potential source of complications with rotational atherectomy. *Cathet Cardiovasc Diagn.* 1996;Suppl 3:64-8.
- Abernethy WB 3<sup>rd</sup>, Choo JK, Oesterle SN, Jang IK. Balloon deflection technique: A method to facilitate entry of a balloon catheter into a deployed stent. *Catheter Cardiovasc Interv.* 2000;51(3):312-3.
- Attaran RR, Butman S, Movahed MR. Going around the bend: Deep inspiration facilitates difficult stent delivery in the native coronary arteries. *Tex Heart Inst J.* 2011;38(3):270-4.
- Takahashi S, Saito S, Tanaka S, Miyashita Y, Shiono T, Arai F, et al. New method to increase a backup support of a 6 french guiding coronary catheter. *Catheter Cardiovasc Interv.* 2004;63(4):452-6.
- Gholoobi A. What is the next step when a non-compliant balloon does not pass through a freshly deployed stent? *J Tehran Heart Cent.* 2014;9(2):97-8.
- Saucedo JF, Muller DW, Moscucci M. Facilitated advancement of the palmaz-schatz stent delivery system with the use of an adjacent 0.018" stiff wire. *Cathet Cardiovasc Diagn.* 1996;39(1):106-10.
- Nguyen T, Hu D, Chen SL, Kim MH, Saito S, Grines C, et al. *Practical Handbook of Advanced Interventional Cardiology.* 4<sup>th</sup> ed. Oxford, UK: Wiley-Blackwell; 2013. p. 107-32.

*Funding: None; Conflict of Interest: None Stated.*

**How to cite this article:** Kachery B, Ephrem B, Gopalakrishnan S. Pull straighten and push technique: A simple solution for guidewire realignment to facilitate stent and device delivery in coronary angioplasty. *Indian J Case Reports.* 2017;3(4):220-223.