

Cutaneous bronchogenic cyst over sternum: A rare case report

Smita Singh, Anamika Kashyap, Kiran Agarwal, Lalrinzuali Sailo

From Department of Pathology, Lady Hardinge Medical College, New Delhi, India

Correspondence to: Dr. Anamika Kashyap, Lady Hardinge Medical College, New Delhi - 110 001, India. Phone: +91-9899566694.

E-mail: anamikakashyap25@gmail.com

Received - 06 July 2017

Initial Review - 04 August 2017

Published Online - 01 September 2017

ABSTRACT

Bronchogenic cyst is a congenital developmental abnormality of the embryonic foregut and is found most commonly in the mediastinum with rare occurrence on the skin or subcutaneous tissues. We report a case of cutaneous bronchogenic cyst that occurred in the skin over the sternum in a 24-year-old male. On ultrasonography, a well-circumscribed, non-echogenic cystic mass was observed measuring 2 cm × 2 cm. Histologically, the cyst was lined by ciliated, pseudostratified, columnar epithelium with interspersed goblet cells, and there were bundles of smooth muscle fibers in the cyst wall. Cutaneous bronchogenic cysts are uncommon congenital malformations and should be included in the differential diagnosis of congenital cystic and nodular skin lesions on the upper chest, upper back, and neck.

Key words: *Bronchogenic, Foregut, Mediastinum*

Bronchogenic cyst is a benign congenital developmental anomaly of the tracheobronchial buds from the primitive foregut [1]. They are generally found in the mediastinum particularly posterior to the carina, but they rarely occur in unusual sites at the skin, subcutaneous tissue, pericardium, and even the retroperitoneum. Bronchogenic cysts presenting in the skin are very rare, with fewer than 70 cases reported [2]. The condition is often misdiagnosed clinically, with the correct diagnosis usually established by histopathological examination. Distinguishing bronchial from bronchogenic cysts is particularly difficult with the presence of lymphoid tissue in the cervical bronchial cysts, and the type of epithelial lining being the most important histologic features for distinguishing between cervical bronchial cysts and cutaneous bronchogenic cysts. However, significant overlap of pathologic findings has been noted in bronchial and bronchogenic cysts [3,4].

CASE REPORT

A 24-year-old male presented with a midline sternal nodule since birth with on and off foul smelling, yellowish discharge through a punctum for the past 3 years. There were no other associated symptoms. The patient had consulted many local practitioners in his native village and was diagnosed as a congenital nodule for which, he had taken several courses of antibiotics but showed no improvement. Therefore, patient consulted our surgery outpatient department for the foul smelling, yellowish discharge. Clinically, a 2.0 cm × 2.0 cm-sized, mobile, skin-colored, cystic mass with a small punctum was noted in midline over sternum. No other abnormalities were found during the general physical examination and laboratory investigations of the patient. Ultrasound

examination showed a well-demarcated hypoechoic cystic mass that was approximately 2.0 cm × 2.0 cm in size without any mediastinal extension. A clinicoradiological diagnosis of thyroglossal cyst was made and total surgical excision of the skin lesion was performed under local anesthesia.

Microscopic examination revealed a cystic structure lined with ciliated, pseudostratified, columnar epithelium in the deep dermis and subcutis interspersed with goblet cells that stained positive for periodic acid-Schiff. There was histologic transition from columnar epithelium to stratified squamous epithelium in the lining epithelium with the presence of several smooth muscle bundles in the cyst wall (Fig. 1). Numerous inflammatory cells, especially lymphocytes and plasma cells were seen infiltrating the cyst wall. Cartilage was not seen. All these features were concordant with bronchogenic cyst. On regular follow-up, patient was found to be disease free without any signs of recurrence or malignant transformation after 3 months.

DISCUSSION

Bronchogenic cysts are abnormalities of pulmonary differentiation that are usually detected in the pediatric patients. Cutaneous bronchogenic cysts are rare with a prevalence range from 1:42,000 to 1:68,000 and it occur 4 times more commonly in males than females [5]. Cutaneous bronchogenic cysts are rarely diagnosed by clinicians because they lack any specific clinical symptoms [6]. First case of a cutaneous bronchogenic cyst was a lesion in the parasternal region reported by Seybold and Clagett in 1945 [7]. The most common location of cutaneous bronchogenic cyst is the suprasternal notch, followed by the parasternal area, neck, and scapula [8]. Unusual sites of occurrence have been described in

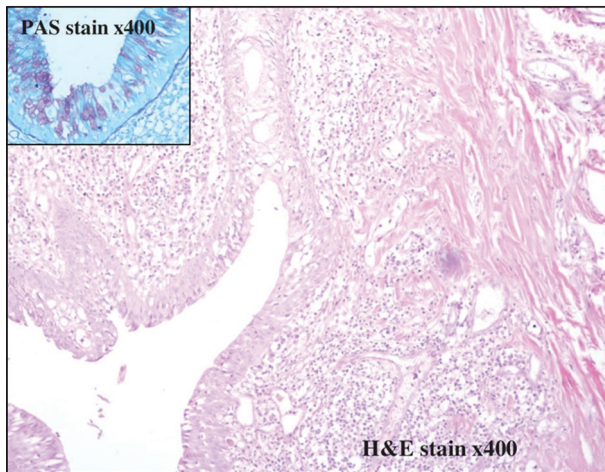


Figure 1: H and E stain ×400: Bronchogenic cyst lined by pseudostratified ciliated columnar epithelium with goblet cells, smooth muscle bundles in cyst wall (inset: Periodic acid-Schiff [PAS] stain ×400: PAS positive goblet cells)

the chin, anterior to the right lobe of thyroid and on the anterior abdominal wall. Bronchogenic cysts in the subcutaneous tissue of the anterior chest wall occur either by anterior migration of an intrathoracic bronchogenic cyst or by a pinching off of the fusing sternal bars on the developing lung parenchyma.

Bronchogenic cyst usually presents as an asymptomatic subcutaneous nodules, a draining sinus or as a pedunculated growth. Some of them have a fistulous opening that drains mucoid material. Characteristically, these cysts are lined by ciliated pseudostratified columnar epithelial cells interspersed with goblet cells, typical respiratory epithelium. They often contain smooth muscle fibers, mucus glands, or cartilages in 80%, 53%, and 7% of these cysts, respectively [1]. Lymphoid aggregates may be found in cutaneous bronchogenic cysts. In our case, it had a typical respiratory epithelium surrounded by smooth muscle bundles, without lymphoid aggregates.

The differential diagnosis includes hypoglossal duct cysts, cutaneous ciliated cysts, bronchial cysts, epidermal inclusion cyst, trichilemmal cyst, and dermoid cysts [9]. Thyroglossal duct cysts present as midline cystic nodules of neck in children or young adults. Histologically, thyroglossal duct cysts may be lined with cuboidal, columnar, or stratified squamous epithelium, and may contain some ciliated columnar cells with the characteristic finding of the presence of thyroid follicles in the cyst wall. Cutaneous ciliated cysts are uncommon cysts occurring mostly in the lower extremities of young women. Histologically, cutaneous ciliated cysts may be unilocular or multilocular, lined by simple, cuboidal-to-columnar ciliated epithelium with papillary projections into the cyst lumen. Bronchial cleft cysts occur in the pre-auricular area, mandibular region, or along the anterior border of the sternocleidomastoid muscle in second or third decade of life. Histologically, these cysts are lined by stratified squamous epithelium or by pseudostratified ciliated columnar

epithelium and are surrounded by lymphoid tissue. The lining of the epidermal inclusion cyst is stratified squamous epithelium and that of trichilemmal cyst is squamous epithelium without an intervening granular cell layer. Dermoid cysts are lined by an epidermis that possesses various epidermal appendages.

In our case, histological finding such as focal stratified squamous epithelium may suggest branchial cysts rather than cutaneous bronchogenic cysts. However, unlike the cutaneous bronchogenic cysts, branchial cysts do not show smooth muscle fibers or secretory cells. In our case, the cyst had drained for a long time and became secondarily infected and the presence of squamous epithelium focally was a metaplastic change due to the chronic inflammation.

The possibility of extension into the mediastinum should be eliminated by evaluation of chest X-ray, magnetic resonance, or ultrasound examinations. Total excision is advised for the treatment of cutaneous bronchogenic cyst along with regular follow-up as mucoepidermoid carcinoma can rarely arise from a bronchogenic cyst. Such patients may need post-operative chemotherapy and radiotherapy. Our patient has not shown any signs of recurrence or malignant transformation 3-month post-surgery.

CONCLUSION

Cutaneous bronchogenic cysts are uncommon congenital malformations and should be included in the differential diagnosis of congenital cystic and nodular skin lesions on the upper chest, upper back, and neck.

REFERENCES

1. Fraga S, Helwig EB, Rosen SH. Bronchogenic cysts in the skin and subcutaneous tissue. *Am J Clin Pathol.* 1971;56(2):230-8.
2. Carden C, Dykes E, Pollock AM. An unusual midline swelling - case report of a cutaneous bronchogenic cyst. *Eur J Pediatr Surg.* 2008;18(5):345-6.
3. Coleman WR, Homer RS, Kaplan RP. Branchial cleft heterotopia of the lower neck. *J Cutan Pathol.* 1989;16(6):353-8.
4. Miller OF 3rd, Tyler W. Cutaneous bronchogenic cyst with papilloma and sinus presentation. *J Am Acad Dermatol.* 1984;11:367-71.
5. Kundal AK, Zargar NU, Krishna A. Scapular bronchogenic cyst. *J Indian Assoc Pediatr Surg.* 2008;13(4):147-8.
6. Lacruz G, González-Enseñat MA, Suñol M, Vicente A. Unknown: A congenital nodule on the scapula. *Dermatol Online J.* 2012;18(10):12.
7. Seybold WD, Clagett OT. Presternal cyst. *J Thorac Cardiovasc Surg.* 1945;14:217-20.
8. Zvulunov A, Amichai B, Grunwald MH, Avinoach I, Halevy S. Cutaneous bronchogenic cyst: Delineation of a poorly recognized lesion. *Pediatr Dermatol.* 1998;15(4):277-81.
9. Farmer ER, Helwig EB. Cutaneous ciliated cysts. *Arch Dermatol.* 1978;114(1):70-3.

Funding: None; Conflict of Interest: None Stated.

How to cite this article: Singh S, Kashyap A, Agarwal K, Sailo L. Cutaneous bronchogenic cyst over sternum: A rare case report. *Indian J Case Reports.* 2017;3(4):203-204.