

## Case Report

Isolation of *Mycobacterium monacense* from chemoport: A rare case report and review of literature

Radharani Dandamudi, Lavanya Nambaru, Senthil J Rajappa

From, the Department of Microbiology, Basavatarakam Indo American Cancer Hospital & Research Institute, Hyderabad, Andhra Pradesh, India

**Correspondence to:** Dr. Lavanya Nambaru, Basavatarakam Indo-American Cancer Hospital & Research Institute, Road No 14, Banjara Hills, Hyderabad - 500034, Andhra Pradesh, India. Email: [nambaru.lavanya@gmail.com](mailto:nambaru.lavanya@gmail.com)

Received: 19 Jan 2017

Initial Review: 10 Feb 2017

Accepted: 30 Mar 2017

Published Online: 15 Apr 2017

## ABSTRACT

We report a rare case of *Mycobacterium monacense* isolated from the blood of a patient with carcinoma breast with an infected chemoport. Initial blood cultures from peripheral line and port were sterile. Repeated blood cultures signaled positive which showed weakly stained gram positive bacilli on smear from both the vials. Nontuberculous Mycobacterial infection and speciation were confirmed by real time polymerase chain reaction and sequencing. Chemoport was removed and patient responded to 3 drug regimen with Rifampicin, Ethambutol and Clarithromycin therapy with no recurrence at 15 month follow-up.

**Keywords:** *Mycobacterium monacense*, rapidly growing mycobacteria, chemoport, real time, PCR

In the past few years, rate of Nontuberculous Mycobacteria (NTM) detection has risen in both immunocompromised and immunocompetent patients [1]. The pathogenic role of NTM has been in doubt for several years. Only *Mycobacterium fortuitum* and *M. chelonae* were considered to be potentially responsible for disease [2]. In the last few years, many rapidly growing species that are often responsible for disease have been described in humans. Till date, only 5 case reports of isolation of *M. monacense* from independent clinical specimens have been reported [3-7]. For the first time we report the isolation of *M. monacense* from blood of patient with carcinoma breast, with an infected chemoport to the best of our knowledge.

## CASE REPORT

A 55 year old female underwent right modified radical mastectomy for carcinoma breast. Histopathological

examination revealed infiltrating duct carcinoma grade 3, pT1N0M0, estrogen receptor negative and HER 2 neu positive. Subsequently, patient was planned for adjuvant chemotherapy and monoclonal antibody trastuzumab. Chemoport placement was done under standard aseptic precautions. Patient initially received 3 weekly and then 12 cycles of weekly chemotherapy regime.

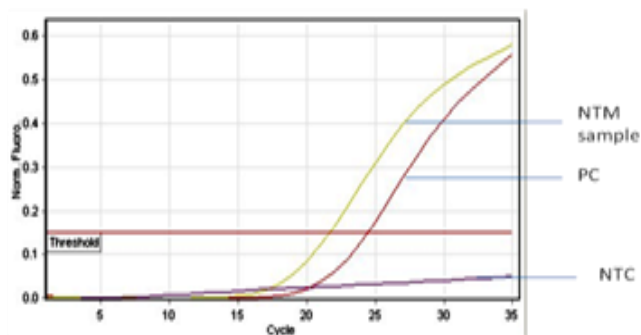
She was continued on 3 weekly infusions of Trastuzumab (440mg). While on treatment, she presented with low grade fever which was treated with empirical antibiotics. She was non neutropenic and HIV was non reactive. However, she did not respond to oral antibiotics. The fever worsened and was now associated with chills and rigors; especially, when the chemoport was used for administration of drugs. She was then admitted for administration of broad spectrum intravenous antibiotics including Vancomycin suspecting a chemoport infection.

She was hemodynamically stable and the chemoport site did not show any signs of inflammation.

CT scans of the chest and abdomen as part of the work up were normal. Initial blood cultures from peripheral line and from the port were sterile. She did not respond to antibiotics and had worsening of her fever, which was now associated with increasing fatigue and dry cough. Blood culture was repeated from both peripheral venipuncture and the port by BacT/ALERT® 3D (bioMérieux). Blood culture from port catheter signaled positive after 44 hours and from peripheral venipuncture site signaled positive on the third day. Gram stained smears from both the vials showed weakly stained gram positive bacilli in clusters. Ziehl-Neelsen staining on both the samples showed acid fast bacilli (AFB). The sample was sub cultured on blood agar, Macconkey agar and Lowenstein-Jensen (LJ) medium. There was growth on blood agar but not on Macconkey agar. It took 5 days for growth on LJ medium.



**Figure 1 – Dark yellow pigmented colonies on LJ medium**



PC-positive control, NTC-No template control

**Figure 2 – Amplification plot for NTM detection by real time PCR**

Colonies on LJ medium, which were incubated in dark, showed yellow pigmentation (**Fig. 1**). The conventional biochemical tests performed showed positive results for growth in 4.5% sodium chloride, nitrate reductase test and negative results for niacin accumulation test and aryl sulfatase production test. Bacterial DNA extraction was done from dark yellow colonies of bacteria in LJ medium, by Dynabeads® DNA DIRECT Universal KIT (Life technologies). Real time polymerase chain reaction (RT-PCR) for qualitative detection of *M. tuberculosis* (MTB) and NTM was done using RT-PCR KIT (3B BLACK BIO). The detection was based on amplification of region upstream of the 65kDa hsp probes specific for NTM genus.

*M. tuberculosis* detection was based on primer and probes targeting IS61105 and MPB646 gene. The isolate was negative for *M. tuberculosis* but amplified for hsp65 gene indicating that the isolate was positive for NTM (**Fig. 2**) For speciation, PCR-based DNA sequencing of the isolate was done with combination of three different gene targets employed for accurate identification of more than 90 different species using DNA sequencing methodology (SRL diagnostics, Mumbai, India). The isolate was confirmed as *M. monacense*. Antibiotic susceptibility testing was done following CDC guidelines by the standard MIC method and tested for the first line drugs Streptomycin, Rifampicin, Ethambutol, Isoniazide and also Levofloxacin, Amikacin, Cotrimoxazole, Azithromycin, Clarithromycin, Linezolid.

Based on the site of infection, the treatment was planned for a period of one year, along with antibody therapy for the carcinoma (which was not immunosuppressive). The chemoport was removed and patient was started empirically on 3 drug regimen with Rifampicin, Ethambutol and Clarithromycin to which she responded. Over the next two weeks, the fever spikes came down and general condition improved. As the patient was tolerating the drugs well with no side effects, the same line of treatment was continued and the patient successfully completed the treatment. She was on follow-up for the past 15 months with no relapse till date.

## DISCUSSION

Nontuberculous Mycobacteria are widely distributed in the environment with high isolation rates worldwide. They are divisible into two main groups: (a) the slow growers and

(b) the rapid growers, according to their rate of growth on subculture. In India, rapidly growing Mycobacteria (RGM) have been associated with various clinical syndromes in immunocompetent and immunocompromised hosts. The risk factors and outcomes of RGM infection in patients with carcinoma have not been clearly defined. With rare exceptions, the pathogenic RGM are *M. abscessus*, *M. chelonae* and *M. fortuitum* [8].

**Table 1: Reported cases of *M. monacense* infection**

No	Article	Sample	Clinical Indications	Pathogenic Role
1	Reischl et al (2006)	bronchial lavage	Lung carcinoma	Uncertain
2	Taieb et al (2008)	left thumb	Diabetic with hand infection	Pathogenic
3	Hogardt et al (2008)	bronchial lavage	Tuberculosis	Pathogenic
4	Therese KL et al (2011)	sputum	Tuberculosis	Pathogenic
5	Shojaei H et al (2012)	sputum	Chronic respiratory infection	Pathogenic

*Mycobacterium monacense* is a gram-positive, acid-fast, non-motile, non spore forming AFB that produces smooth, yellow, scotochromogenic colonies within 7 days at 25–45°C [2]. It was first reported from bronchial lavage in a 80-year-old patient by Reischl et al [2]. Initial reports could not confirm the pathogenic potential of *M. monacense* but subsequent reports confirmed the pathogenic role of the organism [4-8]. Till date, this is the first report of isolation of *M. monacense* from the chemoport. The present report suggests that *M. monacense* should be considered to be a potential human pathogen. The reported cases of *M. monacense* infection are summarized in Table 1.

## CONCLUSION

To the best of our knowledge, this is the first case report of isolation of *M. monacense* associated with chemoport infection from India, establishing its pathogenic role. The condition of the patient improved on removal of the

chemoport. The differentiation of MTB from NTM is of prime significance for choice of antimicrobial therapy and duration of treatment.

## ACKNOWLEDGEMENTS

(We are grateful to Prof Sundaram for her critical comments on the manuscript. and Dr. Iravatham's clinical Laboratory, SRL diagnostics, India for their cooperation and technical help)

## REFERENCES

- Jani MN, Rodrigues CS, Mehta AP. The neglected and often ignored: nontuberculous Mycobacteria. J Glob Infect Dis. 2011; 3:94.
- Reischl U, Melzl H, Kroppenstedt RM, Miethke T, Naumann L, Mariottini A et al. Mycobacterium monacense sp. nov. Int J Syst Evol Microbiol. 2006; 56: 2575-8.
- Taieb A, Ikeguchi R, Yu VL, Rihs JD, Sharma M, Wolfe J et al. Mycobacterium monacense: a mycobacterial pathogen that causes infection of the hand. J Hand Surg Am. 2008; 33: 94-6.
- Therese KL, Gayathri R, Thiruppathi K, Madhavan HN. First report on isolation of Mycobacterium monacense from sputum specimen in India. Lung India. 2011; 28: 124-6.
- Hogardt M, Schreff AM, Naumann L, Reischl U, Sing A. Mycobacterium monacense in a patient with a pulmonary tumor. Jpn J Infect Dis. 2008; 61: 77-8.
- Shojaei H, Hashemi A, Heidarieh P, Hosseini N, Daei Naser A. Chronic Pulmonary Disease Due to Mycobacterium monacense Infection: The First Case from Iran. Ann Lab Med. 2012; 32: 87-90.
- Shojaei H, Heidarieh P, Hashemi A, Feizabadi MM, Daei Naser A. Species Identification of Neglected Nontuberculous Mycobacteria in a Developing Country. Jpn J Infect Dis. 2011; 64: 265-271.
- Redelman-Sidi G, Sepkowitz KA. Rapidly growing mycobacteria infection in patients with cancer. Clin Infect Dis. 2010; 51: 422-34.

**How to cite this article:** Dandamudi R, Nambaru L, Rajappa SJ. Isolation of Mycobacterium monacense from chemoport: A rare case report and review of literature. Indian J Case Reports. 2017; 3(2): 74-76.

*Conflict of interest: None stated, Funding: Nil*