

## Case Report

### Breech presentation and neonatal fracture shaft femur – A rare case presentation

**Pankaj Kumar Mishra, Aashish Anand Gupta**

*From Department of Orthopaedics, Gandhi Medical College, Bhopal, Madhya Pradesh, India*

**Correspondence to:** Aashish Anand Gupta, Department of Orthopaedics, Gandhi Medical College, Bhopal, Madhya Pradesh, India.

Phone: +91-8989094645. E-mail: [draashishanandgupta@gmail.com](mailto:draashishanandgupta@gmail.com)

Received - 13 April 2017

Initial Review - 07 May 2017

Published Online - 06 August 2017

#### ABSTRACT

The breech extraction of the fetus through the vagina has a greater risk of hip fracture compared with the extraction by abdominal route. A 2980 g male infant was delivered at 39 weeks by elective cesarean section for breech presentation. The newborn sustained a fracture of the right femur. A simple immobilization of the limb in extension led to a complete healing of the fracture without sequelae. This case highlights that fact that cesarean delivery reduces the risk of causing a traumatic injury of the newborn compared to vaginal delivery; especially, with breech presentation but does not eliminate this possible accidental complication.

**Key words:** *Breech presentation, Fracture femur, Neonate*

**B**irth related orthopedic injury poses evincive morbidity in spite of evolved obstetric and postnatal care. Among the birth related injuries due to cesarean section, the femur fracture is one of the rarer complications [1]. Hannah et al., in his multicenter study, found that planned vaginal delivery for breech presentation has 0.5% incidence of long bone fracture, while the planned cesarean section for breech presentation has reduced it up to 0.1% [2]. Here, we are presenting a rare case report of newborn delivered by lower segment cesarean section (LSCS) for the breech presentation that let the fracture of right shaft femur and managed by slab and cast.

#### CASE REPORT

A 3 days old male baby brought to the orthopedic out-patient department. As stated by the mother, her baby was unable to move his right lower limb and screams on manipulation of his right lower limb. He was delivered by LSCS under epidural an esthesia with 2.980 kg birth weight. The Apgar score was 8 and 9 at 1 min and 5 min, respectively. The concerning obstetrician stated that it was the breech presentation for which the mild to moderate exertion was applied for the delivery of the baby. However, she did not listen or notice any sound or fracture. Second day, pediatrician found that the baby was irritable, and there was painful swelling with decreased movement of the right lower limb. He suspected for fracture and immediately sought the orthopedician opinion.

On examination, it was a tender swelling with frank abnormal movement of the right mid femur (Fig. 1). X-ray revealed the long spiral fracture of the mid shaft femur (Fig. 2). The bone quality showed the normal mineralization. The other clinical examination of neonate was normal. Particular attention (i.e., blue sclera

and hypotonic) paid to rule out the other possible differential diagnosis such as osteogenesis imperfect and Warding-Hoffman paralysis. Fundus examination, laboratory parameter and social evaluation (for Battered child syndrome) were normal; therefore, the working diagnosis of fracture shaft femur due to birth injury was installed.

Initially, plaster of Paris (POP) slab was applied after the reduction, then after the 1 week, POP cast applied for next 3 weeks (Fig. 3). At the end of progressive follow-up, the bone united and the infant was able to move his lower limb frankly.

#### DISCUSSION

Singleton vaginal birth has the incidence of 2% of the birth related injuries; however, the cesarean section has reduced the birth related injuries up to 1%. Clavicle followed by humerus is the most common bone to get fractured during breech vaginal delivery. Fracture of the femur is rare and next to humerus and clavicular fracture due to vaginal delivery [3]. Cesarean section is considered as a safer mode of delivery and less traumatizing. Although rarely but the cesarean section for breech presentation has also been reported to produce the femur fracture [4,5].

The most common mechanism is torsional forces used during delivery, which causes spiral fracture of femur fracture [6]. Excessive traction over lower limb is applied for fixed breech delivery, so it leads to femur fracture. On the contrary, cesarean section is postulated to minimize such complication [4]; although, the inverse incidence also has been reported in some literature [7]. The probable enumerated factors are less room for maneuver of obstetrician, poor muscle relaxation, poor techniques, and shorter incision [8].

Various treatment modalities for femur fracture are used, i.e., Pavlik harness, toe-groin cast, and strapping. The principle

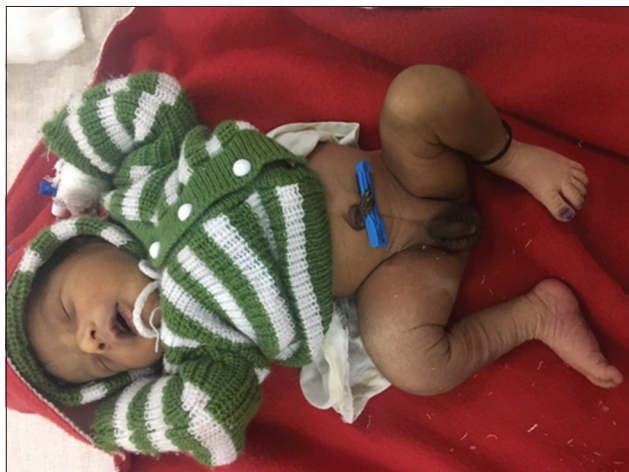

Figure 1: Showing swelling and deformity over right thigh

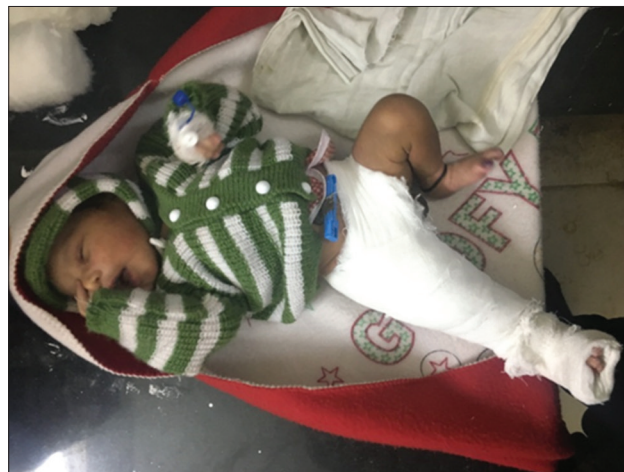

Figure 3: Toe-groin cast applied after reduction under image intensifier

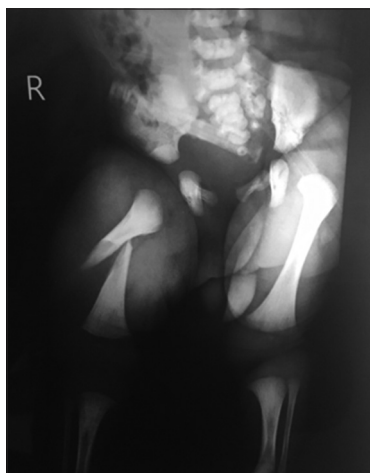


Figure 2: X-ray of pelvis with both hips, depicting long spiral fracture of right femur

behind used modalities is reduction and immobilization. Hence, though femur fracture is rare finding following cesarean section, we have to be cautious and looked out while doing difficult birth delivery. Awareness, clinical examination, and prompt orthopedic consult in any doubtful scenario of birth injury would help.

## CONCLUSION

Although the cesarean section reduces the birth related injuries but never eliminate the possibility of accidental complication. Adequate maneuvering set of rules and standard protocol to avoid the fracture of femur during cesarean section probably have not been developed due to sparsity of data and rare nature of the

complication. Hence, here we bring it to horizon of knowledge and adding this rare case to augment the awareness toward the complication occurring during the delivery, even by the safer mode the cesarean section.

## REFERENCES

1. Bangale RC. Neonatal fracture and caesarean section. *Am J Dis Child.* 1983;137:505.
2. Hannah ME, Hannah WJ, Hewson SA, Hodnett ED, Saigal S, Willan AR. Planned caesarean section versus planned vaginal birth for breech presentation at term: A randomized multicenter trial. *Lancet.* 2000;356(9239):1375-83.
3. Ehrenfest H. *Birth Injuries of the Child.* New York, NY, USA: Appleton-Century Crofts; 1922.
4. Barnes AD, Van Geem TA. Fractured femur of the newborn at caesarean section. A case report. *J Reprod Med.* 1985;30(3):203-5.
5. Vasa R, Kim MR. Fracture of the femur at cesarean section: Case report and review of literature. *Am J Perinatol.* 1990;7(1):46-8.
6. Morris S, Cassidy N, Stephens M, McCormack D, McManus F. Birth associated femoral fractures: Incidence and outcome. *J Pediatrics Orthop.* 2002;22(1):27-30.
7. Toker A, Perry ZH, Cohen E, Krymko H. Cesarean section and the risk of fractured femur. *Isr Med Assoc J.* 2009;11(7):416-8.
8. Rijal L, Ansari T, Trikha V, Yadhav CS. Birth injuries in caesarian sections: Cases of fracture femur and homeruns following caesarian section. *Nepal Med Coll J.* 2009;11(3):207-8.

*Funding: None; Conflict of Interest: None Stated.*

**How to cite this article:** Mishra PK, Gupta AA. Breech presentation and neonatal fracture shaft femur – A rare case presentation. *Indian J Case Reports.* 2017;3(3):148-149.