

Case Report

Two novel mutations with 17 hydroxylase deficiency – Alpha and beta presenting as 46XY disorders of sexual development

Nikhil Lohiya¹, Vaman Khadilkar², Kamini Mehta³, Anuradha Khadilkar⁴

From ¹Fellow, ²Consultant, ⁴Deputy Director, Department of Growth and Pediatric Endocrine, Hirabai Cowasji Jehangir Medical Research Institute, Pune, Maharashtra, India, ³Consultant, Department of Pediatric Nephrology, Kidney Care Clinic for Children

Correspondence to: Dr. Anuradha Khadilkar, Department of Growth and Pediatric Endocrine, Hirabai Cowasji Jehangir Medical Research Institute, Jehangir Hospital, 32, Sassoon Road, Pune - 411 001, Maharashtra, India. E-mail: anuradhavkhadilkar@gmail.com

Received - 08 August 2019

Initial Review - 29 August 2019

Accepted - 04 November 2019

ABSTRACT

17 alpha-hydroxylase and 17 beta-hydroxylase deficiency are rare causes of 46XY disorders of sexual development. The gene for 17 alpha-hydroxylase enzyme (CYP17A1) is located at 10q24.3 and for 17 beta-hydroxylase is (17βHSD3) on 9q22. CYP17A1 can present with delayed puberty and hyporeninemic, hypokalemic hypertension. In 17βHSD3 deficiency, a biochemical pointer to diagnosis includes a stimulated ratio of testosterone (T) to androstenedione (A) of <0.8. We report two cases, one with 17βHSD3 defect in infancy with atypical genitalia and second with CYP17A1 which presented in childhood with novel mutations. There is a wide spectrum of phenotypic presentations of these disorders. Genetic analysis gives confirmation.

Key words: Congenital adrenal hyperplasia, Disorders of sexual development, Endocrine hypertension

Disorders of sexual development (DSD) are congenital conditions where the development of chromosomal, gonadal, or anatomic sex is atypical. Genital development is under the influence of sex steroids. In the steroid pathway, the enzyme 17 alpha-hydroxylase converts pregnenolone and progesterone to 17-hydroxypregnenolone and 17-hydroxy progesterone, respectively. This further progresses to form the dehydroepiandrosterone (DHEA) under the influence of 17, 20-lyase enzyme. 17 alpha-hydroxylase and 17, 20-lyase activities are catalyzed by P450c17 [1]. Sexual dimorphism and reproduction require 17, 20-lyase activity of P450c17 enzyme to synthesize androgens which subsequently get converted to estrogens (Fig. 1). Hence, P450c17 is an exclusive gateway to sex steroid production and both P450c17 and 17βHSD enzymes are critical in the formation of sex steroids.

P450c17 enzyme deficiency is rare and results in congenital adrenal hyperplasia (CAH) and accounts for ~1% cases of CAH [2]. This deficiency may be due to either loss of 17 alpha-hydroxylase activity; 17, 20-lyase; or combined activity. It is often difficult to distinguish these forms and a combined deficiency of both enzymes is often seen. Clinical spectrum varies from unambiguous female external genitalia to atypical genitalia, inguinal hernia, or palpable gonads [3,4]. These conditions usually come to notice during adolescence and often have hyporeninemic, hypokalemic, and hypertension [5].

As 11-βHSD (a form of CAH) also presents with hypertension and atypical genitalia, it is important to perform genetic analysis for a definitive diagnosis. The probability of missing diagnosis has been reported to be as high as 67% [6]. A biochemical pointer

is a stimulated ratio of testosterone (T) to androstenedione (Δ4) of <0.8 [6]. Here, we report two cases, one with 17βHSD3 defect in infancy with atypical genitalia and second with CYP17A1 which presented in childhood with novel mutations.

CASE 1

An 11-month-old reared as female, first born of a non-consanguineous couple (full term, birth weight 2.5 kg), presented with complaints of atypical genitalia noticed by parents since 5 months of age. There were no virilizing features or history of drug intake during antenatal period. There was no family history of atypical genitalia or infertility or gynecomastia noted. There was no history of failure to thrive, vomiting, hypoglycemia, or polyuria.

The child's anthropometric parameters were within reference range [7]. There was no facial dysmorphism on examination. Blood pressure (BP) was 80/58 (normal). There were bilateral palpable gonads in the labioscrotal folds, phallus of 1 cm, slight rugosity, and perineoscrotal hypospadias with a single opening (Prader Stage 3), all suggestive of an undervirilized male (differential diagnosis – ovotesticular DSD, androgen synthetic defect, or disorders of androgen action). Systemic examination was unremarkable.

Ultrasound abdomen showed no Mullerian structures, both gonads were in labioscrotal folds and kidneys appeared to be normal. Karyotype was 46XY. Human chorionic gonadotropin (HCG) stimulation test showed basal testosterone of 0.02 ng/ml (Ref. –0.75–4 ng/ml), dihydrotestosterone 29.8 pg/ml (<98 pg/ml), and A<0.3 ng/ml (0.1–0.3 ng/dl); 72 h after administration of HCG,

T was 4.48 ng/ml, dihydrotestosterone was 92.99 pg/ml, A was 2.9 ng/ml, and T:A ratio was 2. Targeted gene sequencing detected a homozygous missense mutation in exon 1 of the HSD17B3 gene (chr9:99064268G>A; Depth: 152x) that substitutes leucine for proline at codon 40 (p.Pro40Leu; ENST00000375263) (Fig. 2).

A diagnosis of 46 XY 17 β HSD3 deficiency was made. After discussion with parents regarding ease of rearing a DSD child as a girl, the gender of rearing was decided as a female. Parents were counseled for gonadectomy and feminizing genitoplasty surgery.

CASE 2

A 4-year-old child being raised as a girl was referred, with sudden onset progressive weakness in all the 4 limbs, no history of fever, loose stools, vomiting, and diarrhea. She was conscious, alert,

and afebrile with heart rate 136/min, well-felt pulses, respiratory rate of 20/min, spO₂-100%, and BP-160/70 mmHg (Stage 2 hypertension) [8]. Central nervous system examination revealed generalized hypotonia, normal deep tendon reflexes, absent plantar reflexes, and power of Grade 0–1 in all limbs. Other systems were normal.

The electrolyte estimations were suggestive of hypokalemia (2.3 mEq/L [3.3–4.6 mEq/L]) and hypernatremia (150 mEq/L [135–145 mEq/dl]), urinary osmolality was 111.4 mOsm/kg H₂O (275–295 mOsm/kg H₂O), urinary sodium (Na) was 172 mEq/L (normal <20 mEq/L), and potassium (K) was 52 mEq/L (in hypokalemia normal is <25 mEq/L). Cardiac 2D ECHO performed showed normal heart study. Fluids were titrated to maintain Na and K in reference range. BP was not controlled with nifedipine; hence, spironolactone was added. Ultrasonography abdomen

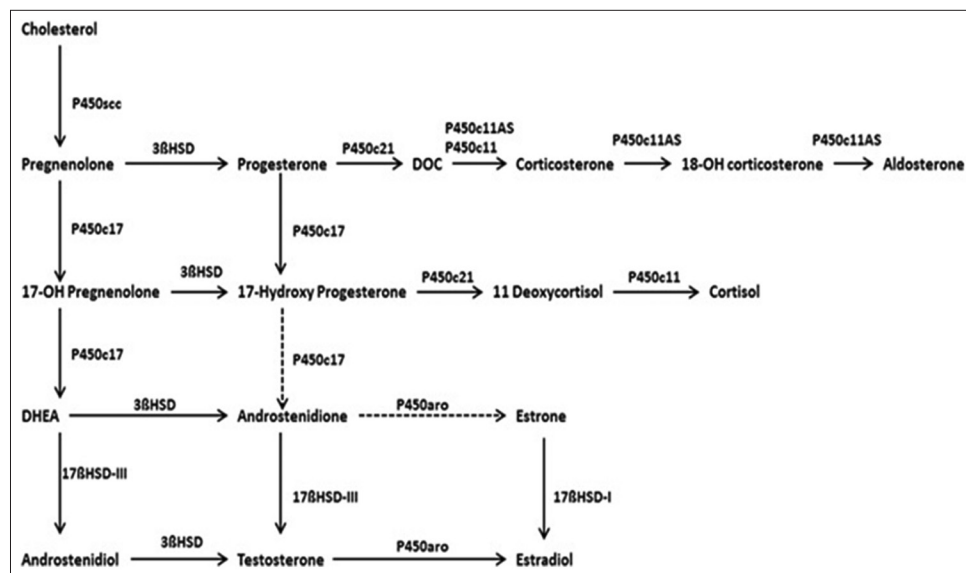


Figure 1: Steroid biosynthetic pathway P450scc – cholesterol side-chain cleavage enzyme, 3BHS – 3-beta-hydroxysteroid dehydrogenase, P450c21 – 21-alpha-hydroxylase, P450c17 – 17-alpha-hydroxylase, and 17BDSH-III – 17-beta-hydroxysteroid dehydrogenase 3. P450c11, P450c11b, and P450c11AS catalyze 11b-hydroxylase, 18-hydroxylase, and 18-methyl oxidase activities, respectively. P450aro – aromatase

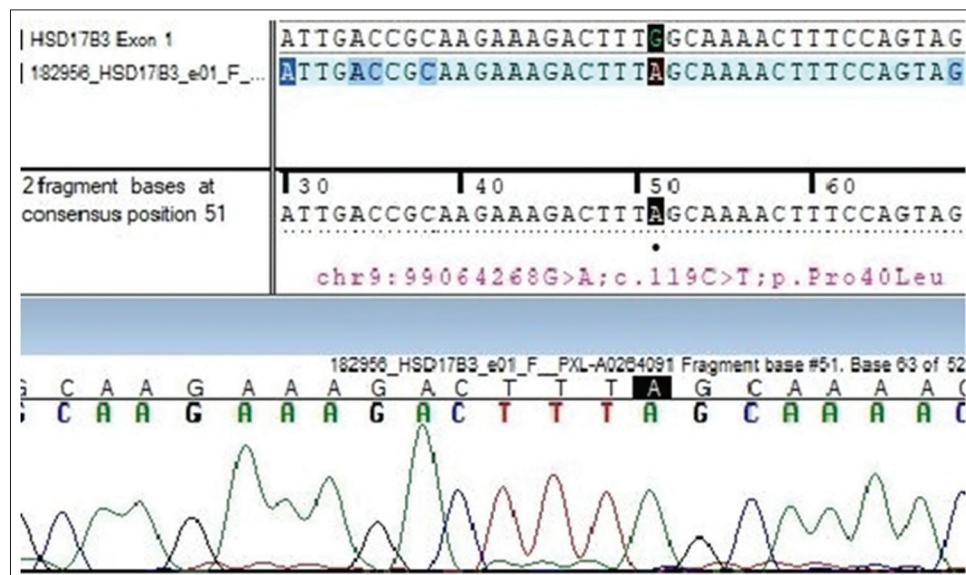


Figure 2: Chromatogram showing homozygous missense mutation in exon 1 of the HSD17B3 gene (chr9:99064268G>A; Depth: 152x) that results in the substitution of leucine for proline at codon 40 (p.Pro40Leu; ENST00000375263) in case 1

showed bilateral testes in inguinal canal (right – 9.3 mm×4.2 mm and left – 12 mm×5.7 mm) and no Mullerian structures.

Child's BP was controlled and electrolytes remained normal. She gradually regained power and at discharge was ambulatory with Grade 5 power. Differential diagnosis of 11 beta-hydroxylase steroid dehydrogenase enzyme deficiency or 17 alpha-hydroxylase steroid dehydrogenase enzyme deficiency was considered. Serum cortisol was 1.33 (3–21 mcg/dl), ACTH was 46.2 pg/ml (6–48 pg/ml), serum aldosterone was 4.36 ng/dL (3–35 ng/dl), plasma renin activity was 38 ng/dl/h (50–580 ng/dl/h), T was 1.61 ng/dL (<0.2–3.4 ng/dL), DHEAS was 19.3 mcg/dL (<5–57 mcg/dL), and A was <3 ng/dL (10–17 ng/dL). Karyotype was 46 XY, targeted exome sequencing identified homozygous variant (chr10:104591264C>T c.1243+1G>A) in the essential splice donor site in intron 7 of CYP17A1 gene.

Silico splice prediction tools (NNSPLICE and MaxEntScan) suggested that this variant may affect splicing due to loss of constitutive splice site and introduction of a new one which leads to frame shift and consequent premature termination of protein that likely results in loss of function (Fig. 3). Oral hydrocortisone was started; weakness and electrolytes subsequently improved. Spironolactone, nifedipine, and oral K supplements were tapered and stopped. Gonadectomy was planned and since the external genitals were female, steroid synthesis was impaired, and after parental discussion, child reared as a girl.

DISCUSSION

CYP17A1 mutations lead to disruption of steroid synthesis in both the adrenals and gonads. Individuals with both 46XX and 46XY karyotype have female external genitalia as there are no testosterone and dihydrotestosterone in fetal life (Leydig cells function). Mullerian structures are not present in patients with 46XY as the anti-Mullerian hormone is preserved (Sertoli cells function) [3]. Although adrenal steroid and cortisol synthesis

are impaired in CYP17A1 defects, there is no glucocorticoid deficiency as corticosterone substitutes for cortisol, and thus adrenal crisis is rare.

Hypertension and hypokalemia are seen due to accumulation of deoxycortisone (DOC). Hypertension responds to mineralocorticoid receptor antagonists [9]. Hence, these children need replacement of physiological glucocorticoids, which help in relieving hypertension. The spectrum of clinical presentation in 46XY children may be atypical genitalia, inguinal hernia, or abdominal testes in infancy or primary amenorrhea and absent secondary sexual characteristics with hypertension and hypokalemia in adolescence [10].

CYP17A1 (located on chromosome 10q24.3) has been found to have 8 exons. Over 100 mutations in CYP17A1 gene have been associated with combined 17-hydroxylase/17, 20-lyase deficiency (OMIM 202110), including point mutations, small insertions or deletions, splice site alterations, and, rarely, large deletions [3]. Many of these mutations occur at C-terminus hence highlighting significance of the last 14 amino acids. We report a frameshift mutation that has not been reported previously.

Children with 17βHSD3 deficiency have female appearing genitalia and hence are commonly assigned female gender. Patients present later in childhood with inguinal hernia and clitoromegaly; during puberty, they present with virilization and amenorrhea [11,12]. In the index case 1, parents noticed a palpable mass and hence, DSD was suspected. There is usually no significant virilization in these patients, this is attributed to limited fetal extragonadal capacity of converting androstenedione (Δ4) to testosterone (T), and hence, external genitals are not masculinized [13].

17βHSD3 is the enzyme responsible for conversion of Δ4 to T and DHEA to androstenediol. When 17βHSD3 enzyme is deficient, higher Δ4 is found, and hence, the stimulated ratio of T/Δ4<0.8 is said to be a diagnostic indicator of 17βHSD3 deficiency [6]. This ratio is also low in patients who have 46 XY dysgenic

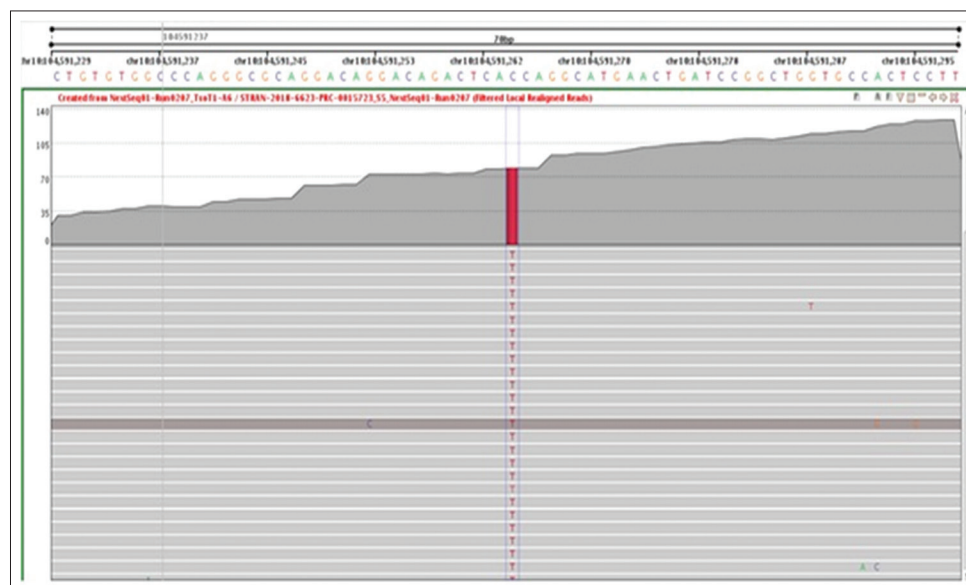


Figure 3: Homozygous variant (c.1243+1G>A) lies in essential splice donor site in intron 7 of CYP17A1 gene. *In silico* splice prediction tools (NNSPLICE and MaxEntScan) suggest that this variant may affect splicing due to loss of constitutive splice site

gonads and in some cases, with partial androgen insensitivity and complete androgen insensitivity [6]. However, higher ratios have been reported in many genetically confirmed cases of 17BHS3 deficiency; thus, genetic testing is important [12,14]. Hence, the diagnosis cannot be absolutely relied on the biochemistry and genetic confirmation is needed. In the index case, stimulated T/ Δ 4 ratio was higher than the suggested cutoff and T:DHT ratio was also high; thus, genetic analysis for all 3 genes, i.e., 5-alpha reductase, androgen insensitivity, and 17BHS3 were performed.

Alterations in the gene of 17 β HSD3 as an etiology of DSD have been identified and more than 47 mutations have been reported [15], which include nonsense, missense, exonic deletions, intronic splice site duplication, and amplification mutations. The most common mutations in Southeast Asian populations are C268Y and A56T. We found a novel, hitherto unreported mutation in our patients with 17BHS3 deficiency.

CONCLUSION

Defects in 17BHS3 and CYP17A are known causes of DSD and have a varied presentation. A high index of suspicion is needed especially in children with hypertension and electrolyte disturbances. Genetic analysis is required to confirm the diagnosis.

REFERENCES

1. Miller LW, Brooks CG, Clayton PE, Brown RS. Brook's Clinical Pediatric Endocrinology, The Adrenal Cortex and its Disorders. 6th ed., Ch. 13. New Jersey: Willey-Blackwell; 2009.
2. Oh YK, Ryoo U, Kim D, Cho SY, Jin DK, Yoon BK, *et al.* 17 α -hydroxylase/17, 20lyase deficiency in three siblings with primary amenorrhea and absence of secondary sexual development. *J Pediatr Adolesc Gynecol* 2012;25:e1035.
3. Auchus RJ. Steroid 17-hydroxylase and 17,20-lyase deficiencies, genetic and pharmacologic. *J Steroid Biochem Mol Biol* 2017;165:71-8.

4. Philip J, Anjali, Thomas N, Rajaratnam S, Seshadri MS. 17-Alpha hydroxylase deficiency: An unusual cause of secondary amenorrhoea. *Aust N Z J Obstet Gynaecol* 2004;44:477-8.
5. Kota SK, Modi K, Jha R, Mandal SN. 17- α -Hydroxylase deficiency: An unusual case with primary amenorrhea and hypertension. *Indian J Endocrinol Metab* 2011;15:127-9.
6. Ahmed SF, Iqbal A, Hughes IA. The testosterone: Androstenedione ratio in male undermasculinization. *Clin Endocrinol (Oxf)* 2000;53:697-702.
7. de Onis M, Onyango AW, Borghi E, Siyam A, Nishida C, Siekmann J. Development of a WHO growth reference for school-aged children and adolescents. *Bull World Health Organ* 2007;85:660-7.
8. Raj M, Sundaram R, Paul M, Kumar K. Blood pressure distribution in children. *Indian Pediatr* 2010;47:477-85.
9. Gupta V. Mineralocorticoid hypertension. *Indian J Endocrinol Metab* 2011;15 Suppl 4:S298-312.
10. Biglieri EG, Kater CE. 17 α -hydroxylation deficiency. *Endocrinol Metab Clin North Am* 1991;20:257-68.
11. Geissler WM, Davis DL, Wu L, Bradshaw KD, Patel S, Mendonca BB, *et al.* Male pseudohermaphroditism caused by mutations of testicular 17 beta-hydroxysteroid dehydrogenase 3. *Nat Genet* 1994;7:34-9.
12. Lee YS, Kirk JM, Stanhope RG, Johnston DI, Harland S, Auchus RJ, *et al.* Phenotypic variability in 17 β -hydroxysteroid dehydrogenase-3 deficiency and diagnostic pitfalls. *Clin Endocrinol* 2007;67:20-8.
13. Ösler A, Silverstein S, Abeliovich D. A (R80Q) mutation in 17 beta-hydroxysteroid dehydrogenase Type 3 gene among arabs of Israel is associated with pseudohermaphroditism in males and normal asymptomatic females. *J Clin Endocrinol Metab* 1996;81:1827-31.
14. Khattab A, Yuen T, Yau M, Domenice S, Costa EM, Diya K, *et al.* Pitfalls in hormonal diagnosis of 17-beta hydroxysteroid dehydrogenase III deficiency. *J Pediatr Endocrinol Metab* 2014;28:623-8.
15. Yang Z, Ye L, Wang W, Zhao Y, Wang W, Jia H, *et al.* 17 β -Hydroxysteroid dehydrogenase 3 deficiency: Three case reports and a systematic review. *J Steroid Biochem Mol Biol* 2017;174:141-5.

Funding: None; Conflict of Interest: None Stated.

How to cite this article: Lohiya N, Khadilkar V, Mehta K, Khadilkar A. Two novel mutations with 17 hydroxylase deficiency – Alpha and beta presenting as 46XY disorders of sexual development. *Indian J Child Health* 2019; November 21 [Epub ahead of print].