

## Case Report

## Transient myeloproliferative disorder: A pointer to underlying trisomy 21

Sharan Subramanian<sup>1</sup>, Sushma Malik<sup>2</sup>, Purvi Kadakia Kutty<sup>3</sup>, Poonam Abhay Wade<sup>4</sup>

From <sup>1</sup>Ex-Resident, <sup>2</sup>Professor and Head, <sup>3</sup>Associate Professor, Department of Pediatrics, Topiwala National Medical College and BYL Nair Charitable Hospital, <sup>4</sup>Hematology and Oncology Consultant, Department of Pediatrics, Lokmanya Tilak Municipal Medical College and General Hospital, Mumbai, Maharashtra, India

**Correspondence to:** Dr. Sushma Malik, Department of Pediatrics, 1<sup>st</sup> Floor, College Building, Topiwala National Medical College and BYL Nair Charitable Hospital, Mumbai Central, Mumbai - 400 008, Maharashtra, India. E-mail: [sushmamalik@gmail.com](mailto:sushmamalik@gmail.com)

Received - 08 April 2019

Initial Review - 24 April 2019

Accepted - 18 May 2019

## ABSTRACT

A 19-day-old male neonate was presented with abdominal distension, refusal to feed, and high-grade fever, suggestive of late-onset sepsis. Apart from a suspected clinodactyly, no dysmorphism was present. The hemograms were suggestive of leukocytosis with 29% blasts and flow cytometry revealed acute myeloid leukemia. Due to the presence of congenital leukemia, the dysmorphism in the child was investigated and a karyotype revealed trisomy 21; a diagnosis of transient myeloproliferative disorder (TMD) was made. The child developed significant bleeding, impending congestive cardiac failure and significant weight loss, and prompting initiation of low-dose chemotherapy with cytarabine. The child improved following therapy but developed fungal sepsis and multiple joint osteomyelitis secondary to the chemotherapy-induced myelosuppression which was managed with antibiotics. The child was discharged and is on close 3 monthly follow-up to screen for acute megakaryoblastic leukemia, as babies with TMD are prone to developing acute megakaryoblastic leukemia in early childhood.

**Key words:** Acute megakaryoblastic leukemia, Congenital leukemia, Transient myeloproliferative disorder, Trisomy 21

**T**ransient myeloproliferative disorder (TMD) is a disorder almost exclusively reported in infants with Down syndrome (DS), with an incidence of approximately 4–10% [1,2]. It is characterized by increased numbers of circulating megakaryoblasts and multisystem involvement. Often, the clinical and morphological features may be indistinguishable from DS-related acute megakaryoblastic leukemia (DS-AMKL). The presence of either the former or the latter in an apparently normal newborn must prompt a detailed evaluation for an underlying syndrome, especially trisomy 21. TMD usually undergoes spontaneous remission in 2–3 months and does not require chemotherapeutic intervention; however, severe or life-threatening features may warrant chemotherapy [1]. About 20–30% of neonates with TMD develop DS-AMKL within 3–4 years of life and need regular follow-up and screening for the same [1,2].

## CASE REPORT

A male neonate presented at 19 days of life with complaints of abdominal distension, umbilical discharge, high-grade fever, and refusal to feed. The neonate was born by a full-term vaginal delivery to a 26-year-old gravida-3, para-2, living-2 mother with an uneventful antenatal period. He was born of a non-consanguineous marriage and his birth weight was 2590 g and birth order was third. Although no anomaly scan was done, two routine obstetric ultrasound scans in the third trimester were documented normal. The baby had an unremarkable postnatal course in the

hospital and was discharged on exclusive breastfeeds. However, the mother reported intermittent feeding difficulty at home in the form of poor latching to the breast in the first 2 weeks of life.

On admission at our centre (Fig. 1), the neonate was lethargic, hemodynamically stable, with a patchy erythematous rash over the face and limbs, generalized abdominal distension with hepatosplenomegaly (liver 5 cm in the midclavicular line and spleen 3 cm along the splenic axis) and shifting dullness. Physical examination revealed no gross dysmorphic or syndromic features except for a suspected clinodactyly.

A provisional diagnosis of late-onset sepsis with suspected meningitis was made; a lumbar puncture was done which was normal. The hemogram report at admission showed a white blood cell (WBC) count of 72,800/mm<sup>3</sup>. The hemoglobin (Hb) was 17.0 g/dL and platelet count was 242,000/mm<sup>3</sup>. Repeat hemograms on day 2 and 3 of admission showed persistently raised WBC count of 74,200/mm<sup>3</sup> and 71,600/mm<sup>3</sup>, respectively. The liver function tests showed total bilirubin of 2.1 mg/dl with aspartate aminotransferase and alanine aminotransferase being 72 IU/L and 52 IU/L, respectively, and lactate dehydrogenase was 1325 U/L.

The peripheral smear (Fig. 2) revealed 29% blasts with cytoplasmic blebs suggestive of megakaryoblasts. The bone marrow aspirate and biopsy samples were inadequate to diagnose acute leukemia. The peripheral blood flow cytometry revealed acute myeloid leukemia (CD33+, CD117+) with CD7, CD38, CD34, and HLA-DR expression but negative for CD3, CD19, and CD20. Cytogenetic study of the bone marrow aspirate revealed

no MLL gene translocation. The child was started on hydroxyurea (10 mg/kg/day) in view of the persistently high counts to prevent leukostasis and associated morbidity. Following this, the WBC count dropped to 36,100/mm<sup>3</sup> within a few days.

In the setting of congenital acute leukemia, the mild dysmorphism in the baby was revisited. Hall's criteria for the diagnosis of Down's syndrome were applied but negative [3]. A peripheral blood karyotype detected trisomy 21 in all the 15 metaphases studied. In light of the above findings, a revised diagnosis of myeloid proliferation related to DS was made, with a high probability of TMD.

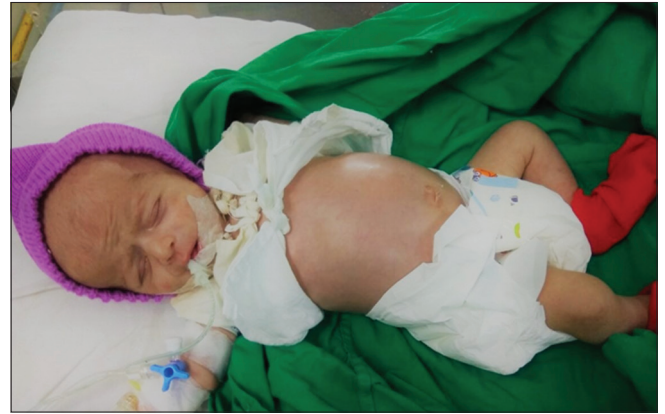The neonate developed malena, hematochezia, and resultant anemia with congestive cardiac failure requiring a blood and fresh frozen plasma transfusions. The PT/INR was 17/1.3 and echocardiography showed a thin rim of pericardial effusion. Tumor lysis markers were monitored daily after starting hydroxyurea and appropriately managed. Gross ascites was documented on serial ultrasound scans, and significant weight loss ensued (Fig. 3) which was tackled by calorie-dense feeding.

In view of the stormy course that the baby was going through, unrelenting gross ascites and clinically significant bleeding, the chemotherapeutic intervention was started with cytarabine (1 mg/kg/day) given subcutaneously for 5 days. Following its administration, normalization of WBC counts (12,300/mm<sup>3</sup>), weight gain, and improvement in the clinical condition were seen over the next 2 weeks. A repeat flow cytometry and bone marrow study showed no evidence of blasts. However, the neonate developed anemia and leukopenia following chemotherapy which reached its nadir a week after administration (Hb=7.0 g/dL, WBC count=3700/mm<sup>3</sup> with an absolute neutrophil count of 1147/mm<sup>3</sup>) and recovered in the following week. Subsequently, neonate developed *Candida glabrata* sepsis with osteomyelitis at multiple sites, which was managed with both antibacterial and antifungal agents for 6 weeks. The child was discharged after 4 months of intensive care with hemogram monitoring at 3 monthly intervals to screen for progression to DS-AMKL.

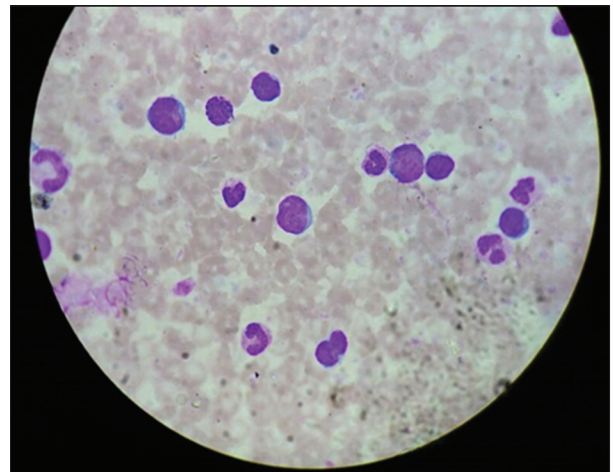
No congenital anomalies were discovered on echocardiography. Thyroid profiles done at birth and at 1 year of age were normal. Otoacoustic emission screening at birth and brainstem evoked response audiometry at 4 months of age revealed hearing sensitivities within normal limits bilaterally. The dysmorphic phenotype consistent with DS became more noticeable with advancing age. At 8, 10, 12, and 15 months of age, the child was hemodynamically stable on follow-up with no features of neoplastic progression. The hemogram done at 15 months revealed Hb of 11.6 g/dL, WBC count of 8800/mm<sup>3</sup>, and platelet count of 299,000/mm<sup>3</sup>. The child was developmentally delayed in the gross motor and speech domains when examined at both 8 and 15 months. At 15 months, he was able to stand with support and speak monosyllables. Milestones in the fine motor and social domains were appropriate for age.

## DISCUSSION

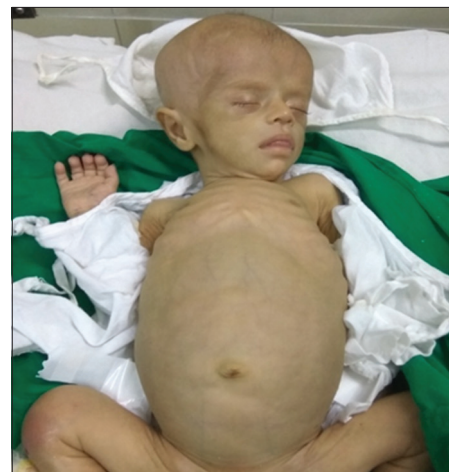Trisomy 21 or DS is the most common chromosomal abnormality in humans and confers a higher risk of developing leukemia in childhood. Occasionally, when the phenotypic features are subtle,



**Figure 1: Neonate on admission, with gross abdominal distension, no dysmorphic features present**



**Figure 2: Peripheral smear reveals atypical cells with high nucleocytoplasmic ratio and scanty, gray-blue cytoplasm with blebs, suggestive of megakaryoblasts**



**Figure 3: Neonate on day of life 40 shows marked emaciation with dysmorphism becoming more apparent**

as in our case, or in a mosaic; the occurrence of TMD may be the first indication that the child has trisomy 21. In this situation, the application of Hall's criteria may aid in the diagnosis; however, the diagnostic gold standard remains karyotyping.

Flow cytometry may show assorted coexpression of stem cell markers (CD34 and CD117), myeloid markers (CD33/CD13),

and megakaryocyte markers (CD36, CD41, CD42b, and CD61) together with CD56, CD7, and HLA-DR expression [2,4]. Flow cytometry revealed a predominance of myeloid series markers in the child; however, CD41 and CD61 were not done as TMD and DS were not suspected initially. The repeat flow cytometry done after cytarabine therapy revealed no blasts, and hence, immunohistochemistry could not be done. The diagnosis of TMD could not be confirmed by a GATA-1 mutation study due to financial limitations but was the most probable diagnosis in this clinical context.

Nearly 80% of TMD cases remit spontaneously; however, ominous features such as hydrops fetalis with gross ascites, extreme leukocytosis ( $WBC > 100 \times 10^6/dL$ ), hepatopathy, diffuse intravascular coagulation (DIC) with bleeding, and renal and/or cardiac failure may increase mortality up to 20% [1]. Ascites, clinically significant bleeding and weight loss complicated the course of the child in the neonatal intensive care unit. Low-dose cytarabine may be considered in such life-threatening situations as its metabolism in children with trisomy 21, is decreased with a consequent increase in drug efficacy and incidence of myelosuppression [2].

The Berlin-Frankfurt-Münster group recommended treatment with cytarabine (0.5–1.5 mg/kg for 3–12 days) for high-risk neonates with TMD [5]. They reported similar survival in the treatment and non-treatment groups, suggesting that cytarabine may have been effective, considering that the treated neonates had more severe disease. A higher dose of 3.33 mg/kg/day used in the “Children Oncology Group Study A2791” revealed a poor survival rate of 51%, with 96% incidence of Grade 3/4 myelosuppression following administration [6]. In another study by the pediatric oncology group (9481), three children received low-dose cytarabine (0.4–1.5 mg/kg every 12 h for 5 or 7 days) and all of them showed remission [7]. However, no data exist as to whether cytarabine offers any protection from progress to acute megakaryoblastic leukemia in these children in the future.

Incidence of DS-AMKL is estimated to be 500 times more than in children without DS. It occurs in 20–30% of TMD cases and manifests within the first 3 years of life, which is earlier as compared to AMKL in children without DS. Thus, after remission of TMD is documented, regular screening of clinical

and hematological parameters (with a hemogram and peripheral smear) to detect its onset is essential.

## CONCLUSION

A hematological picture suggestive of myeloid leukemia or TMD in a neonate without clear features of DS must be carefully evaluated to rule out underlying trisomy 21. Although most cases remit spontaneously, the presence of life-threatening complications such as CCF or DIC may warrant chemotherapy. Regular follow-up is required to screen the child for DS-AMKL as 20–30% neonates with TMD develop AMKL in early childhood.

## REFERENCES

1. Bhatnagar N, Nizery L, Tunstall O, Vyas P, Roberts I. Transient abnormal myelopoiesis and AML in down syndrome: An update. *Curr Hematol Malig Rep* 2016;11:333-41.
2. Bombery M, Vergilio JA. Transient abnormal myelopoiesis in neonates: GATA Get the diagnosis. *Arch Pathol Lab Med* 2014;138:1302-06.
3. Hall B. Mongolism in newborn infants. An examination of the criteria for recognition and some speculations on the pathogenic activity of the chromosomal abnormality. *Clin Pediatr (Phila)* 1966;5:4-12.
4. Baloda V, Subramanian PG, Badrinath Y, Kumar A, Amare PS, Banavali SD, *et al.* Transient abnormal myelopoiesis: A case series and review of the literature. *Pediatr Hematol Oncol J* 2017;2:14-8.
5. Klusmann JH, Creutzig U, Zimmermann M, Dworzak M, Jorch N, Langebrake C, *et al.* Treatment and prognostic impact of transient leukemia in neonates with down syndrome. *Blood* 2008;111:2991-8.
6. Gamis AS, Alonzo T, Gerbing R, Hilden J, Sorrell AD, Sharma M, *et al.* Natural history of transient myeloproliferative disorder clinically diagnosed in down syndrome neonates: A report from the children’s oncology group study A2971. *Blood* 2011;118:6752-9.
7. Al-Kasim F, Doyle J, Massey G, Weinstein H, Zipursky A. Incidence and treatment of potentially lethal diseases in transient leukaemia of down syndrome: Pediatric oncology group study. *J Pediatr Hematol Oncol* 2002;24:9-13.

*Funding: None; Conflict of Interest: None Stated.*

**How to cite this article:** Subramanian S, Malik S, Kutty PK, Wade PA. Transient myeloproliferative disorder: A pointer to underlying trisomy 21. *Indian J Child Health*. 2019; 6(6):332-334.

Doi: 10.32677/IJCH.2019.v06.i06.017