

# Case Report

## Absence of bones at birth - A diagnostic dilemma

Vernika Tyagi<sup>1</sup>, Ashish Jain<sup>2</sup>, Abhishek Chopra<sup>3</sup>

From <sup>1</sup>Senior Resident, Department of Pediatrics, <sup>2</sup>Assistant Professor, <sup>3</sup>Associate Professor, Department of Neonatology, Maulana Azad Medical College, New Delhi, India

**Correspondence to:** Dr. Ashish Jain, Department of Neonatology, Ward 38, LNJP & Allied Hospitals Gate No 2 LNJP Hospital, 2 Bahadur Shah Zafar Marg, New Delhi 110002, Delhi, India. E-mail: ashish.jain.mamc@gmail.com

Received - 16 September 2018

Initial Review - 08 October 2018

Accepted - 03 November 2018

### ABSTRACT

We present a male stillborn baby, born with disproportionate body and omphalocele. The infantogram revealed the absence of mineralization of all the bones, except for a minimal ossification of the ribs and spine. The possibilities that can be considered in such a case of absent mineralization at birth are very few. A definite diagnosis can be made on detailed clinical examination and the specific pattern of bone mineralization. The classical phenotypic features, associated anomalies, and the pattern of mineralization facilitated in diagnosing the rare entity, boomerang syndrome. Although the diagnosis should be confirmed by genetic studies, it is important to know the classical phenotypic and radiological features of boomerang dysplasia as it is often mistaken as achondrogenesis.

**Key words:** *Under mineralized bones, Boomerang syndrome, Disproportionate body*

Skeletal dysplasias are developmental disorders of chondro-osseous tissues or an “abnormal organization of cells into tissue and its morphologic result.” [1] The severe forms of dysplasia have a variable degree of the loss of mineralization. Of these, achondrogenesis is one of the most severe forms of congenital chondrodysplasia characterized by small body, short limbs, and other skeletal abnormalities. However, there are other rarer dysplasias with similar loss of mineralization and other associated anomalies. One such close rare differential is boomerang dysplasia (BD). BD is a rare lethal skeletal dysplasia that was first reported by Kozlowski *et al.* in 1981 and is characterized by decreased ossification of cranium and vertebral bodies and incomplete or absent ossification of long bones that are characteristically curved or boomerang like.

This is a rare lethal skeletal dysplasia characterized by severe short-limbed dwarfism, dislocated joints, club feet, distinctive facies, and diagnostic X-ray findings of under ossified and dysplastic long tubular bones, with a variable boomerang-like bowing of bones. There are also associated omphalocele and male predilection seen in these cases [2,3].

The incidence of BD was estimated to be 1/1,222,698 live-born infants and results from sporadic missense mutations or small in-frame deletions in the Filamin B (FLNB) gene reported in exons 2-5 [4,5]. Multinucleated giant cells are found among chondrocytes in the growth plate of individuals with BD. These appearances could result from defective cell cleavage during the proliferation of chondrocytes within the epiphyseal growth plate.

### CASE REPORT

A stillborn male baby was, delivered at 32 weeks of gestation to a 30-year-old second gravida mother, an outcome of spontaneous conception through a non-consanguineous marriage. There was no history of any drug intake or radiation exposure in mother. The previous baby was alive, male, and healthy with no dysmorphism and currently is 2½ years. Antenatal scan at 24 weeks of gestation showed gross subcutaneous edema with pleural effusion, small posterior fossa with lissencephaly, improper formation of long bones in all four limbs, poorly visualized spine, and myelomeningocele in the sacral region. The pregnancy could not be terminated as a period of gestation was >20 weeks. Hence, at 32 weeks, the baby was delivered by spontaneous labor. The baby had nil fetal heart rate on fetal surveillance before delivery.

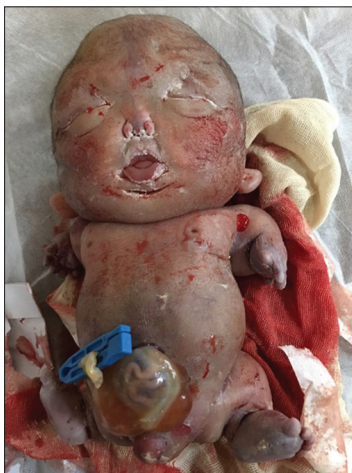At birth, the baby was found to be grossly hydropic with a disproportionate body. There was apparent macrocephaly with a head circumference of 41 cm and a prominent forehead. There was facial dysmorphism with marked hypertelorism, flat broad nasal bridge, mid-facial hypoplasia, and micrognathia. The baby additionally had severe micromelia, narrow chest, and exomphalos measuring about 6×6 cm with herniation of intestinal loops. The genitals of the baby were normal in appearance (Fig. 1). Hands and feet were short and broad, but all digits were present in appropriate numbers. Elbow and knee joints were indiscernible, and there was no cleft lip or palate. On examining the infantogram, there was the absence of mineralization of all the bones, except for minimal ossification of the ribs and spine. The orbits also could not be differentiated from the skull as shown in

Fig. 2. The phenotypic and radiological features were similar to the previously described cases.

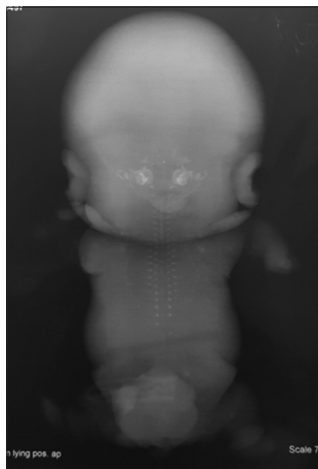
The possible diagnoses, considered in view of the poor mineralization of bones at birth, were achondrogenesis and hypophosphatasia. However, the classical phenotypic features, associated anomalies, and the pattern of mineralization facilitated in diagnosing the rare entity, boomerang syndrome.

## DISCUSSION

Despite the extensive knowledge about skeletal dysplasia and their elaborate classification, skeletal dysplasias with the poor or no mineralization of bones at birth are few and some of them are very rare. Among them, a few to be considered in particular are achondrogenesis, campomelic dysplasia, Roberts syndrome, and thanatophoric dysplasia. These can be often diagnosed on a detailed assessment of the clinical examination, associations, and the pattern of the loss of mineralization. The severity of decreased ossification and phenotypic features helped in pointing out the diagnosis of BD.



**Figure 1: Stillborn male baby with hypertelorism, flat broad nasal bridge, midfacial hypoplasia, severe micromelia, narrow chest, and exomphalos**



**Figure 2: Infantogram revealing the absence of mineralization of all bones with minimal ossification of the ribs and the spine**

The main clinical characteristic of BD is the severe and symmetric micromelia of all four limbs with poorly discernable large joints and talipes equinovarus. The hands and feet are short and broad and have shortened fingers and toes with poly- or oligodactyly, syndactyly, and hypoplastic nails. The skull has a normal occipitofrontal circumference but looks macrocephalic because of the dwarfism. Midfacial hypoplasia, flat and broad nasal bridge, hypertelorism, nasal hypoplasia, and micrognathia are frequent findings, and cleft palate is sometimes present. The thorax is usually small and bell shaped, whereas the abdomen is protuberant. Internal anomalies are infrequent apart from omphalocele [6-8].

Typical radiologic features include hypoplasia, deformation, and diminished ossification of the long tubular bones, severe hypoplasia of metacarpals, and phalanges with reduced ossification in the proximal and middle but not in the distal phalanges and diminished ossification of the vertebral bodies. One of the most typical features is the discrepancy in size between the 3 long tubular bones, with especially the humeri and the femora being invisible on X-rays either because they are absent or uncalcified [4]. The other phenotypic features which are commonly seen are omphalocele, encephalocele, underdeveloped nasal bridge and underdeveloped rib cage leading to respiratory insufficiency. The affected individuals are usually stillborn or die shortly after birth from respiratory failure.

Autosomal recessive spondylocarpotarsal syndrome, atelosteogenesis types I and III, dominant form Larsen syndrome, and BD form a spectrum of skeletal dysplasia with overlapping clinical phenotype [5]. These disorders are characterized by a common genetic mutation of FLNB gene; however, the clinical phenotype varies in severity. BD is distinguished from AO on the basis of a more severe defect in mineralization, with complete absence of ossification in some limb elements and vertebral segments [9]. Diagnosis of this rare entity can be confirmed from skeletal radiographs, chondro-osseous histopathology, and genetic testing [2]. However, in our case, the genetic testing could not be done.

## CONCLUSION

The skeletal dysplasia with poor or no mineralization at birth is a diagnostic dilemma that can be faced by a pediatrician. The causes for such occurrences are few, and many cases including the rare ones can be diagnosed based on the clinical associations and the pattern of bone mineralization. The knowledge of this is important in evaluating such cases.

## REFERENCES

1. Spranger JW, Brill P W, Poznanski AK. Bone Dysplasias: An Atlas of Genetic Disorders of Skeletal Development. New York, NY: Oxford University Press; 2000.
2. Bicknell LS, Morgan T, Bonafè L, Wessels MW, Bialer MG, Willems PJ, *et al.* Mutations in FLNB cause boomerang dysplasia. *J Med Genet* 2005;42:e43.
3. Kozłowski K, Sillence D, Cortis-Jones R, Osborn R. Boomerang dysplasia. *Br J Radiol* 1985;58:369-71.

4. Wessels MW, Den Hollander NS, De Krijger RR, Bonifè L, Superti-Furga A, Nikkels PG, *et al.* Prenatal diagnosis of boomerang dysplasia. *Am J Med Genet A* 2003;122A:148-54.
5. Krakow D, Robertson SP, King LM, Morgan T, Sebald ET, Bertolotto C, *et al.* Mutations in the gene encoding filamin B disrupt vertebral segmentation, joint formation and skeletogenesis. *Nat Genet* 2004;36:405-10.
6. Lam AC, Hu SJ, Tong TM, Lam S. Boomerang dysplasia in a Chinese female fetus. *HK J Paediatr (new series)* 2006;11:324-6.
7. Temple K, Hall CA, Chitty L, Baraitser M. A case of atelosteogenesis. *J Med Genet* 1990;27:194-7.
8. Yang SS, Roskamp J, Liu CT, Frates R, Singer DB. Two lethal chondrodysplasias with giant chondrocytes. *Am J Med Genet* 1983;15:615-25.
9. Greally MT, Jewett T, Smith WL Jr., Penick GD, Williamson RA. Lethal bone dysplasia in a fetus with manifestations of atelosteogenesis I and Boomerang dysplasia. *Am J Med Genet* 1993;47:1086-91.

*Funding: None; Conflict of Interest: None Stated.*

**How to cite this article:** Tyagi V, Jain A, Chopra A. Absence of bones at birth - A diagnostic dilemma. *Indian J Child Health*. 2018; 5(11):706-708.

Doi: 10.32677/IJCH.2018.v05.i11.014