

Unwanted penile engorgement in pediatric patients under anesthesia: The role of anesthetic technique and other contributing factors

Muazzam Hasan¹, Abu Nadeem¹, Nadeem Raza¹, Syed Moied Ahmed²

¹Assistant Professor; ²Professor, Department of Anaesthesiology and Critical Care, Jawaharlal Nehru Medical College, Aligarh Muslim University, Aligarh, India

Correspondence to: Dr. Nadeem Raza, Department of Anaesthesiology and Critical Care, Jawaharlal Nehru Medical College, Aligarh Muslim University, Aligarh, India. E-mail: nadeemraza03@gmail.com

Received – 05 April 2018

Initial Review – 14 May 2018

Accepted – 02 June 2018

ABSTRACT

Background: The mechanism behind intraoperative penile engorgement (PE) is complex. One common myth is that PE occurs more frequently during spinal anesthesia than the general anesthesia. **Objective:** The objective of this study was to report the incidence and management of intraoperative PE in pediatric patients undergoing urogenital operations under spinal anesthesia with or without sedation over a period of 1 year. **Methods:** Patients aged between 2 and 12 years, posted for elective urogenital surgery of expected duration <1 h, were given spinal anesthesia with or without supplemental sedation as per child's cooperation. Incidence of unwanted intraoperative PE, time of onset of the SA, length of surgery, attempts of successful lumbar puncture, need for supplemental systemic sedation, conversion to general anesthesia, and perioperative complications were recorded. **Results:** A total of 348 patients were included in the study. Only two (0.005%) cases developed PE intraoperatively. 225 (64.6%) children required systemic sedation along with spinal blockade. 123 (35.3%) cases were successfully operated under spinal alone without any sedation. None of the cases required conversion into general anesthesia. The mean time of onset of spinal blockade was 100±54 s. First attempt success rate of lumbar puncture was 83% while 16.9% of patients required the second attempt. There were no major complications in any child in the perioperative period. **Conclusion:** Spinal anesthesia is associated with very less incidence of PE and can be practiced safely in the pediatric patients. Just the fear of development of PE should not bias the choice of anesthetic technique toward general anesthesia.

Key words: *Intraoperative penile engorgement, Pediatric anesthesia, Urogenital surgery*

Urogenital procedures such as chordee correction, urethroplasty, and cystoscopic fulguration of posterior urethral valve are commonly performed procedures in pediatric surgery. Although intraoperative penile engorgement (PE) in pediatric patients is infrequently reported, it is very difficult to perform the procedure during penile erection and surgery may be delayed or postponed. Intraoperative PE is mostly idiopathic; however, it may be caused by anesthesia.^[1,2]

Many anesthesiologists avoid regional anesthesia like spinal blockade in children just due to the misconception that there is higher incidence of the development of intraoperative PE after spinal blockade. This leads to undue biases toward the choice of anesthetic technique and exposure of the child to general anesthesia. Primarily, the incidence of PE under spinal anesthesia, role of various common contributing factors, anesthetic technique, and drugs in the development of PE are being discussed in this study. To the best of our knowledge, there are very few studies discussing the anesthetic view of the development of intraoperative PE in pediatric patients.

MATERIALS AND METHODS

This observational study was conducted at the Department of Anaesthesiology of a tertiary care hospital of Uttar Pradesh, India,

over a period of 12 months from September 2016 to September 2017. Pediatric patients, aged between 2 and 12 years, posted for elective urogenital surgery of expected duration <1 h over a period of 1 year were included in our study. Informed consent from the parents of the child was taken. The exclusion criteria included parents who were not willing, patients with local infection, coagulation abnormalities, expected duration of surgery >1 h, and spinal anomalies. Children included in the study were belonging to the American Society of Anesthesiologist grade (ASA) 1 and 2.

All children were kept nil per oral preoperatively as per ASA guidelines. Intravenous access was taken after 1 h of application of eutectic mixture of local anesthetic cream locally at predetermined site night before surgery by the attending nurse, and intravenous ringer lactate was started at the rate of 4 ml/kg/h during the period of fasting as per our institutional protocol. On the day of surgery, non-cooperative children were sedated in the pre-operative room by intravenous midazolam (0.05 mg/kg), injection ketamine (0.5 mg/kg), and atropine (20 µg/kg) and then shifted to operation theater. No premedication apart from intravenous midazolam (0.03 mg/kg) was given to those who were compliant for spinal anesthesia. Standard monitors were attached and baseline parameters recorded. Oxygen supplementation at the rate of 4 l/min was given using face mask during the period of sedation.

Children were then put in lateral position and under strict aseptic precaution; spinal anesthesia using 0.5% bupivacaine was given using 26 gauge Quincke's needle in the L4–L5 interspace as per the institutional protocol. Additional doses of intravenous injection ketamine (maximum cumulative dose of 1.5 mg/kg) were given for sedation to maintain immobility while performing subarachnoid block. The doses of bupivacaine 0.5% used for the spinal block were as per the standard protocol, i.e., 0.5 mg/kg for infants weighing 0–5 kg, 0.4mg/kg for 5–15 kg body weight, and 0.3 mg/kg for >15 kg weight.^[3]

All spinal blockades were given by an experienced anesthesiologist having performed over 100 successful spinal blockades in children. Success of block was assessed using modified Bromage scale in cooperative child while loss of lower limb tone and cremasteric reflex in sedated child. Modified Bromage score of 3 was taken as successful block. Scoring was done as follows:

- 0: Freely able to move both the lower limbs
- 1: Inability to flex at hip joint but able to flex at knee and ankle
- 2: Inability to flex hip and knees but able to do flexion of ankle
- 3: Complete inability to move or flex hip, knees, ankle, or toes.

Incidence of unwanted intraoperative PE, time of onset of the SA, length of surgery, attempts success of lumbar puncture, need for supplemental systemic sedation, conversion to general anesthesia, and perioperative complications were recorded. All data obtained from the study are presented as mean \pm standard deviation. All through the study, $p < 0.05$ is taken as indicative of statistical significance.

RESULTS

A total of 386 cases were done during the study period of 1 year. In 38 patients, duration of surgery unexpectedly extended beyond 1 h; out of which, 15 patients required general anesthesia to complete the surgery as effect of spinal blockade started to wear off. After excluding 38 cases, the final analysis was performed in the remaining 348 cases.

The mean age, weight, and duration of surgery are given in Figure. 1. Only two patients (0.005%) developed PE after spinal block which was managed and surgery was conducted successfully. 225 (64.6%) children required systemic sedation along with spinal blockade while 123 (35.3%) cases were successfully operated under spinal anesthesia alone without any sedation. None of the cases required conversion into general anesthesia. Mean time of onset of spinal blockade was 100 ± 54 s. First attempt success rate of lumbar puncture was 83% while 16.9% of patients required the second attempt. There were no major complications in any child in perioperative period. There were no major hemodynamic or respiratory complications in any child in perioperative period (Table 1).

DISCUSSION

Various studies have highlighted the role of anesthetic technique and drugs used intraoperatively in the development of

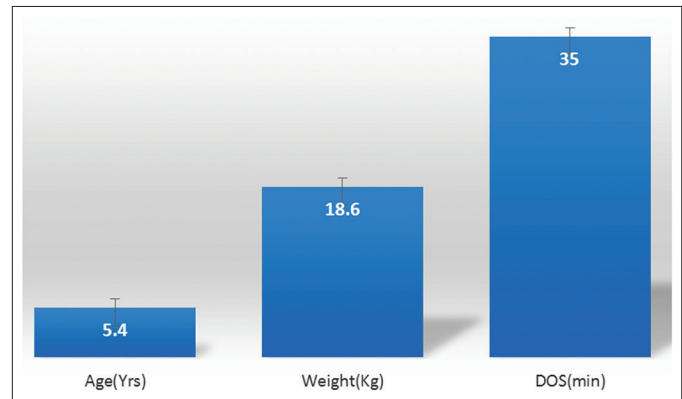


Figure 1: Mean age, weight, and duration of surgery of the patients included in the study

Table 1: Primary and secondary outcomes of the study

Parameters	Outcome
Number of patients completed study	348
Spinal/general anesthesia	348/0 (100%:0%)
Spinal anesthesia only/spinal plus sedation	123/225 (35.3%:64.6%)
Time of onset of spinal blockade (mean \pm SD) seconds	100 \pm 54
Total successful lumbar puncture	348 (100%)
1 st attempt success rate of lumbar puncture	289 (83%)
2 nd attempt success rate of lumbar puncture	59 (16.9%)
Incidence of unwanted intraoperative PE	2 (0.005%)
Perioperative complications	0%

SD: Standard deviation, PE: Penile engorgement

intraoperative PE.^[1,2] PE is of multifactorial cause and involves a complex mechanism. In general, psychic or local sensor stimulation precipitates parasympathetic outflow and can lead to engorgement of the corpora cavernosa. Opposite to this, sympathetic stimulation causes detumescence by constriction of penile venous sinusoids, opening of emissary veins, and thereby increasing blood drainage.^[3-5]

Spinal or neuroaxial anesthesia disrupts the balance of sympathetic and parasympathetic innervations of the penis. Engorgement can also occur reflexly in response to tactile stimulation during part preparation in early stages of spinal anesthesia when block is still incomplete. Another possible reason is the sparing of sacral parasympathetic segments during spinal anesthesia.^[6] The same mechanisms logically should apply during the epidural anesthesia also.

Penile erection during general anesthesia may occur due to different effects of anesthetic drugs and methods.^[2,4,7] During general anesthesia, the autonomic nervous system is depressed. Therefore, sympathetically mediated vasoconstriction may subside and vascular engorgement may occur, requiring deeper levels of anesthesia. Volatile anesthetics increase nasal sinuses, uterine, and cerebral blood flows.^[8-11] Penile blood flow is probably increased by changing penile vascular resistance. In an anesthetized patient, effect of tactile stimulation also occurs, especially in early stages and light anesthesia.

Use of parasympatholytics and sympathomimetics has been reported to treat priapism intraoperatively. Valley and Sang have reported the use of glycopyrrolate to treat intraoperative penile erection in case of continuous spinal anesthesia.^[12] Ravindram *et al.* reported 2 cases of priapism that responded to 0.5 mg/kg of ketamine and 1.5 mg of physostigmine.^[13] Gale also treated intraoperative penile erection during general anesthesia with 1 mg/kg ketamine intravenously, the complete flaccidity occurring 25 min after ketamine.^[14] Studies also reported intracavernous injection of noradrenaline, use of terbutaline (5 mg orally or 0.25–0.5 mg subcutaneously or intravenously), intravenous dexmedetomidine, and dorsal penile nerve block for the management of intraoperative penile erection.^[15-17] Authors of one study have reported the incidence of intraoperative PE to 0.34% for general anesthesia, 0.11% spinal anesthesia, and 1.72% epidural anesthesia.^[17]

In our study, we found the incidence of intraoperative PE to 0.005%. Two (0.005%) of our patients developed intraoperative PE. They were given subarachnoid block only, as they were fully compliant (no systemic sedation given except anxiolytic dose of midazolam 0.03 mg/kg intravenously). Patient developed PE while betadine paint was being applied during part preparation before starting surgery. Part preparation immediately after administration of spinal anesthesia when block is still incomplete may have stimulated the development of PE in these cases. Both responded well to glycopyrrolate 0.2 mg plus 0.3 mg/kg ketamine, intravenously, detumescence occurred within 15 min and surgery was completed successfully. The predominance of penile parasympathetic innervations post-spinal anesthesia seems to play a major role in the development of PE. Furthermore, the tactile stimulations before the block are complete and are the second most important factor.

The main limitation of our study was that this is the single center observational study. We did not compare the incidence of intraoperative PE in patients under spinal, epidural, or general anesthesia, as this would have required a greater sample size.

CONCLUSION

We conclude that spinal anesthesia has a very low incidence of PE; however, complete effect after spinal blockade must be ensured before any tactile stimulation or part preparation. Just the fear of the development of PE should not bias the choice of anesthetic technique toward general anesthesia.

REFERENCES

1. Baltogiannis DM, Charalabopoulos AK, Giannakopoulos XK, Giannakis DJ, Sofikitis NV, Charalabopoulos KA. Penile erection during transurethral surgery. *J Androl* 2006;27:376-80.
2. Rao TH, Zaman W, Jain RK. Intraoperative penile erection. *Arch Esp Urol* 2000;53:953-6.
3. Bernard JD. Regional Anesthesia in children. In: Miller RD, editor. *Anesthesia*. 6th ed. New York: Churchill Livingstone Inc.; 2005. p. 1719-62.
4. Benson GS, McConnell J, Lipshultz LI, Corriere JN Jr., Wood J. Neuromorphology and neuropharmacology of the human penis: An *in vitro* study. *J Clin Invest* 1980;65:506-13.
5. Bosch RJ, Benard F, Aboseif SR, Stief CG, Lue TF, Tanagho EA, *et al.* Penile detumescence: Characterization of three phases. *J Urol* 1991;146:867-71.
6. Greene NM. *Physiology of Spinal Anaesthesia*. 3rd ed. Baltimore: William and Wilkins; 1981.
7. Bakan M, Elicevik M, Bozkurt P, Kaya G. Penile erection during remifentanyl anesthesia in children. *Paediatr Anaesth* 2006;16:1294-5.
8. Beule AG, Wilhelmi F, Kühnel TS, Hansen E, Lackner KJ, Hosemann W, *et al.* Propofol versus sevoflurane: Bleeding in endoscopic sinus surgery. *Otolaryngol Head Neck Surg* 2007;136:45-50.
9. Sivaci R, Yilmaz MD, Balci C, Erincler T, Unlu H. Comparison of propofol and sevoflurane anesthesia by means of blood loss during endoscopic sinus surgery. *Saudi Med J* 2004;25:1995-8.
10. Bimbach D, Browne I. Anesthesia for Obstetrics. In: Miller R, Eriksson LL, editors. *Miller's Anesthesia*. 7th ed. Philadelphia, PA: Churchill Livingstone Elsevier; 2010. p. 2203-41.
11. Monkhoff M, Schwarz U, Gerber A, Fanconi S, Banziger O. The effects of sevoflurane and halothane anesthesia on cerebral blood flow velocity in children. *Anesth Analg* 2001;92:891-6.
12. Valley MA, Sang CN. Use of glycopyrrolate to treat intraoperative penile erection. Case report and review of the literature. *Reg Anesth* 1994;19:423-8.
13. Ravindram RS, Dryden GE and Somerville GM. Treatment of priapism with ketamine and physostigmine. *Anaesth Analg* 1982;61:705.
14. Gale AS. Ketamine prevention of penile tumescence (letter). *JAMA* 1972;219:1629.
15. Welti RS, Brodsky JB. Treatment of intraoperative penile tumescence. *J Urol* 1980;124:925-6.
16. Pertek JP, Coissard A, Artis M. Dorsal nerve block for intraoperative management of penile erection. *Reg Anesth* 1996;21:491-2.
17. Guler G, Sofikerim M, Ugur F, Aksu R, Boyaci A. Intravenous dexmedetomidine for treatment of intraoperative penile erection. *Int Urol Nephrol* 2012;44:353-7.

Funding: None; Conflict of Interest: None Stated.

How to cite this article: Hasan M, Nadeem A, Raza N, Ahmed SM. Unwanted penile engorgement in pediatric patients under anesthesia: The role of anesthetic technique and other contributing factors. *Indian J Child Health*. 2018; 5(6):438-440.