

## Case Report

**Langerhans' cell histiocytosis (histiocytosis X): A rare and diverse group of disorder in children****Vijay B Sonawane, Snehal Prajapati, V Kotrashetti***From Department of Pediatrics, DR. D.Y. Patil Medical College, Navi Mumbai, Maharashtra, India***Correspondence to:** Dr. Vijay Baburao Sonawane, Assistant Professor, Department of Pediatrics, DR. D.Y. Patil Medical College and Hospital, Navi Mumbai - 410 218, Maharashtra, India. E-mail: vijay\_ltm@yahoo.co.in

Received – 05 August 2014

Initial Review – 27 August 2014

Published Online – 11 September 2014

**Abstract**

Langerhans cell histiocytosis is a rare disorder of unknown etiology with proliferation of Langerhans' cells which may infiltrate a single or multiple organs. We report a case of 5-year-old child presented with skin lesions since the age of 4 months and fever for 10 days where skin biopsy revealed histiocytosis.

**Key words:** *Histiocytosis, Langerhans cell, Skin biopsy*

**H**istiocytosis is a heterogeneous group of disorders that are characterized by proliferation and activation of mononuclear phagocyte system. Langerhans cell histiocytosis (LCH) is a disorder of unknown etiology with proliferation of Langerhans' cells which may infiltrate a single or multiple organs [1]. This disease is more common in infants and children under 15 years with incidence of one in 200,000 children [2] and adults even rarer in about one in 560,000 [3]. It usually sporadic but a familial pattern is known. Childhood histiocytosis is a diverse group of disorders that may present great difficulties for pediatricians in diagnosis and treatment as some patients have no symptoms while others have symptoms that are mistaken for an injury or other conditions [4]. Here, we report a case of LCH, diagnosed on skin biopsy since it is rare and unclassified entity with diverse clinical manifestations.

**CASE REPORT**

A 5-year-old male child admitted to hospital with skin lesions since age of 4 months and fever for 10 days. Child had been shown to dermatologist on the outpatient department basis and been treated but no improvement. There is the history of similar

skin lesions in elder sibling. Child also had a history of repeated hospitalization for lower respiratory tract infection. On General examination, child was undernourished, vital parameters being normal, Grade III malnutrition, pallor with significant cervical and axillary lymphadenopathy. Systemic examination reveals hepatomegaly, 5 cm below the costal margin, soft with liver span of 10 cm and splenomegaly of 3 cm.

Skin lesions were scaly, symmetric, papular, and eczematous involving forehead, trunk, back, axilla, and chest. Lesions were dry papules and vesicles with crusting and oozing fluid mainly on flexor aspects (Figs. 1 and 2). Initial differential diagnosis of atopic dermatitis and juvenile xanthogranuloma was made.

Diagnostic workup revealed normal complete blood count, liver function tests, and skeletal survey as bony abnormalities and multiorgan involvement is known, ultrasonography Abdomen was showing hepatosplenomegaly. Urine Osmolality was normal to rule out diabetes insipidus, but skin biopsy from upper back right scapular regions showed splitting of dermis and epidermis and epidermis showed necrosis and parakeratosis while upper dermis showed scanty aggregates of oval cells some with indented nucleus. Histological features showed inflammatory infiltrate

of Langerhans cells with multiple eosinophils and neutrophils suggestive of LCH (Fig. 3).

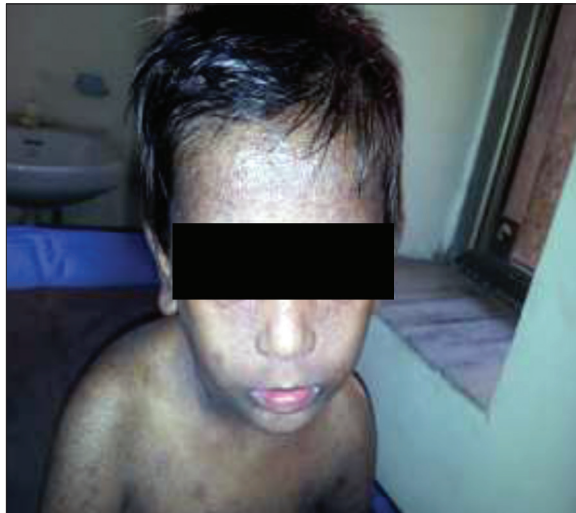## DISCUSSION

The childhood histiocytosis constitutes a diverse group of disorders which, although individually rare, may be severe in their clinical expression. Males are more commonly affected than females [5]. It is currently thought to be a clonal proliferative disorder with highly variable biologic behavior and clinical severity [5,6]. The course of the disease is unpredictable, varying from rapid progression and death to repeated recurrence and recrudescence with

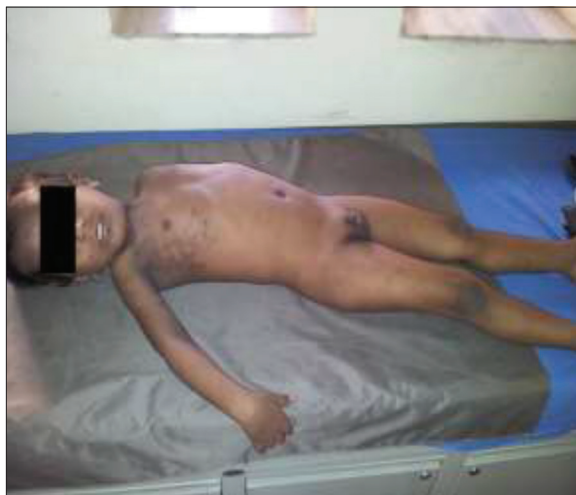chronic sequelae, to spontaneous regression and resolution [7].

Patients with disease that is localized (i.e., either skin or bone) have a good prognosis and is felt to need minimum or even no treatment. In contrast, multiple organ involvement, particularly in young children (<2 years old), carries a relatively poor prognosis [4]. The hallmark of LCH is the presence of Birbeck granules on electron microscopy [8] and CD1 a positivity [4]. But in our patient, immunohistochemistry could not be done due to nonaffordability. The disease is self-limited in some, whereas in some others it is extensive with multi-organ dysfunction. About 80% have skeleton involvement, 50% have skin involvement, 33% have lymphadenopathy, and 20% have hepatosplenomegaly [5]. Lymph node: Enlargement of the liver in 20%, spleen in 30% and lymph nodes in 50% of histiocytosis cases [9]. In the present case, patient had no skeletal involvement but skin lesions along with lymphadenopathy and hepatosplenomegaly. Furthermore, our patient improved after 2 weeks indicating self-limiting course.

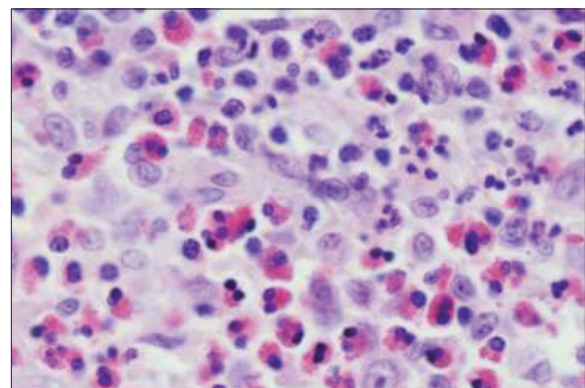
Patients with single system disease can generally be cured with conservative management and overall survival is about 100% in almost all series. Multi-system disease without organ dysfunction has been associated with, a chronic course, a high rate of morbidity and low mortality. Those patients with organ dysfunction require polychemotherapy because they have a life-threatening disorder [10-13].



**Figure 1:** Scaly, symmetric, papular, and eczematous skin lesions on forehead and shoulder



**Figure 2:** Skin lesions on axilla, chest, and forearm



**Figure 3:** Histological features of Langerhans cell histiocytosis showing inflammatory infiltration of Langerhans cells with eosinophils and neutrophils

## REFERENCES

1. Aricò M, Egeler RM. Clinical aspects of Langerhans cell histiocytosis. *Hematol Oncol Clin North Am.* 1998;12(2):247-58.
2. Medline Plus Medical Encyclopedia: Histiocytosis. Available from: <http://www.nlm.nih.gov/medlineplus/ency/article/000068.htm>. [Last accessed on 2014 May 10].
3. Histiocytosis Association of Canada. Available from: [www.histiocytosis.ca](http://www.histiocytosis.ca). [Last accessed on 2014 May 16].
4. The Histiocytoses. In: Ghai OP, Paul VK, Bagga A, eds. *Ghai Essential Pediatrics*. 7<sup>th</sup> ed. New Delhi. CBS Publishers & Distributors Pvt Ltd; 2009; p 595-96.
5. Carstensen H, Ornvold K. The epidemiology of LCH in children in Denmark, 1975. *Med Pediatr Oncol.* 1993;21:387-8.
6. Willman CL, Busque L, Griffith BB, Favara BE, McClain KL, Duncan MH, et al. Langerhans'-cell histiocytosis (histiocytosis X) – A clonal proliferative disease. *N Engl J Med.* 1994;331(3):154-60.
7. De Filippi P, Badulli C, Cuccia M, De Silvestri A, Dametto E, Pasi A, et al. Specific polymorphisms of cytokine genes are associated with different risks to develop single-system or multi-system childhood Langerhans cell histiocytosis. *Br J Haematol.* 2006;132(6):784-7.
8. Valladeau J, Ravel O, Dezutter-Dambuyant C, Moore K, Kleijmeer M, Liu Y, et al. Langerin, a novel C-type lectin specific to Langerhans cells, is an endocytic receptor that induces the formation of Birbeck granules. *Immunity.* 2000;12(1):71-81.
9. Langerhans Cell Histiocytosis - Patient UK. Available from: <http://www.patient.co.uk/doctor/langerhans-cell-histiocytosis>. [Last accessed on 2014 May 16].
10. Berry DH, Gresik MV, Humphrey GB, Starling K, Vietti T, Boyett J, et al. Natural history of histiocytosis X: A Pediatric Oncology Group Study. *Med Pediatr Oncol.* 1986;14(1):1-5.
11. Matus-Ridley M, Raney RB Jr, Thawerani H, Meadows AT. Histiocytosis X in children: Patterns of disease and results of treatment. *Med Pediatr Oncol.* 1983;11(2):99-105.
12. Kusumakumary P, Rajeev Kumar S, James FV, Chellam VG, Krishnan Nair M, Warriar RP, et al. Langerhans cell histiocytosis in children. Pattern of disease and treatment results in Kerala. *Int J Pediatr Hematol Oncol.* 1996;3:297-303.
13. Sims DG. Histiocytosis X: Follow up of 43 cases. *Arch Dis Child.* 1977;52(6):433-40.

*Funding: None; Conflict of Interest: None Stated*

**How to cite this article:** Sonawane VB, Prajapati S, Kotrashetti V. Langerhans' cell histiocytosis (histiocytosis X): A rare and diverse group of disorder in children. *Indian J Child Health.* 2014;1(2):81-3.