

Case Report

Neonatal small left colon syndrome - Radiological diagnosis by gastrografin contrast study

Shashi Sharma¹, B B Sharma², Komal Chamaria², Kush Bansal²

From ¹Department of Pediatrics, SGT Medical College, Budhera, Gurgaon, Haryana, ²Department of Radio-Diagnosis, Post Graduate Institute of Medical Education and Research & Dr. RML Hospital, New Delhi, India

Correspondence to: Shashi Sharma, B-32, Nivedita Kunj, Sector-10, R K Puram, New Delhi - 110 022, India. Tel: 011-26712700, Fax: 011-26182700, E-mail: shashi.s986@gmail.com

Received – 30 September 2014

Initial Review – 28 October 2014

Published Online – 14 February 2015

Abstract

Neonatal small left colon syndrome (NSLCS) is one of the suspected diagnoses if the neonate does not pass meconium within 24 h of birth. Radiological contrast studies play a vital role in diagnosing and treating the entity. We report a case where the newborn did not pass meconium till 4 days of birth and which on gastrografin studies was diagnosed as a case of NSLCS.

Key words: *Gastrografin, Gastrointestinal tract, Neonatal small left colon syndrome, Meconium*

Neonatal small left colon syndrome (NSLCS) is the rare cause of the intestinal obstruction in neonates. The cause is attributed to the caliber of the colon, which suddenly decreases at the site of obstruction. There is no definite data available for this type of entity. The incidence has been noticed in the series of similar type of complaints as 1.5 % of the intestinal obstruction cases [1]. In 1975, Philippart et al. pointed out the cause as humoral and autonomic nervous system changes for this syndrome [2]. However, Schofield and Yunus in 1991 have found the intestinal neural dysplasia as a causative factor for the pathology [3].

CASE REPORT

A 4-day-old male neonate was admitted with the history of not passing meconium even 4 days after the birth and abdominal distension. He had passed urine on 1st day of life and was passing urine regularly. There was no history of fever, vomiting or refusal to feed. His birth order was second and born out of non-consanguineous parents. Antenatal history was non-significant except history of gestational diabetes for which she took some oral medications; however, complete records were not available. Baby was born at full term by normal delivery at home. His immediate post-natal history was non-significant. He was exclusively breast fed and was accepting feeds well.

On examination, baby was alert with stable vital signs and good neonatal reflexes. His weight was 3.2 kg, length was 49 cm and head circumference was 34.4 cm. There were no features of facial dysmorphism and no other obvious congenital anomalies were seen on general examination. Local examination of the anal area showed no anal atresia or stenosis

and per rectal examination was also unremarkable. Abdominal examination showed distended but soft abdomen. There were no organomegaly and bowel sounds were normal. Rest of the systemic examination was non-contributory.

His laboratory investigations, including complete blood counts and serum electrolytes were within normal limits. The plain frontal infantogram has shown distended gut loops without any distinction between the small and large loops. There was no air seen in the pelvis in the region of sigmoid colon (Fig. 1). The patient was subjected first to the upper gastrointestinal study with gastrografin, which was unremarkable (Fig. 2). Then, the contrast gastrografin enema study was done after 2 days. The study has shown the long narrowed caliber of descending colon from the splenic flexure to the proximal sigmoid colon (Figs. 3a, and b). There was no extrinsic impression or filling defect seen in the regions viewed. The infant was diagnosed of neonatal small left colon (NSLC) on clinico-radiological evidences.

There was spontaneous relief of the obstruction after gastrografin study. Enteral feeding was introduced gradually and in next 3 days he was started accepting breast feeds very well. The other probable differential diagnosis of colonic atresia and stenosis along with functional entities were radiologically ruled out. The suction rectal biopsy was undertaken later on to rule out hirschprung disease, which was negative. The neonate also did not show any complication later on follow-up.

DISCUSSION

The newborn must pass meconium in first 24 h of life, which rules out any intestinal obstruction [4]. This can normally be

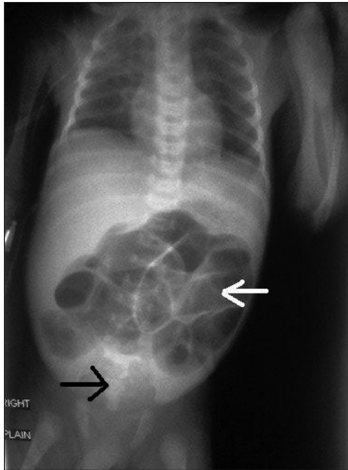


Figure 1: Plain frontal infantogram shows distended bowel loops (white arrow) and the sigmoid region is devoid of gas shadows (black arrow)

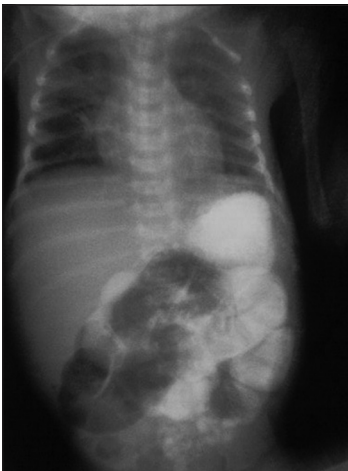

Figure 2: Gastrografin contrast study of the upper gastrointestinal tract shows distended small bowel loops

delayed in case of preterm infants. NSLC is one of the causes where the meconium passage can be delayed. More than half of the infants are borne to the diabetic mothers [5]. There is functional colonic obstruction due to transient dysmotility. This primarily affects the rectum, sigmoid colon and descending colon. In our case, the colon from the splenic flexure to the proximal sigmoid was affected. The newborn usually presents with vomiting, abdominal distension and history of not passing meconium.

Plain abdominal X-ray shows distended gut loops with or without air-fluid levels and contrast studies show a sharp transition zone at the splenic flexure. The differential diagnosis of colonic stenosis, atresia, and functional pathologies should be ruled out before treating for the neonatal intestinal obstruction [6]. It becomes very difficult to diagnose the cause until contrast enema study is done. In most of the cases, diagnostic enema acts as a therapeutic step also as happened in our case. Hirschsprung disease and cystic fibrosis should be

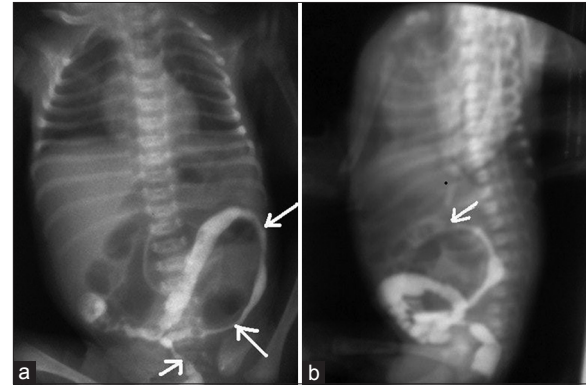


Figure 3: (a) Gastrografin contrast enema in separate sitting shows the narrow segments of descending colon and the part of sigmoid colon (white arrows). (b) Lateral radiograph of the abnormal narrowed segment can be seen extending till splenic flexure (white arrow)

ruled out even if the obstruction has been relieved by diagnostic enema. The rectal biopsy should be undertaken to rule out the other aganglionic colonic pathologies. The surgical intervention is required in complicated cases, which include perforation and recurrent obstruction [2].

CONCLUSION

It is a matter of concern if the infant does not pass meconium within 24 h after the birth. There is a crucial role of contrast study of the upper as well as lower gastrointestinal tract to diagnose the pathology as early as possible. In our case, the infant was diagnosed after the contrast enema study to give passage for further management.

REFERENCES

1. Hajivassiliou CA. Intestinal obstruction in neonatal/pediatric surgery. *Semin Pediatr Surg.* 2003;12(4):241-53.
2. Philippart AI, Reed JO, Georgeson KE. Neonatal small left colon syndrome: Intramural not intraluminal obstruction. *J Pediatr Surg.* 1975;10(5):733-40.
3. Schofield DE, Yunis EJ. Intestinal neuronal dysplasia. *J Pediatr Gastroenterol Nutr.* 1991;12(2):182-9.
4. Weaver LT, Lucas A. Development of bowel habit in preterm infants. *Arch Dis Child.* 1993;68:317-20.
5. Heaton ND, Howard ER, Garrett JR. Small left colon syndrome: An immature enteric plexus. *J R Soc Med.* 1991;84(2):113-4.
6. Juang D, Snyder CL. Neonatal bowel obstruction. *Surg Clin North Am.* 2012;92(3):685-711, ix.

Funding: None; Conflict of Interest: None Stated

How to cite this article: Sharma S, Sharma BB, Chamaria K, Bansal K. Neonatal small left colon syndrome - Radiological diagnosis by gastrografin contrast study. *Indian J Child Health.* 2015;2(1):29-30.