

Case Report

Hairpin impacted in the duodenum of a 4-month-old child - a rarity

Kamal Nain Rattan¹, Priyadarashani², Omkarmanik Baridabad², Kuldeep Kumar Yadav², Bhavna Chopra²

From Departments of ¹Paediatric Surgery and ²Paediatrics, Post Graduate Institute of Medical Sciences, Rohtak, Haryana, India

Correspondence to: Priyadarashani, Department of Paediatrics, Post Graduate Institute of Medical Sciences, Rohtak, Haryana, India.

E-mail: dr.priyadarashani@gmail.com

Received - 07 August 2017

Initial Review - 17 August 2017

Published Online - 08 November 2017

ABSTRACT

Foreign body ingestion is common in children. The accidental ingestion is usually seen in children due to lingual curiosity. Most of the foreign body passes spontaneously through gastrointestinal (GI) tract; hence, requiring no removal. This is a case of impacted hairpin in the duodenum of a 4-month-old female child who accidentally ingested hairpin and was asymptomatic initially for 1 month and later presented with melena requiring surgical removal of hairpin. We failed to find in literature impacted hairpin in the duodenum associated with GI bleeding.

Key words: *Duodenum, Foreign body, Hairpin, Malena*

Foreign body ingestion is frequent in children. The majority of cases occur between the ages of 6 months and 3 years due to their lingual curiosity [1,2]. Commonly ingested objects are coins, jewellery, button-type batteries, needles, and pins [3]. Accidental swallowing is the most common and it can be also be ingested by an act of insanity. The majority of them passes spontaneously through the gastrointestinal tract (GIT) producing no untoward effects, but serious complications such as bowel perforation, GI bleeding, and obstruction can occur in 1% of the cases. Esophagus is the most common site of perforation. There are areas in the GI tract that are normally constricted allowing impaction of foreign body and are potential sites of obstruction. These include pylorus, junction of the second and third part of the duodenum, ileocecal junction, lumen of appendix, junction of cecum and ascending colon, and flexures and haustra of large intestine. Most of the cases are managed conservatively with careful observation to pass with fecal matter. Only few of them require removal and the majority are retrieved by flexible esophagogastroduodenoscopy. Obstruction or acute perforation requires urgent surgery. The current report is about a 4-month-old infant girl who accidentally ingested a metallic corrugated hairpin.

CASE REPORT

A 4-month-old female child accidentally ingested hairpin which was put in her mouth by her elder sister while playing. The pin was swallowed during crying and it passed through the stomach and got lodged in the junction of the second and third part of duodenum. Initially, the child was asymptomatic and was followed as outpatient for about 1 month for spontaneous expulsion or any complications such as perforation and bleeding with repeated

X-ray abdomen. Abdominal X-ray revealed a metallic hairpin impacted in the duodenum (Fig. 1). After a month of conservative management, the child developed GI bleeding in the form of Malena for which child was admitted. Laboratory parameters including coagulation profile were within normal limits.

The patient was planned for laparotomy and no trial of endoscopic removal of hairpin was given. Exploratory laparotomy was done and a metallic hairpin of about 6 cm length was found impacted in the duodenum. There was no evidence of impending perforation and any active bleeder. Duodenotomy was done and hairpin was identified and removed gently. No intraoperative injury to duodenum or bleeding at the site after removal of hairpin was seen. The hairpin was 6 cm in length with corrugated margin (Fig. 2). Duodenum was closed in single layer. Hemostatic ligation was done and abdomen was closed in layers. Post-operative period was uneventful and the patient was discharged in stable condition after 5 days of hospital stay.

DISCUSSION

Foreign body ingestion is common in children with most of them ingested accidentally. The most commonly ingested objects include coins, button batteries, jewellery, and sharp. Most of them which have gone beyond esophagus pass spontaneously through GIT uneventfully, with only 1% causing complications including perforation causing peritonitis, intestinal obstruction, GI bleeding in the form of hematemesis and Malena and rarely even hepatic abscess. Complications occur most commonly in sharp foreign bodies than the blunt ones. Endoscopic removal is needed in around 10–20% of the cases, and in about 1% of the cases, surgical intervention is required, depending on nature, shape, size, number, and location of the foreign bodies [4,5]. The

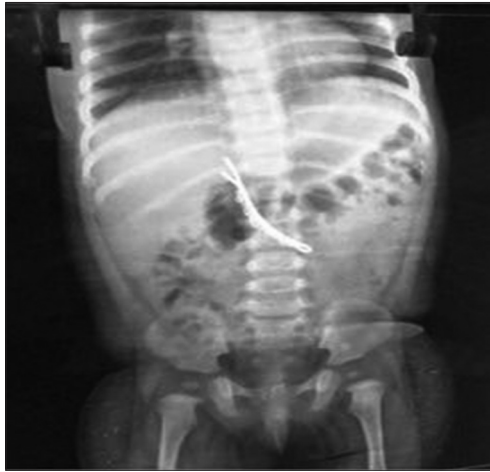


Figure 1: X-ray erect abdomen showing foreign body



Figure 2: Foreign body retrieved from duodenum after open surgery

site at which progression is impeded in GIT includes pylorus, junction of the second and third part of the duodenum, ileocecal junction, lumen of appendix, junction of cecum and ascending colon, flexures, and haustra of large intestine causing impaction of foreign body [6-8]. In this case, hairpin was impacted in the junction of second and third part of duodenum for around 1

month which later caused Malena due to mucosal ulceration in a 4-month-old child. This case also emphasizes on importance of close careful observation with urgent operative intervention whenever indicated in impacted sharp foreign body.

CONCLUSION

Sharp foreign body may get impacted in GI tract and should be closely followed for any serious complications such as perforation and bleeding and should be managed early. These objects should be kept away from children.

REFERENCES

1. van As AB, du Toit N, Wallis L, Stool D, Chen X, Rode H. The South African experience with ingestion injury in children. *Int J Pediatr Otorhinolaryngol* 2003;67 Suppl 1:S175-8.
2. Chung JH, Kim JS, Song YT. Small bowel complication caused by magnetic foreign body ingestion of children: Two case reports. *J Pediatr Surg* 2003;38:1548-50.
3. Velitchkov NG, Grigorov GI, Losanoff JE, Kjossev KT. Ingested foreign bodies of the gastrointestinal tract: Retrospective analysis of 542 cases. *World J Surg* 1996;20:1001-5.
4. Webb WA. Management of foreign bodies of the upper gastrointestinal tract: Update. *Gastrointest Endosc* 1995;41:39-51.
5. Chang JJ, Yen CL. Endoscopic retrieval of multiple fragmented gastric bamboo chopsticks by using a flexible overtube. *World J Gastroenterol* 2004;10:769-70.
6. Kochhar R, Aggarwal R, Goenka MK, Mehta S, Mehta SK. Management of foreign bodies in the upper gastrointestinal tract. *Indian J Gastroenterol* 1990;9:283-4.
7. Nijhawan S, Shimpi L, Mathur A, Mathur V, Roop Rai R. Management of ingested foreign bodies in upper gastrointestinal tract: Report on 170 patients. *Indian J Gastroenterol* 2003;22:46-8.
8. Shivakumar AM, Naik AS, Prashanth KB, Hongal GF, Chaturvedy G. Foreign bodies in upper digestive tract. *Indian J Otolaryngol Head Neck Surg* 2006;58:63-8.

Funding: None; Conflict of Interest: None Stated.

How to cite this article: Rattan KN, Priyadarashani, Baridabad O, Yadav KK, Chopra B. Hairpin impacted in the duodenum of a 4-month-old child - *Indian J Child Health*. 2017; 4(4):647-648.