

## Case Report

### A rare case of beta-ketothiolase deficiency in identical twins

Kavya Kurkal, D Narayanappa, H V Prajwala

From Department of Paediatrics, JSS University, Mysuru, Karnataka, India

**Correspondence to:** Dr. Kavya Kurkal, Department of Paediatrics, JSS Hospital and University, Mysuru - 500 004, Karnataka, India.

E-mail: [kavya\\_kurkal@hotmail.com](mailto:kavya_kurkal@hotmail.com)

Received - 13 July 2017

Initial Review - 09 August 2017

Published Online - 08 November 2017

#### ABSTRACT

Betaketothiolase deficiency is a rare defect of isoleucine and ketone body metabolism which manifests as severe metabolic acidosis following common viral illnesses. A set of 1 year, 8 month-old identical male twins presented with similar symptoms in different time frames. Both of them had severe metabolic acidosis, hypoglycemia, and altered sensorium. Both twins tested positive for beta-ketothiolase deficiency by urine gas chromatography-mass spectrometry. The children responded to symptomatic treatment and are now growing well on a protein-restricted diet. Beta-ketothiolase deficiency is a rare disorder of amino acid metabolism with a favorable outcome if preventive measures are taken early.

**Key words:** *Beta-ketothiolase deficiency, Twins, Amino acid metabolism, Metabolic acidosis, Hypoglycemia*

**B**eta-ketothiolase deficiency, also known as mitochondrial acetoacetyl CoA thiolase (T2) deficiency, is not only one of the rarer but also possibly underdiagnosed inborn errors of metabolism. The first proven case was described in 1971 [1], after which more than 100 cases have been reported [2]. Incidence is said to be <1 in a million [3], but this low incidence may be partly due to underreporting due to the non-specific presentation of this disorder. Incidence in India is yet unknown. It is one of the few inborn errors of metabolism that has a favorable outcome if diagnosed early and preventive measures such as moderate protein restriction are taken along with prompt treatment of intercurrent illnesses. We present such a case in identical twins.

#### CASE REPORT

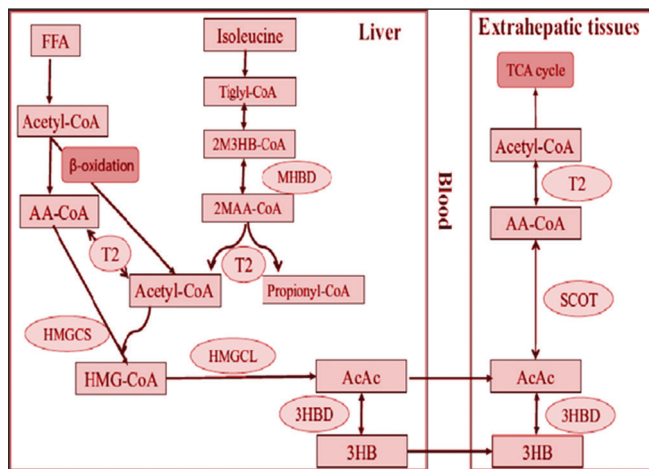
A male child (Twin A) was first brought to our hospital in May 2015, at the age of 1 year with fever, loose stools, severe dehydration, acidotic breathing, and altered sensorium. Before this episode, he had an uneventful perinatal period and was developmentally normal and growing well. He was treated in our pediatric intensive care unit for acute gastroenteritis with some dehydration. Arterial blood gas analysis showed severe metabolic acidosis which was corrected with bicarbonate infusion. His complete blood counts, urine and stool microscopy, and serum ammonia levels were normal. Urine for ketones was positive, blood glucose was low, and blood lactate was high. Metabolic screening was sent before discharge in view of the severity of acidosis and the presence of encephalopathy which was not correlating with the degree of dehydration. Tandem mass spectrometry was positive for increased levels of tiglyl carnitine, hydroxyls butyrylcarnitine, and hydroxyisovalerylcarnitine.

Urine gas chromatography-mass spectrometry findings confirmed the diagnosis of beta-ketothiolase deficiency. Parents were counselled regarding the prognosis of the condition and explained about mild protein restriction and early treatment of minor illnesses.

Twin A presented 8 months later with similar symptoms. He was once again dehydrated with severe metabolic acidosis with pH 7.1,  $\text{HCO}_3^-$  2.1 mmol/L, base excess -27 mmol/L, positive urine ketones, and hypoglycemia. He responded immediately to symptomatic treatment. This time parents gave a history of mild global developmental delay in the child which was confirmed by our assessment. The next day his twin brother (Twin B) was brought with the same symptoms. He was severely dehydrated with acidotic breathing. Urine ketones were large, and blood glucose was low. Arterial blood gas analysis showed severe metabolic acidosis with pH 7.08,  $\text{HCO}_3^-$  3 mmol/L, and base excess was -25.7 mmol/L. He was also treated aggressively with fluid and bicarbonate correction, and hypoglycemia was corrected. This twin was not found to have developmental delay. Complete metabolic screening was sent for this twin; he also tested positive for beta-ketothiolase deficiency by urine gas chromatography-mass spectrometry. Parents were counselled, and the importance of protein restriction and prompt treatment of minor illnesses was reinforced. The twins were growing well till 2 years of age after which they were lost to follow-up.

#### DISCUSSION

Beta-ketothiolase deficiency also known as mitochondrial acetoacetyl CoA thiolase (T2) deficiency is a rare disorder of ketone body and isoleucine metabolism (Fig. 1). Urinary organic acid analysis, even between ketoacidotic episodes, helps make



**Figure 1: Summary of ketone body metabolism and isoleucine catabolism.** 2M3HB indicates 2-methyl-3-hydroxybutyryl; 2MAA, 2-methylacetoacetyl; 3HB, 3-hydroxybutyrate; 3HBD, 3-hydroxybutyrate; AA, acetoacetyl; AcAc, acetoacetate; CoA, coenzyme A; FFA, free fatty acids; HMG-CoA, 3-hydroxy-3-methylglutaryl-CoA; HMGCL, HMG-CoA lyase; HMGCS, mitochondrial HMG-CoA synthase; MHBD, 2-methyl-3-hydroxybutyryl-CoA dehydrogenase; SCOT, succinyl-CoA:3-oxoacid CoA transferase; T2, mitochondrial acetoacetyl-CoA thiolase; TCA, tricarboxylic acid

the diagnosis of T2 deficiency. Excessive excretion of 2-methyl-3-hydroxybutyrate (most reliable), tiglylglycine, and 2 methyl acetoacetate is a typical organic acid profile of this disorder in urine both during and between ketoacidotic episodes [4,5]. However, the absence of these markers does not exclude the diagnosis. The gold standard for diagnosis is enzyme analysis and gene mutation studies, although we could not confirm the diagnosis by these investigations due to financial constraints.

T2 deficient patients are usually asymptomatic during the neonatal period. The ketoacidotic attacks usually start between 5 months and 2 years. The classical presentation is of severe acidosis with loose stools and dehydration usually precipitated by a viral illness such as acute gastroenteritis or an upper respiratory illness, otitis media, prolonged fasting, or by a high protein diet. In between the episodes, child will be asymptomatic [4]. Other symptoms include polypnea, dyspnea, lethargy, or even coma and convulsions. This disorder can mimic an encephalitis/encephalopathy. Blood pH is usually <7.1, base excess <-20 mmol/L, and bicarbonate is usually <7 [4]. Blood glucose levels are usually normal but can range from hypoglycemia to hyperglycemia. Once the acute episode is managed, the long-term prognosis of this particular inborn error of metabolism is usually favorable. Parents have to be counselled about following 3 important things [3,4]:

1. Mild restriction of protein intake (1.5-2 g/kg/day).
2. Prolonged fasting should be avoided.
3. Any acute febrile illness or diarrhea should be promptly treated and foods rich in sugar should be given.
  - L-carnitine is also be supplemented.

Mild developmental delay has been reported in some patients, which might be sequelae of severe ketoacidotic attacks [6]. There are reports of patients surviving till adulthood and one report of a woman getting pregnant and giving birth to a normal baby who turned out to be a heterozygous carrier [7]. Our patients came with the classical presentation. The 2<sup>nd</sup> episode of Twin A was precipitated by fever with loose stools which lasted for a week. Twin B's episode was also probably precipitated by the same viral illness. In retrospect, the parents also gave a history of giving them a high protein diet (i.e., eggs) for the first time that week.

## CONCLUSION

What makes this inborn error of metabolism not only unique but also important, is that it has a favorable outcome if future ketoacidotic episodes can be avoided. This disorder can easily be missed and treated only as severe gastroenteritis with acidosis or ketotic hypoglycemia. Furthermore, this being an autosomal recessive trait, screening of family members, especially siblings, is of utmost importance. In the index case, the parents had refused screening for Twin B initially, when his brother was admitted due to financial constraints. This highlights the importance of metabolic screening in siblings. If recognized early, parents counselled and preventive measures are taken, children with this disorder can go on to live near normal lives.

## REFERENCES

1. Daum RS, Lamm PH, Mamer OA, Scriver CR. A "new" disorder of isoleucine catabolism. *Lancet*. 1971;2(7737):1289-90.
2. Hori T, Yamaguchi S, Shinkaku H, Horikawa R, Shigematsu Y, Takayanagi M, et al. Inborn errors of ketone body utilization. *Pediatr Int*. 2015;57(1):41-8.
3. US National Library of Medicine. Beta-Ketothiolase Deficiency, Genetics Home Reference. Bethesda, MD: The Library, Updated August; 2015. Available from: <http://www.ncbi.nlm.nih.gov/condition/beta-ketothiolase-deficiency>. [Last accessed on 2015 Sep 14].
4. Fukao T. Beta-Ketothiolase Deficiency, Orphanet Encyclopaedia; 2004. Available from: <http://www.orpha.net/data/patho/GB/uk-T2.pdf>. [Last accessed on 2015 Feb 23].
5. Abdelkreem E, Otsuka H, Sasai H, Aoyama Y, Hori T, Aal MA, et al. Beta-ketothiolase deficiency: Resolving challenges in diagnosis. *J Inborn Errors Metab Screen*. 2016;4:1-9c.
6. Schutgens RB, Middleton B, vd Blij JF, Oorthuys JW, Veder HA, Vulsma T, et al. Beta-ketothiolase deficiency in a family confirmed by *in vitro* enzymatic assays in fibroblasts. *Eur J Pediatr*. 1982;139(1):39-42.
7. Sewell AC, Herwig J, Wiegatz I, Lehnert W, Niederhoff H, Song XQ, et al. Mitochondrial acetoacetyl-CoA thiolase (beta-ketothiolase) deficiency and pregnancy. *J Inheret Metab Dis*. 1998;21(4):441-2.

*Funding: None; Conflict of Interest: None Stated.*

**How to cite this article:** Kurkal K, Narayanappa D, Prajwala HV. A rare case of beta-ketothiolase deficiency in identical twins. *Indian J Child Health*. 2017; 4(4):639-640.