

## Neonatal lupus erythematosus – A report of three cases

**Punit S Chhajed, S V Savaskar, N S Bhuri, S T Bandichhode**

*Department of Pediatrics, Dr. V.M. Government Medical College & S.C.S.M. General Hospital, Solapur, Maharashtra, India*

**Correspondence to:** Dr. Punit S Chhajed, Department of Pediatrics, Dr. V.M. Government Medical College & S.C.S.M. General Hospital, Vasantdada Patil Chowk, Opp. District Court, Solapur - 413 003, Maharashtra, India. Phone: +91-9870510050/7507060078. Email: drpunitchhajed29@gmail.com

Received – 25 July 2017

Initial Review – 14 August 2017

Published Online – 10 September 2017

### ABSTRACT

Neonatal lupus erythematosus (NLE) is a rare acquired autoimmune disorder clinically characterized by skin lesions that resemble those of subacute or discoid lupus erythematosus and/or congenital heart block. Skin and cardiac manifestations coexist only in 10% of the patients. It is caused by transplacental passage of maternal autoantibodies, usually anti-Ro/SS-A and /or anti-La/SS-B and less commonly anti-U1 ribonucleoprotein. Mothers of the infants with NLE are either asymptomatic or diagnosed with autoimmune disease. We describe 3 neonates with clinical and immunological findings compatible with NLE, their progress and outcome.

**Key words:** Autoimmune, Congenital heart block, Neonatal lupus, Raccoon eyes, SLE

Neonatal lupus erythematosus (NLE) is a rare, acquired autoimmune disorder. It is associated with transplacental transport of maternal anti-Ro/SS-A and/or anti-La/SS-B and/or anti U1 ribonucleoprotein (RNP) antibodies into fetal circulation. It is characterized by skin lesions and/or cardiac complications in the newborn, which coexist in only 10% of patients [1]. Less commonly, hepatic, hematological, pulmonary, neurological, and gastrointestinal abnormalities may also be present. The maternal connective tissue disorder in most of the cases is systemic lupus erythematosus or Sjogren syndrome. Approximately 50% of the mothers are asymptomatic at the time of diagnosis of NLE in their off springs; testing positive only against Ro/La and/or U1 RNP autoantibodies [2]. We describe three cases of NLE with cutaneous, cardiac and coexistent cutaneous, and cardiac manifestations.

### CASE REPORTS

#### Case 1 - Cutaneous manifestation

A 2-day-old preterm (32 weeks) eutermic and hemodynamically stable female baby was referred to the neonatal intensive care unit (NICU) for rash over face, scalp, and trunk since birth. Erythematous, scaly plaques were present over scalp, trunk, and face with “raccoon eyes” or “owl eyed” appearance and telangiectatic lesions were seen on the trunk (Figs. 1 and 2). Rest of the examination was normal. Mother had a history of fever since 2<sup>nd</sup> month of gestation, associated with progressive photosensitive rash, oral and lip ulcers, and joint aches. Her investigations revealed microcytic hypochromic anemia and raised erythrocyte sedimentation rate. Her serum tested positive for ANA (index 3.2) (index <1.0 = negative, index 1.0-1.2 = borderline,

index >1.2 = positive), anti-dsDNA (140.07 IU/ml) (negative <25, borderline 25-34.9, weakly positive 35-99.9, moderately positive 100-200, strongly positive >200), anti-Ro-52, anti-SS-B, and anti-U1RNP antibodies (qualitative assay). Baby's serum had antibodies against nRNP/Sm and Rib P-protein. Electrocardiogram (ECG), two-dimensional (2D) echocardiogram (ECHO), and other laboratory investigations of the baby were normal. Skin lesions faded over 2 weeks and cleared by 40<sup>th</sup> day of life, leaving behind hypopigmented atrophic macules (Figs. 3 and 4). She did not develop any cardiac complications, required no further treatment, and continues to thrive well.

#### Case 2 - Cardiac manifestation

A 2.4 kg, female child born to a 20-year-old primigravida by lower segment cesarian section (LSCS) at 35 weeks of gestation in view of fetal bradycardia. Mother was registered and immunized, had two antenatal checkups; however, no ultrasonography was done. She had an uneventful antenatal period. Baby cried well after birth, was pink in color, and had good tone and reflex activity. Her heart rate was 50 beats/min and thus, admitted to NICU. She was active, eutermic and was accepting breast feeds. Laboratory investigations were normal. Her ECG revealed a 2:1 heart block (Fig. 5). On 2<sup>nd</sup> day of life, bradycardia persisted and a grade II ejection systolic murmur was heard over left 2<sup>nd</sup> intercostal space. ECHO showed a 3 mm patent ductus arteriosus (PDA) with left to right shunt with congenital heart block. Sera of mother and baby tested positive for anti Ro/SS-A and La/SS-B antibodies. Baby was advised for regular follow-up to assess the need of pacemaker implantation. At 2 month age, baby was thriving well with an average heart rate of 48–50 beats/min but was subsequently lost to follow-up.

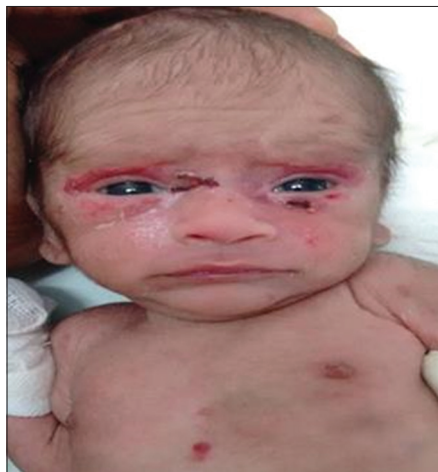

Figure 1: Erythematous scaly plaques in periorbital region giving “raccoon eyes” appearance

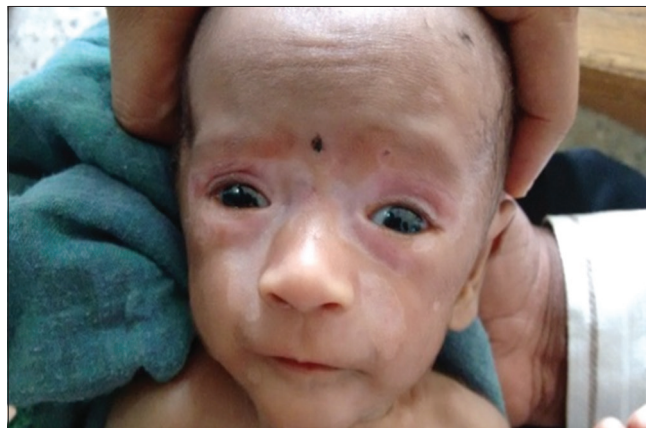

Figure 3: Healed rash at day of life 40. Note the hypopigmentation in periorbital and malar region, identical to the pattern of erythematous rash

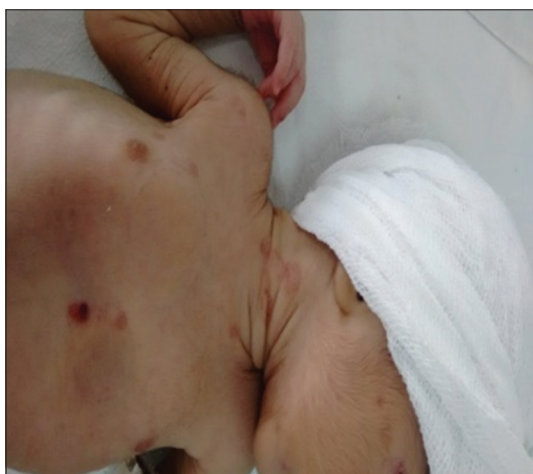

Figure 2: Telangiectatic lesion over epigastrium and scaly papules over neck

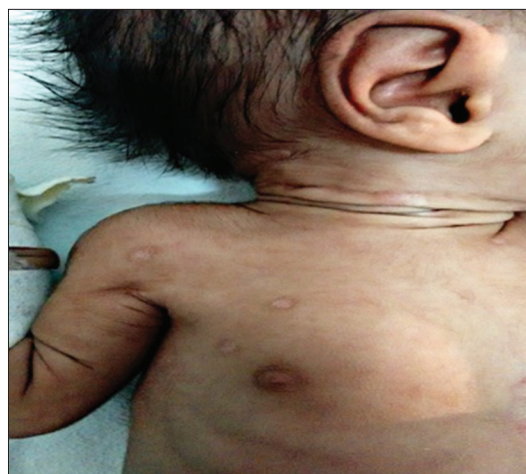

Figure 4: Rash and telangiectatic lesions disappeared leaving behind atrophic macules

### Case 3 - Cardiac and cutaneous manifestation

A 2 kg female child delivered at term by LSCS in view of fetal bradycardia. Baby was admitted to the NICU with a postnatal heart rate 40 beats/min. Her skin showed flat, erythematous, non-blanching, non-scaly papules over forehead and glabella with violaceous hue to both upper eyelids (Fig. 6). ECG revealed a (3:1) complete heart block (CHB) (Fig. 7). 2D ECHO showed no structural defects. Mother was asymptomatic and had no antenatal complaints. Ultrasonography at 33 weeks gestation was suggestive of intrauterine growth retardation and mildly reduced amniotic fluid. Sera of mother and baby showed the presence of anti Ro/SS-A and anti La/SS-B antibodies. The baby succumbed due to cardiac arrest on 7<sup>th</sup> day of life.

### DISCUSSION

NLE is a rare acquired autoimmune disorder present in newborn infants of mothers with autoantibodies against Ro, La, and less commonly U1-RNP mainly characterized by skin lesions and/or cardiac complications. Generally, when patients have skin manifestations, they have no cardiac defects and vice versa;

however, in 10% of cases, these manifestations may coexist [1]. Other findings may involve hematological, hepatic, and rarely neurological manifestations. The incidence of NLE has been estimated as 1 in 20,000 live births [3]. The female-male ratio in large studies has been 1:1, but some studies have suggested a 3:1 ratio [4]. No racial predilection has been observed.

The precise mechanism of injury to specific tissues, such as skin and heart, is not known. The available evidence points strongly to autoantibodies as the cause of NLE. The transitory nature of manifestations that coincides with disappearance of IgG antibodies circulating in infant's blood tends to confirm this hypothesis [5]. Other significant etiological factors (both maternal and fetal) contributing to tissue injury in NLE are currently ill defined, but twin studies suggest that they are likely to be both genetic and environmental [6]. Ultraviolet (UV) light exposure may precipitate and/or exacerbate cutaneous lesions of NLE, but the presence of lesions at birth indicates that UV light is not essential for disease expression. Genes of MHC and C4 have been identified as contributors to NLE [7]. There is emerging evidence that tumor necrosis factor  $\alpha$  and transforming growth factor  $\beta$  polymorphisms may contribute in determining which babies exposed to maternal anti-Ro/SS-A will be affected and which will not [8].



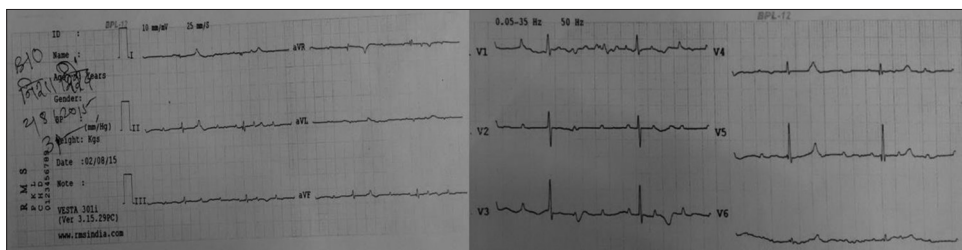


Figure 5: Electrocardiogram showing a heart rate of 46 beats/min with a 2:1 heart block

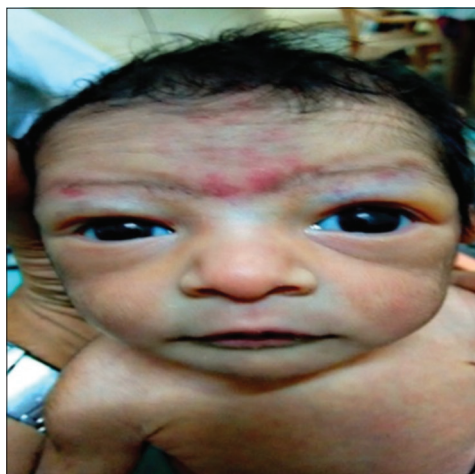


Figure 6: Note the flat, non-scaling erythematous papules over forehead and glabella with violaceous hue to both upper eyelids

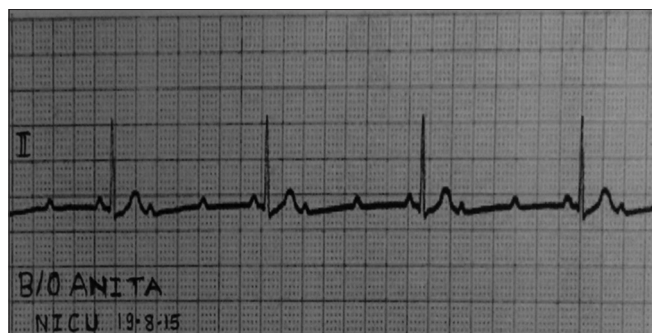


Figure 7: Electrocardiogram, lead II showing heart rate 42 beats/min and complete (3:1) heart block

The maternal connective tissue disorder has been SLE or Sjogren syndrome in most cases. Approximately 50% of mothers are asymptomatic at the time of diagnosis testing positive only against Ro/La and/or U1RNP autoantibodies. With time, most of the mothers develop some symptoms of autoimmunity. The recurrence rate of NLE in subsequent pregnancies has been estimated to be 16-24% [9]. Cutaneous lesions represent the most common manifestation of NLE. Characteristic lesions are transient non-scarring, photosensitive, erythematous, annular macules, papules, and/or plaques with or without fine scaling. There is a predilection for face and scalp, particularly the periorbital region, resulting in so-called “owl’s eye” or “raccoon eyes” (periorbital erythema) appearance seen in 80% of the cutaneous NLE cases.

Saoji and Deopujari [10] reported three cases of NLE with skin lesions since birth. The skin lesions varied from annular lesions in one, purpura in the other, and hypopigmented atrophic

patches on the face and upper trunk in the third case. ECHO was normal in all the three cases indicating no cardiac involvement. Sawant et al. [11] reported a case of anti-Ro-positive cutaneous lupus erythematosus with an uncommon skin manifestation in the form of erythematous annular plaques with scaling on the extremities, palms, and soles with periorbital erythema and edema giving the characteristic “eye mask” or “owl’s eye” appearance. Disease activity resolves spontaneously in few weeks or months, but dyspigmentation, residual telangiectasia, and mild atrophic scarring may persist for months to years. Skin biopsy is not always performed owing to the age of the child and the predilection of lesions for the face. Protection from UV light and use of sunscreen is imperative. Mild topical steroids may be used; however, spontaneous resolution is the natural course of these lesions.

Congenital CHB is the second most common clinical feature of NLE. Isolated CHB occurs in approximately 1 in 20,000 births and of these cases; an estimated 88% may be attributed to NLE. Heart block is thought to result from deposition of anti-SS-A/Ro antibody at the atrioventricular node, which leads to fibrosis and calcification. It usually appears in fetus from 16 to 20 weeks of gestation. In 90% of the cases, it is seen by birth. The CHB is irreversible and in approximately two-third children, it requires permanent pacemaker implantation and is associated with a substantial mortality of 20-30% [4]. Normal sinus rhythm *in utero* can progress to CHB in 7 days. The best treatment for CHB is prevention as once it has occurred treatment seems to be unsuccessful. CHB (and usually second degree block) results in fetal bradycardia that can be detected by routine fetal auscultation or ultrasonography between 18 and 24 weeks of gestation. A weekly scan starting 16 weeks is advisable [6]. The incidence increases 5-10 folds in mothers who already have a child with NLE. Hence, mothers with baby affected by NLE should be serially monitored in subsequent pregnancies. Use of dexamethasone and fluorinated corticosteroids to prevent/treat heart block *in utero* is not supported by evidence [12] and is precluded by its side effects in fetus and mother.

For high-risk mothers, having a previous child with CHB, a multinational open-label study is currently underway to confirm or refute efficacy of intravenous immunoglobulin in preventing CHB [13]. A case-control study suggests that hydroxychloroquine may decrease the risk of cardiac lupus related to anti-SSA/SSB antibodies, but prospective studies are needed for its confirmation [14]. Postnatal diagnosis is done by testing sera of mother and fetus for anti-Ro/SSA antibodies in the setting of

CHB confirmed by an ECG, with or without symptoms in mother. An ECHO should be done to rule out structural heart defects. Cardiomyopathy is the second most common cardiac abnormality commonly in the presence of CHB. Other cardiac problems include subendocardial fibroelastosis, fibrinous pericarditis, and PDA.

The diagnosis of NLE is established from characteristic clinical findings and identification of above-mentioned autoantibodies in the mother and child. The prognosis of disease is defined by the cardiac involvement as most of the other manifestations are transitory and self-resolving. These children are at increased risk of developing autoimmune disease in late childhood or adulthood. The literature on long-term follow-up of NLE babies is limited but four out of 57 infants in the NLE research registry with cutaneous NLE followed up for a mean period of 77 months (1-204 months) developed autoimmune disease in the form of juvenile rheumatoid arthritis (two children), Hashimoto's thyroiditis (one child), and Raynaud's phenomenon (one child), and there are case reports of SLE developing in teenage years [15].

## CONCLUSION

NLE is a rare acquired autoimmune disorder which presents with transient cutaneous manifestations or as irreversible congenital heart block and cardiomyopathy. Prognosis is defined by cardiac involvement. Diagnosis is based on clinical manifestation and serologic testing for anti Ro/SS-A, anti La/SS-B, and/or anti U1 RNP in mother and infant.

## REFERENCES

1. Thornton CM, Eichenfield LF, Shinall EA, Siegfried E, Rabinowitz LG, Esterly NB, et al. Cutaneous telangiectases in neonatal lupus erythematosus. *J Am Acad Dermatol.* 1995;33(1):19-25.
2. Perez MF, Torres ME, Buján MM, Lanoë A, Cervini AB, Pierini AM. Neonatal lupus erythematosus: A report of four cases. *An Bras Dermatol.* 2011;86(2):347-51.

3. Lee LA. Neonatal lupus erythematosus: Clinical findings and pathogenesis. *J Invest Dermatol Symp Proc.* 2004;9(1):52-6.
4. Buyon JP, Hiebert R, Copel J, Craft J, Friedman D, Katholi M, et al. Autoimmune-associated congenital heart block: Demographics, mortality, morbidity and recurrence rates obtained from a national neonatal lupus registry. *J Am Coll Cardiol.* 1998;31(7):1658-66.
5. McCauliffe DP. Neonatal lupus erythematosus: A transplacentally acquired autoimmune disorder. *Semin Dermatol.* 1995;14(1):47-53.
6. Buyon JP, Clancy RM, Friedman DM. Cardiac manifestations of neonatal lupus erythematosus: Guidelines to management, integrating clues from the bench and bedside. *Nat Clin Pract Rheumatol.* 2009;5(3):139-48.
7. Lee LA, Bias WB, Arnett FC Jr, Huff JC, Norris DA, Harmon C, et al. Immunogenetics of the neonatal lupus syndrome. *Ann Intern Med.* 1983;99(5):592-6.
8. Clancy RM, Backer CB, Yin X, Kapur RP, Molad Y, Buyon JP, et al. Cytokine polymorphisms and histologic expression in autopsy studies: Contribution of TNF-alpha and TGF-beta 1 to the pathogenesis of autoimmune-associated congenital heart block. *J Immunol.* 2003;171(6):3252-61.
9. Izmirly PM, Rivera TL, Buyon JP. Neonatal lupus syndromes. *Rheum Dis Clin North Am.* 2007;33(2):267-85, vi.
10. Saoji V, Deopujari S. Neonatal lupus erythematosus-three different presentations. *Indian J Paediatr Dermatol.* 2014;15:110-3.
11. Sawant S, Amladi ST, Wadhawa SL, Nayak CS, Nikam BP. Cutaneous neonatal lupus erythematosus with unusual features. *Indian J Dermatol Venereol Leprol.* 2007;73(4):250-2.
12. Lee LA. The clinical spectrum of neonatal lupus. *Arch Dermatol Res.* 2009;301(1):107-10.
13. Friedman DM, Llanos C, Izmirly PM, Brock B, Byron J, Copel J, et al. Evaluation of fetuses in a study of intravenous immunoglobulin as preventive therapy for congenital heart block: Results of a multicentre, prospective, open-label clinical trial. *Arthritis Rheumatol.* 2010;62:1138.
14. Jaeggi ET, Hamilton RM, Silverman ED, Gordon P, Khamashta MA, Rosenthal E, et al. Evaluation of the risk of anti-SSA/Ro, SSB/La antibody-associated cardiac manifestations of neonatal lupus in fetuses of mothers exposed to hydroxychloroquine. *Ann Rheum Dis.* 2010;69:1827.
15. Neiman AR, Lee LA, Weston WL, Buyon JP. Cutaneous manifestations of neonatal lupus without heart block: Characteristics of mothers and children enrolled in a National Registry. *J Pediatr.* 2000;137(5):674-80.

*Funding: None; Conflict of Interest: None Stated.*

**How to cite this article:** Chhajed PS, Savaskar SV, Bhoori NS, Bandichhode ST. Neonatal lupus erythematosus – A report of three cases. *Indian J Child Health.* 2017; 4(4):631-634.