

Case Report

Pain abdomen in a child - An uncommon cause

Varun Alwadhi, Aashima Dabas, Anju Aggarwal, M M A Faridi

From Department of Pediatrics, University College of Medical Sciences and Guru Tegh Bahadur Hospital, New Delhi, India

Correspondence to: Dr. Anju Aggarwal, Flat No. 3C Block, C2B Janakpuri, New Delhi - 110 058, India. Phone: +91-9910329791.

E-mail: aanju67@gmail.com

Received – 16 August 2016

Initial Review – 18 September 2016

Published Online – 24 September 2016

ABSTRACT

Diagnosis, identification of underlying etiology and management of pain abdomen, remains difficult. Tumors presenting as abdominal pain are rare in children. We report a case of 11-year old boy presenting with pain abdomen. On examination, he had a lump in left hypochondrium. Gastrointestinal tumors constitute about 12% of abdominal masses, 2% of which are pancreatic tumors. He underwent laparotomy was diagnosed as desmoplastic small round cell tumor in the pancreas. This report presents an uncommon cause of a common pediatric problem.

Key words: *Desmoplastic small round cell tumor, Diagnosis, Outcomes, Pancreas*

Abdominal pain is a common problem in pediatric practice. Common causes of abdominal pain include enteritis, infection, worm infestation, constipation, food allergy, peptic ulcer, and obstruction. Tumors presenting as abdominal pain are rare in children. Most common tumor masses in childhood are neuroblastoma, Wilm's tumors, non-Hodgkin's lymphoma, germ cell tumor, and hepatoblastoma [1]. Gastrointestinal tumors account for 12% of causes of abdominal masses of which pancreatic tumors account for 2%. Desmoplastic small round cell tumor (DSRCT) is a rare, aggressive malignant tumor. There are only a few case reports of involvement of the pancreas [2,3].

CASE REPORT

An 11-year-old male child presented with pain in the abdomen. The pain was ill-defined, mainly in the upper abdomen, pain was dull aching, no radiation. There was no relieving or aggravating factor. There were no associated symptoms such as fever, anorexia, weight loss, jaundice, urinary complaints, or alteration in bowel movements. Examination revealed a lump in the region of left hypochondrium extending to the epigastrium. The lump measured 8 cm × 10 cm and was nontender, firm in consistency, immobile and had smooth surface and margins. Systemic examination did not reveal any abnormality.

Blood sugar, hemogram, kidney, and liver functions were within normal limits. Ultrasound confirmed a well-defined heterogeneous mass of 10.4 cm × 7.3 cm × 9.5 cm size containing cystic areas and calcification. Contrast-enhanced computed tomography of abdomen was suggestive of neoplastic mass arising from the pancreas suspected to be pancreatoblastoma with tumor thrombus in superior mesenteric vein and portal vein with mesenteric lymphadenopathy

(Fig. 1). Contrast-enhanced computed tomography of thorax did not reveal any metastasis. Bone marrow aspiration was normal. The patient underwent open laparotomy with resection of pancreatic body and tail and splenectomy and removal of adjoining lymph nodes (Fig. 2). Post-operative histopathology findings confirmed the diagnosis of DSRCT of the pancreas (Grade 4-undifferentiated, pathologic stage pT₃).

DISCUSSION

DSRCT has been reported sporadically worldwide after first identification in 1989 by Gerald and Rosai [4]. The tumor can have various differentiations such as epithelial, mesenchymal, or neuronal differentiation; hence, it is difficult to diagnose DSRCT even with immunohistochemistry [5]. DSRCT has distinct clinical, histologic, and immune phenotypic features, which makes it an often misdiagnosed neoplasm of children and adolescents. Median age at presentation is 20-30 years with male predominance. The tumor cases commonly present with abdominal mass. It has a propensity for serosal surfaces, especially in the peritoneal cavity and is characterized by the presence of large abdominal masses without any obvious organ base and widespread peritoneal involvement.

Bisogno et al. [6] reported six cases of children and adolescents (median age 14 years, range 6.9-17.5) with DSRCT (5 abdominal, 1 paratesticular) registered by the Italian Cooperative Group for soft tissue sarcoma over a 9-year period. Patients received a multidisciplinary treatment, including aggressive initial or delayed surgery and radiotherapy. They have reported that patients with localized abdominal tumors may have a better prognosis. Bent et al. [7] reported a large series of 95 pediatric cases of DSRCT with the median age of 15.3 years (range: 0-21). The majority of tumors

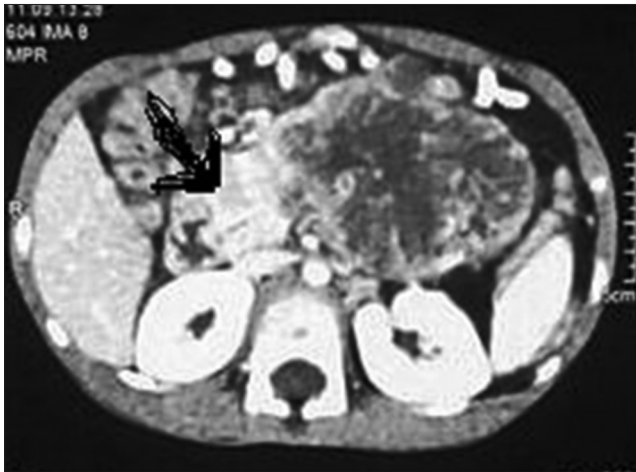

Figure 1: Contrast-enhanced computed tomography of abdomen showing neoplastic mass in pancreas (arrow)

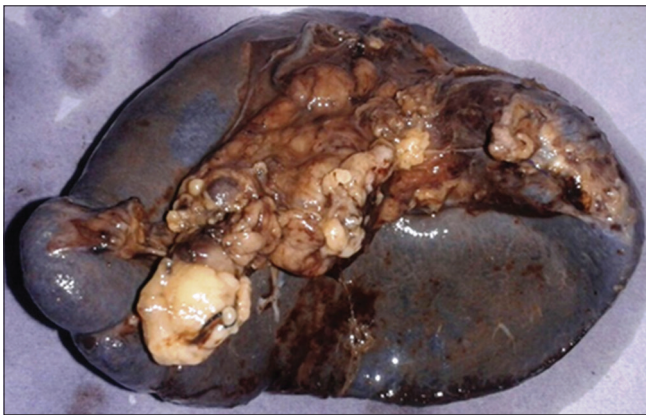


Figure 2: Gross morphology of tumor mass in resected pancreatic body and tail

originated in the abdomen and pelvis (84.4%), and the majority of patients had distant metastasis (72.6%). Overall survival at 5 years was poor (18.1%; 95% confidence interval 10.1-27.9%). Radiation therapy was associated with superior survival.

Multidisciplinary treatment including intensive chemotherapy, aggressive surgery (>90% resection), and adjuvant abdominopelvic radiation with or without myeloablative

chemotherapy with stem cell rescue has been reported to improve survival in DSRCT, although cure remains elusive in widespread disease. 3-year progression free survival rates vary from 27% to 55% [8,9].

CONCLUSION

Our case highlights the importance of careful assessment of every child with nonspecific abdominal pain for the presence of a lump. DSRCT of the pancreas is a rare malignant tumor which requires multimodality therapy.

REFERENCES

1. Golden CB, Feusner JH. Malignant abdominal masses in children: Quick guide to evaluation and diagnosis. *Pediatr Clin North Am.* 2002;49(6):1369-92.
2. Bismar TA, Basturk O, Gerald WL, Schwarz K, Adsay NV. Desmoplastic small cell tumor in the pancreas. *Am J Surg Pathol.* 2004;28:808-12.
3. Ryan A, Razak A, Graham J, Benson A, Rowe D, Haugk B, et al. Desmoplastic small round-cell tumor of the pancreas. *J Clin Oncol.* 2007;25(11):1440-2.
4. Gerald WL, Rosai J. Case 2. Desmoplastic small cell tumor with divergent differentiation. *Pediatr Pathol.* 1989;9(2):177-83.
5. Norton J, Monaghan P, Carter RL. Intra-abdominal desmoplastic small cell tumour with divergent differentiation. *Histopathology.* 1991;19:560-2.
6. Bisogno G, Roganovich J, Sotti G, Ninfo V, di Montezemolo LC, Donfrancesco A, et al. Desmoplastic small round cell tumour in children and adolescents. *Med Pediatr Oncol.* 2000;34(1):338-42.
7. Bent MA, Padilla BE, Goldsby RE, DuBois SG. Clinical Characteristics and Outcomes of Pediatric Patients with Desmoplastic Small Round Cell Tumor. *Rare Tumors.* 2016;8(1):6145.
8. Lal DR, Su WT, Wolden SL, Loh KC, Modak S, La Quaglia MP. Results of multimodal treatment for desmoplastic small round cell tumors. *J Pediatr Surg.* 2005;40(1):251-5.
9. Honoré C, Amroun K, Vilcot L, Mir O, Domont J, Terrier P, et al. Abdominal desmoplastic small round cell tumor: Multimodal treatment combining chemotherapy, surgery, and radiotherapy is the best option. *Ann Surg Oncol.* 2015;22(4):1073-9.

Funding: None; Conflict of Interest: None Stated.

How to cite this article: Alwadhhi V, Dabas A, Aggarwal A, Faridi MMA. Pain abdomen in a child - An uncommon cause. *Indian J Child Health.* 2016; 3(4):351-352.