

Poland syndrome: Atypical presentation and review of literature

Hema Gupta Mittal¹, Yashvant Singh², Hemant Tatawat¹, Arti Maria¹

From Departments of ¹Neonatology and ²Radiology, Dr. RML Hospital & PGIMER, New Delhi, India

Correspondence to: Yashvant Singh, Department of Radiology, Dr. RML Hospital & PGIMER, New Delhi, India.

E-mail: y_ashvant@yahoo.com

Received – 03 January 2017

Initial Review – 15 January 2017

Published Online – 27 January 2017

ABSTRACT

Poland syndrome is a rare congenital disorder with absent or hypoplastic pectoralis major and hand anomalies. Dextroposition, female predisposition, and the left-sided anomalies in Poland syndrome are rarely reported in literature. We report a female baby who was born with chest wall defects, left hand anomalies, dextroposed heart, and hypoplastic ribs. She was diagnosed as Poland syndrome and managed conservatively.

Key words: Neonate, Pectoralis major, Poland syndrome, Dextrocardia

Poland syndrome is a rare congenital condition which manifests typically with the absence of sternocostal part of pectoralis major and ipsilateral hand defects [1]. Other commonly observed anomalies are shoulder girdle defects, breast and nipple anomalies, renal malformations, vertebral anomalies, etc., Sprengel deformity, Moebius syndrome, Klippel–Feil anomaly, lung tumors, and hematological malignancies are also reported with Poland syndrome [2]. The right-sided Poland syndrome and male predisposition are usually observed. Dextrocardia with Poland syndrome is rare and only 48 cases are reported worldwide till 2015 [3]. In the presence of dextrocardia and rib anomalies (2 or more), all cases of Poland syndrome reported till date are left sided. We report a newborn female baby diagnosed as with left-sided Poland syndrome with dextroposed heart, mesocardia and ipsilateral rib and hand anomalies.

CASE REPORT

A female baby product of a nonconsanguineous marriage was delivered at 38 weeks of gestation (appropriate for gestational age), by vaginal delivery to primigravida mother without any significant antenatal history. There was no maternal or family history of congenital malformations or limb deformity or heart defects. After birth baby cried immediately with Apgar score of 9 at both 1 and 5 min.

On examination, newborn had respiratory distress (respiratory rate - 72/min) with subcostal and intercostals retraction, heart rate was 134/min with oxygen saturation (SpO₂) 91% on room air and mean blood pressure was 68/44 mmHg in the right arm. Anthropometry revealed birth weight of 2.42 kg (3rd to 10th centile), length (50.2 cm, 50th to 90th Centile), and head circumference (35.5 cm, 50th to 90th centile). Head to toe examination revealed depression on the left side of the chest wall suggestive of decreased subcutaneous tissue and muscle mass

(Fig. 1a). There was no abnormality in the nipple or breast. The left hand was smaller with syndactyly between left index and middle finger and clinodactyly of the left little finger (Fig. 1b). On chest examination, bilateral air entry was equal with no added sounds. Heart sounds were equally heard on the right and left sternal border and there was no murmur. Examinations of abdomen, nervous system, and spine were within normal limits. Baby was started on exclusive breastfeeding and shifted to mother side (within 24 h of life). Baby tolerated breast feeding well and maintained SpO₂ more than 95% on room air. Tachypnea improved but chest retractions persisted due to asymmetry of chest.

A provisional diagnosis of dextrocardia with hand and chest abnormalities was made and chest radiograph, echocardiography, and computed tomography scan (chest) were planned. X-ray chest showed right-sided heart with hypoplastic 3rd and 4th ribs on left side (Fig. 1c). A two-dimensional echocardiography revealed dextroposed heart with mesocardia with situs solitus without other defects. Computed tomography (CT) chest revealed a dextroposed heart, reduced right side lung volume (Fig. 1d) and absent pectoralis major and pectoralis minor muscle on left side. No anomalies of vertebral column or mediastinal vasculature were noticed (Fig. 1e). Ultrasound Doppler studies and CT angiography also ruled out any subclavian artery stenosis or altered flow. There were no renal anomalies noticed in ultrasound abdomen. In the presence of absent pectoralis major and syndactyly in the left hand, we made a diagnosis of Poland syndrome. Female baby, dextroposed heart with mesocardia and hypoplastic ribs were other rare observations in our case.

DISCUSSION

The incidence of Poland syndrome varies from 1/10,000 to 1/100,000 live births [4]. The incidence of isolated dextrocardia which is described as rotation of base – apex axis of heart

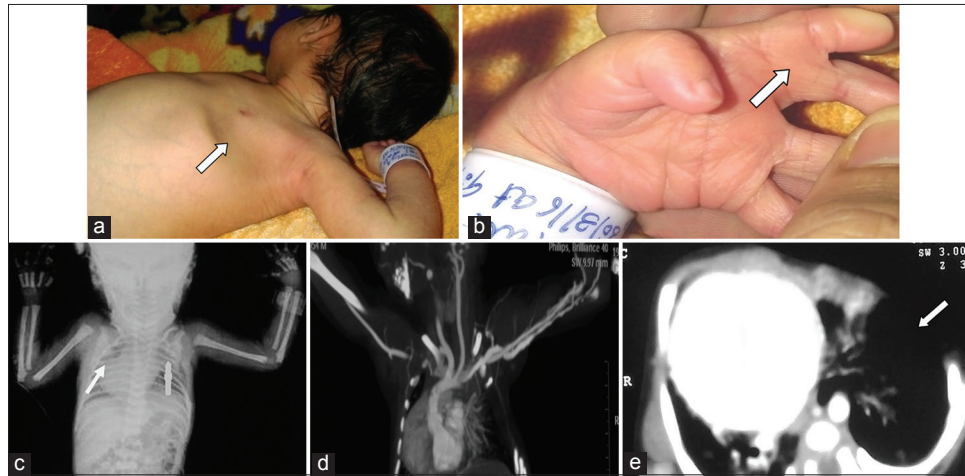


Figure 1: (a) Chest wall depression on left side, (b) syndactyly between index finger and middle finger in left hand, (c) X-ray chest showing hypoplastic 3rd and 4th ribs and dextrocardia, (d) computed tomography coronal section showing dextroverted heart, mesocardia, reduced right lung volume and absence of any subclavian artery narrowing, (e) computed tomography chest axial section showing absence of pectoralis major and minor on left side

to the right side is reported to be 1/30,000. Dextroversion is described as shifting of heart toward right hemithorax which may be accompanied by dextrocardia or not. Poland syndrome and dextrocardia coexist in about 11.5% of patients with Poland syndrome and only 48 cases of Poland syndrome with dextrocardia are reported till date [5]. Torre et al., in his study, of 122 patients diagnosed of Poland syndrome studied pathogenesis of associated dextrocardia. He concluded that dextrocardia was always associated with left-sided two or more rib agenesis.

The exact sequence of events in those diagnosed of Poland syndrome with dextrocardia is still controversial. Most of the authors hypothesize that shifted vascular structures due to dextrocardia result in deficient blood supply on left side and hence associated anomalies of ribs, or muscle agenesis. Other more popular hypothesis suggests that chest malformations lead to dextrocardia. A weak chest wall due to rib hypoplasia or reduced and sunken chest in the absence of rib hypoplasia also reasonably leads to dextrocardia. Cardiac dextroversion in the absence of complex heart defects observed in Poland syndrome appear to be a result of pure mechanical displacement. In a study by Sepulveda, serial antenatal ultrasounds of babies diagnosed of Poland syndrome showed late occurrence of dextrocardia at 31 weeks as compared to other thoracic and hand defects [6]. Previous antenatal ultrasound at 21 weeks did not show any heart position defects. In our case, we found dextroversion with mesocardia only.

Proposed genetic inheritance of Poland syndrome is sporadic mutation with paradominant inheritance or autosomal lethal gene mosaicism. Familial occurrence is also reported [7]. The most accepted pathogenesis of Poland syndrome is interrupted vascular supply by subclavian or vertebral artery or their branches. Bavincck and Weaver describe subclavian artery disruption sequence as a common mechanism for Poland syndrome, Sprengel deformity, Moebius syndrome, Klippel-Feil anomaly, etc. [8]. The absence

of associated heart defects even with dextrocardia decrease morbidity in these patients. There are no life-threatening anomalies reported with Poland syndrome, and hence, life expectancy is unaffected. Management of Poland syndrome includes custom implant for pectoralis muscle using computer aided design. A virtual implant matching the patient is created. For subcutaneous and mammary atrophy surgical techniques such as tissue expansion and lipofilling silicon breast implants are recommended.

REFERENCES

1. Yiyit N, Isitmangil T, Saygin H. Eight patients with multiple bilateral thoracic anomalies: A new syndrome or bilateral Poland's syndrome? *Ann Thorac Surg.* 2014;97(5):1758-63.
2. Goodman RM, Gorlin RJ. Poland anomaly. *The Malformed Infant and Child.* New York: Oxford University Press; 1983. p. 74-5.
3. Yiyit N, İşıtmangil T, Arıbal S. Is isolated dextrocardia a feature of left-sided Poland's syndrome? *Turk Gogus Kalp Dama.* 2015;23(4):700-7.
4. Stevens DB, Fink BA, Prevel C. Poland's syndrome in one identical twin. *J Pediatr Orthop.* 2000;20:392-5.
5. Torre M, Baban A, Buluggiu A, Costanzo S, Bricco L, Lerone M, et al. Dextrocardia in patients with Poland syndrome: Phenotypic characterization provides insight into the pathogenesis. *J Thorac Cardiovasc Surg.* 2010;139(5):1177-82.
6. Sepulveda W. Poland syndrome: A rare cause of cardiac dextroversion in the fetus. *Prenat Diagn.* 2009;29(9):903-5.
7. Baban A, Torre M, Bianca S, Buluggiu A, Rossello MI, Calevo MG, et al. Poland syndrome with bilateral features: Case description with review of the literature. *Am J Med Genet A.* 2009;149A(7):1597-602.
8. Bavincck JN, Weaver DD. 7 Subclavian artery supply disruption sequence: Hypothesis of a vascular aetiology for Poland, Klippel-Feil, and Mobius anomalies. *Am J Med Genet.* 1986;23(4):903-18.

Funding: None; Conflict of Interest: None Stated.

How to cite this article: Mittal HG, Singh Y, Tatawat H, Maria A. Poland syndrome: Atypical presentation and review of literature. *Indian J Child Health.* 2017; 4(2):268-269.