

## Case Report

### Miliary tuberculosis in an immunocompetent adolescent

Swasti Pal<sup>1</sup>, Alpa Gupta<sup>1</sup>, Renu Dhasmana<sup>2</sup>, Manju Saini<sup>3</sup>, Rakhee Khanduri<sup>4</sup>, N K Bhat<sup>1</sup>

From Departments of <sup>1</sup>Pediatrics, <sup>2</sup>Ophthalmology, <sup>3</sup>Radiology, <sup>4</sup>Pulmonary Medicine, Himalayan Institute of Medical Sciences, Swami Rama Himalayan University, Dehradun, Uttarakhand, India

**Correspondence to:** Dr. Alpa Gupta, Department of Pediatrics, Himalayan Institute of Medical Sciences, Swami Rama Himalayan University, Dehradun - 248 016, Uttarakhand, India. Phone: +91-9412911354. E-mail: dralpagupta@hotmail.com

Received – 24 March 2017

Initial Review – 17 April 2017

Published Online – 17 July 2017

#### ABSTRACT

Miliary tuberculosis (TB) is a rare form of TB, seen in approximately 1-2% of all the patients with TB. It represents hematogenous dissemination of uncontrolled TB. Human immunodeficiency virus (HIV) pandemic has led to resurgence of TB in both developed and developing countries. Without treatment, the mortality is near 100%. With early and appropriate treatment; however, mortality can be reduced to <10%. Early diagnosis increases the likelihood of a positive outcome. A 15-year-old boy presented to the outpatient department with complaints of dry cough and fever for 2 months, along with the history of anorexia and weight loss. Clinical workup showed mild pallor, hepatosplenomegaly, and choroid tubercles. Screening for HIV antibodies was negative. X-ray chest showed miliary opacities in the bilateral lung fields. Contrast enhanced computed tomography thorax showed multiple military nodules in both lung fields, tree in bud appearance, and multiple enlarged lymph nodes. The patient was treated with 4 drugs antitubercular treatment along with oral steroids. Follow-up after 1 month showed clinical improvement.

**Key words:** *Choroid tubercles, Miliary tuberculosis, Pulmonary tuberculosis*

Miliary tuberculosis (TB) is a rare form of TB. It is seen in approximately 1-2% of all patients with TB [1]. It occurs due to hematogenous dissemination of mycobacterium TB. Human immunodeficiency virus (HIV) pandemic has led to resurgence of TB in both developed and developing countries. According to the world health organization estimates in 2015, 1 million children currently suffer from TB worldwide (<15 years), and more than 136,000 die each year [2]. Miliary TB is usually seen either in young children or in immunocompromised patients, but it is very rare in immunocompetent patients. We could not find any report of miliary TB in immunocompetent adolescents despite extensive literature search. Here, we are presenting the case of an immunocompetent 15-year-old boy with miliary TB.

#### CASE REPORT

A 15-year-old boy presented in the outpatient department with a history of cough for 2 months, which was dry and progressive in nature with no postural or diurnal variations. There was also the history of low-grade fever, on and off for 2 months, for which, he was receiving symptomatic treatment. In the past 15 days, both fever and cough had increased. There was also history of anorexia and weight loss; although, it was not documented. There was no history of contact with TB, and bacille calmette-guérin (BCG) scar mark was present. There was no history of recurrent respiratory and skin infections, and there was no history of

hospitalization. On general examination, mild pallor was present, but there was no significant lymphadenopathy. Respiratory system examination did not have any significant findings. There was hepatosplenomegaly on per abdomen examination. Central nervous system examination was normal, and there were no signs of meningeal irritation. Detailed ophthalmological examination revealed the presence of choroid tubercles (Fig. 1).

Laboratory investigations showed increased erythrocyte sedimentation rate of 33 mm in 1<sup>st</sup> h. Screening test for HIV antibodies was done which was negative (immunochromatography by SD Bio line kit). Sputum was not available for examination. Induced sputum with 3% saline was tried but the boy did not produce any sputum for investigation. Nasogastric tube placement for gastric lavage was refused by the patient and his parents. Hence, gene expert/cartridge-based nucleic acid amplification test could not be done, and the diagnosis was made on the clinical basis. X-ray chest showed bilateral miliary opacities of the lung. Contrast enhanced computed tomography thorax showed multiple military nodules scattered in both lung fields; small, thick-walled, cavitary lesion in superior segment of left lower lobe and a small, and non-enhancing nodular lesion abutting the pleura in poster basal segment of the right lower lobe (Fig. 2). There was also the presence of reticulonodular interstitial thickening giving tree in bud appearance in superior segment of the left lower lobe along with heterogeneously enhancing lymph nodes in pretracheal, precarinal, and aorta-pulmonary window on computed tomography. Ultrasonography abdomen

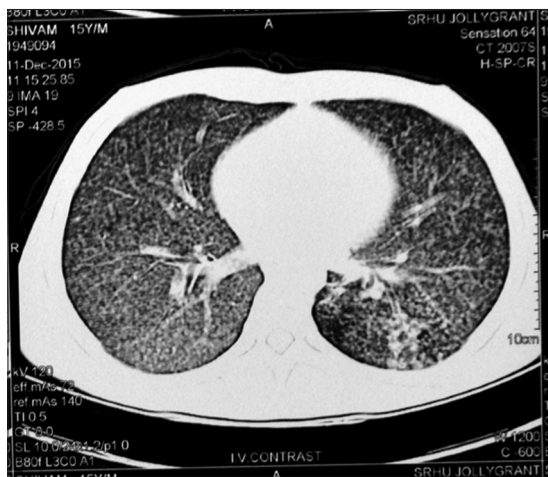


Figure 1: Fundus showing choroid tubercles

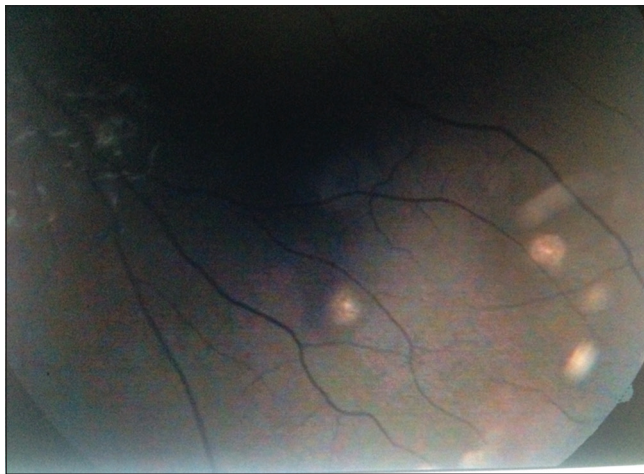


Figure 2: Contrast enhanced computed tomography thorax showing reticulonodular interstitial thickening giving tree in bud appearance in superior segment of the left lower lobe

was suggestive of hepatosplenomegaly with retroperitoneal and mesenteric lymphadenopathy.

The patient was started on 4 drugs antitubercular treatment INH, rifampicin, pyrazinamide, ethambutol (HRZE) along with an oral steroid (prednisolone). An antitussive was given for symptomatic management of cough. The boy tolerated the treatment well. On 2 weeks of follow-up, the cough had markedly decreased, and the patient had become afebrile. On 2 months of follow-up, hepatomegaly was still present but spleen had regressed in size and the appetite had improved.

## DISCUSSION

Miliary TB represents hematogenous dissemination of uncontrolled TB. It can be seen in both primary and secondary TB. Lungs are usually the easiest location for imaging but other organs are also involved. Miliary deposits are about 1-3 mm in diameter (size of a millet seed) with uniform distribution [3]. BCG vaccination decreases the incidence of miliary TB in children [4]. Symptoms, seen more frequently in children, are lymphadenopathy and hepatosplenomegaly; while chills, night

sweats, hemoptysis, and productive cough are less common. A larger proportion of children with miliary TB (20-40%) suffers from tuberculous meningitis compared to adults (15-30%) [5].

Miliary TB has been considered to be more prevalent in children. However, during the last three decades, it is increasingly being recognized in adolescents and adults as well. Several reasons are thought to be responsible for this changing epidemiological trend, most important of which is the rising incidence of HIV/acquired immunodeficiency syndrome. Active TB is 20-30 times more likely in people who are infected with HIV. Approximately 25% of the deaths among HIV-positive people are due to TB. There were an estimated 1.2 million new cases of TB among people who were HIV-positive in the year 2014 [6]. In immunocompetent patients, the reported incidence of miliary TB is very low (<2%).

Diagnosis of miliary TB is essentially radiological. Miliary TB is called so due to the finding of millet-sized lesions on chest X-ray; however, typical findings are seen in only about 50% of the cases. Chest CT scan has higher sensitivity and specificity in displaying well-defined randomly distributed nodules. Tree in bud pattern commonly seen on thin section CT scan of lung consists of a small centrilobular nodule of soft tissue attenuation connected to multiple branching linear structures of similar caliber that originate from a single stalk [7].

The presence of choroid tubercles on fundus examination of the patient is highly suggestive of miliary TB. Choroid tubercles are yellowish lesions, bilateral, pale, gray-white usually <1/4<sup>th</sup> the size of the optic disc and are present within 2 cm of the optic nerve. When present, topical or oral steroids are indicated early in the treatment to prevent visual loss. Miliary TB may rarely occur in an individual organ but commonly affects the entire body including the brain. Meningeal involvement may be seen in up to 25% of patients with miliary TB.

Antitubercular treatment is indicated for 9 months as per the Indian Academy of Pediatrics 2012 Guidelines [8]. Without treatment, the mortality is near 100%; however, mortality can be reduced to <10% with early and appropriate treatment. Early diagnosis increases the likelihood of a positive outcome. The relapse rate is 0-4% with adequate therapy, and most of the relapses are seen during the initial 24 months after completion of therapy [9].

## CONCLUSION

In immunocompetent patients, miliary TB is rare; however, it should be suspected in a case with suggestive history and examination findings as early diagnosis increases the likelihood of a positive outcome. With early and appropriate treatment, mortality can be reduced to <10% which can increase to 100% without treatment.

## REFERENCES

1. Sharma SK, Mohan A, Sharma A, Mitra DK. Miliary tuberculosis: New insights into an old disease. *Lancet Infect Dis*. 2005;5(7):415-30.

2. Global Tuberculosis Report 2015. World Health Organization. Available from: [http://www.who.int/tb/publications/global\\_report/en/#sthash.P8XcdDeo.uSCYqQn3.dpuf](http://www.who.int/tb/publications/global_report/en/#sthash.P8XcdDeo.uSCYqQn3.dpuf). [Last accessed on 2017 February 20].
3. Bickle I, Jones J. Miliary Tuberculosis. Available from: <http://www.radiopaedia.org/articles/miliary-tuberculosis>. [Last accessed on 2017 February 20].
4. Rodrigues LC, Diwan VK, Wheeler JG. Protective effect of BCG against tuberculous meningitis and miliary tuberculosis: A meta-analysis. *Int J Epidemiol*. 1993;22(6):1154-8.
5. Sharma SK, Mohan A, Sharma A. Challenges in the diagnosis & treatment of miliary tuberculosis. *Indian J Med Res*. 2012;135(5):703-30.
6. HIV. Associated Tuberculosis. World Health Organization. Available from: [http://www.who.int/tb/challenges/hiv/tbhiv\\_factsheet\\_2015.pdf?ua=1](http://www.who.int/tb/challenges/hiv/tbhiv_factsheet_2015.pdf?ua=1). [Last accessed on 2017 February 20].
7. Rossi SE, Franquet T, Volpacchio M, Giménez A, Aguilar G. Tree-in-bud pattern at thin-section CT of the lungs: Radiologic-pathologic overview. *Radiographics*. 2005;25(3):789-801.
8. Kumar A, Gupta D, Nagaraja SB, Singh V, Sethi GR, Prasad J. Indian Academy of Pediatrics. Updated national guidelines for pediatric tuberculosis in India, 2012. *Indian Pediatr*. 2013;50(3):301-6.
9. Miliary Tuberculosis. Available from: <http://www.emedicine.staging.medscape.com/article/221777-overview#showall>. [Last accessed on 2017 February 20].

*Funding: Financial support given by Swami Rama Himalayan University, Doiwala, Dehradun, for encouraging academic research work; Conflict of Interest: None Stated.*

**How to cite this article:** Pal S, Gupta A, Dhasmana R, Saini M, Khanduri R, Bhat NK. Miliary tuberculosis in an immunocompetent adolescent. *Indian J Child Health*. 2017; 4(3):459-461.