

CHANGE OF ECG PARAMETERS DEPENDING ON THE LOAD LEVEL IN ATHLETES

Igor Ilić¹, Jasmina Ranković², Olivera Krstić³, Tatjana Popović-Ilić¹, Saša Hadži Ilić¹, Branimir Mekić¹, Slađan Karalejić¹, Vesko Milenković¹ and Rade Stefanović¹

The influence of physical training on bodies of athletes leads to changes that can be characterized as morphological, functional, electrophysiological and psychological. Dynamic exercise, such as running, swimming and riding a bicycle, leads to volume load of heart. Static exercise (gymnastics, weightlifting, wrestling) leads to the development of relatively large muscle force, with or without changes in muscle length and movement of the joint. Given the frequent number of sudden cardiac death cases in sport, it is important to distinguish between changes of the heart that occur as a result of adaptation to physical activity and changes due to some pathological conditions. The aim of this paper is to present the latest information on changes in ECG parameters depending on the load of athletes while performing aerobic trainings in order to better identify markers of adverse cardiovascular events, particularly sudden death in athletes.

It is common to see on the ECG of athletes at rest hypertrophy of the left and right ventricle, interventricular conduction disorder, positive ST changes, and short-term tachycardia. Changes that occur in athletes are due to increased vagal tone and suppression of sympathetic nerve regulation. Many changes can be attributed to intrinsic cardiac component that is responsible for the lower frequency of athlete's heart deinnervation (with atropine or propranolol), which means that intense training influences how the autonomic regulation and the intrinsic cardiac pacemaker function. It is common for athletes to have sinus bradycardia, sinus arrhythmia, first degree AV block and Mobitz I, as well as junctional rhythm, ST segment elevation, high and sharp, or biphasic T-waves, while ST depression or isolated T-wave inversion are less common. They can also have increased amplitude of P-wave and QRS complex, QRS axis rotation to the right and incomplete right branch block. Some but insufficient data tell about the presence of the third-degree AV block and atrial and ventricular ectopic beats and their predictive role for malignant rhythm disorders. *Acta Medica Medianae* 2012;51(3):57-62.

Key words: electrocardiography, heart, sport, physical activity, training

University in Priština, Faculty of Sport and Physical Education, Laposavić¹
Primary Health Care Center Niš²
Municipality of Niš³

Contact: Ilić Igor
University in Priština
Faculty of Sport and Physical Education Laposavić
E-mail: hellper@gmail.com

Introduction

The influence of physical training on bodies of athletes leads to changes that can be characterized as morphological, functional, electrophysiological and psychological. Regular physical training leads to cardiovascular adaptation to physical load. The changes that occur are slow heart rate, blood pressure reduction and increased physical working capacity. Physical activity leads to decreased sympathetic and increased parasympathetic activity (1-3). Repetition of high intensity strains can lead to the "athlete's heart syndrome". The heart is

hypertrophic and characterized by increased efficiency in the state of rest and during physical stress, as well as increased functional capacity (3).

The most common physical activities of athletes are characterized by mixed, both static and dynamic load during exercise. Dynamic exercise is characterized by rhythmic isotonic contractions of large muscle groups, with the result of apparent movement in space. Dynamic exercise, such as running, swimming and riding a bicycle, leads to volume load of the heart. Static exercise (gymnastics, weightlifting, wrestling) leads to the development of relatively large muscle force, with or without changes in muscle length and movement of the joint (2).

The congruity between the tissue need for oxygen and the ability of the cardiovascular system to meet that need can be achieved by exercising in submaximal load zone. The ability of the cardiovascular system increases with training. The basic mechanism here is the adaptive adjustment of neurohumoral regulatory functions. Physical load is

characterized by reaching the limits of the cardiovascular system. In this case, physical training does not affect neurohormonal regulatory mechanisms, but what is important are morphological and functional characteristics of the heart.

The aim of this paper is to present the latest information on changes in ECG parameters depending on the load of athletes while performing aerobic trainings in order to better identify markers of adverse cardiovascular events, particularly sudden death in athletes.

Physiological changes in ECG during load

Many researchers have dealt with changes in electrocardiogram (ECG) parameters before and after physical training. Simnson et al. examined the changes in ECG parameters in healthy young men and middle-aged men. They noticed a decrease in the amplitude of R waves, right-hand axis deviation, junctional depression of ST segment and reduced amplitude of the T wave (4). Sjostrand has shown that the QRS ST depression during the joint exercise in normal subjects is associated with heart rhythm, while other authors found increased P wave amplitude during exercise. These results were confirmed by quantitative ECG analysis using modern computer techniques (5).

ECG changes occur gradually when applying the test for multi-stage practice. The results of such studies show that after the exercise, changes occur only in the sizes of QRS and T, while the directions of these vectors remain constant. On the other hand, Rautaharju et al. have found changes in the size and direction of the vector waveform P wave and ST T segment during submaximal exercise.

ECG can be quantitatively described if measured at rest, in maximum exercise, and in the recovery phase. ECG is observed in normalized intervals of P, QRS and ST segment, in a fixed interval at the end of QRS complex, and in time integral of the negative parts of the ST segment. There are gradual changes in the P, QRS and T waves that may be associated with heart rhythm. The relationship between the ECG and heart rate during the recovery period is significantly different from that during the exercise.

Factors that may be associated with changes in P wave, QRS complex and T wave during exercise include different positions of electrodes that record the heart during rest and during exercise; change of the action potential of atrial and ventricular activation models; enlargement of the atrial repolarization wave; transient increase in the level of potassium in serum; increased hematocrit, and changes in the intracardial blood volume (5).

ECG analysis of the athletes' ergospirometry test is identical to the analysis of the general population. It is common to see on the ECG of athletes at rest the hypertrophy of the left and right ventricle, interventricular conduction disorder, positive ST changes, and short-term tachycardia (8). Changes that occur in athletes are due to

increased vagal tone and suppression of sympathetic nerve regulation. Many changes can be attributed to intrinsic cardiac component that is responsible for the lower frequency of athlete's heart deinnervation (with atropine or propranolol), which means that intense training influences how the autonomic regulation and the intrinsic cardiac pacemaker function (9).

A very common finding in well-trained athletes at rest is sinus bradycardia. Sinus arrhythmia can be found in 13-69% of cases; however, sinus pauses are more frequent and longer. Wandering atrial pacemaker is found more frequently in athletes than in the general population. Any change of rhythm returns to normal in physical activity where simpatic component of the autonomous regulation increases. Another common finding in athletes is disturbance of transition (10, 11).

The most common change in athletes' repolarization is the changes in early repolarization. J spot is the most elevated point, and T-waves may be inverted or tall and sharp. The cause of this phenomenon can be reduction of sympathetic tone at rest, which confirms the finding that changes are lost in the effort and disappear with the cessation of training. However, these claims are not confirmed with great certainty, and we cannot automatically exclude the pathological basis of the occurrence of these changes in athletes (10).

Indicators which point to increased risk of sudden cardiac death

Changes that occur under the influence of physical training (athlete's heart), may be hemodynamic, morphological, metabolic, and psychological neurohormonal (12). Given the frequent number of sudden cardiac death in sport, it is important to distinguish between changes of the heart that occur as a result of adaptation to physical activity and changes due to some pathological conditions (13).

Athlete's heart is characterized by the enlargement of the whole heart, with an increase in its cavities and/or hypertrophy of the heart muscle, and extending its maximum functional capacity. The result is a system cardiovascular adaptation to physical training in the zone of maximum load. Maximum physical load is characterized by achieving the functional limit of the heart and blood vessels. In this load zone, the effects of regulative mechanisms on the cardiovascular system are small (14).

Electrophysiological changes that occur are changes in the heart rhythm, conduction and repolarization changes, and changes in precordial voltage, all manifested in the ECG changes. They are the consequences of the increased vagal tone and suppression of sympathetic nerve regulation. Some of these changes can be attributed to intrinsic cardiac component, which is responsible for the lower frequency of athlete's heart deinnervation (with atropine or propranolol). That means that an intensive training has an impact both on the

autonomic regulation and intrinsic cardiac pacemaker function (9).

Disorders of transmission are very common findings in active athletes: atrioventricular block of first degree, block of second degree, Mobitz type I and II, as well as the third-degree block (10).

Junctional rhythm is more common in athletes than in the general population, while the complete block of His' bundle branch is described in

a very small number of athletes and it is not considered common to the general population (10,15).

Ventricular ectopic beats are rare in athletes; they are not considered to increase the risk of sudden cardiac death (10).

ST segment elevation over the right spouts was found in a small number of cases of sudden cardiac death (16). ST segment depression is less frequent.

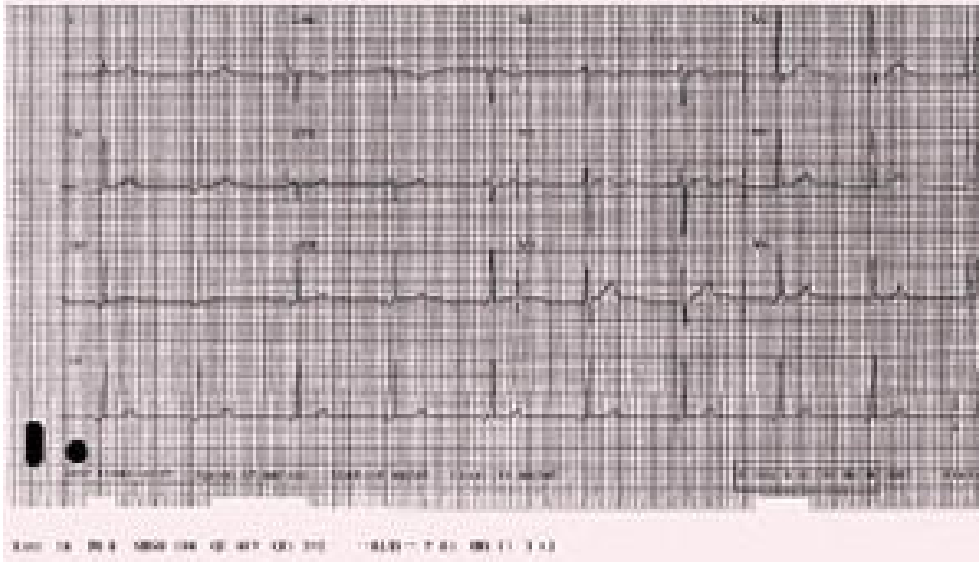


Figure 1. 12 lead ECG showing a junctional rhythm

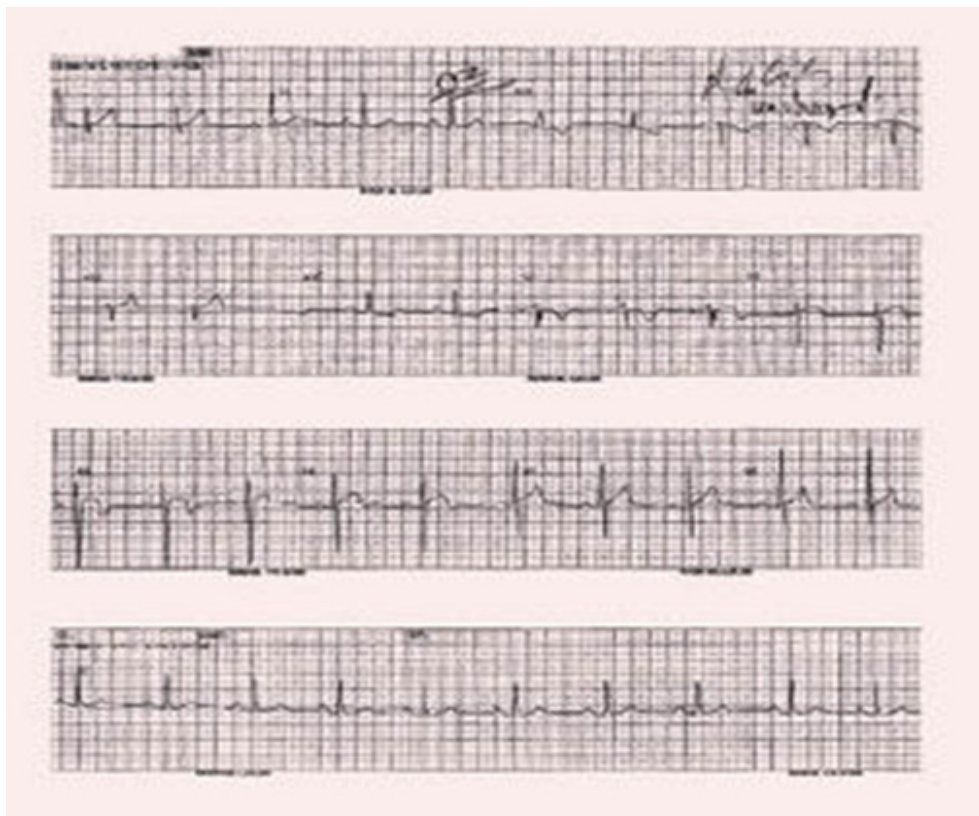

Figure 2. 12-lead ECG showing ST elevation in leads V2 and V3 with terminal T inversions

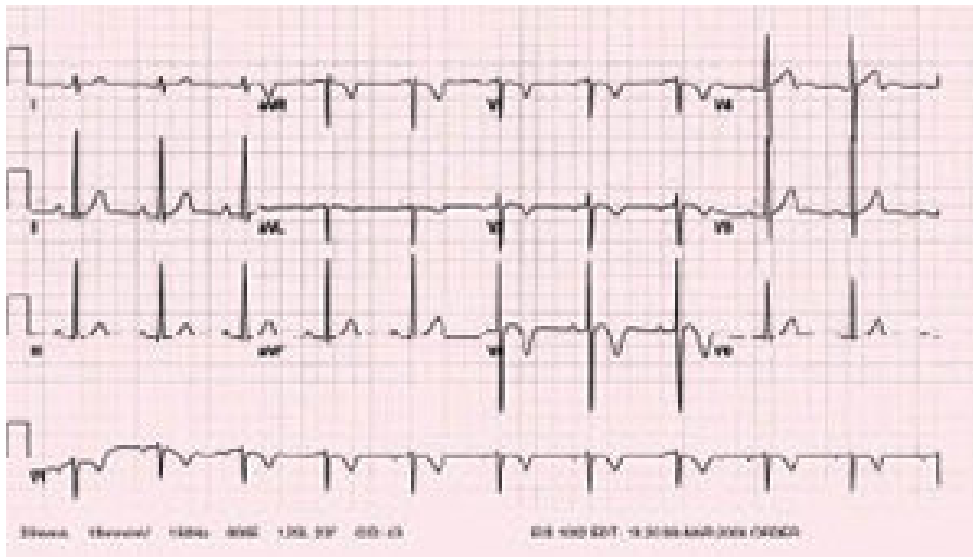


Figure 3: 12 lead ECG; showing terminal T inversions in leads V1 to V3

T-wave of an athlete's heart can change in two directions. It may be tall, tapering or bolted. High T-waves are generally a consequence of early repolarization. In the opinion of some authors, it is not the consequence of the increased concentration of potassium in the blood, as evidenced by the reduction of T-wave amplitude during exercise where we have an increase in the concentration of potassium ions (10). It is considered that the change in the amount of T-wave is the result of changes in repolarization and that it accompanies the increased left ventricular mass (10).

It is not known whether the biphasic T-wave or terminally negative wave, which usually occurs in V3-V5 spouts as a variation of inverted T-wave, is the result of juvenile manifestation or the adaptation to physical activity (10). For all these reasons, great caution is needed when interpreting complete or incomplete inversion of T waves in the ECG, particularly if it is associated with symmetrical contour of T-wave, ST depression, prolonged QT interval, and the absence of normal septal Q-waves. In these conditions, T-wave changes could be a sign of pathology of the heart (10).

Changes in voltage of QRS complexes are very common in athletes compared to non-athletes. It has been proved that dynamic training provides greater changes in voltage than static training, both for left and right ventricle (10).

The axis of QRS complex becomes more vertical with being more trained, which is often associated with incomplete right branch block that can be explained by increased myocardial mass at the top of the right ventricle. This is a change that disappears after cessation of training (10). The elevated P-wave amplitude and jagged Q waves, as well as a prominent U-wave, may be also seen in athletes (10).

Conclusion

Athlete's heart is the result of morphological, functional and electrophysiological alterations during repeated high intensity loads due to the activity of the muscles that need large amounts of oxygen.

It is common for athletes to have sinus bradycardia, sinus arrhythmia, first degree AV block and Mibitz I, as well as junctional rhythm, ST segment elevation, high and sharp, or biphasic T-waves, while ST depression or isolated T-wave inversion is less common. They can also have increased amplitude of P-wave and QRS complex, QRS axis rotation to the right and incomplete right branch block. Some but insufficient data tell about the presence of the third-degree AV block and atrial and ventricular ectopic beats.

References

1. Popović D, Stojiljković S, Šćepanović Lj, Mitrović D. Dinamika arterijskog pritiska i miokardne potrošnje kiseonika pri maksimalnom fizičkom opterećenju kod elitnih košarkaša nacionalnog nivoa i sedentarne kontrolne populacije. *Internist* 2010; 2 (2): 111-7.
2. Levine BD. Exercise Physiology For The Clinician. In: Thompson PD, editor. *Exercise & Sports Cardiology*. Singapore: McGraw-Hill; 2001. pp. 3-30.
3. Popović D, Mazić S, Nešić D, Velkovski S, Stojiljković S, Mijić N, Šćepanović Lj, Mitrović D, Ostojić M. Sindrom sportskog srca. *Srpski arhiv za celokupno lekarstvo*. 2007; 135(3-4): 222-229. [[CrossRef](#)]
4. Simonson E. Effect of moderate exercise on the electrocardiogram in healthy young and middle-aged men. *J Appl Physiol* 1953; 5: 584. [[CrossRef](#)]
5. Simoons ML, Hugenholtz PG. Gradual Changes of ECG Waveform During and After Exercise in Normal Subjects. *Circulation* 1975; 52:570-577. [[CrossRef](#)] [[PubMed](#)]
6. Rautaharju PM, Punsar S, Blackburn H, Warren J, Menotti A. Waveform patterns in Frank-lead rest and exercise electrocardiograms of healthy elderly men. *Circulation* 1973; 48: 541. [[CrossRef](#)] [[PubMed](#)]
7. Sheffield LT, Holt JH, Lester FM, Conroy DV, Reeves TJ. On-line analysis of the exercise electro cardiogram. *Circulation* 1969; 40: 935. [[CrossRef](#)]
8. Popović D i saradnici. Elektrofiziološke karakteristike sportskog srca. *Med Pregl* 2007; 60 (3-4): 156-159. [[PubMed](#)]
9. Huston TP, Puffer JC, Rodney WM. The athletic heart sindrom. *N Engl J Med* 1985; 313: 24-32. [[CrossRef](#)] [[PubMed](#)]
10. Puffer JC. Overview of the athletic heart syndrome. In: Thompson PD. ed. *Exercise and sports cardiology*. Singapore: McGraw-Hill: 2001;30-42. [[PubMed](#)]
11. Landelius J, Norinder U, Svedenhag J, Nowvak J, Sylven C. Beat to beat QRS amplitude variability in elite endurance athletes. *Clin Physiol* 2000; 20(1):79-89. [[CrossRef](#)] [[PubMed](#)]
12. Popović D, Popovic N, Stojiljkovic S, Scepanovic Lj, Mitrovic D, Ostojic MC. Dinamika arterijskog pritiska i miokardne potrošnje kiseonika pri maksimalnom fizičkom opterećenju kod elitnih košarkaša nacionalnog nivoa i sedentarne kontrolne populacije. *Internist* 2010; 2 (2): 111-117
13. Đurđević V, editor. *Sportsko srce*. Beograd: Sportska knjiga; 1981:245-55.
14. Kindermann W. Physiologische anpassungen des herz-kreislauf-systems an koerperlichc belastung. In: Kindermann W. Dickhuth HH. Niess A. Roecker K. Urhausen A, editors. *Sport- Kardiologie*. Darmstadt: Steinkopff; 2003. pp. 1-18.
15. Zeppilli P, Fenici R, Sassara M, Pirrami MM, Caselli G. Wenkebach second-degree A-V block in top-ranking athletes: an old problem revisited. *Am Heart J* 1980;100:281-93. [[CrossRef](#)]
16. Corrado D, Basso C, Buja G, Nava A, Rossi L, Thiene G. Right bundle branch block right precordial ST segment elevation and sudden death in young people. *Circulation* 2001; 103:710-7. [[CrossRef](#)] [[PubMed](#)]

PROMENE PARAMETARA EKG-A U ZAVISNOSTI OD STEPENA OPTEREĆENJA SPORTISTA

Igor Ilić, Jasmina Ranković, Olivera Krstić, Tatjana Popović-Ilić, Saša Hadži Ilić, Branimir Mekić, Slađan Karalejić, Vesko Milenković i Rade Stefanović

Uticajem fizičkog treninga na organizam sportista nastaju promene koje se mogu okarakterisati kao morfološke, funkcionalne, elektrofiziološke i psihološke. Dinamičko vežbanje opterećuje volumen srca. Primeri dinamičke aktivnosti su trčanje, plivanje i vožnja bicikla. Statičko vežbanje (gimnastika, dizanje tegova, rvanje) dovodi do opterećenja pritiskom i razvoja relativno velike mišićne sile, sa ili bez promene u dužini mišića i pokretanja zgloba. S obzirom na česte primere iznenadne srčane smrti u sportu, važno je razlikovanje promena na srcu koje nastaju kao posledica adaptacije na fizičku aktivnost od promena karakterističnih za neka patološka stanja. Cilj rada bio je da se prikažu najnovija saznanja o promenama EKG parametra u zavisnosti od opterećenja sportista pri izvođenju aerobnih treninga kako bi se što bolje identifikovali markeri neželjenih kardiovaskularnih događaja a posebno naprasne smrti kod sportista.

Često se kod sportista u mirovanju na EKG-u mogu videti hipertrofija leve i desne komore, poremećaj interventrikularnog provođenja, ST promene i kratkotrajne tahikardije. Promene su posledica povećanog tonusa vagusa i supresije simpatičke nervne regulacije. Mnoge promene mogu se pripisati in-trizičkoj kardijalnoj komponenti, koja je zaslužna za nižu frekvenciju denervisanog (atropinom ili propranololom) sportskog srca, što znači da intenzivan trening ima uticaja kako na autonomnu regulaciju tako i na intrizičku kardijalnu pejsmejker funkciju. Za sportiste je karakteristična sinusna bradikardija, sinusna aritmija, AV blok prvog stepena i Mibitz I, kao i junctional ritam, elevacija ST segmenta, visoki i zašiljeni, ili bifazični T-talasi, dok se ST depresija ili izolovana inverzija T-talasa ređe sreću. Takođe se javljaju i povećana amplituda P-talasa i QRS kompleksa, rotacija QRS osovine udesno i na kraju inkopletni blok desne grane. Nedovoljno je podataka o zastupljenosti AV bloka III stepena, kao i atrijalnih i ventrikularnih ektopičnih ritmova kod sportista kao i o njihovom prediktivnom značaju za nastanak malignih poremećaja ritma. *Acta Medica Mediana* 2012;51(3):57-62.

Cljučne reči: elektrokardiografija, srce, sport, fizička aktivnost, trening