



## Life-saving percutaneous coronary interventions on the unprotected left main coronary artery in patients with acute coronary syndrome in the catheterization laboratory without cardiosurgical back-up

Spasonosne perkutane koronarne intervencije na nezaštićenom glavnom stablu leve koronarne arterije kod bolesnika sa akutnim koronarnim sindromom u kateterizacionoj laboratoriji bez podrške kardiohirurgije

Sonja Šalinger Martinović\*, Zoran Perišić\*, Michael Weber†, Svetlana Apostolović\*, Milan Živković\*, Miodrag Damjanović\*, Nenad Božinović\*, Tomislav Kostić\*

\*Clinic for Cardiovascular Diseases, Clinical Center Niš, Niš, Serbia; †Kerckhoff-Klinik Herz und Thorax Zentrum Abteilung für Kardiologie, Bad Nauheim, Germany

### Abstract

**Introduction.** The optimal revascularization strategy for unprotected left main coronary disease (ULMCD) is the subject of ongoing debate and patients with ULMCD still represent a challenge for interventionalist, especially in the setting of an acute coronary syndrome (ACS). **Case report.** We presented two cases of percutaneous treatment of ULMCD in the settings of ACS (ST Segment Myocardial Infarction and Non ST Segment Myocardial Infarction – STEMI and NSTEMI) in a catheterization laboratory without back-up of cardiosurgical department. Both patients were hemodynamically unstable with clinical signs of cardiogenic shock. Coronary angiography revealed left main thrombosis and using intra-aortic balloon pump as hemodynamic support primary angioplasty procedures were performed. Immediately after the procedures the patients hemodynamically improved and remained stable till discharge from hospital. **Conclusion.** Percutaneous coronary intervention (PCI) has become the most common strategy of revascularization in ACS patients with ULMCD and is generally preferred in patients with multiple comorbidities and/or in very unstable patients. In cases with no cardiosurgical departments PCI is an inevitable, bail-out, life saving procedure.

**Key words:**  
coronary disease; myocardial infarction; angioplasty, balloon; stents.

### Apstrakt

**Uvod.** Optimalna revaskularizaciona strategija u slučaju suženja glavnog stabla leve koronarne arterije, nezaštićenog graftom (ULMCD), predstavlja veliki izazov za interventne kardiologe, a naročito u situaciji akutnog koronarnog sindroma. (AKS). **Prikaz bolesnika.** Prikazana su dva slučaja perkutanog lečenja tromboze glavnog stabla leve koronarne arterije u akutnom koronarnom sindromu sa i bez elevacije ST segmenta (STEMI i NSTEMI) u centru sa kateterizacionom salom, ali bez kardiohirurške podrške. Oba bolesnika bila su hemodinamski nestabilna, sa kliničkim znacima kardiogenog šoka. Nakon koronarne angiografije kada je registrovana tromboza glavnog stabla, plasirana je intraaortna balon pumpa i urađena primarna angioplastika. Odmah posle procedure registrovano je subjektivno i objektivno poboljšanje hemodinamskog statusa bolesnika i oni su otpušteni sa klinike u stabilnom stanju, bez komplikacija. **Zaključak.** Bolesnici sa AKS usled tromboze glavnog stabla leve koronarne arterije sve češće se podvrgavaju perkutanom koronarnim intervencijama, posebno u slučaju postojanja komorbiditeta ili značajne hemodinamske nestabilnosti. U centrima bez kardiohirurgije, perkutane procedure su neizbežne u cilju spašavanja života jako ugroženih bolesnika.

**Ključne reči:**  
koronarna bolest; infarkt miokarda; angioplastika, balonska; stentovi.

### Introduction

The optimal revascularization strategy for unprotected left main coronary disease (ULMCD) is the subject of ongoing debate<sup>1</sup>. Although it is noteworthy that 2 of the first 5 coro-

nary balloon dilations ever performed were in the left main coronary artery, however several complications such as acute vessel closure precluded the widespread use of multivessel percutaneous transluminal coronary angioplasty (PTCA) in patients with severe coronary disease and left main involve-

ment<sup>2</sup>. On the other hand, a recently performed SYNTAX study has demonstrated good results after ULMCD with similar mortality but higher revascularisation rates in percutaneous coronary interventions (PCI) patients and higher stroke rate in coronary artery bypass graft (CABG) patients<sup>3</sup>.

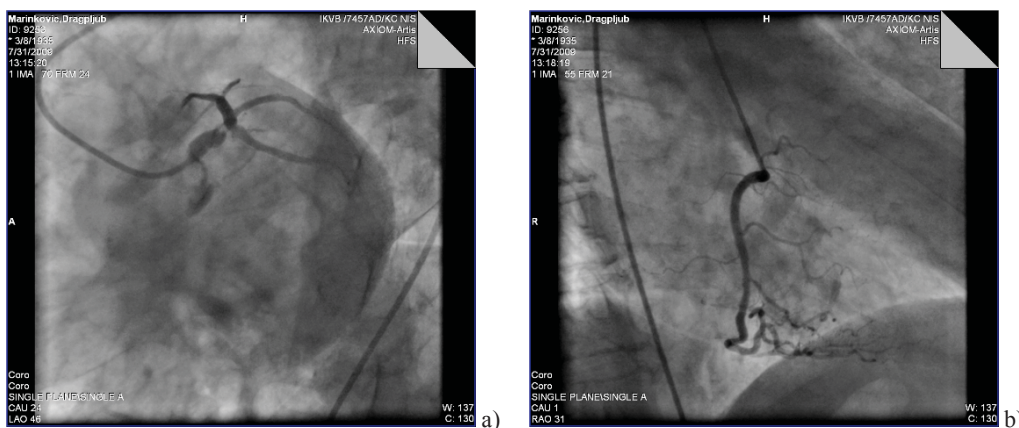
Left main stenting has been carried out with increasing frequency during the last years. Nevertheless, patients with ULMCD still represent a challenge for interventionalist, especially in the setting of an acute coronary syndrome (ACS)<sup>4</sup>. Angiographic and technical details in ULMCD stenting, such as localization of the lesion within the left main (LM), the need for intravascular ultrasound (IVUS) and the technique used to approach the bifurcation, may be extremely important in the acute and long-term results and have already been studied<sup>5,6</sup>. The number of patients who need a CABG in the acute phase is limited, but CABG may be indicated after failed PCI, coronary occlusion not amenable for PCI, the presence of refractory symptoms after PCI, cardiogenic shock or mechanical complications such as ventricular rupture, acute mitral regurgitation or ventricular septal defect<sup>7</sup>.

**Case report**

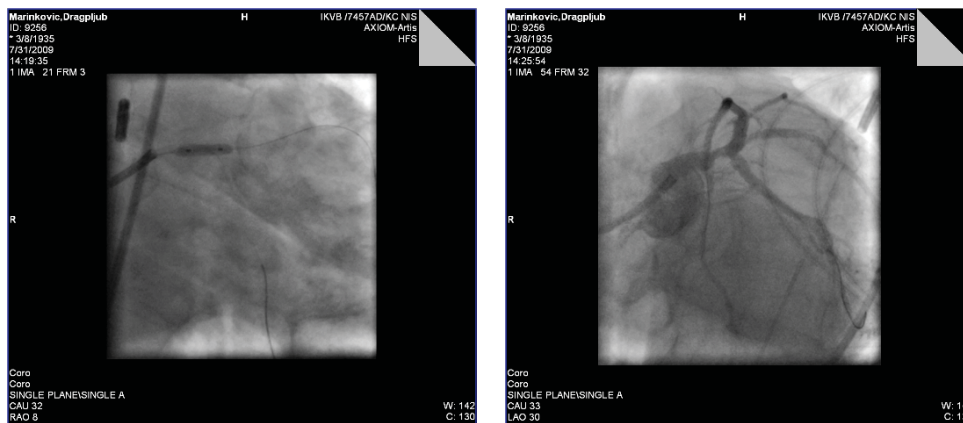
We presented two cases of percutaneous treatment of ULMCD in the settings of ACS (ST Segment Myocardial Infarction and Non ST Segment Myocardial Infarction –

STEMI and NSTEMI) in a catheterization laboratory without back-up of cardio-surgical department.

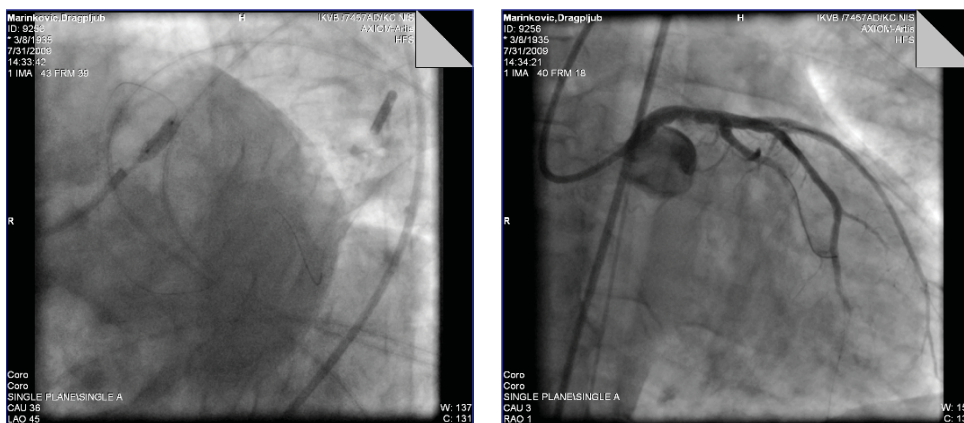
The first patient, a hemodynamically unstable 72-year-old male patient, was admitted to our hospital with an acute coronary syndrome with ST segment elevation in precordial leads. He suffered from arterial hypertension and dyslipidemia, and was a former smoker. Because of intensive chest pain lasting three hours, the patients had called emergency medical service and was transferred to the center with catheterization laboratory. He was treated with unfractionated heparin (UFH, 70 IU /kg), aspirin 300 mg, clopidogrel 600 mg, oxygen, dopamin and analgetics in the emergency means of transportation. At admission the patient was hypotensive with systolic blood pressure of 95 mmHg and with pulmonary basal rales. Emergent coronary angiography revealed spontaneous coronary dissection and thrombosis of the left main with TIMI 1 flow (penetration of the contrast material without perfusion) (Figure 1a). The right coronary artery was without significant stenosis (Figure 1b). After implantation of an intraaortic balloon pump, a guidewire was placed in left anterior descending (LAD) artery, intermediate branch and in right circumflex artery (RCX). Predilatation was performed using Dura-Star compliant balloon 3.0 × 10 mm at 14 atm (Figure 2). A bare metal stent Tsunami Gold 4.0 × 13 was deployed into main stream and inflated at 19 atm (Figure 3), and after that another Tsunami Gold 4.0 × 13 at 14 atm to-



**Fig. 1 – Emergent coronary angiography in ST segment myocardial infarction (STEMI)**  
 a) spontaneous coronary dissection and thrombosis of the left main artery  
 b) the right coronary artery without significant stenosis

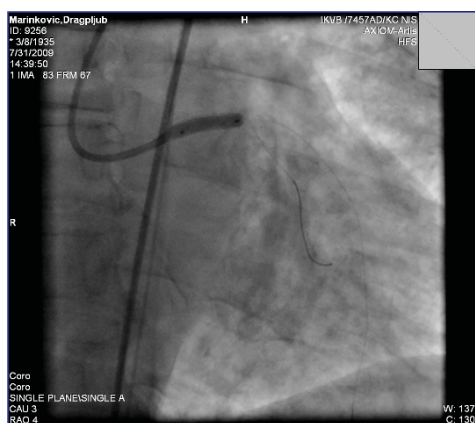


**Fig. 2 – Predilatation with Dura-Star compliant balloon at 14 atm**

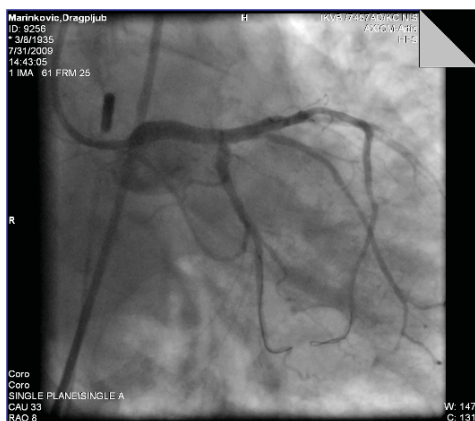


**Fig. 3 – Implantation of a bare-metal stent Tsunami Gold that was inflated at 19 atm**

ward LAD because of visible thrombus nearby ostium (Figure 4). Neither RCX nor right intermediate (RI) were compromised and the procedure was concluded (Figure 5). After 5 days the patient was discharged hemodynamically stable and without any complication.



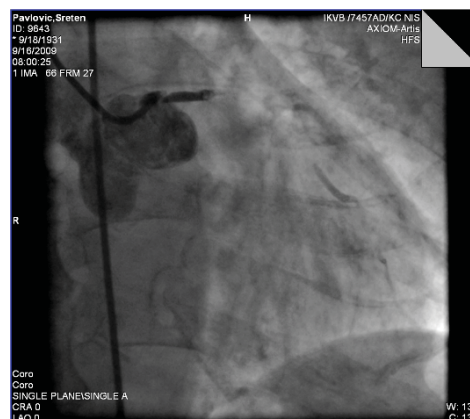
**Fig. 4 – Implantation of the another Tsunami Gold metal stent toward left anterior descending (LAD) artery**



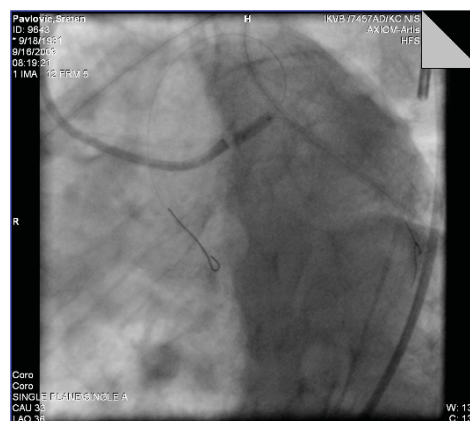
**Fig. 5 – Left anterior descending artery after finishing the procedure**

The second patient was a hemodynamically unstable 78-year-old male, with no risk factor, admitted to our hospital due to chest pain at rest lasting more than 12 h before admission with concomitant ST segment depression of 4 mm. The patient was treated with aspirin 300 mg, clopido-

grel 600 mg, analgetics and UFH (70 IU/kg), and underwent emergent coronary angiography. As culprit lesion ostial LM dissection with thrombus and TIMI 1 flow was found (Figure 6). The right coronary artery (RCA) was without significant stenosis. After implanting an intraortic balloon pump (IABP), a guide wire was introduced in LAD and RCX. Predilatation was performed using a Sprinter NC balloon at 14 atm (Figure 7). Thereafter a 4.0 × 13 baremetal stent Tsunami Gold was inflated at 18 atm (Figure 8a), and proximal part was postdilated with the stent balloon at 20 atm (Figure 8 b and c). During hospitalization of 5 days the patient remained free of symptoms and adverse symptoms.

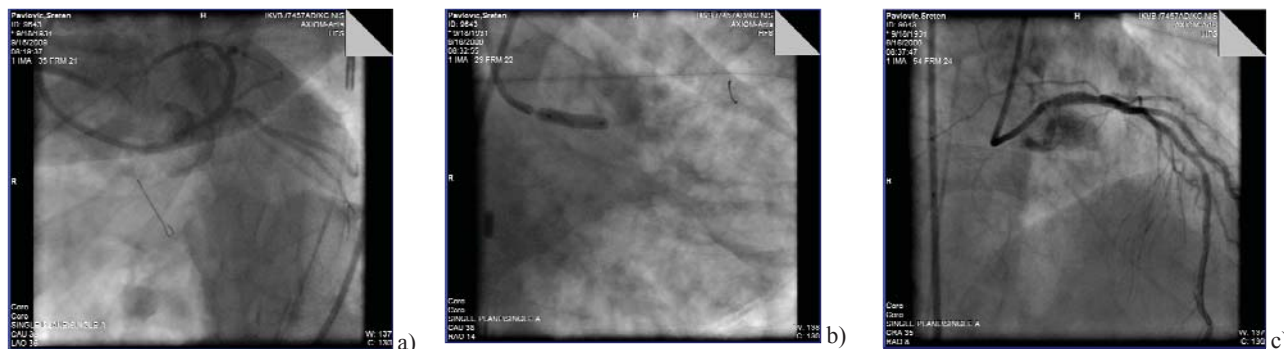

**Fig. 6 – Ostial left main (LM) culprit lesion, dissection and thrombosis on coronary angiography**



**Fig. 7 – Predilatation with a sprinter NC balloon**





**Fig. 8 – Implantation of a bare-metal stent Tsunami Gold**

a – Stent baloon inflated at 18 atm

b and c – proximal part postdilated with stent baloon at 20 atm

## Discussion

Unprotected left main coronary artery disease in patients with an ACS is a serious situation with high in-hospital mortality, especially in those presenting with STEMI and/or hemodynamic or arrhythmic instability Montalescot et al.<sup>1</sup> reported the results of patients with ACS and left main disease included in the Global Registry of Acute Coronary Events (GRACE) between 2000 and 2007 and a trend towards more PCI and less CABG was observed. Overall in-hospital mortality was 7.7% but reached 11% in patients who presented with STEMI or left bundle branch block (LBBB) and was as high as 34% in patients with cardiogenic shock or cardiac arrest<sup>4</sup>. A complete occlusion of the left main is usually associated with cardiogenic shock and therefore represents a very high risk situation requiring immediate life support strategies and urgent revascularization often in conjunction with the use of left ventricular assist devices<sup>8,9</sup>.

In PRECOMBAT (Premier of Randomized Comparison of Bypass Surgery versus Angioplasty Using Sirolimus-Eluting Stent in Patients with Left Main Coronary Artery Disease) prospective, randomized trial involving patients with unprotected left main coronary artery stenosis, PCI with sirolimus-eluting stents was noninferior to CABG with respect to the primary composite end point of major adverse cardiac or cerebrovascular events at 1 year. In addition, the two groups had similar rates of individual components of death, myocardial infarction, and stroke. However, the rate of ischemia-driven target-vessel revascularization at 2 years was lower in the CABG group than in the PCI group<sup>10</sup>.

In a recently on-line published metaanalysis of randomized patients with unprotected left main stenosis, the risk of death and myocardial infarction was comparable between CABG and PCI. However, patients undergoing CABG had a higher risk of stroke, whereas patients undergoing PCI were at a higher risk for repeated revascularization<sup>11</sup>.

In Serbia as developing country, many unresolved clinical needs remain for revascularization strategies. Cardiosurgical departments in most cases are far away and are not able to provide sufficient capacity for surgical back up. Therefore, interventional strategies need to be implemented, even in scenarios in which clear cut recommendations are given for surgical treatment. The presented cases demonstrate that immediate PCI of an unprotected LMA stenosis together with implantation of a left ventricle (LV) assist system (IABP) can be a life saving procedures and should be performed without any delay if surgery is not immediately available.

## Conclusion

Unprotected left main coronary artery disease in patients with an ACS is rare but serious situation with high in-hospital mortality, especially in those presenting with STEMI and/or hemodynamic or arrhythmic instability. Percutaneous coronary intervention has become the most common strategy of revascularization in ACS patients with ULMCD and is generally preferred in patients with multiple comorbidities and/or in very unstable patients. In cases with no cardiosurgical departments PCI is an inevitable, bail-out, life saving procedure.

## REFERENCES

1. Montalescot G, Brieger D, Eagle KA, Anderson FA Jr, FitzGerald G, Lee MS, et al. Unprotected left main revascularization in patients with acute coronary syndromes. *Eur Heart J* 2009; 30(19): 2308–17.
2. Gulati R, Ribbal CS, Gersh BJ. The SYNTAX trial: a perspective. *Circ Cardiovasc Interv* 2009; 2(5): 463–7.
3. Wijns W, Kolb P. Appropriate myocardial revascularization: a joint viewpoint from an interventional cardiologist and a cardiac surgeon. *Eur Heart J* 2009; 30(18): 2182–5.
4. Corti R, Toggweiler S. PCI in acute left main disease: a paradigm shift or a new reality? *Eur Heart J* 2009; 30(19): 2295–6.
5. Lozano I, Avanzas P, Moris C. Should the left main be covered entirely with drug-eluting stents in percutaneous intervention. *J Invasive Cardiol* 2006; 18(11): E276–8.
6. Tamburino C, Di Salvo ME, Capodanno D. Morpho-functional assessment of left main coronary artery disease. In: Tamburino C, Di Salvo ME, La Manna A, Capodanno D, editors. Left main coronary artery disease. A practical guide for the interventional cardiologist. New York: Springer-Verlag; 2009. p. 27–42.
7. Van de Werf F, Bax J, Betriu A, Blomstrom-Lundqvist C, Crea F, Falk V, et al. Management of acute myocardial infarction in patients presenting with persistent ST-segment elevation: the Task Force on the Management of ST-Segment Elevation

- Acute Myocardial Infarction of the European Society of Cardiology. *Eur Heart J* 2008; 29(23): 2909–45.
8. *Antman EM, Anbe DT, Armstrong PW, Bates ER, Green LA, Hand M*, et al. ACC/AHA guidelines for the management of patients with ST-elevation myocardial infarction: a report of the American College of Cardiology/American Heart Association Task Force on Practice Guidelines (Committee to Revise the 1999 Guidelines for the Management of Patients with Acute Myocardial Infarction). *Circulation* 2004; 110(9): e82–292.
  9. *Tamburino C, Di Salvo ME, Capodanno D*. Literature Review. In: *Tamburino C, Di Salvo ME, La Manna A, Capodanno D*, editors . Left main coronary artery disease. A practical guide for the interventional cardiologist. New York: Springer-Verlag; 2009. p. 15–25.
  10. *Park SJ, Kim YH, Park DW, Yun SC, Ahn JM, Song HG*, et al. Randomized trial of stents versus bypass surgery for left main coronary artery disease. *N Engl J Med* 2011; 364(18): 1718–27.
  11. *Desch S, Boudriot E, Rastan A, Buszman PE, Bochenek A, Mohr FW*, et al. Bypass surgery versus percutaneous coronary intervention for the treatment of unprotected left main disease : A meta-analysis of randomized controlled trials. *Herz* 2012; DOI: 10.1007/s00059-012-3596-y.

Received on July 2, 2010.

Revised on April 17, 2012.

Accepted on April 17, 2012.