



Morphometric parameters as risk factors for anterior cruciate ligament injuries – A MRI case-control study

Morfometrijski parametri kao faktori rizika od nastanka povrede prednjeg ukrštenog ligamenta

Lazar Stijak*, Marko Bumbaširević†, Marko Kadija†, Gordana Stanković*,
Richard Herzog‡, Branislav Filipović*

*Department of Anatomy, Faculty of Medicine, University of Belgrade, Belgrade, Serbia; †Clinic for Orthopaedic Surgery and Traumatology, Clinical Center for Serbia, Belgrade, Serbia; ‡Kantonales Spital Luzern, Luzern, Schweiz

Abstract

Background/Aim. The anterior cruciate ligament (ACL) is the most frequently injured ligament of the knee, representing 50% of all knee injuries. The aim of this study was to determine the differences in the morphometry of knee injury patients with an intact and a ruptured anterior cruciate ligament. **Methods.** The study included 33 matched pairs of patients divided into two groups: the study group with the diagnosis of anterior cruciate ligament rupture, and the control group with the diagnosis of patellofemoral pain but no anterior cruciate ligament lesion. The patients were matched on the basis of 4 attributes: age, sex, type of lesion (whether it was profession-related), and whether the lesion was left- or right-sided. Measurements were carried out using magnetic resonance imaging (MRI). **Results.** The anterior and posterior edges of the anterior cruciate ligament in the control group were highly significantly smaller ($p < 0.01$; in both cases). The control group showed a statistically significantly larger width of the

anterior cruciate ligament ($p < 0.05$). A significant correlation between the width of the anterior cruciate ligament and the width ($p < 0.01$) and height ($p < 0.05$) of the intercondylar notch was found to exist in the control group, but not in the study group ($p > 0.05$). The patients in the control group showed a shorter but wider anterior cruciate ligament in comparison to their matched pairs. The control group of patients was also characterized by the correlation between the width of the intercondylar notch and the width of the anterior cruciate ligament, which was not the case in the study group. **Conclusions.** According to the results of our study we can say that a narrow intercondylar notch contains a proportionally thin anterior cruciate ligament, but we cannot say that this factor necessarily leads to rupture of the anterior cruciate ligament.

Key words:

anterior cruciate ligament; injuries; risk factors; anthropometry.

Apstrakt

Uvod/Cilj. Prednja ukrštena veza je veza kolena koje se najčešće povređuje, što čini 50% od ukupnih povreda kolena. Cilj ove studije bio je da se utvrde razlike u morfometriji zgloba kolena kod bolesnika sa intaktnom i rupturisanom prednjom ukrštenom vezom. **Metode.** Ispitanike ove studije činili su 33 para sa povredom zgloba kolena, podeljena u dve grupe: ispitivanu grupu činili su bolesnici sa dijagnostikovanom rupturom prednje ukrštene veze, a kontrolnu bolesnici sa dijagnostikovanom patelofemoralnim sindromom bez povrede prednje ukrštene veze. Bolesnici su bili upareni na osnovu četiri karakteristike: godine, pol, vrsta povrede (koja je uslovljena vrstom sporta kojim se bave) i na osnovu strane tela. Sva merenja su vršena na snimcima magnetne rezonance. **Rezultati.** Ispitanici bez rupture prednje ukrštene veze posedovali su statistički visokoznačajno kraću prednju i zadnju ivicu

prednje ukrštene veze od svojih parova ($p < 0,01$; u oba slučaja). Takođe, kontrolna grupa za razliku od ispitivane, imala je statistički značajno veći sagitalni prečnik prednje ukrštene veze ($p < 0,05$). Postojala je statistički značajna povezanost sagitalnog prečnika prednje ukrštene veze sa širinom ($p < 0,01$) i visinom ($p < 0,05$) međukondilarne jame unutar kontrolne, ali ne i unutar ispitivane grupe ($p > 0,05$; u oba slučaja). Bolesnici kontrolne grupe posedovali su kraću ali širu prednju ukrštenu vezu od svojih parova. **Zaključak.** Na osnovu podataka naše studije možemo reći da uska međukondilarna jama sadrži proporcionalno tanju prednju ukrštenu vezu, ali ne možemo tvrditi da ovaj faktor nužno vodi rupturi prednje ukrštene veze.

Ključne reči:

ligament, prednji ukršten; povrede; faktori rizika; antropometrija.

Introduction

The anterior cruciate ligament (ACL) is the most frequently injured ligament of the knee, representing 50% of all knee injuries¹. ACL injury is almost always associated with physical activity which is why the incidence of this type of injury is the highest amongst the population of athletes. It is often necessary to reestablish the continuity of the ruptured ACL in order to avoid giving way episodes.

In addition to the morphometric characteristics of the intercondylar notch and the tibial slope, the morphometric characteristics of the ligament also have effect on the frequency of ACL injury². These characteristics are primarily its length and thickness. An increased length can increase laxity of the joint while a ligament that is too thin may rupture more easily. On the other hand, a short ligament may restrict movement of the knee joint, primarily extension. As early as 1938 Palmer³ reported that the ACL may sustain injury from the medial edge of the lateral condyle. Norwood and Cross reported that, in extension, the ACL can come in contact with the lateral wall of the intercondylar notch which can result in injury⁴. Many studies have shown the correlation between a narrow intercondylar notch and ACL ruptures⁵⁻⁷. It is a generally accepted fact that a small intercondylar notch contains a small and weak ACL^{8,9}.

In addition to the length and thickness of the ACL, the morphometric characteristics of the femoral and tibial attachments of the ligament were also observed in this study. Edwards et al.^{10,11} described the anatomic localization of the tibial insertion and the femoral origin of the ACL and of its parts. They emphasized the significance of the choice of attachment location on the femur and tibia for the preservation and normal functioning of the implanted graft. The anterior part of the ACL origin on the femur has the form of a straight line¹ extending from the posterior femoral cortex line. The posterior edge of the insertion has the form of an arc of 4 mm in width⁹ (Figure 1a). The ACL insertion on the tibia is somewhat larger and stronger than the

front and the anterior horn of the lateral meniscus at the back. The edges of the insertion are limited by the joint surface of the tibial condyles.

The aim of this study was to determine the differences between ACL morphometry in patients with and intact and those with a ruptured ACL.

Methods

The study group consisted of 205 patients with isolated noncontact ruptures of the ACL and with no reported lesions of collateral ligaments, posterior cruciate ligaments or other bone elements. The control group consisted of 258 patients whose major complaint was patellofemoral pain, but did not have any dysplastic change of the knee. After matching 33 pairs from the two groups, a total of 66 patients were taken into consideration for the study. The patients were matched according to their age at the time of accident (a difference of up to 5 years was tolerated), sex, type of lesion (whether it was profession-related), and whether the lesion affected the left or right side of the knee. There were 21 male and 12 female pairs: 9 pairs with soccer related, 4 pairs with ski related, 3 pairs with gymnastics related, and 16 pairs of patients with other sports-related lesions as well as one case of a motorbike accident. Twenty pairs had the lesion on their right knee and thirteen pairs on the left knee. The average age of the patients was 30 ± 10 years (range, 15–48 years) in the study group, and 30 ± 11 years (range, 15–48 years) in the control group. All measurements were performed by radiography and magnetic resonance imaging (MRI). All MRIs were made using 1.5 T magnets in Schweizer Paraplegiker-Zentrum (SPZ) Nottwil (Schweiz) within 7 days of knee injury.

The following anatomical parameters were measured: the length of the anterior and posterior edge of the ACL on the sagittal MR section; the mean length and the sagittal diameter (width) of the ligament; the length of the femoral origin; the length and width of the tibial insertion; the width and the height of the intercondylar notch.




Fig. 1 – A schematic presentation of the femoral origin (a) and tibial insertion (b) of the anterior cruciate ligament (ACL) and its parts.

a) blue – the anteromedial part; green – the posterolateral part (t – length of origin; h – width of origin);
b) blue – the anteromedial part; green – the posterolateral part (a – insertion width; b – insertion length).

insertion on the femur¹². It has an elliptic form with a greater anteroposterior diameter (Figure 1b). It is situated between the anterior horn of the medial meniscus in the

The frontal MR section was used for the selection of the sagittal section that best covered the ACL (Figure 2). The borders of the tibial and femoral attachments were drawn on

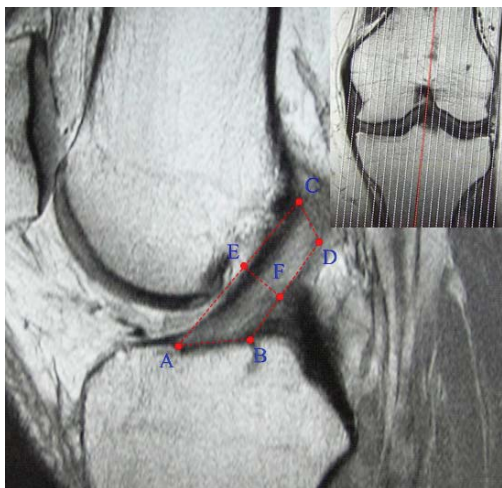


Fig. 2 – Selected sagittal section. Method of measuring anterior cruciate ligament (ACL) dimensions and the dimensions of its attachments on the sagittal magnetic resonance (MR) section (AC – anteromedial edge; BD – posterolateral edge; AB – length of tibial insertion; CD – length of femoral origin; EF – sagittal diameter or width). Picture in the upper right corner shows selected sagittal section (red section) in coronal plane.

the selected section and the distance from the most anterior point on the tibia to the proximal point on the femur (the length of the anterior edge) and the distance from the most posterior point on the tibia to the distal point on the femur (length of the posterior edge) of the ACL were measured. The same image was used to measure the sagittal diameter (width) of the ACL represented as the length perpendicular to the direction of the ligament, at an equal distance from the tibial to the femoral attachment. The length of the tibial insertion was measured as the distance between the anterior and the posterior point of the insertion. The length of the femoral origin was measured as the distance between the most proximal to the most distal point of the origin. The width of the tibial insertion was measured on the frontal image running through the widest segment of the insertion (Figure 3).

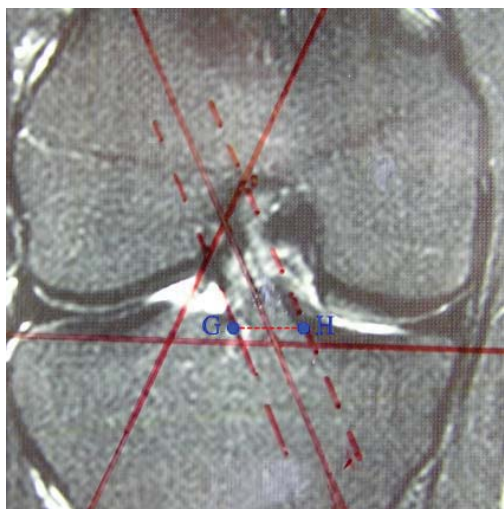


Fig. 3 – The method of measuring the width of the anterior cruciate ligament (ACL) tibial insertion (GH distance).

The intercondylar notch dimensions were measured on the horizontal MR section passing through the most posterior

points of the medial and lateral condyle of the femur (Figure 4). The following were measured on the selected MR image: the width of the intercondylar notch at the level of the popliteal groove (ICW), the maximum intercondylar width (ICW_{max}) and the intercondylar height (ICH) measured as the shortest distance between the highest point of the intercondylar notch and the line passing through the most posterior point of the medial and lateral condyles.

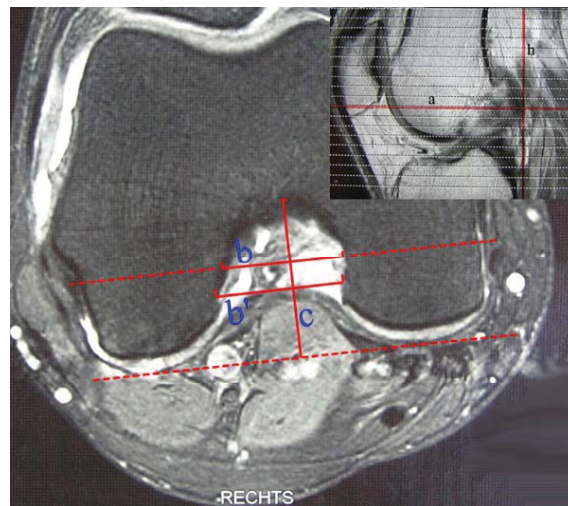


Fig. 4 – The section (a) used for measurements was determined on the basis of the vertical line (h) passing through the most posterior point of the lateral condyle (picture in the upper right corner). The width of the intercondylar notch at the level of the popliteal groove (b), the maximum width of the intercondylar notch (b') and the height of the notch (c) were measured.

In order to estimate intraobserver variation, all morphometric parameters were measured twice by one observer, with a coefficient of variance of less than 3%. The differences between the groups in relation to the above mentioned anatomical parameters were tested with the use of the Student's *t*-test for matched pairs. The relation between the ACL sagittal diameter (width) and the morphometric parameters of the intercondylar notch was tested via the Pearson's coefficient of correlation within the SPSS 11.0 programme. The level of statistical significance was $p < 0.05$.

Results

The lengths of the anterior and posterior ACL edges in the study group, as well as their mean value were greater by approximately 4 mm than in the control group (Table 1). This difference is of high statistical significance ($p < 0.01$). The study group displayed a narrower ACL width by some 1.1 mm in comparison to the control group. This difference is statistically significant ($p < 0.05$). No statistically significant difference was determined between the study and control groups as regards to the length and width of the ACL tibial and femoral attachments nor the width of the intercondylar notch at the level of the popliteal groove and at the widest point ($p > 0.05$).

Table 1
Morphometric parameters of the anterior cruciate ligament (ACL) and the intercondylar notch.
(mean values and standard deviations)

Variables	Examined group (mm)	Control group (mm)	<i>p</i> value
Length of the ACL anterior edge	46.6 ± 4.7	42.6 ± 3.0	< 0.01
Length of the ACL posterior edge	27.8 ± 3.6	23.6 ± 2.6	< 0.01
Median ACL length	37.2 ± 3.9	33.2 ± 2.2	< 0.01
ACL width	11.0 ± 1.8	12.1 ± 1.7	< 0.05
Tibial insertion width	11.3 ± 1.5	11.9 ± 1.9	= 0.092
Tibial insertion length	19.4 ± 2.7	18.4 ± 2.8	= 0.102
Femoral origin length	13.0 ± 2.6	13.5 ± 2.4	= 0.446
ICW	21.2 ± 2.5	22.3 ± 3.0	= 0.083
ICW _{max}	22.9 ± 2.7	23.1 ± 2.9	= 0.771
ICH	31.9 ± 3.2	30.6 ± 2.4	< 0.05

ICW – the width of the intercondylar notch at the level of the popliteal groove; ICW_{max} – maximum intercondylar width; ICH – intercondylar height.

The ACL width correlates with the width of the intercondylar notch at the level of the popliteal notch ($r = 0.580$) and at the widest point ($r = 0.506$), in patients whose ACL remained intact after knee joint injury ($p < 0.01$), but not in the patients with a ruptured ACL ($p > 0.05$; Table 2). Also, the ACL width correlates with the height of the intercondylar notch ($r = 0.347$) in the patients with an intact ACL ($p < 0.05$), but not in the patients with a ruptured ligament ($p > 0.05$).

tained in our study. The reason for greater values in our study can be explained by different places of measurement. The above mentioned author measured the length of the anteromedial and posterolateral parts of the ACL while we measured its anterior and posterior edges.

In our study, the mean length of the ACL showed greater values ($p < 0.01$) in the study group than in the control group. Bradley et al.¹⁴ measured an average ACL length of 32 mm on four cadaverous knees with no pathological

Table 2
Correlation between the anterior cruciate ligament (ACL) width and the morphometric parameters of the intercondylar notch

Group	Coefficient of correlation		
	ICW	ICW _{max}	ICH
Examined	0.100	0.204	0.243
Control	0.580**	0.506**	0.347*

ICW – the width of the intercondylar notch at the level of the popliteal groove;

ICW_{max} – maximum intercondylar width; ICH – intercondylar height.

* $p < 0.05$; ** $p < 0.01$.

Discussion

Measuring the width of the ruptured ACL using sagittal MR image posed a problem due to the broken continuity of the ruptured ligament. This is why, on MR images of both groups of patients, we measured the length of the ACL anterior edge as the distance from the most anterior point of the tibial insertion to the most proximal point of the femoral origin, and the length of the posterior edge, as the distance between the most posterior point of the tibial insertion to the most distal point of the femoral origin. Also, the width was measured at an equal distance from the tibial and femoral attachments, perpendicular to the direction of the ACL, as the distance between the approximate anterior and posterior edges.

The study group showed greater values for the anterior ACL edge length than the control group, and a similar difference was also noted regarding the posterior ACL edge ($p < 0.01$; in both cases). In their study, performed on 9 volunteers using 3D MR images, Iwahashi et al.¹³ reported that the length of the anteromedial ACL bundle was 34 mm and the length of the posterolateral bundle was 27 mm. The length of the anteromedial bundle was shorter, and the length of the posterolateral bundle was greater than the lengths ob-

changes of the joint, obtaining a result rather similar to our results in the control group. In the study of 33 cadaverous knees Odensten and Gillquist¹⁵ reported an average ACL length of 31 mm.

In our study the acquired values of ACL width are statistically significantly greater in the control than in the study group ($p < 0.05$). Anderson et al.¹⁶ measured the width of the ACL on oblique sagittal MR images and obtained significantly lower values in female (7.6 mm) than in male basketball players (8.7 mm) aged 16 years, on average. Also, the reason for lower values of the ACL width could be the result of the fact that the examinees' body growth was not yet complete.

The width of the intercondylar notch of the control group at both points of measurement (at the level of the popliteal groove and at the level of maximum width) showed somewhat greater values than in the case of the study group. However, this difference is not statistically significant ($p > 0.05$). Other authors report generally lower values in the width of the intercondylar notch, which is probably the reason for measuring the width at different depths of the notch, in patients of different sex and in different age groups. Both of our groups covered adult subjects, mostly male, who displayed no osteoarthritic changes, i.e. a population whose

growth process was complete and the process of ageing had not yet started. Lund-Hanssen et al.¹⁷ reported that an intercondylar width below 17 mm was critical for the increase of risk of ACL injury. Only one examinee (a woman) in our study had the value of the intercondylar width below this critical amount. Lombardo et al.¹⁸ measured the width of the intercondylar notch on X ray images and also found no difference between professional basketball players with a ruptured ACL (23.4 mm) and those whose ACL was intact (23.5 mm). These values are only slightly greater than the values obtained in our study, which is probably the result of measuring being performed in different population groups and the use of MR during measurement. In their study on 213 track-and-field athletes Laprade and Burnet⁶ concluded that the narrowing of the intercondylar notch was associated to ACL injury. Good et al.¹⁹ measured a somewhat smaller ICW in three groups of patients: patients with chronic ACL insufficiency (16.1 mm), patients with acute ACL injury (18.1 mm) and cadaveric material (20.4 mm). The intercondylar notch width was measured at the widest part of the anterior outlet of the intercondylar notch, just above the meniscal plane. In this case the presence of osteophytes in patients with chronic ACL insufficiency led to the narrowing of the intercondylar notch. Odensten and Gillquist¹⁵ did not find a statistically significant difference in ICW between the control group and the group with a ruptured ACL.

In the control group, but not in the study group, our study determined the existence of a highly statistically significant correlation between the value of the ACL's width and the width of the intercondylar notch at the level of the popliteal groove and at the widest point ($p < 0.01$), as well as between the values for the ACL's width and the height of the intercondylar notch ($p < 0.05$). We can assume that this correlation between the ACL's width and the size of the intercondylar notch has a positive effect on the preservation of the ACL. Based on the data from our study we can conclude that there is a disproportion between the ACL's width and the intercondylar notch in patients with a ruptured ACL. As the intercondylar notch is filled by the ACL and PCL, further studies should determine whether in the case of a thin ACL the remaining space is filled by the PCL thus increasing the misbalance between the stronger PCL and the weaker ACL, i.e. whether a wide ACL damages itself by pressing against the lateral femoral condyle or against the PCL.

On the other hand the data about the existence of a correlation between ACL width and the width of the intercondylar notch were explained by Dienst et al.²⁰ in their study on MR images of 20 volunteers whose knees showed no pathological changes. They established that there was a highly statistically significant correlation ($p < 0.01$) between ACL transverse sections and transverse sections of the inlet i.e. the outlet of the intercondylar notch. In the above mentioned study the ACL transverse section, at the point where it is closest to the PCL, was compared, as well as the mean value of the cross-sectional notch area on the notch inlet (the distal part of the notch) and the notch outlet (the proximal part of the notch). Davis et al.⁸ also analyzed "normal" knees using MR images. They found that there was a signifi-

cant correlation between the ACL and the intercondylar width. They measured the width of the notch and the width of the ACL at the point where the two ligaments (ACL and PCL) cross one another. The section chosen in each knee was the section where the ACL and the PCL cross one another as close as possible to the mid-substance of the ACL). Similar results were obtained by Stäubli et al.²¹ on oblique frontal MR images (showing a significantly positive correlation between the width of the ACL and the intercondylar width). This study was also performed on knees with an intact ACL. On the other hand, in their study performed on cadavers, using a caliper and mould technique (a positive mold of the entire anterior cruciate ligament was created with silicone rubber and plaster commonly used for dental molding), Muneta et al.⁹ did not find a significant correlation between the intercondylar width and the different measurements of the ACL (the width, sagittal length, and the cross-sectional area of the mid-substance and the femoral and tibial insertions of the ACL), with the exception of the length of the tibial insertion. A possible explanation for these results might lie in the fact that the donors were 40 years older, on average, than our donors, which could have influenced the dimensions of the intercondylar notch, as well as the dimensions of the ACL. In the study of 50 cadaverous knees Stijak et al.²² found a significant correlation between the ACL width and the male intercondylar width but not with the female intercondylar width.

The data obtained in our study do not describe the length and width of the ACL tibial insertion nor the length of the ACL femoral origin as significant for ACL injury ($p > 0.05$; in all three cases). Papachristou et al.²³ obtained very similar values of the tibial insertion for men (19.5 mm) and women (17.4 mm), by direct measurements on the tibiae of 55 cadavers (30 male and 25 female). In their study performed on 55 cadaverous knees of an older mixed population, Edwards et al.¹⁰ also obtained the result of 18 mm for the length of the tibial insertion. Stäubli and Rauschnig²⁴ compared 3 different methods of measuring the length of the tibial insertion: method one – direct measurement performed on 10 cadaverous knees; method two – the cryoplaning technique (on 5 knees); and method three – use of MR imaging on 25 knees (23 male and 12 female). The published values for the length of the tibial insertion were: 15 mm for cadaverous knees; 17.4 mm for the cryoplaning technique and 16.9 mm and 16 mm for the MR imaging of men and women, respectively.

Upon measuring 22 cadaveric knees Edwards et al.¹¹ obtained the result of 14 mm for the length of the femoral origin, while Bradley et al.¹⁴ obtained the result of 14.5 mm for the length of the femoral origin, also on cadavers. These values are only slightly greater than the values obtained in our study and are probably the result of the indirect measuring method and the different population groups.

Conclusion

Upon studying the ACL morphometric characteristics in 33 matched pairs we can say that the patients whose ACL remains intact after knee joint injury have a shorter

but wider ACL in comparison to their matched pairs. Also, the control group of patients is characterized by a correlation between the width of the intercondylar notch and the width of the ACL, which is not the case with the study group. In this case we can conclude that a narrow intercon-

dylar notch contains a narrow ACL, but this fact is not significant to ACL rupture. What is significant to rupture is the fact that a narrow intercondylar notch can contain a wide ACL and *vice versa*, a wide intercondylar notch can contain a narrow ACL.

R E F E R E N C E S

1. *Lesic A, Bumbasirevic M.* The clinical anatomy of cruciate ligaments and its relevance in anterior cruciate ligament (ACL) reconstruction. *Folia Anat* 1999; 27(1): 1–11.
2. *Arendt EA.* Anterior cruciate ligament injuries. *Curr Womens Health Rep* 2001; 1(2): 211–7.
3. *Palmer I.* On the injuries to the ligaments of the knee joint: a clinical study. *Acta Chir Scand Suppl* 1938; 53: 1–28.
4. *Norwood LA, Cross MJ.* The intercondylar shelf and anterior cruciate ligament. *Am J Sports Med* 1977; 5(4): 171–6.
5. *Ireland ML, Ballantyne BT, Little K, McClay IS.* A Radiographic analysis of the relationship between the size and shape of the intercondylar notch and anterior cruciate ligament injury. *Knee Surg Sports Traumat Arthrosc* 2001; 9(4): 200–5.
6. *Laprade RF, Burnett QM.* Femoral intercondylar notch stenosis and correlation to anterior cruciate ligament injuries. A prospective study. *Am J Sports Med* 1994; 22(2): 198–203, discussion 203.
7. *Shelbourne KD, Davis TJ, Klootnyk TE.* The Relationship between intercondylar notch width of the femur and the incidence of anterior cruciate ligament tears. *Am J Sports Med* 1998; 26(3): 402–8.
8. *Davis TJ, Shelbourne KD, Klootnyk TE.* Correlation of the intercondylar notch width of the femur to the width of the anterior and posterior cruciate ligaments. *Knee Surg Sports Traumat Arthrosc* 1999; 7(4): 209–14.
9. *Muneta T, Takakuda K, Yamamoto H.* Intercondylar notch width and its relation to the configuration and cross-sectional area of the anterior cruciate ligament. A cadaveric knee study. *Am J Sports Med* 1997; 25(1): 69–72.
10. *Edwards A, Bull AMJ, Amis AA.* The attachments of the anteromedial and posterolateral fiber bundles of the anterior cruciate ligament. Part 1: Tibial attachment. *Knee Surg Sports Traumat Arthrosc* 2007; 15(12): 1414–21.
11. *Edwards A, Bull AMJ, Amis AA.* The attachments of the anteromedial and posterolateral fiber bundles of the anterior cruciate ligament. Part 2: Femoral attachment. *Knee Surg Sports Traumat Arthrosc* 2008; 16(1): 29–36.
12. *Girgis FG, Marshall JL, Al Monajem A.* The cruciate ligaments of the knee joint: anatomical, functional and experimental analysis. *Clin Orthop Relat Res* 1975; 106: 216–31.
13. *Iwabashi T, Shino K, Nakata K, Nakamura N, Yamada Y, Yoshikawa H, et al.* Assessment of the "functional length" of the three bundles of the anterior cruciate ligament. *Knee Surg Sports Traumat Arthrosc* 2008; 16(2): 167–74.
14. *Bradley J, Fitzpatrick D, Daniel D, Sbercliff T, O'Connor J.* The evaluation of cruciate ligament orientation in the sagittal plane - a method of predicting length changes vs. knee flexion. *J Bone Joint Surg (Br)* 1988; 70B: 94–9.
15. *Odensten M, Gillquist J.* Functional anatomy of the anterior cruciate ligament and a rationale for reconstruction. *J Bone Joint Surg (Am)* 1985; 67(2): 257–62.
16. *Anderson AF, Anderson CN, Gorman TM, Cross MB, Spindler KP.* Radiographic measurements of the intercondylar notch: Are they accurate. *Arthroscopy* 2007; 23(3): 261–8, 268.e1–2.
17. *Lund-Hanssen H, Gannon J, Engebretsen L, Holen KJ, Anda S, Vatten L.* Intercondylar notch width and the risk for anterior cruciate ligament rupture: a case control study in 46 female handball players. *Acta Orthop Scand* 1994; 65(5): 529–32.
18. *Lombardo S, Sethi PM, Starkey C.* Intercondylar notch stenosis is not a risk factor for anterior cruciate ligament tears in professional male basketball players: an 11-year prospective study. *Am J Sports Med* 2005; 33(1): 29–34.
19. *Good L, Odensten M, Gillquist J.* Intercondylar notch measurements with special reference to anterior cruciate ligament surgery. *Clin Orthop Relat Res* 1991; 263: 185–9.
20. *Dienst M, Schneider G, Altmeyer K, Voelkerling K, Georg T, Kramann B, et al.* Correlation of intercondylar notch cross section to the LCA size: a high resolution MT tomographic in vivo analysis. *Arch Orthop Trauma Surg* 2007; 127(4): 253–60.
21. *Stäubli HU, Adam O, Becker W, Burgkart R.* Anterior cruciate ligament and intercondylar notch in the coronal oblique plane: anatomy complemented by magnetic resonance imaging in cruciate ligament-intact knees. *Arthroscopy* 1999; 15(4): 349–59.
22. *Stijak L, Radonjić V, Nikolic V, Blagojević Z, Aksić M, Filipović B.* Correlation between the morphometric parameters of the anterior cruciate ligament and the intercondylar width gender and age differences. *Knee Surg Sports Traumatol Arthrosc* 2009; 17(7): 812–7.
23. *Papachristou G, Sourlas J, Magnissalis E, Plessas S, Papachristou K.* ACL reconstruction and the implication of its tibial attachment for stability of the joint: anthropometric and biomechanical study. *Int Orthop* 2007; 31(4): 465–70.
24. *Stäubli HU, Rauschnig W.* Tibial attachment area of the anterior cruciate ligament in the extended knee position. *Knee Surg Sports Traumat Arthrosc* 1994; 2(3): 138–46.

Received on September 5, 2012.
Accepted on December 14, 2012.