



## Long-term outcome of strabismus and ptosis surgery in a mother and daughter with congenital fibrosis of extraocular muscles

Dugotrajni ishod hirurškog lečenja strabizma i ptoze zbog kongenitalne fibroze ekstraokularnih mišića kod majke i ćerke

Branislav Stanković\*, Milenko Stojković\*, Gordana Vlajković†, Ivana Zdravković‡, Dušica Risović§

Clinical Center of Serbia, \*Institute of Ophthalmology, †Institute of Anaesthesiology, ‡Institute of Neurosurgery, Clinical Center Zvezdara, §Ophthalmology Clinic, Belgrade

### Abstract

**Background.** Congenital fibrosis of extraocular muscles (CFEOM) is a very rare congenital condition, characterized by variable amounts of restriction of the extraocular muscles, with or without ptosis. The aim of this report was to describe a severe, atypical, exposure-induced corneal stromal lysis in two patients. **Case report.** A mother and a daughter with a severe CFEOM were presented. The surgery of both extraocular muscles and ptosis led to a fair outcome in mother even 30 years after, and a very good outcome in daughter 4 years after the treatment. **Conclusion.** Though frequently challenging and disappointing the outcome of surgery of both extraocular muscles and ptosis in CFEOM can be favorable even in rather severe cases. To the best of our knowledge, the atypical keratolysis we described has not been highlighted in the literature on CFEOM so far.

**Key words:** blepharoptosis; strabismus; abnormalities; parents; child; ophthalmologic surgical procedures.

### Apstrakt

**Uvod.** Kongenitalna fibroza ekstraokularnih mišića (CFEOM) vrlo je retko kongenitalno oboljenje, karakterisano različitim stepenom restrikcije ekstraokularnih mišića, prisustvom ili odsustvom ptoze. **Prikaz slučaja.** Prikazani su majka i ćerka sa teškim oblikom CFEOM. Hirurški zahvat na ekstraokularnim mišićima i operacija ptoze dali su dobre rezultate, koji su se kod majke održali čak 30 godina, a kod ćerke je rezultat vrlo dobar i četiri godine posle hirurškog lečenja. Opisano je, na rožnjači majke, atipično područje izrazite lize strome usled lagoftalmusa. **Zaključak.** Mada je često izazovna i razočaravajuća, hirurgija ekstraokularnih mišića i ptoze kod CFEOM može da bude uspešna i kod veoma teških slučajeva. Koliko nam je poznato, atipična keratoliza koju smo opisali nije do sada istaknuta u literaturi.

**Ključne reči:** blefaroptoza; strabizam; anomalije; roditelji; deca; hirurgija, optalmološka, procedure.

### Introduction

The congenital fibrosis syndrome is a rare inherited subset of monogenic isolated syndromes of strabism that it presented as nonprogressive restrictive ophthalmoplegia, and that includes classic and atypical forms of congenital fibrosis of the extraocular muscles (CFEOM) and Duane syndrome. The syndrome was originally described by Baumgarten<sup>1</sup> in 1840. In 1879 Heuk<sup>2</sup> showed on a postmortem examination an abnormal insertion and replacement of the extraocular muscles with fibrous tissue. It has been traditionally regarded as a primary eye muscle disease. Recent neuropathologic studies have indicated that these disorders may be the result of a primary neuropathy caused by the maldevelopment of

oculomotor, trochlear and abducens cranial nerve nuclei, with secondary myopathic changes<sup>3,4</sup>.

CFEOM is, in most cases, an autosomal dominant congenital condition<sup>5</sup> characterized by the variable amounts of restriction of the extraocular muscles, with or without ptosis. CFEOM has been previously divided into several clinical entities: general fibrosis syndrome, congenital fibrosis of the inferior muscle, strabismus fixus, vertical retraction syndrome and congenital unilateral fibrosis. Several types of presentation of the CFEOM within one family have suggested that these are the variants of the same condition<sup>6</sup>.

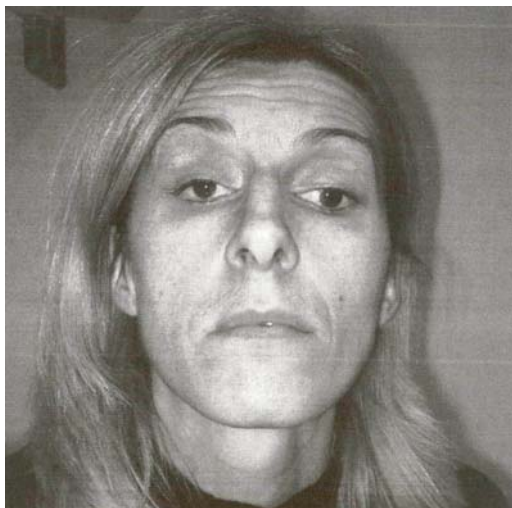Surgical treatment of patients with CFEOM is challenging<sup>5</sup>, frequently disappointing, and most patients appreciate any, even a minimal improvement<sup>7</sup>. Binocular vision is

rarely attained postoperatively, even with a good surgical result, and a repeated surgery is often necessary if a significant amount of residual deviation gradually develops after surgical intervention<sup>8,9</sup>.

We present the clinical and long-term surgical outcome of a mother and a daughter with a severe CFEOM.

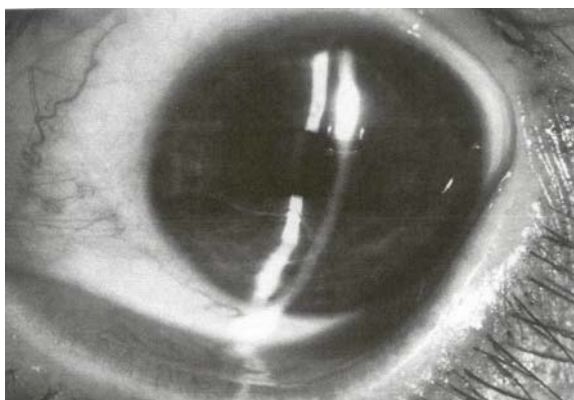
### Case report

*Case 1* – a 38-year-old woman with strabismus and bilateral ptosis which had caused a moderate chin elevation (Figure 1), otherwise healthy, was referred for the evaluation



**Fig. 1** – Thirty years after the surgery

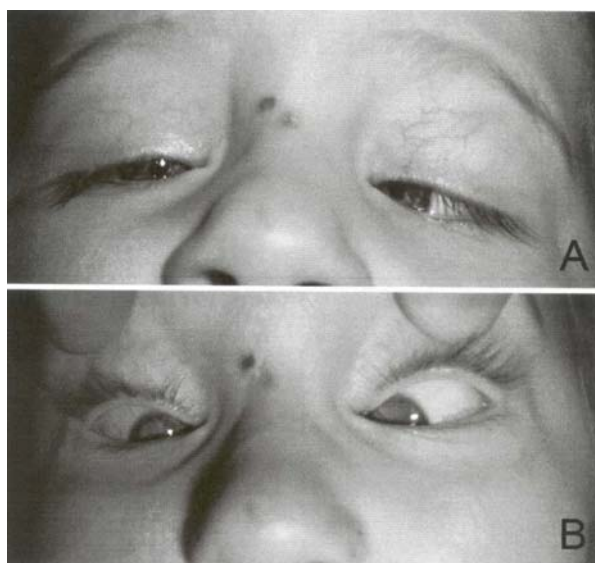
of her daughter with a similar appearance she used to have in infancy. The mother had undergone multiple squint and ptosis surgeries 30 years ago. No documentation on the treatment was available. The best (spectacle) corrected visual acuity was 0.6 and 0.1 in the right and in the left eye, respectively. She had rather unusual, mainly horizontal areas, of stromal thinning with a minimal scar formation and a minimal superficial punctate keratopathy, i.e. a form of trophic stromal lysis due to exposure, in the inferior third of both corneas (Figure 2). Surprisingly, these areas of stromal lysis devel-



**Fig. 2** – Deep, irregularly shaped, mainly horizontal, area of stromal lysis due to exposure, with minimal scarring in nasal angle of the lesion and minimal superficial punctate keratopathy, in the inferior third of the cornea of the left eye in mother

ped without any symptoms of irritation. However, a gradual decrease in visual acuity occurred because of developing astigmatism. An extremely high mixed oblique astigmatism was measured: in the right eye (RE) +2.0 DSph et - 5.0 Dcyl/23°, and in the left eye (LE) +4.0 DSph et -8.25 Dcyl/10°, which followed the extent of corneal thinning in favour of the LE. In anomalous head posture (AHP) there was a 20 prism diopters (PD) left exotropia (XT) with 25 PD hypotropia and amblyopia from the childhood. Elevation was absent in addition to the marked reduction of eye movement in both eyes except abduction, with an increasing vertical deviation of vertical side gaze and convergence of attempted upgaze. She refused additional surgery. Artificial tears and safety polycarbonate glasses were recommended.

*Case 2* – a healthy 12-month-old girl with extreme torticollis and both eyes fixed in extreme downward and inward position (Figure 3), had undergone augmented bilateral me-



**Fig. 3 A and B** – Extreme torticollis. Position of the eyes under general anesthesia

dial and inferior rectus recession one month after the presentation. A passive duction testing under general anesthesia revealed a severely limited elevation and abduction in the RE and severely limited elevation and moderately limited abduction in the LE. The medial rectus muscle had the course upward to the insertion, suggesting a lower origin in the orbit. Trying to avoid convergence on upgaze we decided to use graded hang back recession: OD 12.0 lower margin /14.5 upper margin; OS 11.0 lower margin /13.5 upper margin, measured from the limbus. For inferior rectus recession we have done “super maximum” hang back recession of 10.0 mm measured from the insertion with recession of conjunctiva and tenon’s capsule. Postoperatively, she developed an immediate large right consecutive XT and small hypotropia. Subsequently, 10 days later she underwent 2.5 mm medial rectus and 2 mm inferior rectus anteposition and bilateral slightly undercorrected brow suspension with polyamide suborbicular pentagon suture according to Fox. Associated high hyperopia was corrected with the appropriate glasses and a part time patching of the LE was instituted. Four years

after the surgery (Figure 4) she assumed a nearly normal head posture with residual small right exotropia of 5 PD and 7 PD of hypotropia. Elevation was also absent, eye movements limited, particularly adduction and more RE, but the upward convergence seemed unnoticeable. With prolonged treatment with artificial tears (0.3% preservative free HPMC sid and HPMC 2% once at bedtime) after the ptosis surgery her corneas are tolerating the exposure well, with just a mild occasional superficial punctate keratopathy of RE, without the signs of stromal lysis or scar formation in the cornea.

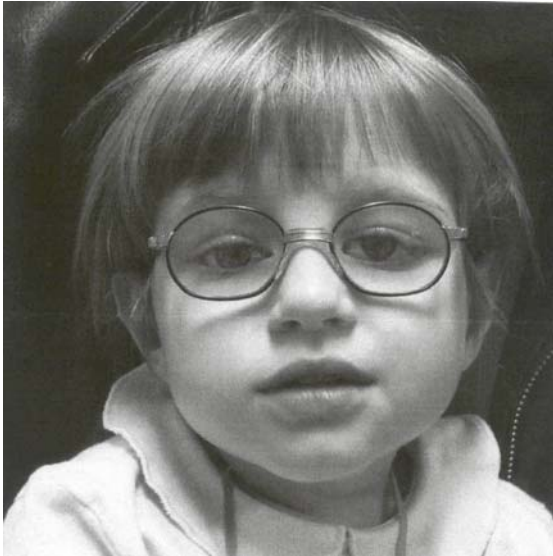

Fig. 4 – Four years after the surgery

### Discussion

The treatment of CFEOM is primarily surgical and aimed at relieving of uncomfortable head position, the reduction of ptosis, and/or the elimination or reduction of significant misalignment of the eyes<sup>8</sup>. Unfortunately, nothing could be done to correct the absence of eye movements<sup>10</sup>. In general, the less severe the fibrosis, the better the result of surgery<sup>7</sup>. Boergen<sup>11</sup> reported a large series of CFEOM patients in which an aggressive surgical approach led to good clinical results.

The surgery of both extraocular muscles and ptosis gave fair results in the mother even 30 years after, and very

good results in the daughter 4 years after the treatment. An extreme torticollis is certainly the condition that should be alleviated and a treatment not postponed unnecessarily. When considering augmented surgery on medial rectus muscles for children less than 2 years of age, cautious approach must be used even in cases with a large deviation and extreme restrictions. Early ante-position of recessed inferior rectus muscle was probably unnecessary, as even new smaller amount acted as disinsertion, which is, otherwise, a standard approach. Amblyopia can be successfully treated when recognized early. An appropriate optical correction where significant refractive errors are present as well as amblyopia monitoring is needed. To prevent exposure keratopathy and a more serious damage to the cornea, even with mandatory slight undercorrection in brow suspension procedure, close follow-up and treatment with artificial tears and gel or ointment before sleep when needed is obligatory. Although advocated for six months postoperatively it may be a lifelong need in some patients and is sometimes much desired, as exemplified in our case of corneal stromal lysis, despite the apparent lack of symptoms. In patients in whom exposure keratopathy with severe stromal thinning has developed, glasses with polycarbonate lenses to prevent possible perforation of thinned cornea even after a minor blunt trauma to the eye, are recommended.

Despite numerous accounts of postoperative superficial keratopathy and scar formation<sup>5, 6, 10</sup>, to the best of our knowledge, our patient is rather unique in respect to the finding of large areas of deep stromal lysis with almost intact epithelium and minimal peripheral scar formation, both in terms of area and density. This being more so because no symptoms apart from gradually decreasing uncorrected visual acuity were reported by the patient. Although this finding is rather unusual according to the literature (though it may be “hidden” within a set of patients in whom scar formation with no further detail was described) it is not entirely surprising in a setting in which scar formation, albeit in a different tissue, is the pathologic basis of clinical manifestations of the disease. It is tempting to regard corneal thinning in our case as a manifestation of the tendency of corneal tissue to form rather hypotrophic scars or no scars at all in response to chronic trophic stromal lysis due to exposure. This seemingly adds to the spectrum of corneal alterations in CFEOM.

### R E F E R E N C E S

1. Baumgarten M. Erfahrungen über den Strabismus und die uskeldurchschneidung am Auge in physiologisch – pathologischer und therapeutischer Beziehung. *Monatsschr Med Augenheilkd Chir* 1840; 3: 473–99. Available from: [http://: www.citebase.org/cgi-bin/citations?id=oai:pubmed-central.gov:100320](http://www.citebase.org/cgi-bin/citations?id=oai:pubmed-central.gov:100320)
2. Henk G. Ueber angeborenen veterbten Beweglichkeits-Defekts der Augen. *Klin Monatsbl Augenheilkd* 1879; 17: 253–78. (German)
3. Nakano M, Yamada K, Fain J, Sener EC, Selleck CJ, Awad AH, et al. Homozygous mutations in AR1X(PHOX2A) result in congenital fibrosis of the extraocular muscles type 2. *Nat Genet* 2001; 29(3): 315–20.
4. Flaberty MP, Grattan-Smith P, Steinberg A, Jamieson R, Engle EC. Congenital fibrosis of the extraocular muscles associated with cortical dysplasia and maldevelopment of the basal ganglia. *Ophthalmology* 2001; 108(7): 1313–22.
5. Yazdani A, Traboulsi EI. Classification and surgical management of patients with familial and sporadic forms of congenital fibrosis of the extraocular muscles. *Ophthalmology* 2004; 111(5): 1035–42.
6. Reck AC, Manners R, Hatchwell E. Phenotypic heterogeneity may occur in congenital fibrosis of the extraocular muscles. *Br J Ophthalmol* 1998; 82(6): 676–9.

7. *Helveston EM*. Surgical management of strabismus. In: *Von Norden, Bunter K*, editors. An atlas of strabismus surgery. 4th ed. St. Louis: Mosby; 1993. p. 518–19.
8. *Traboulsi EI, Jaafar MS, Kattan H, Parks MM*. Congenital fibrosis of the extraocular muscles: Report of 24 cases illustrating the clinical spectrum and surgical management. *Am Orthopt J* 1993; 43: 45–53.
9. *Apt L, Axelrod RN*. Generalized fibrosis of the extraocular muscles. *Am J Ophthalmol* 1978; 85(6): 822–9.
10. *Magli A, de Berardinis T, D'Esposito F, Gagliardi V*. Clinical and surgical data of affected members of a classic CFEOM I family. *BMC Ophthalmol* 2003; 3: 6.
11. *Boergen P*. Congenital fibrosis of extraocular muscles. In: *Kaufman H*, editor. Proceedings of 18th European Strabismological Association Congress; 1989; Krakow. p. 55–9.
12. *Noorden GK von, Campos EC*. Special forms of strabismus. In: *Noorden GK von, Campos EC*, editors. Binocular vision and ocular motility: Theory and management of strabismus. 6th ed. St Luis: Cv Mosby; 2002. p. 474–6.

The peper was received on April 3, 2006.