

# Imunohistološke karakteristike mioepitelnih ćelija pomoću monoklonskih antitela

DOI: 10.2298/SGS0801007D

## Immunohistological characterization of myoepithelial cells using monoclonal antibodies

Ivan Dožić<sup>1</sup>, Miodrag Čolić<sup>2</sup><sup>1</sup> Institut za Opštu i oralnu Biohemiju, Stomatološki fakultet, Beograd<sup>2</sup> Institut za medicinska istraživanja, VMA, Beograd<sup>1</sup> Institute for oral biochemistry, School of Dentistry, Belgrade<sup>2</sup> Institute for Medical investigation, VMA, BelgradeORIGINALNI RAD (OR)  
ORIGINAL ARTICLE

### KRATAK SADRŽAJ

**Cilj** ovog rada je bio da se ispita ekspresija monoklonskih antitela (mAt) u mioepitelnim ćelijama podvilične pljuvačne žlezde (PPŽ) pacova tokom postnatalnog razvoja.

**Materijal i metode:** Istraživanja su rađena na pacovima soja AO, muškog pola, starosti 1, 30, 60 dana. Korišćena je imunohistohemijska metoda streptavidin-biotin peroksidazno bojenje. Kriostatski preseki su fiksirani u acetonu, inkubirani su sa mAt specifičnim za polipeptide citokeratina (CK) (CK7, CK8, CK18, CK bubrega, K8.12, K8.13), epitel pacova (PT13D11), kolagen pacova (RMC-23), laminin ( $\alpha\beta 1$ ) i sialoadhezin pacova (ED3).

**Rezultati:** Dobijeni rezultati ove imunohistohemijske analize su pokazali fenotipsku heterogenost mioepitelnih ćelija tokom postnatalnog razvoja. Mioepitelne ćelije oko acinusa bile su reaktivne sa mAt K8.13, PT13D11 i ED3, dok su pokazale negativnu reakciju sa CK7, CK8, CK18, CK-bubrega, RMC-23 i  $\alpha\beta 1$  mAt. Kod odraslih životinja (60 dana), mioepitelne ćelije oko ekskretornih kanala su bile obojene sa K8.12 mAt.

**Zaključak:** Ovi rezultati pokazuju fenotipsku heterogenost mioepitelnih ćelija i mogu biti korisni za razumevanje razvoja i funkcije ovih ćelija.

**Gljučne reči:** mioepitelne ćelije, podvilična pljuvačna žlezda, monoklonska antitela, ontogeneza

### SUMMARY

**Aim:** The aim of this study was to investigate the expression of monoclonal antibody (mAbs) in the myoepithelial cells of the rat submandibular salivary glands (SSG) during postnatal development.

**Material and method:** SSG were obtained from 1, 30 and 60 days old, male, AO rats. Streptavidin-biotin immunoperoxidase method was used for immunohistochemistry. Cryostat sections were fixed in acetone and incubated with mAbs which specifically reacts with cytokeratins (CK) polypeptides (CK7, CK8, CK18, CK kidney, K8.12, K8.13), rats epithelial (PT13D11), rats collagen (RMC-23), laminin ( $\alpha\beta 1$ ) and rats sialoadhesin (ED3).

**Results:** Immunohistochemical analysis of the myoepithelial cells showed phenotypic heterogeneity during the postnatal development. Myoepithelial cells of acini were stained by K8.13, PT13D11 and ED3 mAbs, whereas these cells were not stained by mAbs CK7, CK8, CK18, CK-kidney, RMC-23 and  $\alpha\beta 1$ . In adult rats, myoepithelial cells of excretory duct were stained by K8.12 mAb.

**Conclusion:** The obtained results show phenotypic heterogeneity of myoepithelial cells and might also be useful to further understanding of myoepithelial cells development and functions.

**Key words:** myoepithelial cells, submandibular salivary glands, monoclonal antibody, ontogenesis

## Uvod

Mioepitelne ćelije (MĆ) predstavljaju značajnu komponentu histofiziološke strukture egzokrinih žlezda. One se nalaze između bazalne membrane i epitelnih ćelija. U pljuvačnim žlezdama, MĆ imaju različit oblik u zavisnosti od lokalizacije. Oko acinusa MĆ imaju zvezdast oblik, dok su oko interkalatnih kanala ove ćelije vretenastog oblika<sup>1</sup>. Korisne informacije o MĆ pljuvačnih žlezda su uglavnom dobijene imunohistohemijskim tehnikama, pomoću specifičnih antitela. U mnogim radovima je dokazana reaktivnost MĆ sa antitelima specifičnim za kontraktilne proteine kao što su aktin, miozin, kalponin, kaldezmon<sup>2-7</sup>. Ovi proteini su specifični markeri diferencijacije glatkih mišićnih ćelija. Sličnost u citodiferencijaciji sa glatkim mišićnim ćelijama ukazuje da MĆ imaju ulogu u kontrakciji i da učestvuju u sekreciji pljuvačke<sup>8,9</sup>. MĆ sadrže i citokeratinske (CK) intermedijarne filamente koji su prepoznatljivi markeri epitelnih ćelija. Imunohistohemijskim analizama dokazani su CK14, CK5, CK17 u MĆ humanih pljuvačnih žlezda<sup>6,10-12</sup>, dok je CK 14 dokazan u istim ćelijama pljuvačnih žlezda pacova<sup>3</sup>. Ekspresija svih ovih različitih proteina u MĆ ukazuje na njihovu heterogenost jer poseduju imunofenotipske karakteristike epitelnih i glatkih mišićnih ćelija. Komparativna analiza ekspresije različitih markera u MĆ pljuvačnih žlezda je od posebnog interesa za dobro razumevanje histogeneze ovih ćelija ne samo u fiziološkim već i u različitim patološkim stanjima.

Cilj ovog rada je bio da se ispituju imunofenotipske karakteristike MĆ na podviličnoj pljuvačnoj žlezdi (PPŽ) pacova u toku postnatalnog razvoja, pomoću monoklonskih antitela specifični za polipeptide CK, komponente ekstraćelijskog matriksa i adhezione molekule.

## Materijal i metode

Kao biološki materijal u ovoj studiji korišćena je podvilična pljuvačna žlezda uzimana od pacova soja AO (Albino Oxford), muškog pola, starosti 1, 30, i 60 dana. Pacovi su žrtvovani etarskom inhalacionom anestezijom. Preseci tkiva, debljine 5-6  $\mu\text{m}$ , sušeni su na sobnoj temperaturi 2-3 sata ili su ostavljani u frižideru preko noći. Nakon toga fiksirani su u acetonu tokom 10 min.

U ovom radu su korišćena primarna monoklonska antitela čije su specifičnosti, izotipovi, razblaženja i proizvođači prikazani u tabeli 1.

Sekundarna antitela su imunoglobulini kože ili ovce protiv mišjeg imunoglobulina. Antitela su konjugovana biotinom (Dakopats). Streptavidin-konjugovan peroksidom je takođe dobijen od Dakopats-a.

## Introduction

Myoepithelial cells (MC) are an important component of the histophysiological structure of exocrine glands. They are localized between the basal membrane and epithelial cells. MCs have different shapes depending on the localization. MCs are star-shaped around acini and spindle-shaped around intercalated ducts.<sup>1</sup> Useful information about salivary gland MCs has been obtained using immunohistochemical techniques and specific antibodies. Numerous papers have presented the reactivity of MCs with antibodies specific to contractile proteins such as actin, myosin, calponin, caldesmon.<sup>2-7</sup> These proteins are specific markers of smooth muscle cell differentiation. The similarity with cyto-differentiation with smooth muscle cells implies that MCs have a role in contraction and salivary secretion.<sup>8,9</sup> MCs contain cytokeratin (CK) intermediary filaments which are known markers of epithelial cells. Immunohistochemical analyses have confirmed CK14, CK5, CK17 in MCs of human salivary glands<sup>6,10-12</sup> whereas CK 14 has been confirmed in the same cells of rat salivary glands.<sup>3</sup> The expression of all these proteins in MCs point out to their heterogeneity as MCs possess immunophenotypic characteristics of epithelial and smooth muscle cells. Comparative analysis of the expression of various markers in salivary gland MCs is of great importance for understanding the histogenesis of these cells in physiological and pathological conditions.

The aim of this study was to investigate the immunophenotypic characteristics of MCs of the rat submandibular salivary glands (SSG) during postnatal development using monoclonal antibodies specific to CK polypeptides, components of extracellular matrix and adhesion molecules.

## Materials and methods

As biological material used in the present study, submandibular salivary glands were taken from AO, male rats 1, 30 and 60 days old. The rats were sacrificed using ether inhalation anesthetics. Tissue sections, 5-6  $\mu\text{m}$  thick, were dried at room temperature for 2-3 h or left in the fridge over night. Afterwards, the sections were fixed in acetone for 10 min.

The specific characteristics, isotypes, solutions and manufactures of the primary monoclonal antibodies used in the present study are given in Table 1.

Secondary antibodies against the rat immunoglobulin were goat or sheep immunoglobulin. The antibodies were conjugated with biotin (Dakopats). Streptavidin conjugated with peroxidase was also obtained from Dakopats.

Imunohistohemijska ispitivanja su obuhvatila Streptavidin-biotin peroksidazno bojenje. Kriostatski preseki tkiva PPŽ koji su bili fiksirani u acetonu, inkubirani su sa po 20 $\mu$ l primarnog mAb odgovarajućeg razblaženja (tabela 1) u TBS (tris-buffered saline), u vlažnoj komori 60 min. Zatim su tkivni preseki isprani u TBS 10min., posle čega je blokirana endogena peroksidaza sa 3% vodonik peroksidom u metanolu, 20 min.

Na preseke tkiva je naneto 20-30 $\mu$ l sekundarnog antitela konjugovanog biotinom u razblaženju 1:50. Preseci su inkubirani u vlažnoj komori 30 min. na sobnoj temperaturi. Kako su pločice isprane u TBS naneto je po 20 $\mu$ l streptavidina konjugovanog peroksidazom u razblaženju 1:50, i ostavljene su 30 min. na sobnoj temperaturi. Ispiranjem u TBS nanošen je supstrat DAB (3'3' diaminobenzedim tetrahidrochlorid) na pločice u trajanju 5-15 min, kada je došlo do razvoja citochemijske reakcije. Preparati su kontrastirani rastvorom hematoksilina i montirani Kajzerovim gelom. Analiza obojenih preparata je vršena svetlosnim mikroskopom. Negativna kontrola je dobijena zamenom primarnog antitela sa rastvorom TBS-a.

U ovom radu su korišćena monoklonska antitela koja prepoznaju citokeratine (CK7, CK8, CK18, K8.12, K8.13, CK-bubrega), epitel pacova (PT13D11), sijaloadhezin pacova (ED3) i neke od komponenti vanćelijskog matriksa kolagen (RMC-23) i laminin ( $\alpha_6\beta_1$ ) na PPŽ pacova. Imunohistološke karakteristike ove žlezde su proučavane na životinjama 1, 30 i 60 dana tokom postnatalnog razvoja. Zadnji termin istovremeno označava i polnu zrelost životinje. Analiza je urađena na svetlosnom mikroskopu firme Olympus. Intenzitet citochemijske reakcije je gradiran od 1 do 4 (- = negativno bojenje, 1+ = slabo bojenje, 2+ = umereno bojenje, 3+ = snažno bojenje, 4+ = izrazito snažno bojenje). Broj pozitivnih ćelija analiziran je semikvantitativno na sledeći način: a = 10-20% pozitivnih ćelija, b=30-50% pozitivnih ćelija, c = većina pozitivnih ćelija.

Immunohistochemical analysis comprised Streptavidin-biotin peroxidase staining. The cryostat sections of SSG, that were fixed in acetone, were incubated with 20  $\mu$ l of appropriately diluted primary mAb (Table 1) in TBS (tris-buffered saline) in a humid chamber for 60 min. Afterwards, the tissue sections were rinsed in TBS for 10 min, and endogenous peroxidase was blocked using 3% hydrogen peroxide in methanol, for 20 min.

Tissue sections were subjected to 20-30  $\mu$ l of secondary antibodies conjugated with 1:50 solution of biotin. The sections were incubated in a humid chamber for 30 min at room temperature. After the discs had been rinsed in TBS, 20  $\mu$ l of 1:50 solution of streptavidin conjugated with peroxidase was applied and left for 30 min at room temperature. After rinsing in TBS, the DAB (3'3' diaminobenzedim tetrachloride) substrate was applied to the discs for 5-15 min and the cytochemical reaction occurred. The specimens were counterstained with hematoxylin and mounted in Kaiser gel. The analysis of the stained specimens was done using a light microscope. Negative control was created by switching the primary antibody with TBS solution.

The monoclonal antibodies specific to cytokeratins (CK7, CK8, CK18, CK kidney, K8.12, K8.13), rat epithelium (PT13D11), sialoadhesin (ED3) and certain components of extracellular matrix - collagen (RMC-23) and laminin ( $\alpha_6\beta_1$ ) of rat SSG, were used in the present study. Immunohistological characteristics of this gland were studied in animals at 1, 30 and 60 days of their postnatal development. At the same time, the last term marks animal sexual maturity. The analysis was performed using the Olympus light microscope. The intensity of the cytochemical reaction was scored 1 - 4 (- = negative staining, 1+ = weak staining, 2+ = moderate staining, 3+ = strong staining, 4+ = very strong staining). The number of positive cells was analyzed semi quantitatively as follows: a = 10-20% positive cells, b = 30-50% positive cells, c = the majority of positive cells.

**Tabela 1:** Specifične karakteristike primarnih monoklonskih antitela

**Table 1:** Characteristics and specificities of monoclonal antibodies

monoklonska antitela	polipeptidi CK	izotip	razblaženje	proizvođač
CK7	CK7	IgG1	1:100	Sigma
CK8	CK8	IgG1	1:100	Sigma
CK18	CK18	IgG1	1:100	Sigma
K8.12	CK13,16	IgG1	1:50	ICN
K8.13	CK1,5-8,10,11,18	IgG2a	1:50	ICN
PT13D11	epitel pacova	IgM	1:150	*
RMC-23	kolagen pacova	IgG1	1:150	*
$\alpha_6\beta_1$	receptor za laminin	IgG1	1:50	Biosource
CK bubrega	CK bubrega (CK7?)	IgG2a	1:10	Amersham
ED3	sijaloadhezin	IgG1	1:25	Serotek

\* antitela proizvedena u Institutu za medicinska istraživanja VMA

## Rezultati

Ova imunohistochemijska studija ukazuje na različitu reaktivnost MĆ PPŽ pacova sa panelom monoklonskih antitela u toku postnatalnog razvoja (tabela 2).

## Results

The present immunohistochemical study has suggested diverse reactivity of MCs in rat SSG with a wide range of monoclonal antibodies during postnatal development (Table 2).

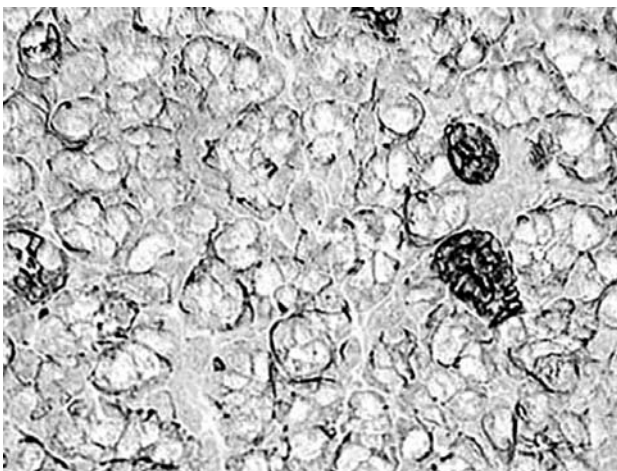
STRUKTURNI ELEMENTI	CK7 ontogeneza (dani)			CK8 ontogeneza (dani)			CK18 ontogeneza (dani)			CK bubrega ontogeneza (dani)			K8.13 ontogeneza (dani)			K8.12 ontogeneza (dani)			PT13D11 ontogeneza (dani)			RMC-23 ontogeneza (dani)			$\alpha_6\beta_1$ ontogeneza (dani)			ED3 ontogeneza (dani)					
	1	30	60	1	30	60	1	30	60	1	30	60	1	30	60	1	30	60	1	30	60	1	30	60	1	30	60	1	30	60			
ACINUS mioepitelne ćelije (Mukozni) (Serozni)	-	-	-	-	-	-	-	-	-	-	-	-	4+(b)	4+(c)	4+(c)	-	-	-	4+(b)	4+(c)	4+(c)	-	-	-	-	-	-	-	-	-	4+(b)	4+(c)	4+(c)
	-	-	-	-	-	-	-	-	-	-	-	-	4+(a)	4+(b)	4+(c)	-	-	-	4+(a)	4+(b)	4+(b)	-	-	-	-	-	-	-	-	-	-	-	-
UMETNUTI KANALI mioepitelne ćelije	-	-	-	-	-	-	-	-	-	-	-	-	-	-	-	-	-	-	-	-	-	-	-	-	-	-	-	-	-	-	-	-	-
PRUGASTI KANALI mioepitelne ćelije	-	-	-	-	-	-	-	-	-	-	-	-	-	-	-	-	-	-	-	-	-	-	-	-	-	-	-	-	-	-	3+(a)	2+(a)	2+(a)
EKSKRETORNI KANALI mioepitelne ćelije	-	-	-	-	-	-	-	-	-	-	-	-	4+(c)	4+(c)	4+(c)	4+(c)	4+(c)	4+(c)	-	-	-	-	-	-	-	-	-	-	-	-	4+(a)	4+(b)	4+(b)

LEGENDA : - = negativno bojenje, 1+ = slabo bojenje, 2+ = umereno bojenje, 3+ = snažno bojenje, 4+ = izrazito snažno bojenje, a = 10-20% pozitivnih ćelija, b = 30-50% pozitivnih ćelija, c = većina pozitivnih ćelija.

LEGEND: - = negative staining; 1+ = weak staining; 2+ = moderate staining; 3+ = strong staining; 4+ = very strong staining; a = 10-20% positive cells; b = 30-50% positive cells; c = majority of cells positive.

K8.13 mAt je reagovalo sa MĆ PPŽ. Uočena je izrazito snažna konstantna pozitivnost ovih ćelija oko ekskretornih kanala u toku ontogeneze za razliku od MĆ oko prugastih kanala koje su K8.13-. Međutim, MĆ oko acinusa imaju različitu reaktivnost sa ovim mAt. Kod adultnih životinja (60 dana) MĆ kako seroznih tako i mukoznih acinusa su K8.13+,

K8.13 mAb reacted with SSG MC. An extreme and constant positive reaction was observed in these cells around excretory ducts during ontogenesis in contrast to MCs around stripe ducts which were K8.13-. However, the acini MCs had different reactivity with the same mAb. In adult animals (60 days old), MCs around both serous and mucous acini were K8.13+



Slika 1: K8.13 mAt reaguje sa mioepitelnim ćelijama oko acinusa (60 dana). Streptavidin-biotin peroksidazno bojenje x 10

Figure 1. K8.13 mAb reacted with myoepithelial cells around acini (60 days), Streptavidin-biotin immunoperoxidase staining. x 10

za razliku od MĆ seroznih acinusa neonatalnih životinja koje su jedva prisutne. Broj ovih ćelija se u kasnijem ontogenetskom razvoju povećavao tako da je 30-og dana detektovano oko 30-50% pozitivnih ćelija upoređujući sa adultnim životinjama. Takođe i MĆ oko mukoznih acinusa nisu na rođenju sve pozitivne već oko 50% u odnosu na adultne životinje i njihov broj se progresivno povećavao do 30 dana.

**K8.12** mAt izrazito snažno boji MĆ oko ekskretornih kanala PPŽ. Ova prebojenost je konstantna tokom celog postnatalnog perioda. Za razliku od njih, MĆ oko acinusa su pokazale negativnu reakciju sa ovim antitelom.

**PT13D11** mAt detektuje epitel pacova. Imunoreaktivnost sa ovim mAt pokazivale su MĆ oko acinusa za razliku od MĆ oko izvodnih kanala PPŽ koje su negativne. U neonatalnom periodu, polovina MĆ oko mukoznih acinusa je prebojena u odnosu na adultni period dok su MĆ oko seroznih acinusa bile jedva prisutne u neonatalnom periodu.


**ED3** mAt specifično za pacovski sijaloadhezin je predominantni marker MĆ PPŽ

in contrast to MCs around serous acini in neonatal animals which were barely present. The number of these cells increased during ontogenesis and circa 30-50% positive cells were recorded at day 30 compared to adult animals. Furthermore, not all MCs around mucous acini were positive at birth, but only circa 50% compared to adult animals, but this number progressively increased until day 30.

**K8.12** mAb showed very strong MC staining around excretory ducts in the SSG. This feature was constant during the whole postnatal period. Unlike these, MCs around the acini showed negative reactivity to this antibody.


**PT13D11** mAb detected rat epithelium. Immunoreactivity toward this mAb was observed in acini MCs unlike MC around excretory ducts in the SSG which were negative. In the neonatal period, half of the MCs around mucous acini were stained compared to adulthood whereas MCs around serous acini were barely present during the neonatal period.

**ED3** mAb specific to rat sialoadhesin was a predominant marker for SSG MC



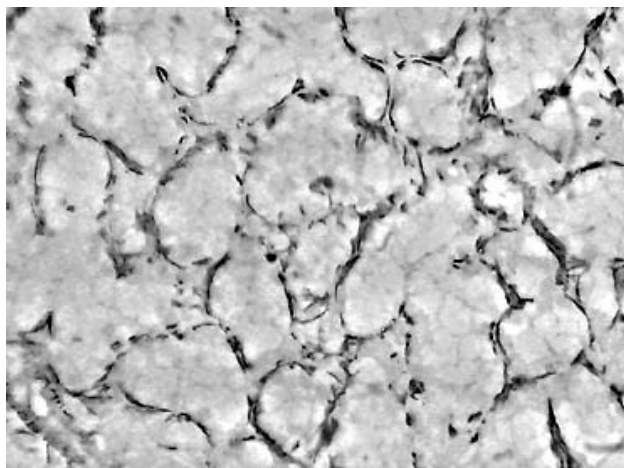
*Slika 2: PT13D11 mAt reaguje sa mioepitelnim ćelijama oko mukoznih acinusa (30 dana). Streptavidin-biotin peroksidazno bojenje x 40*

*Figure 2. PT13D11 mAb reacts with myoepithelial cells of the mucous acini (30 days), Streptavidin-biotin immunoperoxidase staining. x 40*



*Slika 3: PT13D11 mAt reaguje sa mioepitelnim ćelijama oko acinusa (60 dana). Streptavidin-biotin peroksidazno bojenje x 20*

*Figure 3. PT13D11 mAb reacts with myoepithelial cells of the acini (60 days), Streptavidin-biotin immunoperoxidase staining. x 20*



**Slika 4:** ED3 mAb kod adultne zlezde. Najsnažnija imunoreaktivnost u mioepitelnim ćelijama oko acinusa. Streptavidin-biotin peroksidazno bojenje x 20

**Figure 4.** ED3 mAb, at the adult gland. The strongest immunoreactivity in the myoepithelial cells around acini. Streptavidin-biotin immunoperoxidase staining. x 20

Broj snažno prebojenih MĆ oko mukoznih acinusa, kao i kod PT13D11, se povećavao tokom postnatalnog razvoja. Sličnu reaktivnost u adultnom periodu imaju i MĆ oko seroznih acinusa. Broj pozitivnih MĆ oko ekskretornih kanala se povećava u toku ontogeneze, za razliku od MĆ oko prugastih kanala čija se ekspresija smanjuje.

Imunoreaktivnost **CK7, CK8, CK18, CK-bubrega, RMC23 i  $\alpha_6\beta_1$**  mAb nije dokazana sa MĆ na PPŽ pacova u toku ispitivanog razvojnog perioda.

## Diskusija

Mioepitelne ćelije predstavljaju veoma značajnu komponentu histofiziološke strukture pljuvačnih zlezda. Ove ćelije imaju epitelno poreklo jer sadrže keratinske intermedijarne filamente<sup>13</sup>. Do sada je identifikovano najmanje 20 polipeptida citokeratina u epitelnim ćelijama. Podeljeni su u dve grupe kao tip I ili kiseli keratini i tip II ili neutralni-bazni keratini. Citokeratini su u epitelnim ćelijama prisutni u parovima i to po jedan polipeptid iz tipa I i tipa II<sup>14,15</sup>.

U pregledanoj literaturi ima vrlo malo podataka o ekspresiji citokeratinskih polipeptida u MĆ na PPŽ pacova u toku ontogeneze. Ova istraživanja ukazuju da CK 7, 8, 18 i CK bubrega mAb nisu bila reaktivna sa MĆ. Za razliku od ovih rezultata, drugi autori su dokazali prisustvo CK 7,8,17,18,19 u MĆ na humanim pljuvačnim žlezdama<sup>16,17</sup>. Imunoreaktivnost MĆ je bila veoma izražena sa K8.13 mAb specifično za polipeptide CK 1,5-8,10,11,18 i K8.12 mAb specifično za CK par 13/16. U istraživanjima, na pljuvačnim žlezdama čoveka detektovane su MĆ oko acinusa i umetnutih kanala pomoću K8.13 mAb i antitela koja prepoznaju CK 4, 5, 6, 10 i 11<sup>18</sup>. Slične rezultate dobili su Burns i sar.<sup>16</sup> koristeći antitela reaktivna sa CK 10 i 11 kao i sa K8.12 mAb. Međutim ove rezultate nije potvrdio Dardick<sup>19</sup>. Na osnovu rezultata drugih autora MĆ sadrže i CK18<sup>18</sup>, CK7<sup>17</sup>, CK14, CK17<sup>4,6</sup>. Može se zaključiti da se citokeratinski profil MĆ PPŽ pacova razlikuje od citokeratinskog sastava ovih ćelija u drugih vrsta sisara.

The number of strongly stained MCs around mucous acini, as with PT13D11, increased during postnatal development. Similar reactivity in adulthood was seen in MCs around serous acini. The number of MCs around excretory ducts increased during ontogenesis, unlike MCs around stripe ducts which showed decreasing expression.

Immunoreactivity of **CK7, CK8, CK18, CK-kidney, RMC23 and  $\alpha_6\beta_1$**  mAb was not confirmed with SSG MCs in rats during the investigated developmental period.

## Discussion

Myoepithelial cells are an important component of the histophysiological structure of salivary glands. These cells have epithelial origin because they contain keratin intermediary filaments.<sup>13</sup> To date, at least 20 cytokeratin polypeptides have been identified in epithelial cells. They have been classified as type I or acidic keratins and type II or neutral-base keratins. In epithelial cells, cytokeratin are present in pairs, one polypeptide type I and the other type II.<sup>14,15</sup>

The current literature reveals only limited amount of data on cytokeratin polypeptide expression in rat SSG MCs during ontogenesis. The present study has suggested that CK7, 8, 18 and CK-kidney mAb were not reactive with MCs. Unlike the present results, other authors have confirmed the presence of CK 7, 8, 17, 18, 19 in MCs in human salivary glands.<sup>16,17</sup> Immunoreactivity of MCs was very distinctive with K8.13 mAb specific to polypeptides CK1-5, 8, 10, 11, 18 and K8.12 mAb specific to the CK pair 13/16. In studies on human salivary glands, MCs around acini and inserted ducts were detected using K8.13 mAb and antibodies specific to CK 10, 4, 5, 6, 19 and 11.<sup>18</sup> Similar results were reported by Burns et al.<sup>16</sup> using antibodies reactive with CK 10 and 11 as well as K8.12 mAb. However, these results were not confirmed by Dardick.<sup>19</sup> Based on other studies, MCs also contain CK18<sup>18</sup>, CK7<sup>17</sup>, CK14, CK17.<sup>4,6</sup> It can be concluded that the cytokeratin profile of rat SSG MCs differs from cytokeratin composition of these cells in other mammals.

Na osnovu ovih rezultata može se sa velikom verovatnoćom pretpostaviti da u MĆ PPŽ pacova nisu prisutni CK prostog epitela. Osim CK para 13/16 antitela u MĆ PPŽ može pomoći u dodatnom rasvetljavanju procesa normalnog razvoja ovih ćelija kao i procesa histogeneze tumora pljuvačnih žlezda.

PT13D11 je novoprodukovano mAb u Institutu za medicinska istraživanja VMA<sup>20</sup>. Kao imunogen korišćen je timus pacova. Obzirom da je ovo mAb specifično za epitel pacova ono je pokazalo dominantno vezivanje za MĆ, jer ove ćelije sadrže proteine koji ukazuju na njihovo epitelno poreklo. Ova konstantna i potpuna pozitivnost se odnosila na MĆ mukoznih acinusa u adultnom periodu, dok su MĆ kanala dale negativnu reakciju sa PT13D11 mAb. Kakav je značaj ovog molekula za sada se ne može reći dok ne bude identifikovana njegova biohemijska priroda.

Monoklonsko antitelo ED3 prepoznaje pacovski sijaloadhezin<sup>21</sup>. Funkcije ovog molekula nisu dovoljno proučene ali se pretpostavlja da ima značajnu ulogu u regulaciji funkcije makrofaga kao i u komunikaciji makrofaga sa okolinom<sup>22,23</sup>. Rezultati istraživanja prikazani u ovoj studiji su prvi koji pokazuju reaktivnost ED3 mAb sa MĆ pljuvačnih žlezda. Obzirom da je sijaloadhezin adhezivni molekul može se pretpostaviti da je on verovatno uključen i u adhezivne interakcije između epitelnih ćelija pljuvačnih žlezda i drugih komponenti ćelijskog ili vanćelijskog matriksa.

## Zaključak

Dobijeni rezultati ukazuju da MĆ, lokalizovane uz bazalne membrane acinusa i izvodnih kanala, PPŽ pacova poseduju karakteristična fenotipska svojstva. One ispoljavaju CK reaktivne sa K8.13 i K8.12 mAb, karakteristični za stratifikovani epitel. Takođe ove ćelije ispoljavaju antigene PT13D11 i ED3 mAb. Antigenske karakteristike MĆ se menjaju tokom ontogeneze. Najznačajnije promene se odnose na broj MĆ i ekspresiju njihovih antigena koji se povećavaju tokom ontogeneze. Nalazi otvaraju nove pravce istraživanja biohemijskih i funkcionalnih karakteristika MĆ.

Based on the present results, it may be hypothesized with great probability that rat SSG MCs do not contain simple CKMCs showed negative reactivity toward PT13D11 mAb. The importance of this molecule remains unclear until its biochemical nature is identified.

PT13D11 is a newly produced mAb at the Institute for medical research of the Military Medical Academy (MMA).<sup>20</sup> Rat thymus was used as an immunogen. Given the fact that this mAb was specific to rat epithelium, it showed a dominant reaction with MCs, because these cells contain proteins suggesting their epithelial origin. This constant and full positive reactivity was associated with MCs of mucous acini in adulthood, whereas duct MCS showed negative reactivity toward PT13D11 mAb. The importance of this molecule remains unclear until its biochemical nature is identified.

ED3 mAb recognized rat sialoadhesin.<sup>21</sup> The function of this molecule has not been sufficiently studied, but it is assumed that it has a regulatory role in macrophage function as well as the communication of macrophages with the environment.<sup>22,23</sup> The present results are the first showing the reactivity of ED3 mAb with salivary gland MCs. Because sialoadhesin is an adhesive molecule, it may be assumed that it is probably involved in adhesive interactions between salivary gland epithelial cells and other components of cellular and extracellular matrix.

## Conclusion

The obtained results suggest that MCs of rat SSG, localized near acinal basal membranes and excretory ducts, possess characteristic phenotypic properties. They express CKs reactive with K8.13 and K8.12 mAb, which are characteristic for stratified epithelium. Furthermore, these cells express PT13D11 and ED3 mAb. MC antigen characteristics change during ontogenesis. The most important changes are associated with the number of MCs and their antigen expression which increase during ontogenesis. The present results open new pathways for studying biochemical and functional characteristics of MCs.

## Literatura / References

1. Riva A, Seera GP, Proto E et al. The myoepithelial and basal cells of ducts of human major salivary glands: A SEM study. *Arch Histol Cytol* 1992;55:115-124.
2. Gugliotta P, Sapino A, Macri L, Skalli O, Gabbiani G, Bussolati G. Specific demonstration of myoepithelial cells by anti-alpha smooth muscle actin antibody. *J Histochem Cytochem* 1988;36:659-663.
3. Ogawa Y, Yamauchi S, Ohnishi A, Ito R, Ijuhin N. Immunohistochemistry of myoepithelial cells during development of the rat salivary glands. *Anat Embryol* 1999; 200: 215-228.
4. Ogawa Y., Kishino M., Atsumi Y., Kimoto M., Fukuda Y., Ishida T. and Ijuhin N. Plasmacytoid cells in salivary-gland pleomorphic adenomas: evidence of luminal cell differentiation. *Virchows Arch*: 2003; 443: 625-634.

5. Foshini MP, Scarpellini F, Gown AM, Eusebi V. Differential expression of myoepithelial markers in salivary, sweat and mammary glands. *Intern J Surg Pathol* 2000;8(1):29-37.
6. Grandi D, Campanini N, Becchi G, Lazzaretti M. On the myoepithelium of human salivary glands. An immunocytochemical study. *Eur. J. Morphol*, 2000;38:249-255.
7. Namba Y, Yamada K, Kudeken W et al. Phenotypic changes in salivary gland myoepithelial cells during postnatal development of rats. *Acta Histochem Cytochem* 2000;33(2):73-79.
8. Redman RS. Myoepithelium of salivary glands. *Microsc Res Techn* 1994;27:25-45.
9. Segawa A, Shoi N, Yamashina S. Function of myoepithelial cells in salivary secretion: revolution of the expulsion theory. *Acta Anat Nippon* 1995;70:330-7.
10. Draeger A, Nathrath WBJ, Lane EB, Sundstrom BE, Stigbrand TI. Cytokeratins, smooth muscle actin and vimentin in human normal salivary gland and pleomorphic adenomas. *Immunohistochemical studies with particular reference to myoepithelial and basal cells. APMIS* 1991;99:405-415.
11. Su L, Morgan PR, Harrison DL, Wseem A, Lane EB. Expression of keratin mRNAs and proteins in normal salivary epithelia and pleomorphic adenomas. *J Pathol* 1993;171:173-181.
12. Ogawa Y, Toyosawa S, Ishida T, Ijuhin N. Keratin 14 immunoreactive cells in pleomorphic adenomas and adenoid cystic carcinomas of salivary glands. *Virchows Arch* 2000;437:58-68.
13. Franke WW, Schamid E, Freudenstein C, Appelhans B, Osborn M, Weber K, Ullmann TW. Intermediate sized filaments of the prekeratin type in myoepithelial cells. *J Cell Biol* 1980; 84: 633-654.
14. Moll R, Franke WW, Schiller DL, Geiger B, Krepler R. The catalog of human cytokeratins. *Patterns of expression in normal epithelial, tumors and cultured cells. Cell* 1982; 31: 11-24.
15. Moll R, Schiller DL, Franke WW. Identification of protein IT of the intestinal cytoskeleton as a novel type 1 cytokeratin with unusual properties and expression patterns. *J Cell Biol* 1990;111: 567-80.
16. Burns BF, Dardick I, Parks WR. Intermediate filament expression in normal parotid glands and pleomorphic adenomas. *Virchow Archiv A Pathol Anat* 1988; 413: 103-112.
17. Born IA, Schwechheimer K, Maier H, Otto HF. Cytokeratin expression in normal salivary glands and in cystadenolymphomas demonstrated by monoclonal antibodies against selective cytokeratin polypeptides. *Virchow Archiv A* 1987;411:583-589.
18. Geiger S, Geiger B, Leitner O, and Marshk G. Cytokeratin polypeptides expression in different elements of human salivary glands. *Virchows Arch A* 1987; 410:403-414.
19. Dardick I, Cavelli S, Boivin M, et al. Salivary gland myoepithelioma variants. Histological, ultrastructural and immunocytological features. *Virchow Archiv A Pathol Anat* 1989; 416:25-42.
20. Pavlović DM, Čolić M, Vučević D, Dujčić A. Two novel monoclonal antibodies reactive with different components of the rat thymic epithelium. *Thymus* 1993;21:235-246.
21. Dijkstra CD, Dopp EA, Joling P, Kraal G. The heterogeneity of mononuclear phagocytes in lymphoid organs: distinct macrophage subpopulation in the rat recognized by monoclonal antibodies ED1, ED2 and ED3. *Immunology* 1985;54:589.
22. Van den Berg TK, Breve JJ, Damoiseaux JG et al. Sialoadhesin on macrophages: its identification as a lymphocyte adhesion molecule. *J Exp Med* 1992;176:647-655.
23. Crocker PR, Paulson JC, Varki A. Siglecs and their roles in the immune systems. *Immunology* 2007;7:255-266.

#### Adresa za korespondenciju

Dr Ivan Dožić  
 Dr Subotića br.1  
 Mob.tel 064-1111237  
 Email: idozić@eunet.yu

#### Address for correspondence

Dr Ivan Dožić  
 Dr Subotića br.1  
 Mob.tel 064-1111237  
 Email: idozić@eunet.yu