



Pakistan Veterinary Journal

ISSN: 0253-8318 (PRINT), 2074-7764 (ONLINE)

Accessible at: www.pvj.com.pk

SHORT COMMUNICATION

Trichloroacetic Acid Spray for the Treatment of Foot Ulcers of Foot and Mouth Disease in Cattle

Imad I. Aldabagh, Oday S. Al-Obaddy and Hafidh I. Al-Sadi*

Central Veterinary Hospital, Ninevha Province and *Department of Pathology and Poultry Diseases, College of Veterinary Medicine, University of Mosul, Mosul, Iraq

*Corresponding author: hafidhalsadi@yahoo.com

ARTICLE HISTORY

Received: May 25, 2011
 Revised: June 13, 2011
 Accepted: June 26, 2011

Key words:

Cattle
 Foot and mouth disease
 Treatment
 Trichloroacetic acid
 Ulcers

ABSTRACT

An attempt was made to evaluate the therapeutic effect of trichloroacetic acid (TCA) for ulcers of the hooves of 120 cattle affected with foot and mouth disease (FMD). Each hoof was cleaned and washed with water before using the TCA spray (2%) once daily. Biopsies were taken from the soft tissue lesions before and after 10 days of treatment. These tissue specimens were processed routinely for histopathological examination. A marked improvement was seen in the pain inflicted by palpation of the affected hoof. Microscopically, coagulative necrosis of the soft tissue of the hoof was seen. An advanced stage of healing of the hoof ulcers was observed on 10th day post-treatment. It was concluded that 2% solution of TCA was an effective treatment of ulcers of the hooves of cattle affected with FMD.

©2011 PVJ. All rights reserved

To Cite This Article: Aldabagh II, OSA Obaddy and HI Al-Sadi, 2012. Trichloroacetic acid spray for the treatment of foot ulcers of foot and mouth disease in cattle. *Pak Vet J*, 32(1): 136-137.

INTRODUCTION

Trichloroacetic acid or trichloroethanoic acid (TCA; CCl_3COOH) is made by chlorinating acetic acid; it is mainly used in the production of its sodium salt, which is used in many industries (e.g., as an herbicide, etching agent and antiseptic). The TCA is also known for its keratolytic agent that can coagulate proteins of the skin, killing all living structures to the level of the reticular dermis (Lin *et al.*, 2005). It is commonly used for the treatment of cutaneous hyper-pigmentation and fine wrinkling, genital warts, human papilloma virus infection and other conditions in humans (Herbig *et al.*, 2009; Kim *et al.*, 2009; Sanchez *et al.*, 2009) and animals (Yang *et al.*, 2007; Karami *et al.*, 2009).

Foot and mouth disease (FMD) is one of the most serious livestock diseases (McGavin and Zachary, 2007). In this disease, the coronary bands of the hooves can be affected. As a consequence of vesiculation of the coronary bands, sloughing of the hoof may occur. Although, FMD is not fatal, however, affected animals usually suffer from pain and in-appetence leading to weight loss (Radostits *et al.*, 2007). Some of the drug used for treatment of bovine foot ulcers include copper sulphate, oxytetracycline with gentian violet spray and formalin. Little success has been reported for the use of these solutions. The TCA has been commonly used as chemical peel (Lee *et al.*, 2009). The

purpose of the present study was to report the successful treatment of foot lesions of suspected naturally-occurring FMD in cattle.

MATERIALS AND METHODS

One hundred and twenty bovine cases with ulcers of the hooves resulting from FMD were treated. Affected animals showed signs of pain upon palpation of the hooves, during walking and standing. The most common location of the ulcers was interdigital space. The animals were treated with a commercial grade 2% TCA (Aqueous Solution; Ninevha Province, Iraq). The TCA solution was sprayed once daily, using a barber bottle, for 10 days. Before treatment, the hooves were cleaned with water and sprayed with TCA till the ulcers were fully covered with the spray. Tissue biopsies were taken from the soft tissue of the hoof before and after 10 days of the spray and fixed in 10% formalin for 48-72 hours. Following fixation, the tissue specimens were washed with tap water, dehydrated in ascending grades of alcohol, cleared in xylol and embedded in paraffin wax (60-62°C melting point). Sections of 4-6 μm thickness cut and stained with hematoxylin and eosin and the slides were examined under a light microscope and photographs were taken using digital camera (Sony Corp, Digital Still Camera Model No. DSC-S650, 7.2 Mega pixels, Japan).

RESULTS AND DISCUSSION

Healing of the foot ulcers was enhanced greatly within 24 hours following treatment with TCA and almost completely healed after 10 days of treatment. An 80% improvement in the ataxia of the affected animals was noticed on 10th day post-treatment. Similar success was obtained by others using chemical ablation with TCA to treat eyelid apocrine hidrocystomas in a cat (Yang *et al.*, 2007). The TCA has also been found effective in the treatment of posterior conjunctival cyst in an anophthalmic socket (Sanchez *et al.*, 2009). The TCA matricectomy was effective in the treatment of ingrowing toenails (Kim *et al.*, 2009).

Histopathologically, the TCA treated soft tissues were converted to masses of coagulative necrosis (Fig. 1 and 2). This finding is comparable to that of Lin *et al.* (2005), who reported that 50% TCA was a potential agent for low-grade vaginal intraepithelial neoplasia, with minimal side effects.

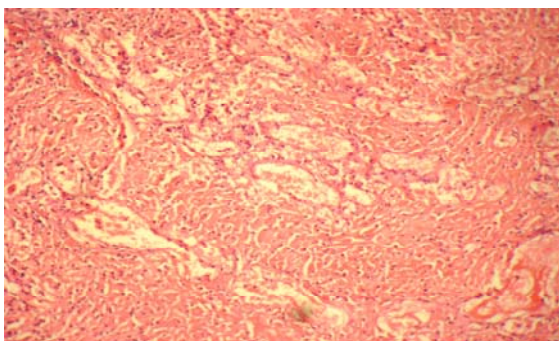


Fig. 1: The dermis (interdigital space) of a cow affected with FMD. Vascular changes and very mild infiltration of mononuclear inflammatory cells could be seen. H and E X200.

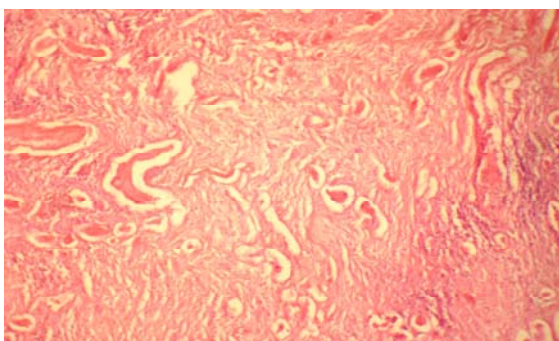


Fig. 2: The dermis (interdigital space) of a cow affected with FMD, 10 days after local treatment with 2% TCA spray. Coagulative necrosis of the dermis is visible. H and E X200.

The TCA is a commonly utilized agent for chemical resurfacing of the face and a combination of Jessner's solution and 35% TCA has been found to be effective and safe resurfacing tool that can treat superficial to moderate rhytids (Herbig *et al.*, 2009). The TCA concentrations of 20 to 35% are usually used to perform medium-depth chemical peel of the skin. This effect of TCA has been attributed to its feature as a keratocoagulant which produces a frost or whitening of the skin (Dinner and Artz, 1998). Application of TCA to the skin precipitates the proteins and causes coagulative necrosis of cells in the epidermis and necrosis of collagen in the papillary to upper reticular dermis. Within few days the necrotic layers slough and the skin re-epithelializes from the adnexal structures that were spared from chemical damage. The clinical effects of TCA have been attributed to reorganization in dermal structural elements and increased dermal volume as a result of increased collagen content, glycosaminoglycan, and elastin (Lee *et al.*, 2009).

From results of the present study it was concluded that 2% TCA was effective for the treatment of ulcer of the hooves of cattle affected with FMD. Further controlled study is warranted to investigate the effects of different TCA concentrations.

REFERENCES

- Dinner MI and JS Artz, 1998. The art of trichloroacetic acid chemical peel. *Clin Plast Surg*, 25: 53-62.
- Herbig K, AP Trussler, RK Khosla and RJ Rohrich, 2009. Combination Jessner's solution and trichloroacetic acid chemical peel: technique and outcomes. *Plast Reconstr Surg*, 124: 955-964.
- Karami B, A Khayat, F Moazami, S Pardis and P Abbott, 2009. Histological evaluation of the effect of three medicaments; trichloroacetic acid, formocresol and mineral trioxide aggregate on pulp-tomized teeth of dogs. *Aust Endod J*, 35: 18-28.
- Kim SH, HC Ko, CK Oh, KS Kwon and MB Kim, 2009. Trichloroacetic acid matricectomy in the treatment of ingrowing toenails. *Dermatol Surg*, 35: 973-979.
- Lee JB, WG Chung, H Kwahek and KH Lee, 2009. TCA localized peeling (focal treatment of acne scars with trichloroacetic acid) TCA cross method. <http://www.cosmeticskin.com/skinacne4.shtml>
- Lin H, EY Huang, HY Chang and CC Chang Chien, 2005. Therapeutic effect of tropical applications of trichloroacetic acid for vaginal intraepithelial neoplasia after hysterectomy. *Jap J Clin Oncol*, 35: 651-654.
- McGavin MD and JF Zachary, 2007. Pathological basis of veterinary disease, 4th Ed. Mosby/Elsevier, Missouri, USA, pp: 303-305.
- Radostits OM, CC Gay, KW Hinchcliff and PD Constable 2007. Veterinary medicine. A textbook of the diseases of cattle, horses, sheep, pigs and goats. 10th. Ed, Saunders/Elsevier, Edinburgh, UK, pp: 1223-1230.
- Sanchez EM, NA Formento, M Perez-lopez and AA Jimenez, 2009. Role of trichloroacetic acid in treating posterior conjunctival cyst in an anophthalmic socket. *Orbit*, 28: 101-103.
- Yang, SH, CH Liu, CD Hsu, LS Yeh and CT Lin, 2007. Use of chemical ablation with trichloroacetic acid to treat eyelid apocrine hidrocystomas in a cat. *J Am Vet Med Assoc*, 230: 1170-1173.