


ISSN 2210-2612

# INTERNATIONAL JOURNAL OF SURGERY CASE REPORTS

Advancing surgery through shared experience



ERUDITIO • DILIGENTIA • FIDES

EST. 2003



INTERNATIONAL JOURNAL OF  
**SURGERY CASE REPORTS**  
The Largest Journal Publishing Surgical Case Reports

ADVERTISEMENT

Lc

Articles & Issues For Authors For Reviewers Journal Info Sister Journals Thomas Starzl Prize [Submit Your Manuscript](#)

All Content  [Advanced Search](#)

## Editorial Board

### Editor-in-Chief

**David Rosin**, Bridgetown, Barbados

### Managing and Executive Editor

**Riaz Agha**, London, England, UK

### Senior Editors

**R.Y. Afifi**, Cairo, Egypt

**H. Alam**, Ann Arbor, USA

**J. P. Barret**, Barcelona, Spain

**B. Challacombe**, London, UK

**X-P. Chen**, Wuhan, China

**R.L. De Wilde**, Oldenburg, Germany

**B. Ekser**, Indianapolis, USA

**H.B. Hechtman**, Boston, USA

**J. W. Y. Lau**, Shatin, Hong Kong

**O. Muensterer**, Mainz, Germany

**S. Rogers**, Chicago, USA

**J. Talati**, Karachi, Pakistan

**M. Thorat**, London, UK

**F.C. Wei**, Taipei, Taiwan

### Associate Editors

**R. Coppola**, Rome, Italy

**V. Kasivisvanathan**, London, UK

**R Keijzer**, Winnipeg, Canada

**B Kirshtein**, Beer-Sheva, Israel

**J.A. McCaul**, Bradford, UK

**E.R. McGlone**, London, UK

**D. Muzumdar**, Mumbai, India

**A Petroianu**, Belo Horizonte, Brazil

**S.G. Raja**, London, UK

**K Raveendran**, Ipoh, Malaysia

**D. Yeh**, Boston, USA

#### Assistant Editors

**R. Al-mahfoudh**, Oxford, England, UK

**H. M. Atta**, Boston, Massachusetts, USA

**M. Bashashati**, Calgary, Canada

**S. Basu**, Varanasi, India

**A. Beamish**, Gothenburg, Sweden

**A. G. Charles**, Chapel Hill, North Carolina, USA

**A. Das**, Hyderabad, India

**M.E. Erdil**, Istanbul, Turkey

**S. A. Esquivel Gaón**, Mexico

**J. Gómez Rivas**, Madrid, Spain

**H. Kaafarani**, Boston, Massachusetts, USA

**Y. D. Kamat**

**O. Khan**, London, UK

**T. Manning**, Melbourne, Victoria, Australia

**I. Mukherjee**, Staten Island, USA

**E Ofo**, Adelaide, South Australia

**S. Pai**, Mumbai, India

**S. Feng**, Shanghai, China

**A. Smailys**, Kaunas, Lithuania

**D.G. Weber**, Perth, Australia

**H. Zhu**, Shanghai, China

#### Statistical Editors

**N. Donaldson**, Colombia, South America

**M.W. Gray**, Washington DC, USA

#### Society Representatives

**X-P. Chen**, President of the Chinese Chapter of International Hepato-Pancreato-Biliary Association

**G.F. Coppa**, President of the New York Surgical Society

**A. Williams**, President, Association of Surgeons in Training

#### Executive Committee

**Professor D.K.C Cooper**, Pittsburgh, USA

**A. Darzi**, London, England, UK

**H. Ellis**, London, England, UK

**Sir G. Catto**, London, UK

**Sir B. Jackson**, London, UK

**Professor S. Standring**, London, UK

**Lord R. Winston**, London, UK

**Sir N. Williams**, London, UK

**C.-H. Leong**, Hong Kong, China

**A. Li K-C.**, Wanchai, Hong Kong

**I. McColl**, London, UK

**J. Norcini**, Philadelphia, USA

**M. Yacoub**, London, England, UK

## Editorial Board

**R. A. Badwe**, Mumbai, India

**M. Boscoe**, Middlesex, England, UK

**R. Bueno**, Boston, USA

**K. Chatamra**, Bangkok, Thailand

**P. Coulthard**, Manchester, UK

**A. d'Cruz**, Mumbai, India

**M. Desai**, Mumbai, India

**W. Green**, London, UK

**I. Harirchi**, Tehran, Iran

**D. Henne-Bruns**, Ulm, Germany

**D. Kahn**, Cape Town, South Africa

**X. Lin**, Shanghai, China

**A. Mahapatra**, New Delhi, India

**I. Mitra**, Mumbai, India

**V. Naraynsingh**, West Indies

**F. Nicoli**, London, England, UK

**A. Núñez De Pierro**, Buenos Aires, Argentina

**R. Orda**, Tel Aviv, Israel

**V. Semiglazov**, St Petersburg, Russia

**T. Singh**, Ludhiana, India

**B.L. Smith**, Boston, USA

**T.E. Udwardia**, Mumba, India

**M. C. Warlé**, Nijmegen, Netherlands

**J. Wee**, Boston, Massachusetts, USA

**M. Weiser**, New York, USA

**Y. Zhang**, Shanghai, China

**J Zhong**, Shanghai, China



## International Journal of Surgery Case Reports

OPEN ACCESS

Articles in press

Latest issue

Special issues

All issues

About the journal ↗

Set up journal alerts

## Volume 53

*In progress* (2018)

This issue is in progress but contains articles that are final and fully citable.

[< Previous vol/issue](#)

[Next vol/issue >](#)

Show all article previews [Download PDFs](#) [Export](#)

Case report *Open access*  
**Report of metastatic ileal neuroendocrine tumor to the submandibular gland**  
David Forner, Peter Cho, Martin Bullock, Daniel Rayson, ... Matthew H. Rigby  
Pages 1-4

[Download PDF](#) [Article preview](#) ✓

Case report *Open access*  
**Challenges in managing a vagal schwannomas: Lesson learnt**  
Norhafiza Mat Lazim  
Pages 5-8

[Download PDF](#) [Article preview](#) ✓

Case report *Open access*  
**Breast tuberculosis cases rising in Sicily**

Angela Strazzanti, Claudio Trovato, Santi Gangi, Francesco Basile

Pages 9-12

 [Download PDF](#) [Article preview](#) 

Case report *Open access*

*En bloc* liver-kidney transplantation with renal artery variation using donor splenic artery and left gastric artery as inflow to the kidney: Case report

Michelle C. Nguyen, Sylvester Black, Ken Washburn, Ashraf El-Hinnawi

Pages 13-16

 [Download PDF](#) [Article preview](#) 

Case report *Open access*

A case report of a concomitant total thyroidectomy and carotid body tumor resection in a 43 year old female

Ramon Garcia-Alva, Luis O. Bobadilla-Rosado, Luis H. Arzola, Monserrat Escobar-Preciado, ... Carlos A. Hinojosa

Pages 17-20

 [Download PDF](#) [Article preview](#) 

Case report *Open access*

Splenic epithelial cyst mistaken with Hydatid cyst: A case report

Youssef A. Sleiman, Ali Bohlok, Melody El-Khoury, Pieter Demetter, ... Issam El Nakadi

Pages 21-24

 [Download PDF](#) [Article preview](#) 

Case report *Open access*

Hepatic epithelioid hemangioendothelioma: A great mimicker

Antoni Lluca, Dolors Piquer, Yasmine Maazouzi, Carmen Medina, ... Javier Escrig

Pages 25-28

 [Download PDF](#) [Article preview](#) 

Case report *Open access*

Small bowel obstruction secondary to left paraduodenal hernia: A case report and literature review

Youssef Sleiman, Alaa El-Kheir, Melody El-Khoury, Omar Hamdach, ... Mustafa Allouch

Pages 29-31

 [Download PDF](#) [Article preview](#) 

Case report *Open access*

Necrotizing fasciitis of chest and right abdominal wall caused by acute perforated appendicitis: Case report

Lotfi Rebai, Aziz Daghmouri, Ines Boussaidi

Pages 32-34

 [Download PDF](#) [Article preview](#) 

Case report *Open access*

A rare complication in a liver transplant patient: Meckel diverticulum perforation due to biliary stent

Uğur Topal, Abdullah Ülkü, Ahmet Gökhan Sarıtaş, Atılğan Tolga Akçam  
Pages 35-38

 [Download PDF](#) [Article preview](#) 

Case report *Open access*

Angiomyxoma of the ureter imitating an upper tract urothelial carcinoma: A case report

Ahmed S. Zugail, Faris Baowaidan, Eva-Maria Comperat, Bertrand Guillonnet, Alexandre Colau

Pages 39-42

 [Download PDF](#) [Article preview](#) 

Short communication *Open access*

The lost stone — Laparoscopic exploration of abscess cavity and retrieval of lost gallstone post cholecystectomy: A case series and review of the literature

Uri Kaplan, Gregory Shpoliansky, Ossama Abu Hatoum, Boaz Kimmel, Doron Kopelman

Pages 43-45

 [Download PDF](#) [Article preview](#) 

Case report *Open access*

Multiple isolated small bowel perforations following blunt abdominal trauma

João Louro, Miguel Albano, Teresa Caroco, Luís Reis, Carlos C. Almeida

Pages 46-49

 [Download PDF](#) [Article preview](#) 

Case report *Open access*

A case report of Lipoblastoma: Presenting as a swelling in the nape of the neck of 14 years old girl

Shabbar Hussain Changazi, Ghulam Mujtaba Ghuman, Aamir Bashir, Samiullah Bhatti, ... Usman Ismat

Pages 50-53



 [Download PDF](#) [Article preview](#) 

Case report *Open access*

Chronic anemia due to transmural e-PTFE anti-adhesive barrier mesh migration in the small bowel after open incisional hernia repair: A case report

Francesca Ceci, Linda D'Amore, Elena Annesi, Lucia Bambi, ... Paolo Negro

Pages 54-57

 [Download PDF](#) [Article preview](#) 

Case report *Open access*

Pure mucinous breast carcinoma in a 25-year-old female, a case report

Irean Garcia-Hernandez, Carlos A. Lopez-Garcia, Servando Cardona-Huerta, Rocio Ortiz-Lopez, ... Gabriela Sofia Gomez-Macias

Pages 58-60

 [Download PDF](#) [Article preview](#) 

Case report *Open access*

Gigantism in a McCune-Albright's syndrome with calcified GH-releasing pituitary adenoma: Case report and literature review

Miguel Vega-Arroyo, Martha Lilia Tena-Suck, Celia Teresa de Jesús Álvarez-Gamiño, Citlaltepelt Salinas-Lara, Juan Luis Gómez-Amador

Pages 61-65

 [Download PDF](#) [Article preview](#) 

Case report *Open access*

Extrapelvic endometriosis in abdominal wall scar and PPAR gamma expression: A case report

Achmad Kemal Harzif, Melisa Silvia, Ana Mariana, Lydia Olivia, ... Budi Wiweko

Pages 66-69

 [Download PDF](#) [Article preview](#) 

Short communication *Open access*

Crohn's disease manifesting as ileo-urachal fistula: Two cases reports and review of literatures

Hirosuke Kuroki, Akira Sugita, Kazutaka Koganei, Kenji Tatsumi, ... Tsuneo Fukushima

Pages 70-74



 [Download PDF](#) [Article preview](#) 

Short communication *Open access*

Facial cutaneous lesions of dental origin: A case series emphasizing the awareness of the entity and its medico-legal consequences

Mohammad M. Al-Qattan, Muhammed I. Almotairi

Pages 75-78

 [Download PDF](#) [Article preview](#) 

Case report *Open access*

First dorsal compartment musculotendinous avulsion accompanied by close radial styloid fracture: Case report

Emre Anıl Özbek, Mehmet Armangil, Sırrı Sinan Bilgin

Pages 79-84

 [Download PDF](#) [Article preview](#) 

Case report *Open access*

A resected case of hepato-pancreaticoduodenectomy for widely extended cholangiocarcinoma undergoing previous intra-abdominal poly-surgery

Atsushi Nanashima, Naoya Imamura, Masahide Hiyoshi, Koichi Yano, ... Hiroshi Ito

Pages 85-89

 [Download PDF](#) [Article preview](#) 

Case report *Open access*

A successfully resected case of left trisectionectomy with arterio-portal combined resection for advanced cholangiocarcinoma

Atsushi Nanashima, Naoya Imamura, Masahide Hiyoshi, Koichi Yano, ... Hiroshi Ito

Pages 90-95



[Download PDF](#)[Article preview](#)  Case report *Open access*

### Intestinal ischemia secondary to superior mesenteric venous thrombosis—A case report

Jason Cui, Brian Kirkby

Pages 96-98

[Download PDF](#)[Article preview](#)  Case report *Open access*

### Excision of rare carotid body tumour without preembolisation: Case report and literature review

S. Shahi, Anupam Raj Upadhyay, Anuj Devkota, Tridip Pantha, ... Dhundi Raj Paudel

Pages 99-101

[Download PDF](#)[Article preview](#)  Case report *Open access*

### Synchronous bilateral breast cancer: A case report of heterogeneous estrogen receptor status

Sunny Dhadlie, Joseph Whitfield, Rasika Hendahewa

Pages 102-106

[Download PDF](#)[Article preview](#)  Case report *Open access*

### Rescue of ankylosing hip following open reduction and internal fixation of acetabular fracture by surgical resection of heterotopic ossification: A case report

Kazumichi Kitayama, Yohei Kawakami, Tomoaki Fukui, Keisuke Oe, ... Takahiro Niikura

Pages 107-111

[Download PDF](#)[Article preview](#)  Case report *Open access*

### Laparoscopic extraction of gastric self-expandable metallic stent after migration in ileum: A case report

F.-X. Terryn, E. Dereeper, S. Lo Bue

Pages 112-114

[Download PDF](#)[Article preview](#)  Case report *Open access*

### Case report of squamous cell cancer arising in perineal epidermal inclusion cyst, presenting as rapidly enlarging and cavitating lesion

Jose Vale, Yijun Pang, Arthur Kumpf, David Fitkin, Scott Drew

Pages 115-119

[Download PDF](#)[Article preview](#)  Case report *Open access*

### Laparoscopic hysterocropexy in case of total uterus prolapse – case report

Paweł Szymanowski, Wioletta Katarzyna Szepieniec, Paweł Gruszecki, Isabel Netzer

Pages 120-126

[Download PDF](#)[Article preview](#)  Case report *Open access*

### Very rare localization of a retroperitoneal hemangiopericytoma revealed by lumbosciatalgia: A case report

Amine Chhaidar, Skandar Zouari, Ahlem Bdioui, Moncef Mokni, Ali ben Ali

Pages 127-131

[Download PDF](#)[Article preview](#)  Case report *Open access*

### Juxta-adrenal schwannoma presenting as a giant adrenal tumor: A case report and a literature review

Maher Abdessater, Mohammad El Mokdad, Jerome Gas, Walid Sleiman, ... Stephane Bart

Pages 132-136

[Download PDF](#)[Article preview](#)  Case report *Open access*

### A case report: Rectal endometriosis mimicking rectal cancer

Li-Juan Zhao, Yuan-He Wang, Jing-Dong Zhang

Pages 137-139

[Download PDF](#)[Article preview](#)  Case report *Open access*

### First case of laparoscopic partial splenectomy in a child with hamartoma: Case report and review of the literature

Francesco Serra, Lorena Sorrentino, Francesca Cabry, Diego Biondini, ... Roberta Gelmini

Pages 140-143

[Download PDF](#)[Article preview](#)  Case report *Open access*

### Metastatic melanoma: An unusual cause of gastrointestinal bleeding and intussusception—A case report

Sílvia Silva, Nádia Tenreiro, Ana Melo, José Lage, ... Paulo Avelar

Pages 144-146

[Download PDF](#)[Article preview](#)  Case report *Open access*

### Impacted ureteric stone causing iliofemoral vein thrombosis: The first reported case

Mohammed Abed Al Kadum Hassan, Rawa Hama Ghareeb Ali, Okba Fathy Ahmed, Fahmi H. Kakamad, Hewa Mahmood Toffeq

Pages 147-150

[Download PDF](#)[Article preview](#)  Case report *Open access*

### Unusual complication of seroma after ventral hernia mesh repair: Digestive perforation by tacks. A case report

Mohamed Amine Elghali, Salsabil Nasri, Asma Seghaier, Khaireddine Dhouioui, ... Rached Letaief  
Pages 151-153

 [Download PDF](#) [Article preview](#) 

Case report *Open access*

Post-menopausal acquired diaphragmatic herniation in the context of endometriosis

Tejas P. Singh, Syed A.A. Rizvi, Casper F. Pretorius

Pages 154-156

 [Download PDF](#) [Article preview](#) 

Case report *Open access*

A tourniquet-less technique using saline epinephrine irrigation system in an arthroscopic ACL reconstruction in patient with history of popliteal artery ligation

Irissandya D. Atisuksma, Sholahuddin Rhatomy, Punto Dewo

Pages 157-162

 [Download PDF](#) [Article preview](#) 

Short communication *Open access*

Castleman disease: Case series of two surgical patients from different ends of the disease spectrum with literature review

Radhika Raj C.G., Suresh B.

Pages 163-167

 [Download PDF](#) [Article preview](#) 

Case report *Open access*

Case report of surgical treatment of scoliosis caused by neurofibroma located posterior mediastinum

Nozomu Motono, Masahito Kawaguchi, Norio Kawahara, Hidetaka Uramoto

Pages 168-170

 [Download PDF](#) [Article preview](#) 

Case report *Open access*

A case report of a rare and challenging gangrenous splenic flexure volvulus in a pregnant patient

Alison Bullen, Joel Lewin, Trent Cross, Benjamin Woolven

Pages 171-174

 [Download PDF](#) [Article preview](#) 

Case report *Open access*

A proliferating trichilemmal cyst in the perianal region: A case report

Denise Graffitti D'Avila, Danilo Toshio Kanno, Daniel de Castilho da Silva, Vitor Rafael Pastro, ... Carlos Augusto Real Martinez

Pages 175-178

 [Download PDF](#) [Article preview](#) 

Case report *Open access*

A rare case of primary thyroid amyloidosis

M.A. Cannizzaro, S. Lo Bianco, W. Saliba, S. D'Errico, ... G. Magro

Pages 179-181



 [Download PDF](#) [Article preview](#) 

Case report *Open access*

Intestinal occlusion by stenotic neuroendocrine tumours of left colon and concomitant association with small bowel gastrointestinal stromal tumours: A case report

M. Amoruso, V. Papagni, A. Picciariello, V.L. Pinto, ... A. Margari

Pages 182-185

 [Download PDF](#) [Article preview](#) 

Case report *Open access*

A case report of Villar's nodule in a woman without surgical history

Nabonswindé Lamoussa Marie Ouédraogo, Safy Ilboudo, Abdoul Karim Ouattara, Aimé Sosthène Ouedraogo, ... Si Simon Traore

Pages 186-188

 [Download PDF](#) [Article preview](#) 

Case report *Open access*

Early diagnosis of femoral neck stress fractures may decrease incidence of bilateral progression and surgical interventions: A case report and literature review

Kruten M. Patel, Brian A. Handal, William K. Payne

Pages 189-192

 [Download PDF](#) [Article preview](#) 

Case report *Open access*

Liver perivascular epithelioid cell tumor in a patient with systemic lupus erythematosus

Paraskevi V. Voulgari, Vissaria Tatsi, Haralampos J. Milionis, Anna Goussia, ... George K. Glantzounis

Pages 193-195


 [Download PDF](#) [Article preview](#) 

Short communication *Open access*

Sentinel lymph node biopsy in porocarcinoma: A case reports

Simona Reina, Denise Palombo, Alexandru Bosceanu, Nicola Solari, ... Ferdinando Cafiero

Pages 196-199

 [Download PDF](#) [Article preview](#) 

Short communication *Open access*

Can tibial tantalum cones eventually eliminate the adjuvant use of metallic augments for AORI type 2B/3 metaphyseal defects??—A novel surgical technique and case series

Mohit M. Kukreja, Todd V. Swanson

Pages 200-206

 [Download PDF](#) [Article preview](#) 

Case report *Open access*

## Laparoscopic treatment of large bowel obstruction due to a self-locating peritoneal dialysis catheter

Tamara Díaz Vico, José Luis Rodicio Miravalles, Emilio Sánchez Álvarez, María Moreno Gijón, ... Lourdes Sanz Álvarez

Pages 207-210

[Download PDF](#) [Article preview](#)  Case report *Open access*

## Endometriosis of the appendix presenting as acute appendicitis with unusual appearance

B.P. St. John, A.E. Snider, H. Kellermier, S. Minhas, J.M. Nottingham

Pages 211-213

[Download PDF](#) [Article preview](#)  Short communication *Open access*

## Pneumatosis intestinalis a trap for the unwary: Case series and literature review

Sunny Dhadlie, Daniel Mehanna, James McCourtney

Pages 214-217

[Download PDF](#) [Article preview](#)  Case report *Open access*

## Correction of severe valgus deformity of knee osteoarthritis with non-constrained total knee arthroplasty implant: A case report

Dwikora Novembri Utomo, Ferdiansyah Mahyudin, Andre Yanuar, Lukas Widhiyanto, Kukuh Dwiputra Hernugrahanto

Pages 218-222

[Download PDF](#) [Article preview](#)  Short communication *Open access*

## Isolated Roux loop pancreaticojejunostomy versus conventional pancreaticojejunostomy after pancreaticoduodenectomy: A case-control study

Amine Chhaidar, Mohamed Ben Mabrouk, Ali ben Ali

Pages 223-227

[Download PDF](#) [Article preview](#)  Case report *Open access*

## Reconstruction of a surgical defect in the popliteal fossa: A case report

Dan C. Filitis, Juliya Fisher, Faramarz H. Samie

Pages 228-230

[Download PDF](#) [Article preview](#) 

ISSN: 2210-2612

Copyright © 2018 Surgical Associates Ltd. All rights reserved

Contents lists available at [ScienceDirect](http://www.sciencedirect.com)

## International Journal of Surgery Case Reports

journal homepage: [www.casereports.com](http://www.casereports.com)

## Correction of severe valgus deformity of knee osteoarthritis with non-constrained total knee arthroplasty implant: A case report

Dwikora Novembri Utomo<sup>a,\*</sup>, Ferdiansyah Mahyudin<sup>a</sup>, Andre Yanuar<sup>b</sup>,  
Lukas Widhiyanto<sup>a</sup>, Kukuh Dwiputra Hernugrahanto<sup>a</sup><sup>a</sup> Orthopedic and Traumatology Department, Faculty of Medicine, Universitas Airlangga/Dr. Soetomo General Hospital, Surabaya, Indonesia<sup>b</sup> Santo Borromeus Hospital, Bandung, Indonesia

## ARTICLE INFO

## Article history:

Received 18 September 2018

Received in revised form 19 October 2018

Accepted 29 October 2018

Available online 2 November 2018

## Keywords:

Severe valgus deformity

No consensus

MCL shift

Non-constrained implant

Case report

## ABSTRACT

**INTRODUCTION:** Knee osteoarthritis with valgus deformity presents a surgical challenge that must be solved during total knee arthroplasty (TKA). In some case whereby ligament imbalance is found, constrained implant should be used. Unfortunately, the implant is not always readily accessible in some developing countries. The objective of this paper is to provide alternative solution to such case.

**PRESENTATION OF CASE:** We reported a 71-year-old female patient with a painful and fixed valgus deformity of her right knee. Preoperatively, the patient's right knee range of motion (ROM) was 10–145° of flexion with a 32° fixed valgus deformity. A constrained implant was not accessible. To balance the ligament, Medial Collateral Ligament (MCL) origin was shifted to superior and anterior. A non-constrained implant was used. The valgus deformity was corrected intraoperatively and ROM achieved 0–140° of flexion.

**DISCUSSION:** It is crucial that attention is given not only to the restoration of proper bony alignment but even more importantly to soft tissue balancing. By using the non-constrained implant, the cost can also be reduced and suitable for developing countries with limited coverage of state insurance.

**CONCLUSION:** Three months after the surgery, the patient achieved stable and painless knee with 10–90° of flexion and complete correction of her valgus deformity.

© 2018 Published by Elsevier Ltd on behalf of IJS Publishing Group Ltd. This is an open access article under the CC BY license (<http://creativecommons.org/licenses/by/4.0/>).

## 1. Introduction

Knee osteoarthritis with valgus deformity presents a surgical challenge that must be solved during total knee arthroplasty (TKA). This deformity (defined as a valgus angle equal to or greater than 10°) is observed in nearly 10% of patients undergoing TKA [1]. The valgus deformity in osteoarthritis knee is a continuing process developed by bone tissue remodeling and soft tissue contraction/elongation. Bone tissue alterations consist of lateral cartilage erosion, lateral condylar hypoplasia, and metaphyseal femur and tibial plateau remodeling. Soft tissue alterations are characterized by tightening of lateral structures such as lateral collateral ligament (LCL), posterolateral capsule (PLC), popliteus tendon (POP), hamstring tendons, the lateral head of the gastrocnemius (LHG) and iliotibial band (ITB). Some authors also described a posterior cruciate ligament (PCL) alteration in valgus knees, but in the liter-

ature, its influence in maintaining the deformity is not universally recognized. The described deformities can lead to a tibial external rotation and to a patellar lateral subluxation tendency [2]. Three grades of valgus deformity have been described. In grade I, the deviation is less than 10°, passively correctable with contracture of the lateral soft tissue but without elongation of the medial collateral ligament (MCL, 80% of cases). In grade II, the axial deviation ranges between 10° and 20°, the lateral structures are contracted and the MCL is elongated but functional (15% of cases). Grade III deformity is present in the remaining 5% of the patients; the axial deformity is greater than 20°, the lateral structures are tight and the medial stabilizers are not functional [1,3].

Valgus deformity in osteoarthritis, for this reason, is a challenge for the surgeon both for gap balancing and implant constrained choice. Several different surgical techniques have been described to perform TKA in valgus deformity; the aim of this article is to give an optional soft tissue balancing by re-tensioning MCL and using the non-constrained implant. This case report is written according to the recently published SCARE criteria as it used for supporting transparency and accuracy in publication of case-reports [4].

\* Corresponding author at: Jl. Manyar Tirtosari IV/7, Surabaya, East Java, Indonesia.

E-mail addresses: [dwikora-novembri-u@fk.unair.ac.id](mailto:dwikora-novembri-u@fk.unair.ac.id) (D.N. Utomo), [ferdiansyah@fk.unair.ac.id](mailto:ferdiansyah@fk.unair.ac.id) (F. Mahyudin), [andreyanuar@yahoo.com](mailto:andreyanuar@yahoo.com) (A. Yanuar), [lukas-w@fk.unair.ac.id](mailto:lukas-w@fk.unair.ac.id) (L. Widhiyanto), [kukuhdh@gmail.com](mailto:kukuhdh@gmail.com) (K.D. Hernugrahanto).

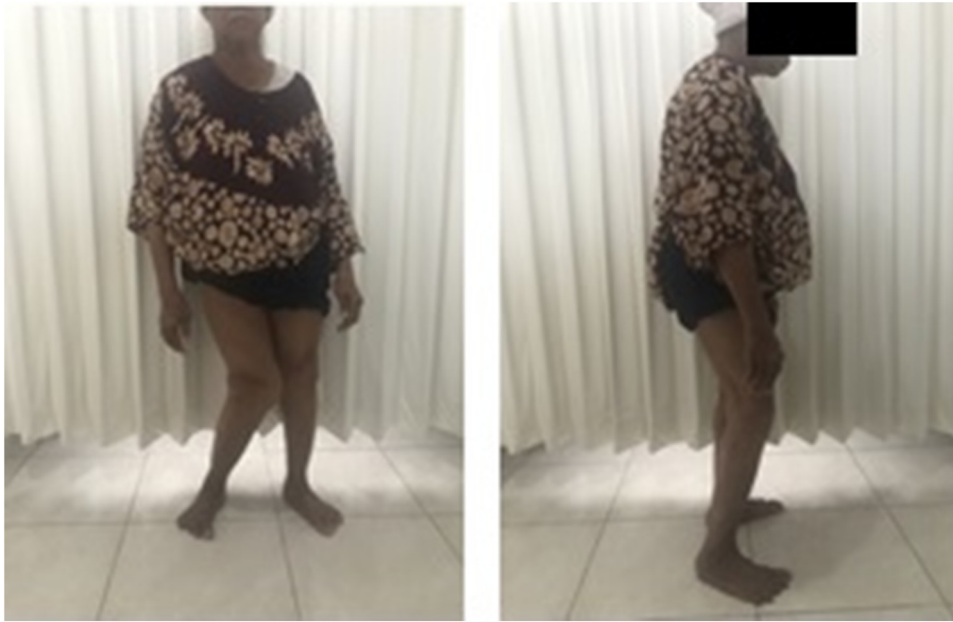

Fig. 1. Patient's clinical appearance (source: internal documentation).

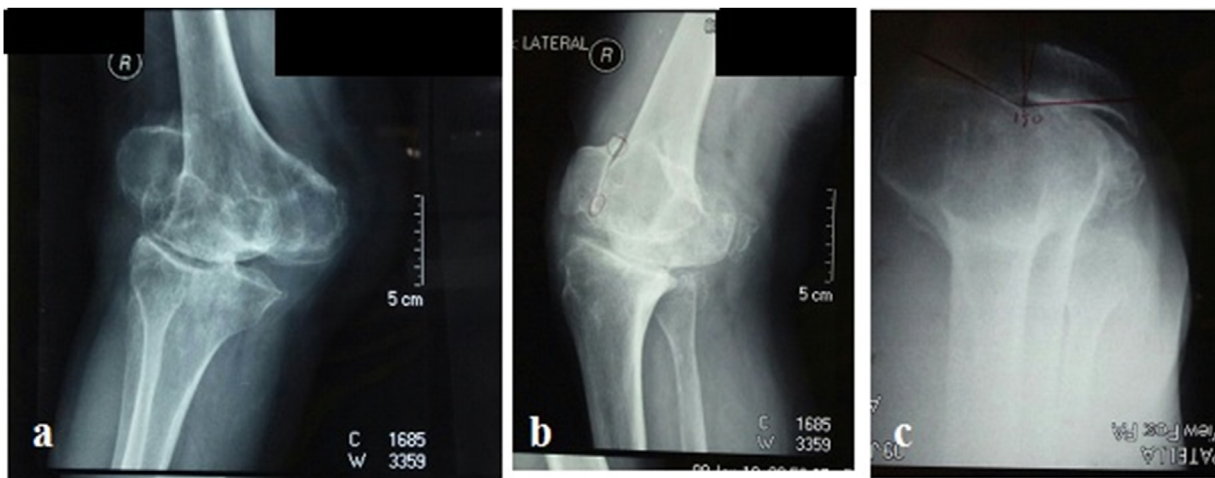


Fig. 2. (a–c) Radiological imaging shows severe osteoarthritic valgus deformity knee (source: internal documentation).

## 2. Presentation of case

Mrs. P is a 71-year-old, slightly obese Indonesian female with an atraumatic progressive painful deformity of her right knee. The patient had become limited to minimal house activity. She required a walker and/or wheelchair for independent mobility at home. She had difficulty to stand and could no longer climb stairs without assistance. Her pain was in proportion to her activities and was unresponsive to nonsteroidal anti-inflammatory drugs (NSAIDs) medication. She had no history of comorbidities related to her knee complaints.

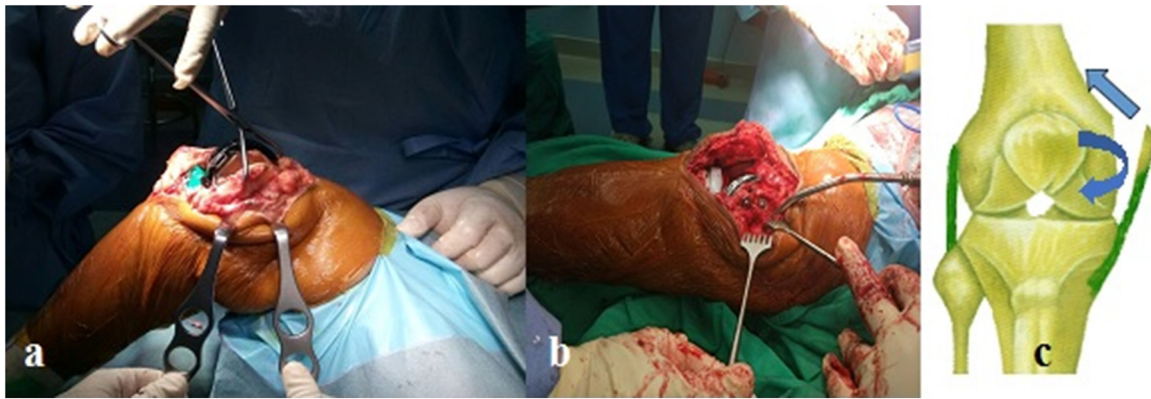
On physical examination, the patient was found to be an alert, oriented female sitting in a wheelchair in no apparent distress. However, she had significant pain on her right knee when she tried to bear-weight. The skin over the right lower extremity was intact and there was no effusion, soft tissue swelling or erythema about the right knee. The right knee was held in a flexed posture (Fig. 1). The right knee range of motion (ROM) was relatively painless but limited to 10–145° of flexion with a 32° (Grade III) fixed valgus deformity.

Left knee also had 10° valgus deformity, however, the ROM of the left knee and both hips were painless within normal limits. X-ray demonstrated a significant valgus deformity of the right knee, erosion of lateral femoral condylar bone and severe tri-compartmental osteoarthritis (Fig. 2). After all of failed attempts of conservative options of treatment, the patient agreed for right total knee arthroplasty. The surgery was performed by the author.

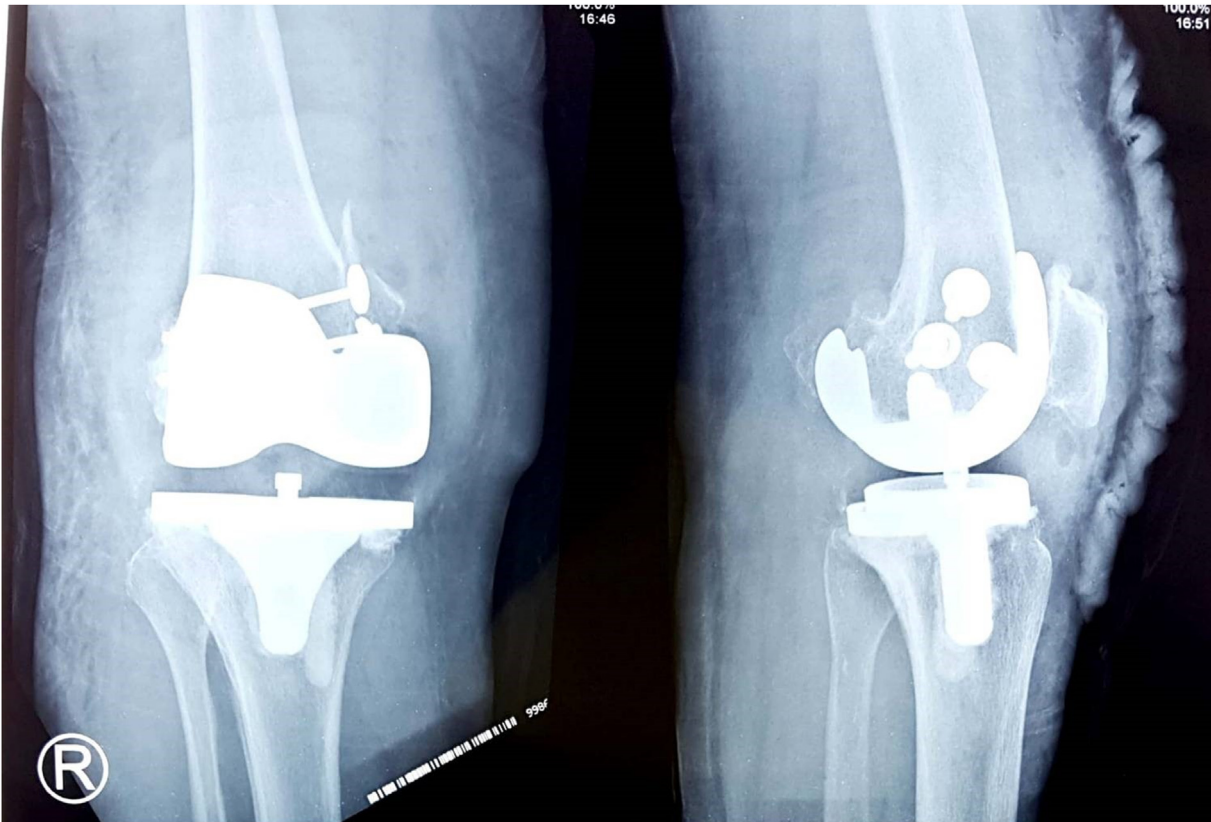
Preoperatively, we had assessed the right knee with severe valgus deformity. We found that the lateral aspect was tight. Therefore, initially we decided to use constrained implant in this patient. Unfortunately, due to limited coverage of the state insurance in, the constrained implant was inaccessible. Therefore, we carried on with the surgery using standard non-constrained implant with addition of soft tissue balancing procedure.

The patient underwent a TKA with epidural anesthesia and intra-operative tourniquet. We performed a medial parapatellar approach. First, we performed the tibial cut, perpendicular to the anatomical axis and removed the smallest possible bone amount, especially from the lateral side. After finishing the bone cuts, we once again tried to assess the balance of the tissue. It was found





**Fig. 3.** (a, b) Medial Collateral Ligament (MCL) origin was shifted to superior and anterior then fixed using 3 screws, (c) Illustration of the MCL origin shift (source: internal documentation).



**Fig. 4.** Post surgery result (source: internal documentation).

that there was soft tissue imbalance due to the severe valgus deformity. The lateral ligaments were tight with loose medial ligaments as predicted preoperatively. Ideally, this grade III valgus deformity should be corrected with constrained implant. Therefore, as planned preoperatively, we did an alternative soft tissue procedure with non-constrained implant.

The MCL origin was cut together with the bone, such as in avulsion fracture. The origin was shifted superiorly in extension. Then, the balanced position was marked. The balancing was continued in flexion position which needs anterior shift of the already marked new position of MCL origin. The new MCL origin was fixed with 3 cortical screws, expecting a bone to bone healing (Fig. 3). ROM achieved intra-operatively was 0–140° of flexion with no valgus deformity. The patella was resurfaced with a 6 mm thickness polyethylene component. This patient used Medacta Evolis® Pri-

mary Posterior Stabilized Implant TKA with an 11 mm polyethylene insert. Postoperative X-ray was shown in Fig. 4. The surgery took two hours since skin incision until wound closure. Blood lost was estimated about 500 ml. Postoperatively the patient's treatment included: routine DVT prophylaxis, gentle progressive active and active-assisted ROM and non-weight-bearing activities for 5 weeks until clinical union.

The patient had a good postoperative recovery and was discharged to a rehabilitation facility to continue her therapy. She returned to her home after a week post-surgery and walked independently in non-weight-bearing with a walker. Rehabilitation was continued, initially within the home and then outside the home. By three months post-TKA, the patient had achieved 10–90° of right knee flexion, with no recurrence of her valgus deformity (Fig. 5).





**Fig. 5.** Clinical appearance 3 months following the surgery; stable while walking (source: internal documentation).

### 3. Discussion

Soft tissues are extremely important for the physiologic functioning of the knee joint [5]. Severe osteoarthritis is often associated with deformity and compromise of normal soft tissue. TKA is a highly successful procedure for the relief of painful arthritis [6]. However, when attempting to restore function and correct abnormalities in ROM and alignment by TKA, it is crucial that attention is given not only to the restoration of proper bony alignment but even more importantly to soft tissue balancing. Sufficient and good soft tissue balance will make the knee stable with non-constrained implant. However, insufficient or incorrect soft tissue balancing may result in the limitation in ROM, patellar mal-alignment, knee instability, premature mechanical failure of the TKA components and pain which result in the need of using constrained implant to address the instability issue [7]. There is no consensus regarding the sequence in which the structures about the knee should be released in the valgus knee [8,9]. Different authors tried to describe a lateral structure release sequence based on functional and anatomical consideration. If the release of the lateral structures does not sufficiently stabilize flexion and extension gaps, then the medial side of the joint should be addressed. Several techniques have been described for successfully and safely tightening

the incompetent medial collateral ligament (MCL). Krackow et al. [3] described MCL advancement of the tibial side, and Krackow [10] described MCL mid-substance division and imbrication to equalize the joint gaps. Ranawat's "pie-crusting technique" has been described for releasing the lateral structure with an inside-out procedure. In this technique, the tight lateral structures are palpated when the lamina spreaders are inserted and they are released performing multiple transverse incisions with a number 15 surgical blade [1].

Healy et al described recessing the origin of the MCL with a bone block from epicondyle [11]. Although these procedures are technically demanding and may affect ligament strength and isometricity, they may be necessary to equalize joint gaps to achieve a stable and durable result. Our early experience using this technique also showed stable and durable after 3 months following surgery (Fig. 5). Another important consideration in the management of valgus deformity is prosthesis selection with regard to the degree of component constrained. Ideally, this patient should have used constrained implant. However, in our country, the state insurance coverage was limited and therefore the implant became inaccessible. There are numerous type of implants ranging from non-constrained to constrained ones. Each type and design has its own degree of constrain, advantages, and disadvantages. Constrained is the limitation of motion between two bodies linked by a joint. There is a spectrum of constrained options available during TKA. Cruciate retaining (CR) prosthesis provides the least amount of constrained. Posterior stabilized (PS) knee prosthesis comes at the next level of constrained. It sacrifices the Posterior Cruciate Ligament (PCL) and provides posterior stability by virtue of a tibial polyethylene post, which engages in the intercondylar cam of femoral component. However, it provides little varus-valgus and rotational stability. Condylar constrained knee (CCK) is at the next level of constrained prostheses. It is a semi constrained, non-linked implant, which confers varus-valgus as well as some rotational stability. Hinge knee prosthesis is a linked constrained device, which provides the highest level of component-to-component constrained, and therefore, confers coronal plane, sagittal plane, as well as rotational stability. The primary goal of total knee arthroplasty is to provide a pain free stable joint, to restore knee kinematics, and alignment with good component fixation, which translate into successful functional and clinical outcome. As we know, if proper soft tissue balance is restored, a minimally constrained implant can be used. Therefore, after we made a good soft tissue balance, we decided to use PS knee prosthesis [12]. By using the non-constrained implant, the cost also can be very significantly reduced and suitable for our country's limited coverage of state insurance.

### 4. Conclusion

The valgus knee presents a surgical challenging problem that must be addressed during total knee arthroplasty. Both bone and soft-tissue deformities complicate restoration of proper alignment, positioning of components, and attainment of joint stability. The variables that may need to be addressed include lateral femoral condyle or tibial plateau deficiencies secondary to developmental abnormalities, and/or wear and laxity of the medial collateral ligament. We found that shifting MCL origin proximally could give stable result after 3 months following surgery and non-constrained implant work well by using this technique. Further evaluation with more number of cases and longer term of evaluation is needed to assess the effectivity and survival using this technique.

### Conflicts of interest

The authors have no conflict of interest to declare.

**Funding source**

There is no specific grant from funding agencies in the public, commercial, or not-for-profit sectors.

**Ethical approval**

Approval to publish case report is waived by the institution.

**Consent**

Written informed consent was obtained from the patient for publication of this case report and accompanying images. A copy of the written consent is available for review by the Editor-in-Chief of this journal on request.

**Author contribution**

Dwikora Novembri Utomo, surgeon: performed the literature review and data collection, designed the manuscript.

Ferdiansyah Mahyudin, surgeon: performed the literature review and data collection, designed the manuscript.

Andre Yanuar, surgeon: contributed to the manuscript writing and data collection.

Lukas Widhiyanto, surgeon: data collection and designed the manuscript.

Kukuh Dwiputra Hernugrahanto: contributed to the manuscript writing and data collection.

**Registration of research studies**

We have reported a single case with no requirement for registry. This manuscript only describes observational study in patient.

**Guarantor**

Dwikora Novembri Utomo.  
Ferdiansyah Mahyudin.

Andre Yanuar.  
Lukas Widhiyanto.  
Kukuh Dwiputra Hernugrahanto.

**Provenance and peer review**

Not commissioned, externally peer reviewed.

**Acknowledgment**

None.

**References**

- [1] A.S. Ranawat, C.S. Ranawat, M. Elkus, V.J. Rasquinha, R. Rossi, S. Babhulkar, Total knee arthroplasty for severe valgus deformity, *J. Bone Joint Surg. Am.* 87 (Suppl 1 (Pt 2)) (2005) 271–284.
- [2] P.A. Keblish, The lateral approach to the valgus knee. Surgical technique and analysis of 53 cases with over two-year follow-up evaluation, *Clin. Orthop. Relat. Res.* 271 (1991) 52–62.
- [3] K.A. Krackow, M.M. Jones, S.M. Teeny, D.S. Hungerford, Primary total knee arthroplasty in patients with fixed valgus deformity, *Clin. Orthop. Relat. Res.* 273 (1991) 9–18.
- [4] R.A. Agha, A.J. Fowler, A. Saetta, I. Barai, S. Rajmohan, D.P. Orgill, S.C.A.R.E. Group, The SCARE statement: consensus-based surgical case report guidelines, *Int. J. Surg.* 34 (2016) 180–186.
- [5] F.M. Griffin, J.N. Insal, G.R. Scuderi, Accuracy of soft tissue balancing in total knee arthroplasty, *J. Arthroplasty* 15 (8) (2000) 970–973, <http://dx.doi.org/10.1054/arth.2000.6503>.
- [6] J. Insall, A.J. Tria, W.N. Scott, The total condylar knee prosthesis: the first 5 years, *Clin. Orthop. Relat. Res.* 145 (1979) 68–77.
- [7] R.S. Laskin, B. Beksac, Computer-assisted navigation in TKA: where we are and where we are going, *Clin. Orthop. Relat. Res.* 452 (2006) 127–131.
- [8] M.A. Freeman, R.C. Todd, P. Bamert, W.H. Day, ICLH arthroplasty of the knee: 1968–1977, *J. Bone Joint Surg. Br.* 60 (1978) 339–344.
- [9] J.N. Insall (Ed.), *Surgery of the Knee*, Churchill Livingstone, New York, NY, 2000, pp. 1558–1562.
- [10] K.A. Krackow, Management of medial collateral ligament loss: repair and augmentation, in: P.A. Lotke, J.P. Garino (Eds.), *Revision Total Knee Arthroplasty*, Lippincott-Raven, Philadelphia, Pa, 1999, pp. 227–250.
- [11] W.L. Healy, R. Iorio, D.W. Lemos, Medial reconstruction during total knee arthroplasty for severe valgus deformity, *Clin. Orthop. Relat. Res.* 356 (1998) 161–169.
- [12] P.J. Favorito, W.M. Mihalko, K.A. Krackow, Total knee arthroplasty in the Valgus knee, *J. Am. Acad. Orthop. Surg.* 10 (1) (2002) 16–24.

**Open Access**

This article is published Open Access at [sciencedirect.com](https://www.sciencedirect.com). It is distributed under the [IJSCR Supplemental terms and conditions](#), which permits unrestricted non commercial use, distribution, and reproduction in any medium, provided the original authors and source are credited.