

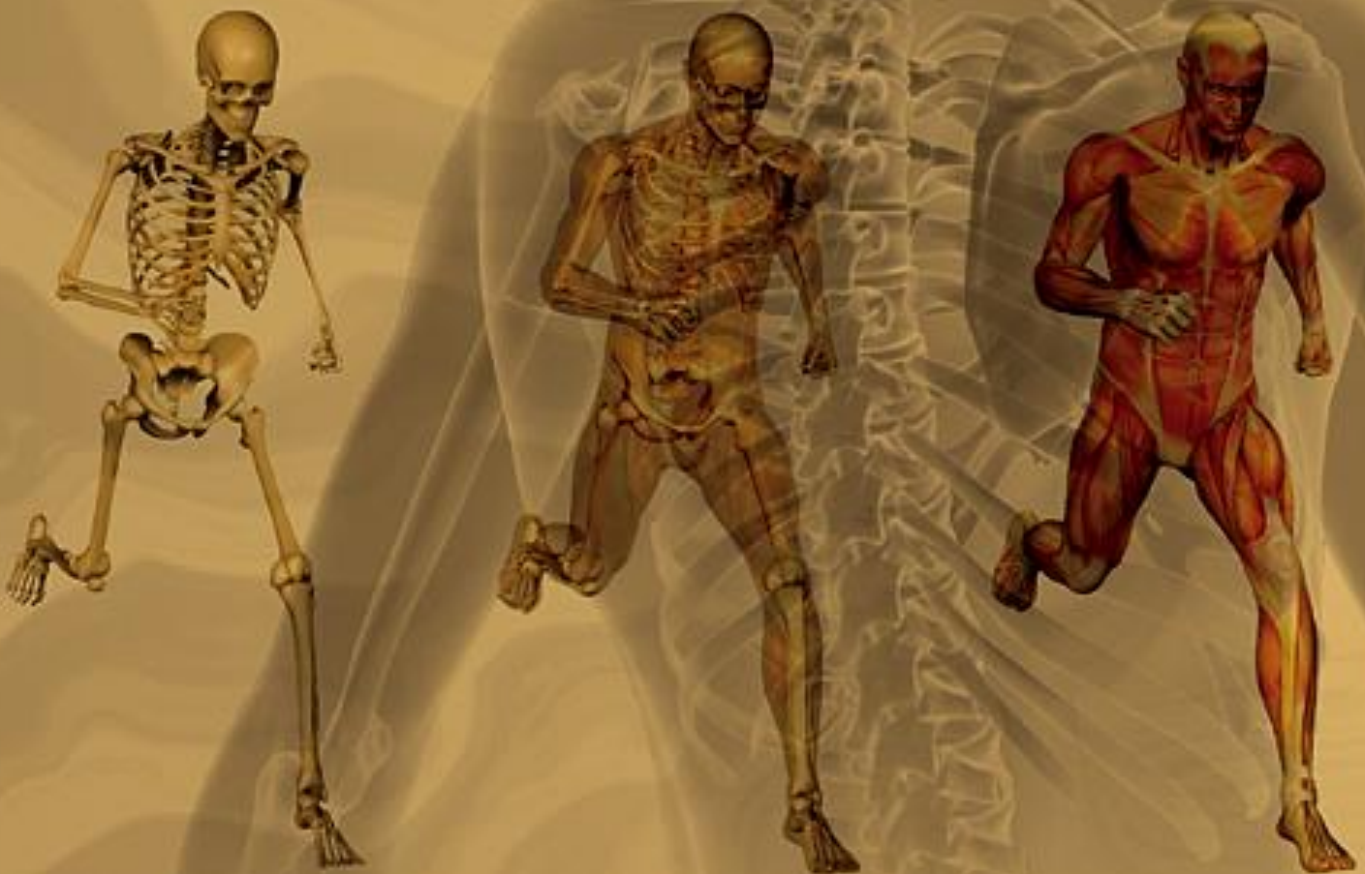Volume 15 | Number 3 | September 2018



JOURNAL *of* ORTHOPAEDICS

Official publication of Prof P K Surendran Memorial Educational Foundation



ISSN: 0972-978X

JOURNAL of ORTHOPAEDICS

Official publication of Prof P K Surendran Memorial Educational Foundation

ISSN: 0972-978X

Editorial Board

Honorary Editor

M.K. Viswanathan
Professor of Orthopaedics
Rajendra Hospital
Kerala, India

Administrative Editor

Nikhil. O. Govindan
Assistant Professor Fascio Maxillary Surgery
Kerala Health University
Kerala, India

Chief Editor

Gopinathan Patinharayil
Professor of Orthopaedics
Gopinath Orthopaedic Centre
Kerala, India

Executive Editor

Anwar Marthya
Professor of Orthopaedics
Kerala Health University
Kerala, India

Associate Editors

Sibin Surendran
Professor of Orthopaedics, Kerala Health University
Kerala, India

Nijith O Govindhan
Kerala Health University Medical College
Calicut, India
dmijith@gmail.com

Editorial Board

Y Y Won
Professor, Ajou University
Suwon, South Korea

Chang Whan Han
Professor, Orthopaedics, Catholic University
Daejon, South Korea

Heiko Graichen
Professor, Orthopaedics
Asklepios Orthopädische Klinik Lindenlohe
Munich, Germany

Masayuki Iki
Professor of Epidemiology, Kinki University
Japan

Oliver Loannis Schmidt
Consultant, Trauma Centre, St. Georg
Klinikum, Germany

Chia-shi Lu
Consultant in Orthopaedics
Singapore General Hospital
Singapore

Hithesh Gopalan
Assistant Professor, Kerala Health University
Kerala, India

Raju Karuppal
Professor, Kerala Health University
Kerala, India

Vinod Scaria
Assistant Professor, Kerala Health University
Kerala, India

Pascal Christel
Professor of Orthopedics Medical Center Olaya
Saudi Arabia

Dr. Thomas Seibel
Chief of Orthopaedics, Puettlingen Klinik
Germany

Antony Kallur
Assistant Professor
University of New Mexico Albuquerque
NM, USA

Piers Yates
Professor, University of Western Australia
Head of Department
Fremantle & Kaleeya Hospitals
Perth, Australia

Lakshmanan Palniyappan
Consultant Spinal Surgeon
Orthopaedic Trauma
Sunderland Royal Hospital
United Kingdom

Rajesh Purushothaman
Professor, Kerala Health University
Kerala, India

Hiroshi Hagino
Professor, Tottori University Faculty of Medicine
Tottori, Japan

Jayesh Trivedi
Head of Department of Spinal Surgery
Robert Jones and Agnes Hunt Hospital
Oswestry, UK

Colin Nandi
Consultant Orthopaedic Spine Surgeon Oxford
University Hospitals NHS Trust
UK

Rocco Paolo Pitto
Associate Professor of Orthopaedics
University of Auckland
New Zealand

Prof. Gautam Chakrabarty
Consultant Orthopaedic and Knee Surgeon
at Calderdale & Huddersfield
Foundation NHS Trust
Huddersfield, United Kingdom

Dr. Darren Tay Keng Jin
Singapore General Hospital (SGH) as a Consultant
Orthopaedic Surgeon. Adjunct Assistant Professor
with both the NUS Yong Loo Lin School of
Medicine and the Duke-NUS Graduate
Medical School
Singapore

M C Rajesh
Consultant Orthopedic Anesthesiologist Baby
Memorial Hospital
Calicut, India

Dr. Ashish Babulakar
Consultant Orthopaedic Surgeon
Mangeshkar Hospital
Pune, India



Keywords
Author name
Journal of Orthopaedics
Volume
Issue
Pages

Journal of Orthopaedics

SUPPORTS OPEN ACCESS

[Articles in press](#) [Latest issue](#) [All issues](#) [About the journal ↗](#) [Follow journal](#)

Volume 15, Issue 3

In progress (September 2018)

This issue is in progress but contains articles that are final and fully citable.

[← Previous vol/issue](#)

[Next vol/issue >](#)

Expand all article previews [Download PDFs](#) [Export](#)

Research article

Association of TNF- α -308 G>A and -238G>A polymorphisms with knee osteoarthritis risk: A case-control study and meta-analysis

Mohammad Reza Sobhan, Masoud Mahdinezhad-Yazdi, Kazem Aghili, Masoud Zare-Shehneh, ... Hossein Neamatzadeh

Pages 747-753



[Purchase PDF](#)

[Article preview](#)

Research article

Arthroscopic approach of femoroacetabular impingement: Early clinical outcomes. A multicentric study

J. Wadhvani, Bellido P. Correa, Huete H. Chicote

Pages 754-756



[Purchase PDF](#)

[Article preview](#)

Research article

Long-term results after surgical treatment of subacromial pain syndrome with or without rotator cuff tear

Eivind Inderhaug, Maiken Kalsvik, Kristin H. Kollevold, Janne Hegna, Eirik Solheim

Pages 757-760



[Purchase PDF](#)

[Article preview](#)

Research article

Functional outcome of open acromioclavicular joint stabilization for instability following distal clavicle resection

Jonathan A. Baxter, Joideep Phadnis, Paul M. Robinson, Lennard Funk

Pages 761-764



[Purchase PDF](#)

[Article preview](#)

Research article

A comparison of two different navigated hip replacement techniques on leg length discrepancy

T.N. Jennison, P. Craig, Edward D. Davis

Pages 765-767



[Purchase PDF](#)

[Article preview](#)

Review article

A review of literature: Mosaicoplasty as an alternative treatment for resection of patellar osteoid osteoma and cartilage reconstruction

Motasım K. Bavaneh, Gorkem Kiyak, Tevfik Balikci

Pages 768-771

[Purchase PDF](#)[Article preview](#) Research article

Fresh frozen femoral head osteochondral allograft reconstruction of the humeral head reverse hill sachs lesion

L.E. Murphy, A. Tucker, A.P. Charlwood

Pages 772-775

[Purchase PDF](#) Review article

Calcifying Tendinitis of Shoulder: A Concise Review

Balaji Umamahesvaran, Senthil Nathan Sambandam, Varatharaj Mounasamy, Ponnusami Pillai Gokulakrishnan, Munis Ashraf

Pages 776-782

[Purchase PDF](#)[Article preview](#) Review article

Arthroscopic acetabular labral reconstruction with rectus femoris tendon autograft: Our experiences and early results

Ritesh Rathi, Jacek Mazek

Pages 783-786

[Purchase PDF](#)[Article preview](#) Research article

The 3-dot circle: A reliable method for safe and efficient digital templating of the acetabular component

Firas Arnaout, Varun Dewan, Christos Paliobeis

Pages 787-791











[Purchase PDF](#)[Article preview](#) Research article











Functional outcome of arthroscopic double row repair for Bankart lesion

Roshan Wade, Bhanuprakash Reddy P V

Pages 792-797

[Purchase PDF](#)[Article preview](#)

- Research article
Mortality in patients sustaining a periprosthetic fracture following a hemiarthroplasty
Toby Jennison, Rathan Yarlagadda
Pages 798-801
 [Purchase PDF](#) [Article preview](#) 
- Research article
The effect of C-arm fluoroscope on unicompartmental knee replacement arthroplasty
Hee-Gon Park, Kun-Woong Yu, Sung-Hyun Kim, Dong-Ho Lee
Pages 802-807
 [Purchase PDF](#) [Article preview](#) 
- Review article
Eosinophilic granuloma of the spine involving C1 and pulmonary infiltration in young children – Presentation of two cases with a follow-up over 10 years including review of the literature
Tugrul Kocak, Benjamin Ulmar, Heiko Reichel, Sebastian Weckbach
Pages 808-811
 [Purchase PDF](#) [Article preview](#) 
- Review article
Are non-steroidal anti-inflammatory drug injections an alternative to steroid injections for musculoskeletal pain?: A systematic review
Vandit Sardana, Joanna Burzynski, Khaled Hasan, Paul Zalzal
Pages 812-816
 [Purchase PDF](#) [Article preview](#) 
- Research article
Morbid obesity and 1-year costs after elbow dislocation
Dhanur Damodar, Derek D. Berglund, Rushabh M. Vakharia, Dragomir Mijic, ... Jonathan C. Levy
Pages 817-819
 [Purchase PDF](#) [Article preview](#) 

- Research article
Flatfoot and normal foot a comparative analysis of the stress shielding
V. Filardi
Pages 820-825
 [Purchase PDF](#) [Article preview](#) 
- Short communication
Primary intra-articular epithelioid sarcoma of the knee: Unusual presentation of a rare entity
P.E. Flikweert, T.L. Bollen, M.J.G.M. Speth, N. Wolterbeek, L. Timmerman
Pages 826-828
 [Purchase PDF](#) [Article preview](#) 
- Research article
Outcomes of internal fixation of intracapsular hip fractures using dynamic locking plate system (Targon[®] FN)
Hosam E. Matar, Prakash Chandran
Pages 829-831
 [Purchase PDF](#) [Article preview](#) 
- Review article
Cubital tunnel syndrome: Anatomy, clinical presentation, and management
Kyle Andrews, Andrea Rowland, Ankur Pranjal, Nabil Ebraheim
Pages 832-836
 [Purchase PDF](#) [Article preview](#) 
- Research article
Knee dislocation with popliteal artery disruption: A nationwide analysis from 2005 to 2013
Qais Naziri, George A. Beyer, Neil V. Shah, Maximillian Solow, ... William P. Urban
Pages 837-841
 [Purchase PDF](#) [Article preview](#) 
- Research article
Prognostic factors that predict failure of manipulation under anesthesia for the stiff total knee arthroplasty: A systematic review

Alex Gu, Adam J. Michalak, Jordan S. Cohen, Jeffrey G. Stepan, ... Peter K. Sculco

Pages 842-846

 [Purchase PDF](#) [Article preview](#) 

Research article

Patient reported and clinical outcomes of robotic-arm assisted unicondylar knee arthroplasty: Minimum two year follow-up

J. Melvin Deese, Gwen Gratto-Cox, Denny A. Carter, Thomas M. Sasser, Karah L. Brown

Pages 847-853

 [Purchase PDF](#) [Article preview](#) 

Research article

WNT16 induces proliferation and osteogenic differentiation of human perivascular stem cells

Carolyn A. Meyers, Jia Shen, Amy Lu, Aaron W. James

Pages 854-857

 [Purchase PDF](#) [Article preview](#) 

Research article

Proximal fibula osteotomy as an alternative to TKA and HTO in late-stage varus type of knee osteoarthritis

Dwikora Novembri Utomo, Ferdiansyah Mahyudin, Agung Malinda Wijaya, Lukas Widhiyanto

Pages 858-861

 [Purchase PDF](#) [Article preview](#) 

Research article


The use of a subacromial spacer-inspace balloon in managing patients with irreparable rotator cuff tears

Rahi Kiran Yallapragada, Alex Apostolopoulos, I. Katsougrakis, T.P. Selvan

Pages 862-868

 [Purchase PDF](#) [Article preview](#) 

ISSN: 0972-978X



Proximal fibula osteotomy as an alternative to TKA and HTO in late-stage varus type of knee osteoarthritis

Dwikora Novembri Utomo^{*}, Ferdiansyah Mahyudin, Agung Malinda Wijaya, Lukas Widhiyanto

Department of Orthopedics & Traumatology Dr. Soetomo General Hospital / Universitas Airlangga, Surabaya, Indonesia

ARTICLE INFO

Keywords:

Proximal fibular osteotomy
Osteoarthritis
Varus type
Knee problem

ABSTRACT

Background: Knee osteoarthritis has a high prevalence in Indonesia. Aim of this research is knowing the outcome of knee osteoarthritis patient after PFO procedure.

Methods: Data collected and analyzed in hospitals in Surabaya from July to December 2017. This study compares preoperative and postoperative outcome on radiological evaluation, patient satisfaction, and clinical function.

Results: The study includes 15 patients. Radiological evaluation on Tibiofemoral Angle and Joint Space Ratio increases significantly. Patient satisfaction evaluation using SF12 significantly improve. Evaluation using KOOS and Oxford Knee Score also increase significantly.

Conclusion: PFO could become an alternative treatment for last stage knee osteoarthritis.

1. Introduction

Osteoarthritis (OA) of the knee joint, is a chronic progressive degenerative disease, accompanied by joint pain, joint stiffness, and deformity.¹ The prevalence of knee OA in Indonesia is also quite high at 15.5% and 12.7% in men and women respectively.² Factors leading to the progression of OA are mechanical, structural, genetic, and environmental factors.³

Total Knee Arthroplasty (TKA), which is a gold standard treatment for late-stage OA, and High Tibial Osteotomy (HTO) are commonly used procedures for OA of the knee. However, these procedures are relatively costly, complex and unsuitable either for young patients or patients with severe comorbidities that have the potential to cause complications or even death at the time and postoperatively.^{4,5} HTO also has some disadvantages including the delay of patients undergoing full-weight bearings (FWB), increased risk of nonunion and delayed union, peroneal nerve paralysis and surgical wound infection (SSI).^{6,7} Several other surgical procedures have been developed to prevent the progression of OA, including Proximal Osteotomy Fibula (PFO).

Zhang et al., in 2015 have succeeded in discovering PFO techniques as a new surgical technique to significantly relieve pain in a relatively short time to improve joint function, to allow postoperative ambulation conditions, and to restore joint space on the medial side of the knee. PFO also improves the alignment of lower limb alignment in some

patients, especially in those with severe varus knees. Compared to TKA or HTO, PFO is a simple, safe, quick, and requires no additional implant insertion. Therefore, PFO could be an alternative procedure in most developing countries that are still constrained by funding and advanced instrumentation.⁵

Using a knee joint model with 3D finite element method, Maeyama et al. found that the contact of the lateral plateau pressure increased post-osteotomy of the fibula. This hypothesized that fibular osteotomy may reduce the pressure on the medial plateau so that pain in knee OA is reduced.⁸ Prakash in 2015 also states a correlation between the proximal fibular osteotomy in cases of proximal fibular fracture with the result of a decrease in pain due to significant OA.⁹ This finding is also supported by a study by Yang et al. in which long-term pain reduction is accompanied by changes in radiological features.

Based on the existing data, this study was conducted to determine the effectiveness of PFO procedures on the outcome of high-grade OA patients. Simple proximal fibula osteotomy (PFO) is expected to be an alternative solution for knee OA patients who can not undergo HTO or TKR surgery for various reasons.

2. Methods

This study was an observational analytic with prospective form, which was evaluated on samples of patients with radiological OA of the

^{*} Corresponding author. Jl. Manyar Tirtosari IV/7, Surabaya, East Java, Indonesia.

E-mail addresses: dwikora-novembri-u@fk.unair.ac.id (D.N. Utomo), ferdiansyah@fk.unair.ac.id (F. Mahyudin), agungmal96@gmail.com (A.M. Wijaya), lukas-w@fk.unair.ac.id (L. Widhiyanto).

<https://doi.org/10.1016/j.jor.2018.08.014>

Received 6 June 2018; Accepted 3 August 2018

Available online 16 August 2018

0972-978X/ © 2018 Prof. PK Surendran Memorial Education Foundation. Published by Elsevier, a division of RELX India, Pvt. Ltd. All rights reserved.

knee who would be compared with the clinical appearance of the patient. Sampling was done in total sampling to the research population of knee OA stage 4 varus type who performed PFO at one of the hospitals in Surabaya in the period July 2017 to December 2017.

Inclusion criteria include: all patients who performed PFO within the period from July 2017 to December 2017; patients with complete medical record data on identity, physical examination results, and postoperative scores may be performed for the function of the knee; and knee OA patients with a classification of stage 4 varus type who were unfit for TKA or HTO due to severe comorbidity. Exclusion criteria include patients who refused treatment and could not do the clinical evaluation. Criteria for drop out are patients who do not control and refuse to be evaluated.

Stages of preparation of research by performing complete patient data collection according to inclusion criteria, then the patient was called to the outpatient clinic or visit the patient directly with a home visit to evaluate clinically and assess SF12, KOOS, and Oxford Knee Score. Data of examination and counting result are grouped, presented in tabulation form, and analyzed descriptively. For inferential analysis using SPSS 23 program. The analytic statistics in this study used paired *t*-test for femorotibial angle outcomes and Joint Space Ratio on radiological evaluation, and SF12, KOOS, and Oxford Knee Score scores on patient satisfaction evaluation and clinical knee functionality (see Figs. 1 and 2).

3. Results

There were 15 patients with knee osteoarthritis degree 4 varus type performed PFO action from July 2017 to December 2017. We obtained 4 men patients (26.7%) and 11 women patients (73.3%) with an average age of 61.47 ± 8.34 years.

The mean measurement of preoperative tibiofemoral angle of $181.28^\circ \pm 1.88^\circ$ and Joint Space Ratio (distance medial space (mm)/lateral space (mm)) of 0.40 ± 0.02 . The postoperative rate of $177.33^\circ \pm 2.06^\circ$ and Joint Space Ratio of 0.57 ± 0.04 .

The average preoperative SF12 score of 23.20 ± 1.74 . KOOS calculation results are divided into 5 scores, namely: KOOS Pain score, KOOS Symptom score, KOOS ADL score, KOOS Sports score, and KOOS QOL score. The mean score of preoperative POS score was 39.98 ± 2.60 ; KOOS Symptom preoperative score of 40.91 ± 3.55 , KOOS ADL preoperative score of 47.64 ± 2.58 , KOOS Sport preoperative score of 33.36 ± 2.32 , and KOOS QOL preoperative score of 38.81 ± 1.20 . The mean score of the Oxford Knee Score Preoperative

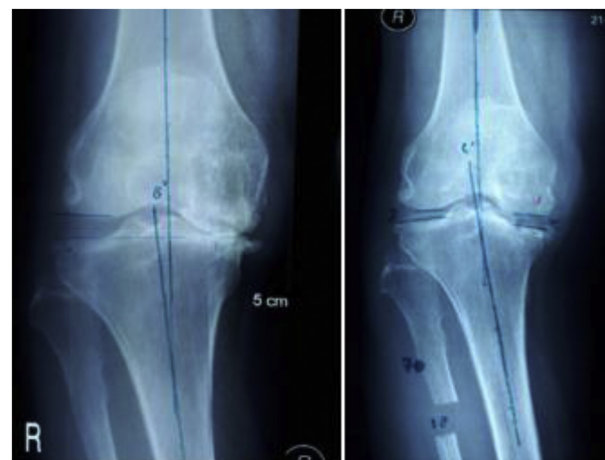

Fig. 2. Pre and postoperative comparison PFO knee results taken from one of the patients sample, female 63 years old.

Questionnaire was 25.66 ± 4.18 .

The mean postoperative SF12 score was 38.06 ± 3.51 . Calculation results average score of postoperative POS scores was 89.24 ± 1.35 ; KOOS Symptom postoperative score of 86.44 ± 1.41 , KOOS ADL postoperative score of 82.28 ± 1.07 , KOOS Sport postoperative score of 85.36 ± 0.88 , and KOOS QOL postoperative score of 87.93 ± 0.80 . The mean score of the Oxford Knee Score postoperative Questionnaire was 36.80 ± 3.00 (see Table 1).

4. Discussion

Knee osteoarthritis is one of the joint disorders that often occur and cause severe pain that leads to impaired mobility. Total Knee Arthroplasty (TKA) is an effective therapy in reducing pain and improves knee function in patients with end-stage osteoarthritis. However, TKA is an expensive and complex procedure and some patients require multiple revisions.¹⁰

In addition, there is another procedure called High Tibial Osteotomy (HTO). This procedure is a surgical treatment option for young patients with osteoarthritis in the medial compartment part of the knee.¹¹ Lack of this procedure is a long time before patients undergo full weight bearing rehabilitation and risk for non-union and delayed union, peroneal nerve paralysis, and wound infections.¹²

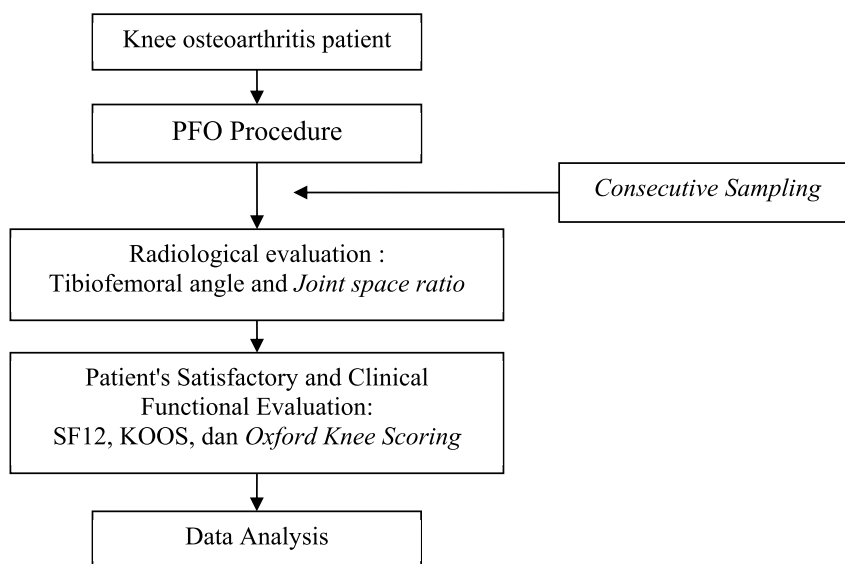


Fig. 1. Research scheme.

Table 1
Frequency distribution of Proximal Fibular Osteotomy patient characteristics.

Patient Characteristics	Total	
Sex		
Male	4 (26,7%)	
Female	11 (73,3%)	
Age (yaers)	61,47 ± 8,34	
Examination	Preoperative (mean ± sd)	Postoperative (mean ± sd)
Tibiofemoral Angle	181,28° ± 1,88°	177,33° ± 2,06°
Joint Space Ratio	0,40 ± 0,02	0,57 ± 0,04
SF12 Daily Living Score	23,20 ± 1,74	38,06 ± 3,51
KOOS Pain Score	39,98 ± 2,60	89,24 ± 1,35
KOOS Symptom Score	40,91 ± 3,55	86,44 ± 1,41
KOOS ADL Score	47,64 ± 2,58	82,28 ± 1,07
KOOS Sport Score	33,36 ± 2,32	85,36 ± 0,88
KOOS QOL Score	38,81 ± 1,20	87,93 ± 0,80
Oxford Knee Score	25,66 ± 4,18	36,80 ± 3,00

Proximal Fibular Osteotomy (PFO) becomes the new choice of surgical procedure to reduce pain and improve joint function in patients with knee osteoarthritis as reported by Zhang et al. (2015). The most interesting is this procedure increases pain reduction in the medial part and increases the medial joint space.¹³

Bone mass decreases as part of the normal aging process.¹³ Variations in the rate of bone mass composition are in joints used as load bearings, such as knees, hips, ankles, and spine. In the proximal tibia, lateral fibular support to the lateral tibial plateau usually leads to a non-uniform arrangement. The involved part is more severe in the medial plateau than in the lateral plateau. The slope of the tibial plateau arising from uniform deviations results in a transverse shear force, with the femoral condyle shifting medially during walking and exercise.¹⁴ Furthermore, side-slip exacerbates the uniform arrangement of the tibial plateau, especially in the medial plateau. Thus, an increasing cycle of load distribution in the medial compartment and non uniform arrangement occurs. There is also evidence that tibiofemoral articular stress distribution is associated with knee OA occurrence.⁵ Lateral support of the fibula to the tibial plateau is a key factor causing non-uniform arrangement of bilateral plateau and medial shift of the mechanical axis, resulting in degeneration and varus abnormalities of the knee joint.¹⁵

Zongyou et al. (2015) reported the use of proximal fibular osteotomy procedures as effective as high tibial osteotomy. From the above mechanism, our study looked at the tibiofemoral angle in patients undergoing proximal fibular osteotomy procedures.¹⁵ We found in our patients there were significant differences in tibiofemoral angle before and after action ($p < 0.001$). We obtained improvement from the tibiofemoral angle in patients who performed proximal fibular osteotomy procedures. The mean of tibiofemoral angle of the patient decreases significantly so that the varus deformity is reduced. This is in line with the results of a study reported by Zongyou et al. (2015) at the patient's follow-up there was a significant decrease after proximal fibular osteotomy procedure.¹⁵

The radiological evaluation performed in addition to the tibiofemoral angle is the measurement of the joint space ratio to observe the narrowing of the joint gap. In our study, we found a statistically significant increase in joint space ratio in patients who had performed proximal fibular osteotomy ($p < 0.001$) procedures. Zongyou et al. reported that the ratio of increased joint space improved significantly statistically.¹⁵ The improved radiological evaluation results will provide a good clinical evaluation because of the structural improvements of the deformity will decrease the pain of the patient's knee. Nevertheless, the proximal fibular osteotomy fixation mechanism cannot yet be fully explained. One theory holds that the improvement of the joint space and the tibiofemoral angle occurs because the fibula that serves as the support of the lateral part is removed. The fibula that causes

varus genus in this case has a role to support one-sixth of body weight. Proximal procedure of fibular osteotomy re-stabilizes or distributes the load to the lateral and medial portions of the tibial plateau after surgery.¹⁴

Structural improvements achieved after the PFO are highly likely to enable functional improvement of the patient's knee. In our study, we looked at the results of clinical evaluation for the level of daily satisfaction of patient using SF-12 Daily Living Score. There was a statistically significant difference in the value of SF-12 Daily Living Score in patients after proximal fibular osteotomy ($p \leq 0.001$). There is an increase in the value of SF12 Daily Living Score, which indicates an increase in patient satisfaction with improved knee pain.

We observed also from the patient's knee function by evaluating the value of KOOS and Oxford Knee Score. There was an increase in knee function according to re-evaluation using the KOOS score in osteoarthritis patients who had undergone surgery. We found a statistically significant difference in the KOOS five score: KOOS Pain score, KOOS Symptom score, KOOS ADL score, KOOS Sports score, and KOOS QOL score in patients after proximal fibular osteotomy ($p \leq 0.001$).

To provide further confirmation we evaluate using Oxford Knee Score. Knee function in patients increases according to the Oxford Knee Score assessment after this procedure is performed. There was a statistically significant difference in the value of Oxford Knee Score in patients who had performed proximal fibular osteotomy procedure ($p \leq 0.001$). Patients can undergo better knee function than before surgery.

From our research, we can see that there is a correlation between the improvement of the structural knee joint with the patient's knee function in accordance with the theory. As the patient's knee function improves, patient satisfaction with daily life increases.

This study shows that proximal fibular osteotomy is a simple, safe, quick and affordable surgical procedure to reduce pain in the knee of end-stage osteoarthritis patients. In accordance with the previous article, the procedure of proximal fibular osteotomy can be used as an alternative to total knee replacement and high tibial osteotomy procedures. In addition, patients can still undergo a total knee replacement if needed. However, there are some shortcomings from this study in the form of a poor sample, the absence of comorbid control of the patient, and the absence of complete information on the patient's initial condition. This may be a reference for further research and requires experimental or prospective research for proximal fibular osteotomy procedures.

The proximal fibular osteotomy technique can be an alternative treatment option in patients with late-stage osteoarthritis. This is evident from the improvement of the 4 assessment parameters, namely: tibia-femoral angle after PFO is smaller than before the procedure, thereby reducing the varus deformity; Joint space ratio after PFO is greater than before the procedure, so that the medial joint cleft widened; increasing patient subjective score on SF 12 Daily Living Score; as well as increased functional scores of patients using KOOS and Oxford Knee Score. More studies are needed to further strengthen existing findings, including using larger sample quantities, and by randomized double-blind controlled trial or prospective research to reduce biases and errors in the study.

Conflicts of interest

The authors declare no conflict of interest in this study.

Funding/support statement

This research did not receive any specific grant from funding agencies in the public, commercial, or not-for-profit sectors.

Acknowledgment

None.

References

1. Focht BC. Move to improve: how knee osteoarthritis patients can use exercise to enhance quality of life. *ACSM's Health & Fit J.* 2012;16:24–28.
2. Soeroso J, Isbagio H, Kalim H, Broto R, Pramudiyo R. *Osteoarthritis, Buku Ajar Ilmu Penyakit Dalam.* Jakarta: Edisi Pertama. Internal Publishing; 2009 h.2539-2549.
3. Vincent KR, Conrad BP, Fregly BJ, Vincent HK. The pathophysiology of osteoarthritis: a mechanical perspective on the knee joint. *PM&R.* 2012;4(5):S3–S9.
4. Paknikar S. *Knee Replacement Surgery.* <http://www.medindia.net/surgicalprocedures/knee-replacement-surgery-indications-and-contraindications.htm> Accessed 10 March 2018.
5. Zhang YZ. Innovations in orthopedics and traumatology in China. *Chin Med J.* 2015;128(21):2841–2842.
6. Sprenger TR, Doerzbacher JF. Tibial osteotomy for the treatment of varus gonarthrosis. Survival and failure analysis to twenty-two years. *J Bone Joint Surg Am.* 2003;85-A(3):469–474.
7. W-Dahl A, Robertsson O, Lidgren V. Surgery for knee osteoarthritis in younger patients. *Acta Orthop.* 2010;81(2):161–164.
8. Maeyama A, Hagio T, Osawa T, et al. *The Effect of Fibular Osteotomy on Contact Pressure of the Knee Joint.* 2017; 2017 ISAKOS Biennial Congress ePoster #1528.
9. Prakash L. Prakash fibular osteotomy for unicompartmental knee osteoarthritis. *10th Global Orthopedicians Annual Meeting.* July 02-04, 2017; July 02-04, 2017 Kuala Lumpur, Malaysia.
10. Yang ZY, Chen W, Li CX, et al. Medial compartment decompression by fibular osteotomy to treat medial compartment knee osteoarthritis: a pilot study. *Orthopedics.* 2015;38(12):e1110–e1114.
11. Duivenvoorden T, Brouwer RW, Baan A, et al. Comparison of closing-wedge and opening-wedge high tibial osteotomy for medial compartment osteoarthritis of the knee: a randomized controlled trial with a six-year follow-up. *J Bone Joint Surg Am.* 2014;96:1425–1432.
12. Laprade RF, Spiridonov SI, Nystrom LM, Jansson KS. Prospective outcomes of young and middle-aged adults with medial compartment osteoarthritis treated with a proximal tibial opening wedge osteotomy. *Arthroscopy.* 2012;28(3):354–364.
13. Zhang Y, Li C, Li J, et al. The pathogenesis research of non-uniform settlement of the tibial plateau in knee degeneration and varus. *J Hebei Med Univ.* 2014;35(2):218–219.
14. Segal NA, Anderson DD, Iyer KS, et al. Baseline articular contact stress levels predict incident symptomatic knee osteoarthritis development in the MOST cohort. *J Orthop Res.* 2009;27(12):1562–1568.
15. Zong-You Yang MD, Wei Chen MD, Cun-Xiang Li MD, et al. Medial compartment decompression by fibular osteotomy to treat medial compartment knee osteoarthritis: a pilot study. *Slack incorporated.* 2015;38(12):e1110–e1114.