



International Journal of Sciences: Basic and Applied Research (IJSBAR)

ISSN 2307-4531
(Print & Online)

<http://gssrr.org/index.php?journal=JournalOfBasicAndApplied>



Detection of the Level of Matrix Metalloproteinase-1 in Breast Cancer Patients

Muna Ahmed Abdullah*

College of Dentistry, Tikrit University

Email: munaabdulla@tu.edu.iq

Abstract

Matrix metalloproteinase-1 MMP1 has attracted interest in cancer research, owing to its role in tumour progression. The current study aimed to evaluate the expression of matrix metalloproteinase-1 MMP1 in human breast cancer women patients. An immunohistochemical study was performed using tumours from 41 breast cancer patients, with specific antibodies against, MMP-1. The results indicated that expression was related to tumour size, histological grade, Regarding the malignant lesions, the age incidence in six cases below forty years were (19.37%). 23 patients (41.93%) were between (40-49) years. four cases (12.90%) were between (50-59) years old and eight cases were above (60) years old about (25.8%) matrix metalloproteinase-1 MMP1 is expressed in the cytoplasm of the cells. Negative expression scored (0) were observed in 25 out of 31 samples (48.3%), while score (+) found in 5 out of 31 samples (16.12%), score (++) found in 2 out of 31 samples (6.4%) and score (+++) found in 9 out of 31 samples (29%). While the benign breast lesions revealed positive expression in (5.26%) of lesions. Breast carcinomas in present work indicated overexpression strong by MMP1 marker.

Keywords: breast carcinoma; matrix metalloproteinase-1 MMP1; Immunohistochemical staining; Iraqi women patients.

* Corresponding author.

1. Introduction

the most common risk factor female malignancy in Iraq and worldwide was Breast cancer disease, recorded nearly million cases annually [1]. Breast tumors arise from terminal ductal lobular units, and divided in two phenotype first ductal carcinoma and the second lobular neoplasia [2]. Breast cancer disease based in the history of the family and the invasion and virulence based on molecular base, and also immunohistochemical like MMP 1 maker [3,4]. Iraqi Cancer Registry recorded reports summarized in : first the commonest type of malignancy in females and there is a general trend towards an increase in the frequency and the second the incidence of breast cancer in younger age group. The environment of the cell represented the site of tumor exists, which included extracellular matrix (ECM), immune cells, fibroblasts, surrounding blood vessels, signaling molecules and other cells in the tissue. There's closely relationship between microenvironment and tumor when tumors can effects in the microenvironment through extracellular signals releasing, peripheral immune tolerance inducing, and through tumor angiogenesis promoting [5]. The microenvironment of tumor cell treated angiogenesis through interfere with the required for cell recruitment and vascular construction signaling pathways. matrix metalloproteinase-1 (MMP1) have a correlation with cell metastasis and also recruited for angiogenesis under hypoxic conditions [6] this present work aimed to detection of matrix metalloproteinase-1 (MMP1) expression using immunohistochemical technique (IHC).

2. Methods

Immunohistochemical IHC staining method and evaluation of Immunohistochemistry results

1. Slide baking: the slides were placed in a 45° and Deparaffinization: in xylene for 15 minutes two times at room temperature.

3. Rehydration: the slides were immersed sequentially in the following solutions at room temperature starting with:

-Twice in absolute ethanol for 5 minutes.

-95% ethanol for 5 minutes.

-90 % ethanol for 5 minutes.

-80 % ethanol for 5 minutes.

-70 % ethanol for 5 minutes.

-Distilled water for 5 minutes.

4. Enough drops of hydrogen peroxide block were added to slides

5. Enough drops of protein block were added to slides and incubated at 37°C for 10 minutes.

6. Diluted primary antibody was applied to each slide,

7. Enough drops of secondary antibody (link antibody yellow drops) reagent were added and incubated in humid chamber for 20 minutes at 37°C.

The Positive reading result was appeared when the cytoplasmic pigmentation cells display a brown staining, while when cytoplasmic pigmentation absence of immunostaining the results for the cases consider negative reading. Cut off values for all the antibodies used in the study were done with the help of a pathologist. The scoring of the immunostaining was done under light microscope to evaluate the percentage of antibodies immunostaining; positively stained cells were counted at 5 representative fields (400X).

Immunohistochemical scoring of matrix metalloproteinase-1 MMP1 Anti –MMP1 antibody [ab3203]

matrix metalloproteinase-1 MMP1 [ab3203] over expression(positive) was seen in the cytoplasm of the subjected cell of breast cancer and in contrl benign cells and the scoring of positive tumor cell was considered as follows [7]: the percentage value pf intensity 0 =0-10% , 1+ =10-25%, 2+ =25-50%, 3+ =more than 50%.

3. Statistical Analysis

The values of positive expression of the studied marker parameters were represented by (mean \pm standard error), and person correlation using version 7.5 of computer program SAS. The value of probability ≥ 0.05 and 0.001[8].

4. Results and Discussion

Clinicopathological features show total of newly diagnosed, 41 Iraqi females patients with breast cancer had a mean age (42 \pm 7.35) years with a range of 33 to 72 years compared with 19 patients control (with benign breast lesions their mean age were (29.21 \pm 3.54) years with a range of (19 to 49 years). Regarding the malignant lesions, the age incidence in six cases below forty years were (19.37%).

13 patients (41.93%) were between (40-49) years. four cases (12.90%) were between (50-59) years old and eight cases were above (60) years old about (25.8%) as show in table (1).

In Benign Breast lesions, 16 cases (84.21%) were less than 40 years; 3 cases (15.7%) were 40-49 years and no cases aged more than 49 years, table (1).

The invasive breast carcinomas NOS type were graded according to the Nottingham histological grading (WHO and modified Bloom-Richardson grading system), 21 (67.7%) cases were grade II and 10 (32.2%) cases were grade III.

Table (1) reveals the stages of BC for 41 patients according to TNM system, 14 cases (45. 1%) were stages (I and II); 15 cases (48.3%) were stage III and 2 cases (6.45%) were stage IV.

Table 1: Clinicopathological characteristics of the breast cancer patients

Parameter	Malignant breast (41)	
Age (Years)	No.	%
<40	6	19.37
40-49	13	41.93
50-59	4	12.90
≥60	8	25.80
Tumor Type		
Invasive ductal carcinoma	31	100
Histological grade		
Grade II	21	67.7
Grade III	10	32.2
Staging system		
Stages I and II	14	45.1
Stage III	15	48.3
Stage IV	2	6.4

The presented results on Iraqi patients revealed that a high age frequency of cancer occurred between (40-49) years old (41.93%). This is due to causes such as environmental factors, the nutrition, low exercise, poor health education. The high dose exposure of depleted uranium during the war may be considering the most causative reason for breast cancer risk increasing in the Iraqi community. Also theirs no attention from the national screening programs for early diagnosis of breast cancer patients in all the country .Our results agreed with many studies in Iraq performed on breast cancer and revealed that the peak of age frequency in the Iraqi breast cancer patients was 44.5 years, and that 76.8% were under 50 years [9], showed that a mean age of the 48.7 years and that 32.6% of the cancer patients were in the peak age frequency of 40-49 years.

The middle aged and elderly women have a risk of breast cancer and consider higher in this ages when compared with young women. Thers strong correlation between age and breast cancer disease [10]. Breast cancer affects up to one in eight women in developed countries with a median age of 61 years at diagnosis. Approximately 2% of breast cancers occur in young women between 20 and 34 years of age and 11% between 35 and 44 years of age [11]. In USA during 2002-2006, 50% of women who developed breast cancer were at the age 61 or younger at the time of diagnosis [12] Although grading system could be variable because of its subjective nature, still it is one of the important parameter regarding prognosis evaluation [13]. Grading of the malignant cases was assessed according to the Nottingham Modification of the Bloom-Richardson system [14] . In this study, 67.7% were moderately differentiated (grade I) and 32.2% were poorly differentiated (grade III). In our study immunohistochemical techniques were used to detect the protein expression of matrix

metalloproteinase-1 MMP1 in the Iraqi breast tissues, among breast cancer groups and benign tumor groups

IHC expression of matrix metalloproteinase-1 MMP1

Matrix metalloproteinase-1 MMP1 is expressed in the cytoplasm of the cells, so it differs from the other studied markers which were nucleus expressed markers. Negative expression scored (0) were observed in 15 out of 41 samples (48.3%), while score (+) found in 5 out of 31 samples (16.12%), score (++) found in 2 out of 31 samples (6.4%) and score (+++) found in 9 out of 31 samples (29%). While the benign breast lesions revealed positive expression in (5.26%) of lesions as in Table (2). Statistical analysis of the matrix metalloproteinase-1 MMP1 expression showed high significant difference between the malignant breast samples expression and the benign samples (P <0.001). The figure (1).show the expression of matrix metalloproteinase-1 MMP1 in the membrane of ductal carcinoma stained by IHC (Brown stained membrane which indicates the positive expression matrix metalloproteinase-1 MMP1 and the negative expression showed no nucleus staining).

Table 2: Immunohistochemical of matrix metalloproteinase-1 MMP1 Expression in ductal carcinoma

Score group	0	+	++	+++	Total positive
Benign	18 (94.73%) A	0 (0%) B	0 (0%) B	1 (5.26%) C	1 (5.26%) from (19)
Malignant	15 (48.38%) AB	5 (16.12%) C	2 (6.45%) C	9 (29.03%) C	16 (51.6%) from(31)

*** P <0.001

Difference letters mean presence of significant difference.

Same letters mean there is no significant difference.

matrix metalloproteinase-1 MMP1 marker represented as putative cancer stem cells marker in breast cancer, the value of MMP1 expression mean that theirs important roles to MMP1 marker the in microenvironment of the tumor related to breast cancer. The results of our present study, represented by:

- 1- Evaluation of matrix metalloproteinase-1 MMP1 expression in the subjected studied cases of human breast carcinoma.
- 2- clinicopathological correlations with the studied markers determination.

Recent evidence has suggested that breast cancer originates from CSCs, which strongly express adhesion molecule matrix metalloproteinase-1 MMP1 [15]. The cell adhesion molecule matrix metalloproteinase-1 MMP1 is considered as a receptor for cell surface for glycosaminoglycan hyaluronic (HA) extracellular matrix,

these activities of studied immune marker lead to different important biological events through interactions between HA and matrix metalloproteinase-1 MMP1 these interaction lead to activation, inflammatory reactions, tumor dissemination embryogenesis, hematopoiesis and lymphocyte homing [16].

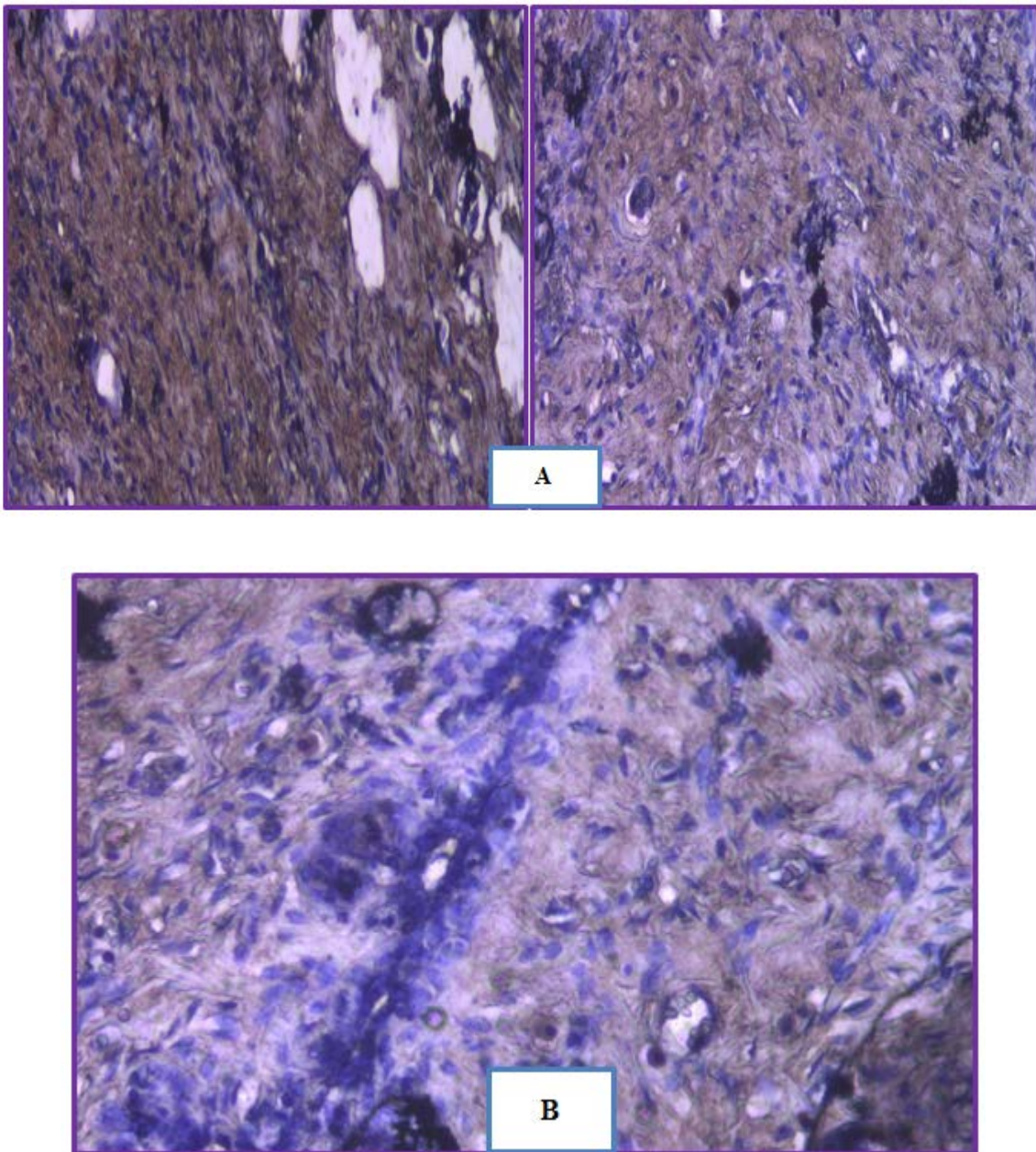


Figure 1: Immunohistochemical staining in breast cancer sections. immunostaining by peroxidase/ DAB (brown) counterstained with heamatoxyline (blue) , (A) positive matrix metalloproteinase-1 MMP1 expression(400X),(B) negative (no expression) for matrix metalloproteinase-1 MMP1 (400X).

Our results relatively agreed with the results obtained from Wang and his colleagues (2011) who study the expression of matrix metalloproteinase-1 MMP1 in invasive ductal carcinoma which expressed in (43.6%). And also they completely agree with [17] who revealed the matrix metalloproteinase-1 MMP1 marker was commonly expressed among primary breast carcinomas (51.2% of positive cases).

the important of matrix metalloproteinase-1 MMP1 marker expression lead to understanding the most important points in treatment of Cancer, therapeutic target, focus on the tumor microenvironment and non-malignant cells are more stable in genetic manner and have a phenotypes not evolve into drug resistant. The microenvironment of the tumor tissue appeared that theirs contribution lead to development of tumor. [18]. While the microenvironment of normal cell produce signaling lead to malignant cell growth inhibition, the cell proliferation in the tumor microenvironment support against development of cancer in synergistic manner [19,20].

5. Conclusion

Matrix metalloproteinase-1 MMP1 over expression in present studied cases lead to understand the importance of an altered microenvironment in tumorigenesis and nature of the molecular alterations underlying in treatment and suggesting molecular detection to the studied cases for more understanding[20].

References

- [1]. Al-Anbari, S.S. (2009). Correlation of the clinicopathological presentations in Iraqi breast cancer patients with the finding of biofield breast cancer diagnostic system (BDS), HER-2 and Ki-67 immunohistochemical expressions. Ph.D thesis, College of medicine, University of Baghdad.
- [2]. Al-Khafaji, A.J.; Al-Kelabi, L.H. and AL-Dujaily, E.A. (2010). HER-2/neu overexpression in correlation to Vascular Endothelial Growth Factor, grade and stage of Non other wised specified Invasive ductal carcinoma. *Al Qadisiah .Medical Journal*, 6(10):27-37.
- [3]. American Cancer Society, (2007). *Cancer Facts & Figures*. Atlanta, Ga: American cancer society. (Internet)
- [4]. Gudmundsdottir, K. and Ashworth, A. (2006).The roles of BRCA1 and BRCA2 and associated proteins in the maintenance of genomic stability. *Oncogene*.25(43): 5864-74.
- [5]. Hanahan, D. and Weinberg, R.A.(2011). Hallmarks of cancer.*Cell*, 144:646-67.
- [6]. Irwin, M.L. ; Smith, A.W.; McTiernan, A. ; Ballard-Barbash, R.; Cronin, K.; Gilliland, F.D.; Baumgartner, R.N.; Baumgartner, K.B. and Bernstein, L. (2008). Influence of pre-and postdiagnosis physical activity on mortality in breast cancer survivors: the health, eating, activity, and lifestyle study. *J.Clin.Oncol.*, 26(24): 3958-3964.
- [7]. Ricardo, S.; Vieira, A.F.; Gerhard, R.; Leitaõ, D.; Pinto, R.; Cameselle-Teijeiro, J.F.; Milanezi, F.; Schmitt,F. and Paredes, J.(2011). Breast cancer stem cell markers CD44, CD24 and ALDH1: expression distribution within intrinsic molecular subtype. *J. Clin .Pathol .*,64:937- 946.
- [8]. SAS users (2004). *Guide personal computer (ver.7) inst. Inc. Cary. Nc., USA*.
- [9]. Jain, R. K. (2005). Normalization of tumor vasculature: an emerging concept in antiangiogenic therapy. *Science*,307:58–62.
- [10]. Swanson, C.A.; Coates, R.J.; Malone, K.E.; Gammon, M.D.; Schoenberg, J.B. and Brogan, D.J. (1997).Alcohol Consumption and Breast Cancer Risk among Women under Age 40 Years.*Epidemiol.*, 8:231-237.
- [11]. Takeshita, S.; Kawamura, Y.; Takabayashi, H.; Yoshida, N. and Nonoyama, S.(2005). Imbalance in the

production between vascular endothelial growth factor and endostatin in Kawasaki disease. *Clin.Exp. Immunol.*, 139: 575–579.

- [12]. Wu, S.C.; Hotes, J.; Fulton J.P.; Chen, V.W.; Howe, H.L. and Correa, C. (2002). *Cancer in North America. NAACCR combined cancer j.*, vol.III. Pp.92-144.
- [13]. Yoshiji, H.; Gomez, D.E.; Shibuya, M. and Thorgeirsson, U.P. (1996). Expression of Vascular endothelial growth factor, its receptor, and other angiogenic factors in human breast cancer. *Cancer Res.*, 56:2013-2016.
- [14]. Zhao, J.; Yana, F.; Ju, H.; Tang, J. and Qin, J.(2004). Correlation between serum vascular endothelial growth factor and endostatin levels in patients with breast cancer. *Cancer Letters*, 204:87–95.
- [15]. Hery, C.; Ferlay, M.; Boniol, M. and Autier, P. (2008). Changes in breast cancer incidence and mortality in middle-aged and elderly women in 28 countries with Caucasian majority populations. *Ann. Oncol.*, 19(5):1009-18.
- [16]. Iraqi Cancer Board. Results of the Iraqi Cancer Registry (2008). Baghdad, Iraqi Cancer Registry Center, Ministry of Health, 2008
- [17]. Iraqi Cancer Board. Results of the Iraqi Cancer Registry (2004). Baghdad, Iraqi Cancer Registry Center, Ministry of Health, 2008
- [18]. Avwioro, O.G. (2010). *Histochemistry and tissue pathology, principles and techniques*. Claverianum press, Nigeria.
- [19]. Balasubramanian, S.P.; Cross, S.S.; Globe, J.; Cox, A.; Brown, N.J. and Reed, M.W.(2007). Endostatin gene variation and protein levels in breast cancer susceptibility and severity. *BMC Cancer*, 7:107.
- [20]. Brandy, A. (2004). Breast cancer. *Manual of Clin.Oncol.*,5: 233-253.