

TUBEROUS SCLEROSIS AND ANGIOMYOLIPOMAS OF THE KIDNEYS : A CASE REPORT

M. SEGASOTHY
AYE AYE YI
SIDIQ MOHAMED

SUMMARY

Tuberous sclerosis is a disease with a well known association with renal masses, both cysts and angiomyolipomas. Reported here is a case of a 26 year old woman who had, in addition to angiomyolipomas of the kidneys, adenoma sebaceum, paraungual fibromas, shagreen patches and cerebral tubers.

INTRODUCTION

Tuberous sclerosis is a hereditary disease showing a widespread disturbance of organogenesis affecting many parts of the body. In the most severe form, patients show the classical triad of mental retardation, epilepsy and adenoma sebaceum of the face. Many patients however exhibit incomplete forms of the disease ("formes frustes") in which many of the characteristic abnormalities are absent.

Renal angiomyolipomas may occur in 50 to 80 percent¹ of patients. They are composed of three main tissues: (1) abnormal thick-walled blood vessels with a tendency to haemorrhage, (2) smooth muscle, and (3) fat.² It is generally believed that all

three tissue components arise from embryonal cells in the kidney.

Renal cysts have also been recognized as an unusual manifestation of tuberous sclerosis in children. Renal carcinoma associated with tuberous sclerosis is extremely rare, and the mode of behaviour of these tumours may be unusual.³

CASE REPORT

A 26 year old female presented with colicky abdominal pain associated with vomiting, dysurea and frank haematuria of 4 days duration. There was no past history of renal disease, haematuria or tuberculosis. Since the age of one month, she had generalised epileptic convulsions and was also noted to be mentally retarded. Her fits ceased at the age of 12.

On examination, she was found to be mentally retarded and had adenoma sebaceum in a malar distribution, shagreen patches in the sacral and lumbar region, and paraungual fibromas. Fundoscopic examination was normal. She had bilaterally enlarged kidneys, the right being larger than the left.

Laboratory data included: Haemoglobin 7.2 g/dl, the blood film and serum iron studies indicating an iron deficiency anaemia, serum creatinine 110 $\mu\text{mol/l}$, urea 2.8 mmol/l and normal serum electrolytes.

Chest x-ray was normal. Skull x-ray showed discrete multiple irregular areas of calcification with areas of sclerosis in the vault and frontal bones. X-ray of feet showed irregular periosteal new bone formation along the shafts of the right second and third metatarsals and the second left metatarsal. X-ray of hands showed areas of sclerosis

M. Segasothy, M.R.C.P. (UK),
Department of Medicine,
Universiti Kebangsaan Malaysia.

Aye Aye Yi, M.B.B.S. (Rgn.), D.M.R.D. (Lond.),
Department of Radiology,
Faculty of Medicine,
Universiti Kebangsaan Malaysia.

Sidiq Mohamed, M.R.C.P. (UK), DTm & H (Lond.)
Dip. Ven. (Lond.), Department of Medicine,
Universiti Kebangsaan Malaysia.

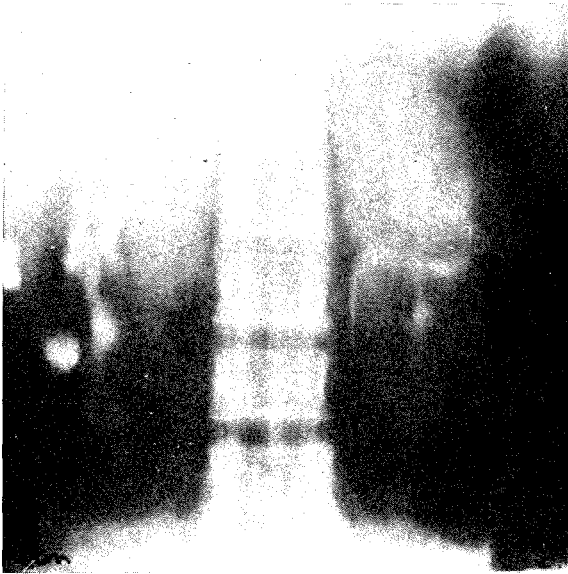

Fig. 1 Bilateral large kidneys with calyceal displacement and distortion by relatively radiolucent renal masses.

of the shaft of the left second metacarpal, the right second and third metacarpals and the proximal phalanges of the right index, middle and little fingers.

Intravenous urogram demonstrated bilaterally enlarged kidneys with relatively radiolucent areas stretching the calyces (Fig. 1). The collecting systems on both sides appeared relatively dilated but no obstruction was seen.

Free flush aortogram with bilateral selective renal angiogram demonstrated numerous highly vascular areas involving the lower two-thirds of the right kidney and the entire left kidney (Fig. 2). Nephrographic phase showed relatively translucent areas within the vascular area (Fig. 3, 4). The appearances are consistent with angiomyolipomatosis of both kidneys.

DISCUSSION

Features of tuberous sclerosis include the following:- (1) Cutaneous lesion (a) "Adenoma sebaceum", which are actually angiofibromas, in a butterfly distribution on the cheeks and nose. (b) "Shagreen patches", which are connective tissue naevi and clinically exhibit a "cobblestone" or "pigskin" appearance, most commonly occurring lumbosacraly. (c) Congenitally hypopigmented "ash leaf" macules mainly located on the trunk, visualization being enhanced by Wood's light. (d)

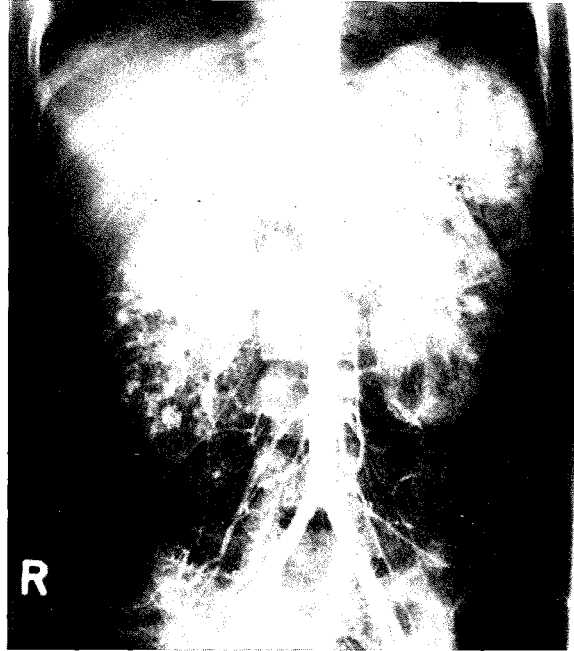


Fig. 2 Extensive vascularity of the entire right kidney except for a small normal portion in the upper pole. The left kidney shows numerous generalised vascular tumour vessels "Cock-Screw Vessels". No A-V shunting shown.

Cafe 'au lait' spots. (e) Periungual or subungual fibromas. (2) Cerebral involvement: sclerotic glial nodules, or tubers, develop in the basal ganglia and periventricular regions resulting in mental retardation and epilepsy. Skull x-rays may demonstrate circumscribed intra-cranial calcifications and electroencephalographic findings are abnormal in about 70 percent of cases. ⁴ Carotid angiography shows berry-like aneurysms in the tubers during the late arterial phase. ⁵ Pneumoencephalography shows characteristic "candle gutterings" in the lateral ventricles. Computerized tomography, which demonstrates the hamartomas well and is non-invasive and without risk, is likely to become the diagnostic method of choice to demonstrate central nervous system lesions. ⁶ (3) Retinal gliomas: are of two types, a peripheral lesion that is flat, white and circular and a nodular, mulberry-like lesion that occurs near the optic head. (4) Multiple visceral tumours: these are usually hamartomatous malformations, and may be found in the kidneys, heart, liver, adrenals, thyroid, lungs and ovaries. (5) Pulmonary involvement: multiple cystic lesions giving a honey-combed appearance, or intrapulmonary hamartomata. ⁷ (6) Skeletal lesions:

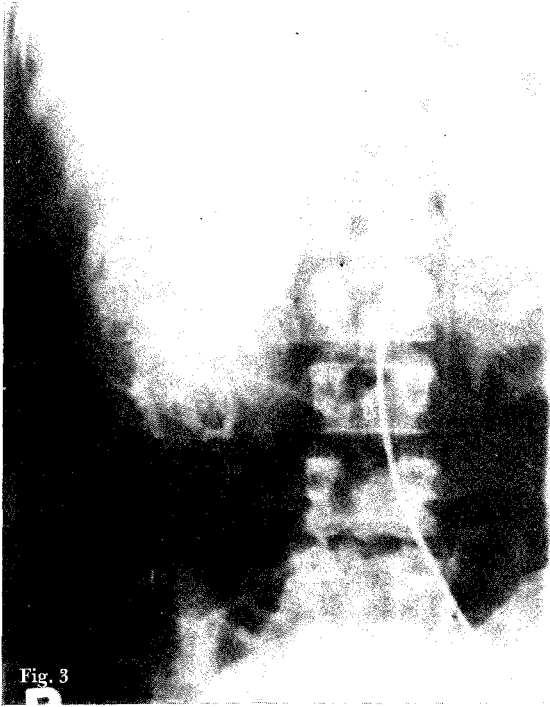


Fig. 3

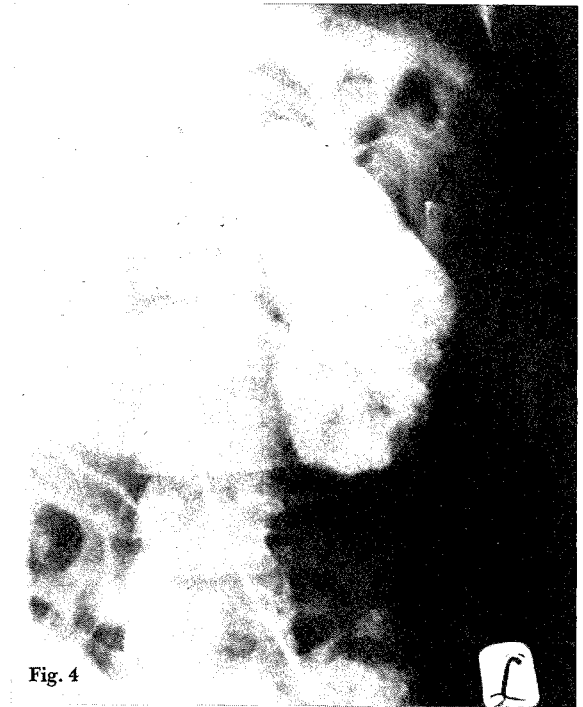

Fig. 4

Fig. 3, 4 Dense nephrograms intermixed with radiolucencies representing the fatty components of the angioliomatosis.

sclerotic islands may be seen in the skull and pelvic bones, or cystic lesions in the phalanges.⁸ (7) Stigmata common among mentally defective patients: the simian hand, hypertrophy or asymmetry of the ears, high arched palate, supernumerary digits, or shortening and incurving of the little finger. (8) Endocrine and metabolic abnormalities are varied and nonspecific and include goiter, hypothyroidism, Cushing's syndrome, low pituitary-adrenal reserve, abnormal glucose tolerance, precocious puberty, and adrenal hyperplasia.⁹ (9) A family history. (10) Increased IgM and decreased IgG levels.¹⁰

The most common renal involvement is angiomyolipomas and these can mimic polycystic disease on intravenous urography. Malignant transformation of angiomyolipomas as well as renal carcinoma have been reported in tuberous sclerosis.

Differentiation between angiomyolipomas and renal carcinomas can be difficult as they share some common angiographic findings. However, findings which are reported to be more characteristic for an angiomyolipoma include: (1) saccular aneurysmal dilatation of interlobar and interlobular arteries that look like a "cluster of grapes",¹¹ (2) circumferential peripheral tumour vessels.¹² (3)

"whorled onion peel" appearance in the nephrographic phase presumably related to the myomatous tissue present,¹³ (4) sharp delineation between the tumour and the normal kidney in the nephrographic phase, (5) thin radiolucent cleavage line around parts of the tumour peripherally,² and (6) lack of arteriovenous shunt and early venous filling.¹²

However it must be realized that these findings are not diagnostic for angiomyolipomas since they can occasionally be found in renal cell carcinoma and other lesions.¹²

Recently ultrasonic findings in patients with angiomyolipomas revealed renal masses that were very echogenic.¹⁵ The exact cause of the marked echogenicity of the angiomyolipomas is unknown but may be due to the fat within the tumour. Computed tomography may also demonstrate fat within the tumour. These two imaging methods may be helpful in differentiating renal cell carcinoma from angiomyolipomas.

As renal tumours in tuberous sclerosis are in most cases hamartomata, treatment should be conservative and surgical intervention reserved for cases with uncontrollable haematuria, infection, pain, or where the symptoms produced are due to

the size of the tumour. Percutaneous needle biopsy is not recommended because of the vascular nature of many of these tumours.

REFERENCES

- ¹ O'Callaghan T J, Edward J A, Tobin M, Mookerjee B K. Tuberos sclerosi with striking renal involvement in a family. *Arch. Intern Med.* 1975; 135: 1082.
- ² Bissada N K, White H J, Sun N C, Smith P L, Barbour G C, Redman J F. Tuberos sclerosi complex and renal angiomyolipoma. Collective review. *Urology* 1975; 6: 105-113.
- ³ Honey R J, Honey R M. Tuberos sclerosi and bilateral renal carcinoma. *Br. J. Urol.* 1977; 49: 441-446.
- ⁴ Lagos J C, Gomez M R. Tuberos sclerosi: reappraisal of a clinical entity. *Mayo Clin. Proc.* 1967; 42: 26-49.
- ⁵ Herz D A, Liebeskind A, Rosenthal A, Schechter M M. Cerebral angiographic changes associated with tuberos sclerosi. *Radiology* 1975; 115: 647.
- ⁶ Gomez M R, Mellinger J F, Reese D F. The use of computerized transaxial tomography in the diagnosis of tuberos sclerosi. *Mayo Clin. Proc.* 1975; 50: 553.
- ⁷ Hawkins T D. Radiological bone changes in tuberos sclerosi. *Br. J. Radiol.* 1959; 157-161.
- ⁸ Beck R E, Case Hammond R. Renal and osseous manifestation of tuberos sclerosi: case report. *J. Urol.* 1957; 77: 578-582.
- ⁹ Sareen C K, Ruvalcaba R H A, Scotvold M J, Mahoney C P, Kelley V C. Tuberos sclerosi: clinical, endocrine, and metabolic studies. *Am. J. Dis. Child* 1972; 123: 34.
- ¹⁰ Rundle A T, Atkin J, Dollimore J. Serum and tissue proteins in tuberos sclerosi. II Immunoglobulin levels. *Humagenetik* 1975; 28: 147.
- ¹¹ Viamonte M, Ravel R, Politano V, Bridges B. Angiographic findings in a patient with tuberos sclerosi. *AJR* 1966; 18: 723-733.
- ¹² Becker J A, Kinkhabwala M, Pollack H, Bosniak M. Angiomyolipoma (hamartoma) of the kidney. An angiographic review. *Acta Radiol (Diag.) (Stockh)* 1975; 14: 561-568.
- ¹³ Khilnani M T, Abrams R M, Beranbaum E R. Angiographic features of hamartoma of the kidney. *Radiology* 1968; 90: 994-1000.
- ¹⁴ Love L, Frank S J. Angiographic features of angiomyolipoma of the kidney. *AJR* 1965; 95: 406-408.
- ¹⁵ Beham M Kazam E. The echographic characteristics of fatty tissues and tumours. *Radiology* 1978; 129: 143-151.