



ISSN:
Electronic version: 1984-5685
RSBO. 2017 Jul-Sep;14(3):186-91

Case Report Article

CVDentus bur for epithelial abrasion in the treatment of melanin pigmentation: case report

Katiane Vieira Menezes Leite¹
Patrícia Oliveira de Souza¹
Jussania Fonseca da Paz¹
Ana Beatriz Franco Fernandes²
Leonardo Fernandes da Cunha²
Gisele Maria Correr²

Corresponding author:

Leonardo Fernandes da Cunha
Universidade Positivo
Rua Professor Pedro Viriato Parigot de Souza, n. 5.300 – Campo Comprido
CEP 81280-330 – Curitiba – Paraná – Brasil
E-mail: cunha_leo@me.com

¹ DeVry | School Facimp – Imperatriz – MA – Brazil.

² Program of Post-Graduation in Dentistry, Positive University – Curitiba – PR – Brazil.

Received for publication: June 20, 2017. Accepted for publication: July 27, 2017.

Keywords:

dental esthetic;
hyperpigmentation;
melanin.

Abstract

Introduction: The gingival melanin hyperpigmentation (GMH) is resulted from an abnormal deposition of melanin, but it is not a pathology. However, GMH is an esthetic problem for some people. Some alternatives of treatment for this situation exist. The epithelial abrasion has been an interesting alternative because it has a satisfactory esthetic outcome, is a fast procedure, of easy execution, and low cost. Recently, tips adapted in ultrasound (CVDentus) can be an alternative approach. **Objective:** To report a clinical case of GMH treated by the technique of the epithelial abrasion with association of instrument adapted in ultrasound. **Case report:** Patient aged 28 years, melanoderm, sought treatment due to esthetic dissatisfaction because of intense dark color in the maxillary gingiva. The GMH removal was proposed through the technique of the epithelial abrasion CVD bur. **Conclusion:** The technique of epithelial abrasion using CVD bur was effective in removing GMH at one-year follow-up showing to be easy and safe technique.

Introduction

Different types of oral pigmentation may be present in individuals [4]. The pigmentation can be caused by exogenous factors, such as the tattoos resulting from amalgam restorations, or endogenous, including hemoglobin, carotene, and melanin also known as melanin pigmentation [10].

Melanin pigmentation, the most frequent cause of oral pigmentation is common in populations of Africa, Asia, and the Mediterranean [6]. The gums are the intraoral location more often pigmented. Melanin is formed by cells called melanocytes, and the degree of pigmentation is dependent on the melanoblastic activity, and not on the increase in the number of melanocytes [9]. Clinically, melanin pigmentation is symmetric, asymptomatic, and does not alter the normal gingival architecture [4].

An esthetic dissatisfaction can be generated by the presence of melanin pigmentation. Different techniques can be employed to solve this situation. One of the most popular techniques is epithelial abrasion, gingivo-abrasion, or mucous-abrasion, in which the surface layer is removed [7]. It is a simple, fast, and low-cost procedure to be performed under infiltrative anesthesia. It can be performed with different instruments, such as scalpel blades or diamond tips.

Recently tips coupled with ultrasound devices are used. One of these alternative technologies was developed by the National Institute for space research (INPE), so-called Chemical Vapor Deposition (CVD). The diamond made from CVD technology is synthetically generated and has physical and chemical properties similar to those of natural diamond. The diamond formation process occurs directly on a molybdenum rod, using gases like methane in the presence of hydrogen, resulting in a single piece on the metal rod without need for methods of adhesion as the conventional diamond tips [15]. Among the various applications of CVD tips in dentistry are the esthetic situations in the soft tissue. In addition, different formats of tips are available so that the

dentist choose the format that best suited for each clinical situation.

This study aimed to describe the epithelial abrasion technique through CVC tips for treating melanin pigmentation.

Case report

Patient aged 28 years, melanoderm, sought treatment due to esthetic dissatisfaction because of intense dark color in the maxillary gingiva. After the diagnosis of melanin pigmentation, we proposed the removal of the pigmentation through the technique of the epithelial abrasion. The patient was informed on the procedures which she would be submitted.

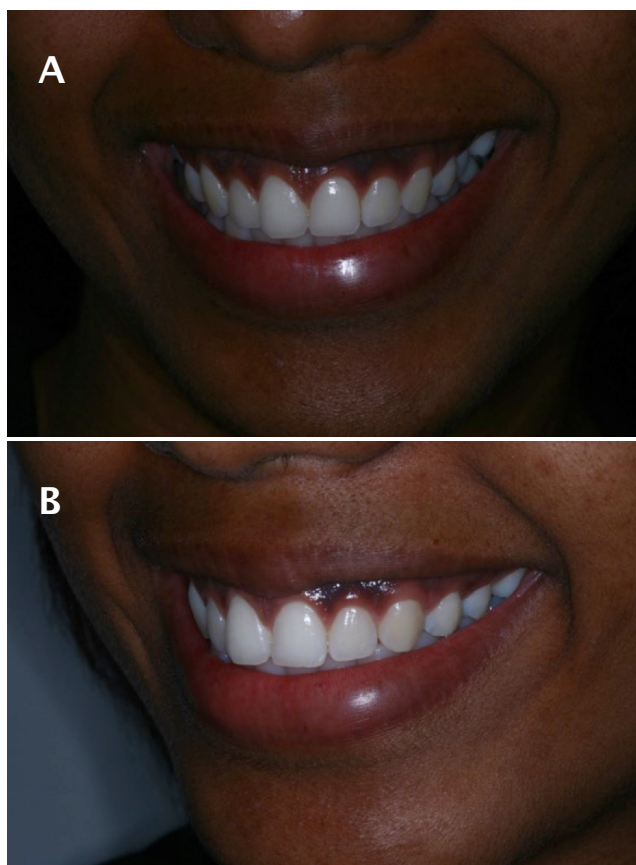

Figure 1 - Smile view evidencing presence of gingival melanin pigmentation

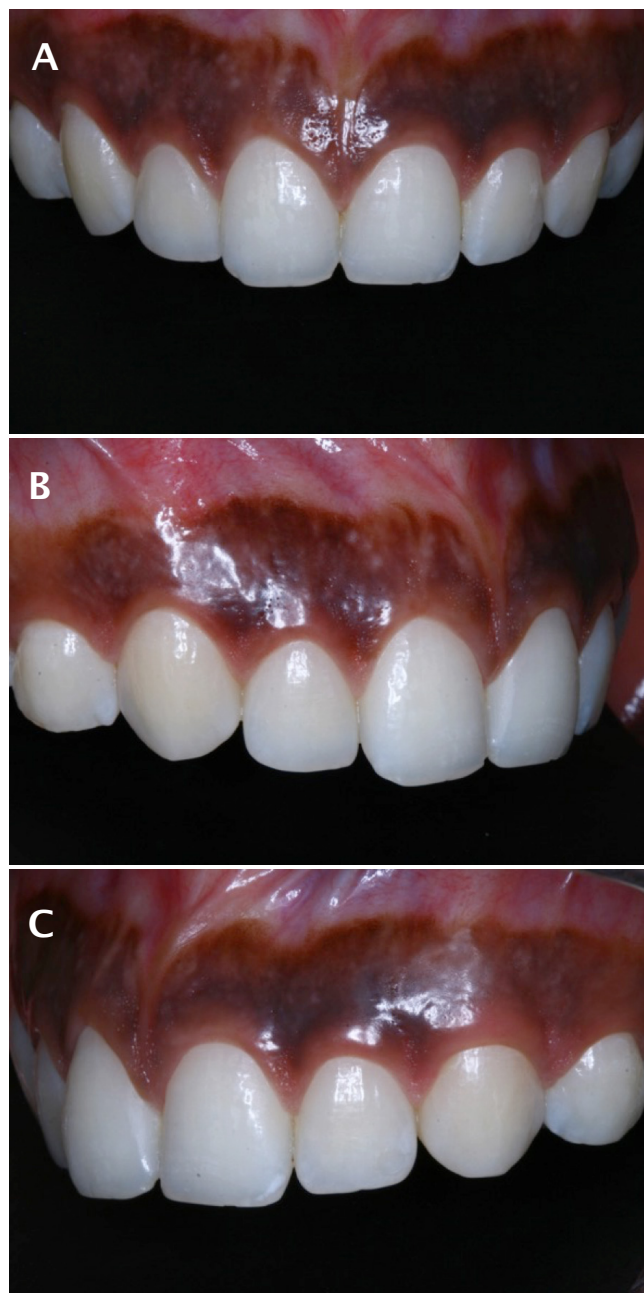


Figure 2 - (A) Pre-operative frontal clinical aspect; pre-operative clinical detail at right (B) and left side (C) demonstrating the pigmentation

After that, initial preparation was carried out by means of prophylaxis and pre-operative

intraoral antiseptics with chlorhexidine solution mouthrinse. The infiltrative anesthesia used local vasoconstrictor to favor the hemostasis.

The epithelial abrasion was initially carried through cylindrical long connector tip mounted in an ultrasound device with controlled speed and irrigation. During all the procedure the tip was softly moved on the gingival tissue through anterior-posterior movements to remove all the epithelial layer (figure 3A). The hemostat control was only carried through compression with gauze humidified with frozen physiological solution. The procedure was initially done on the right side and then, in the same appointment, on the left side (figure 3B). The initial healing after a few hours can be seen in figure 4.

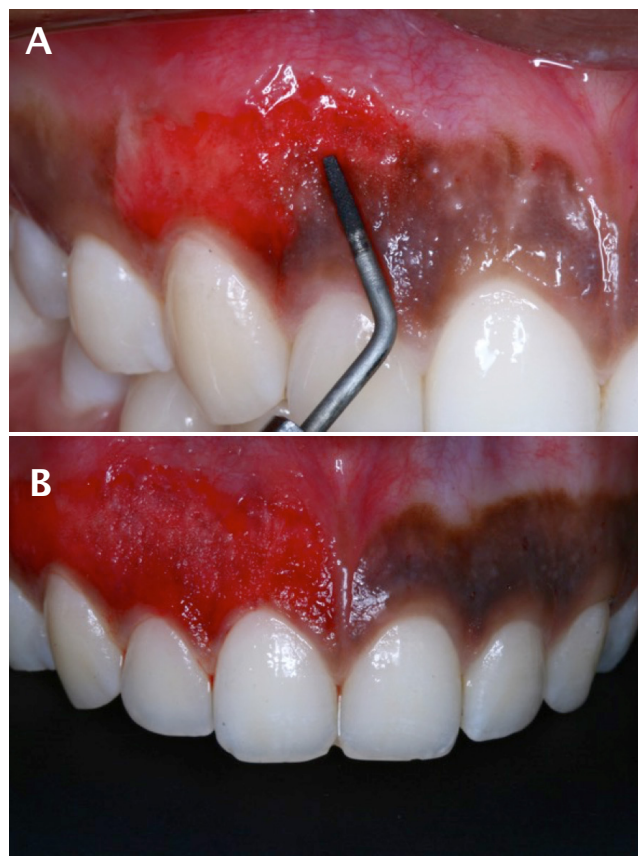


Figure 3 - (A) CVDentus Tip used for the procedure of epithelial abrasion; (B) postoperative clinical aspect of right maxillary arch

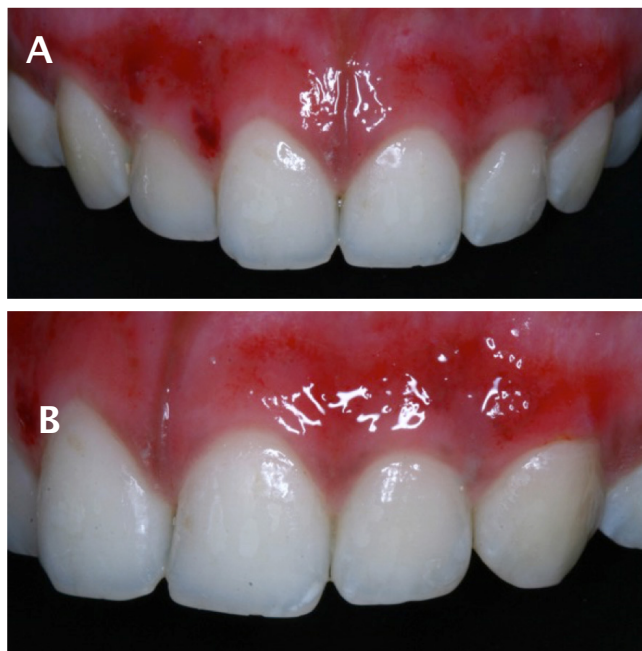


Figure 4 - (A) Clinical follow-up demonstrating favorable esthetics after initial healing; (B) Post-operative clinical detail at left side

The final esthetic result and 12-month treatment follow-up can be observed in figures 5 and 6.

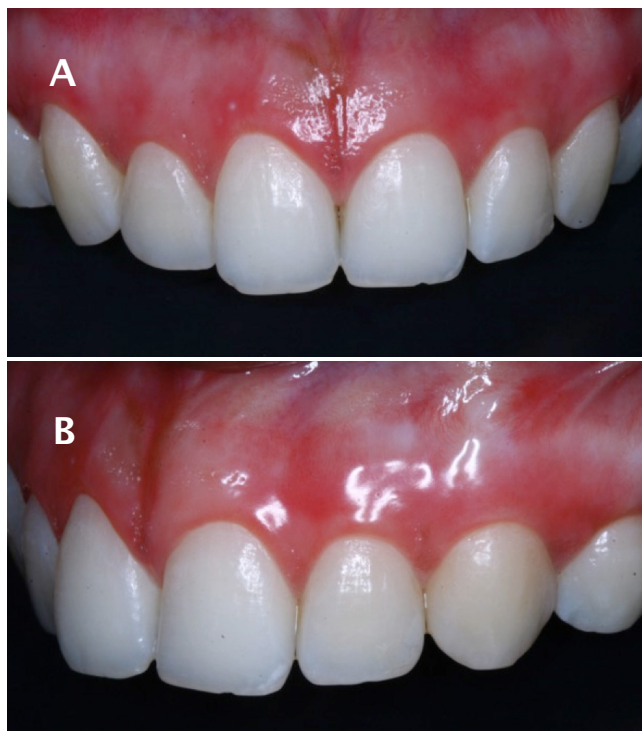


Figure 5 - 1-year clinical follow-up. Note that no recurrence occurred during this period and the health of periodontal tissues

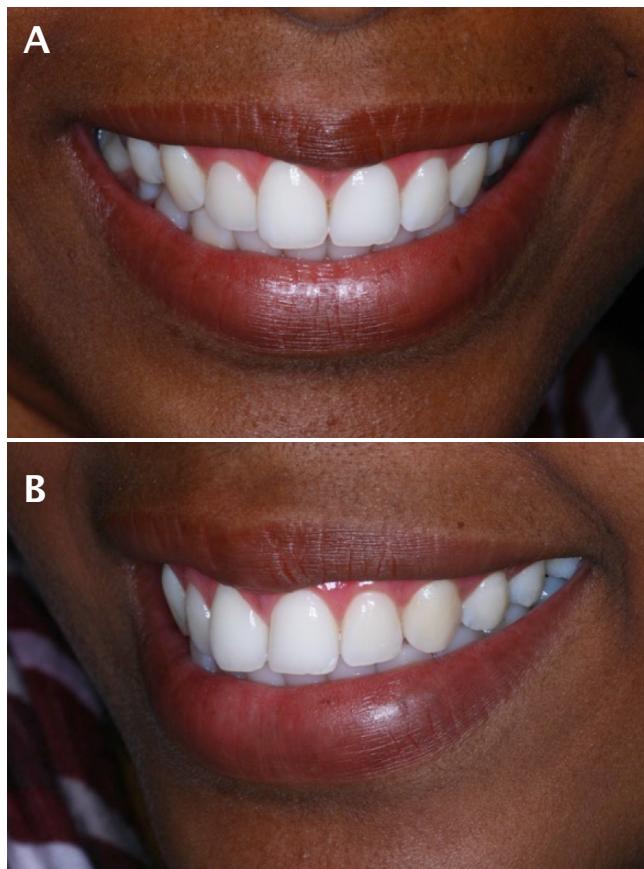

Figure 6 - Final outcome of smile at 1-year follow-up

Discussion

A frequent reason for patients seeking dental care is related to the presence of color changes in the smile, the teeth, or gums. Thus, among the various aspects associated with the esthetics of the smile, the gingival coloration is fundamental and should be considered. The gingival melanin hyperpigmentation (GMH) is not a disease, but a normal variation and may become an esthetic problem, especially for those individuals with high smile line. Epithelial abrasion technique, using round diamond tips at high speed associated with abundant irrigation [5], has been extensively employed for removal of hyperpigmentation [2, 11]. The treatment through CVD tips proved to be effective. GMH removal can also be done using #15 scalpel blades or other manual instrument to scrap the epithelium up to the connective tissue exposure. The technique using the CVD tip proved to be slower when compared to the conventional diamond tips, however it provides less noise and discomfort to the patient. In the cases of thin

gingival tissue, prominent roots, and thin bone cortical, special care should be directed to the amount of tissue removed [3]. In these cases, the CVD tip is easier to be controlled when compared with the high speed of the conventional diamond tips. In addition, it is a technique less costly when compared to the CO², Nd:YAG and Erbium:YAG laser [1, 8], which also have been used for the GMH treatment.

In addition, the epithelial abrasion technique is simple, fast, offers immediate results and the longevity of results proves the effectiveness of the technique. However, in some cases, regardless of the technique used, there are reports of recurrence of stains after treatment [3]. In this case report, no relapse after the evaluated period of 12 months occurred. The other recommended techniques in literature have more limitations. The free gingival graft causes unsatisfactory esthetic result in light of the resulting coloring discrepancy, as well as to involve two surgical sites [14]. Cryosurgery is another treatment option; however, the technique requires a clinical skill in manipulating equipment and instruments that are not part of the routine arsenal available in the offices [12, 13].

The emergence of new materials and devices in dentistry is essential. In 1994, the system of diamond tips CVDentus (Clorovale Diamantes Ind. e Com. Ltd., São Paulo, Brazil) was introduced in the market. It consists of a molybdenum substratum system, covered in the active part by a single artificial diamond rock obtained by suitable CVD process adapted to the ultrasound device. These tips have some advantages, such as lesser generation of noise and greater time of useful life. Its use in Restorative Dentistry has been indicated for cavity preparation, however its use in Periodontics still needs more studies. Considering the good results demonstrated in this and other studies [15, 16], CVD tips are a promising material in Dentistry.

Conclusion

The technique of epithelial abrasion using CVD tips was effective in removing GMH at one-year follow-up showing to be easy and safe technique.

References

1. Atsawasuwan P, Greethong K, Nimmanon V. Treatment of gingival hyperpigmentation for esthetic purposes by Nd:YAG laser: report of 4 cases. *J Periodontol.* 2000 Feb;71(2):315-21.
2. Bishop K. Treatment of unsightly oral pigmentation: a case report. *Dent Update.* 1994 Jul;21(6):236-7.
3. Carvalho PFMD, Cury PR, Silva RCD, Joly JC, Ciotti DL. Tratamento de pigmentação melânica gengival por abrasão epitelial: relato de casos clínicos. *Rev Dental Press Periodontia Implantol.* 2008;2(1):47-57.
4. Dummett CO, Barends G. Pigmentation of the oral tissues: a review of the literature. *J Periodontol.* 1967 Sep;38(5):369-78.
5. Farnoosh AA. Treatment of gingival pigmentation and discoloration for esthetic purposes. *Int J Periodontics Restorative Dent.* 1990;10(4):312-9.
6. Gaeta GM, Satriano RA, Baroni A. Oral pigmented lesions. *Clin Dermatol.* 2002 May;20(3):286-8.
7. Henriques PG, Nunes Filho DP, Nunes LFP, Nunes MP. Atlas clínico de cirurgia plástica periodontal e manipulação de tecidos moles em implantodontia. Editora Santos; 2007.
8. Ishikawa I, Aoki A, Takasaki AA. Potential applications of Erbium:YAG laser in periodontics. *J Periodontal Res.* 2004 Aug;39(4):275-85.
9. Meleti M, Vescovi P, Mooi WJ, Van Der Waal I. Pigmented lesions of the oral mucosa and perioral tissues: a flow-chart for the diagnosis and some recommendations for the management. *Oral Surg Oral Med Oral Pathol Oral Radiol Endod.* 2008 May;105(5):606-16.
10. Muller S. Melanin-associated pigmented lesions of the oral mucosa: presentation, differential diagnosis, and treatment. *Dermatol Ther.* 2010 May;23(3):220-9.
11. Perlmutter S, Tal H. Repigmentation of the gingiva following surgical injury. *J Periodontol.* 1986 Jan;57(1):48-50.
12. Tal H, Landsberg J, Kozlovsky A. Cryosurgical depigmentation of the gingiva. A case report. *J Clin Periodontol.* 1987 Nov;14(10):614-7.
13. Tal H, Littner S, Kozlovsky A. Depigmentation of human gingivae: clinical observations after surgical and cryosurgical procedures. *Compendium.* 1988 Jan;9(1):22-5.

14. Tamizi M, Taheri M. Treatment of severe physiologic gingival pigmentation with free gingival autograft. *Quintessence Int.* 1996 Aug;27(8):55-8.

15. Valera MC. Pontas de diamantes-CVD. *Rev Gaúcha Odontol.* 1996;44(2):104-8.

16. Vieira AS, Santos MP, Antunes LA, Primo LG, Maia LC. Preparation time and sealing effect of cavities prepared by an ultrasonic device and a high-speed diamond rotary cutting system. *J Oral Sci.* 2007 Sep;49(3):207-11.