



## Case Report Article

# Thermoplastic endodontic obturation – TC system: case report

Kauhanna Vianna de Oliveira<sup>1</sup>  
Flávia Sens Fagundes Tomazinho<sup>1</sup>  
Beatriz Serrato Coelho<sup>1</sup>  
Rodrigo Otavio Jatahy Ferreira do Amaral<sup>1</sup>  
Bruno Marques da Silva<sup>1</sup>  
Flares Baratto Filho<sup>1</sup>  
Kauhanna Vianna de Oliveira<sup>1</sup>

### Corresponding author:

Denise Piotto Leonardi  
Rua Professor Pedro Viriato Parigot de Souza, n. 5.300 – Campo Comprido  
CEP: 81280-330 – Curitiba – PR – Brasil  
E-mail: kauhanna@hotmail.com

<sup>1</sup> Department of Dentistry, Positivo University – Curitiba – PR – Brazil.

*Received for publication: September 13, 2015. Accepted for publication: December 12, 2015.*

### Keywords:

Endodontics; root canal obturation; gutta-percha.

### Abstract

**Introduction:** The TC system, developed in 2002, allows the endodontic filling by means of a non-conventional technique that uses gutta-percha at alpha phase, thermoplasticized in its own oven, placed into canal through a McSpadden compactor, without using a main cone. **Objective:** The aim of this case report was to show the TC system used for root canal filling. **Case report:** Three teeth of a patient was indicated for endodontic treatment, so TC system was used for the root filling. **Conclusion:** This technique showed to be effective for the root canal filling.

## Introduction

Root canal treatment consists of cleaning, disinfection, modeling and obturation of the root canal and the main purpose is to enable the pulpless tooth maintenance in the oral cavity [2]. In addition, the root canal filling should not leave empty spaces inside root canal to prevent recontamination [3]. The gutta-percha has been the most used filling material due to biocompatibility, dimensional stability, plasticity, and ease of removal when necessary [1]. Its use is associated with the endodontic sealer, which aims to fill irregularities and act as a lubricant.

The obturation techniques are classified in conventional and unconventional. The unconventional technique uses gutta-percha thermoplasticized mechanically or by means of heating devices [4]. Ribeiro *et al.* [6] state that the thermoplastification aims to promote greater amount of gutta-percha, better adaptation to irregularities, and consequently, the smaller amount of cement compared to those that use cold gutta-percha, lateral condensation and vertical condensation and the single cone.

Schilder [7] introduced the vertical condensation technique with heated gutta-percha, and since that, thermoplastic methods have been proposed. Among them, Thermafil (Dentsply Maillefer, Ballaigues, Switzerland), Ultrafil 3D (Coltene Whaledent, Altstätten, Switzerland), and Microseal (Sybron Endo, Orange, USA), employing gutta-percha at alpha phase [8].

The TC system (Tanaka de Castro & Minatel Ltda., Cascavel, Brazil) appeared in 2002 with thermoplastic filling characteristics similar to Microseal. The aim was to make the technique accessible, since there is the use of Brazilian technology. In this system alpha-phase gutta-percha is plasticized by a low intensity electric heater, using lower temperature and longer heating time. Piati *et al.* [5] affirm that in this way the gutta-percha syringes can be reused without changing the properties of the material. It is not necessary to use the main or accessories cones. The results of recent research on the use of TC system have been very satisfactory as the filling of curved and flattened root canals [5, 6].

## Case report

Patient AMP, male, aged 32 years, reported he had undergone emergency care at basic health care center three months before, in which teeth #36, #37, and #46 had the coronal access performed.

Tooth #37: Slight thickening of the periodontal ligament space was radiographically found (figure

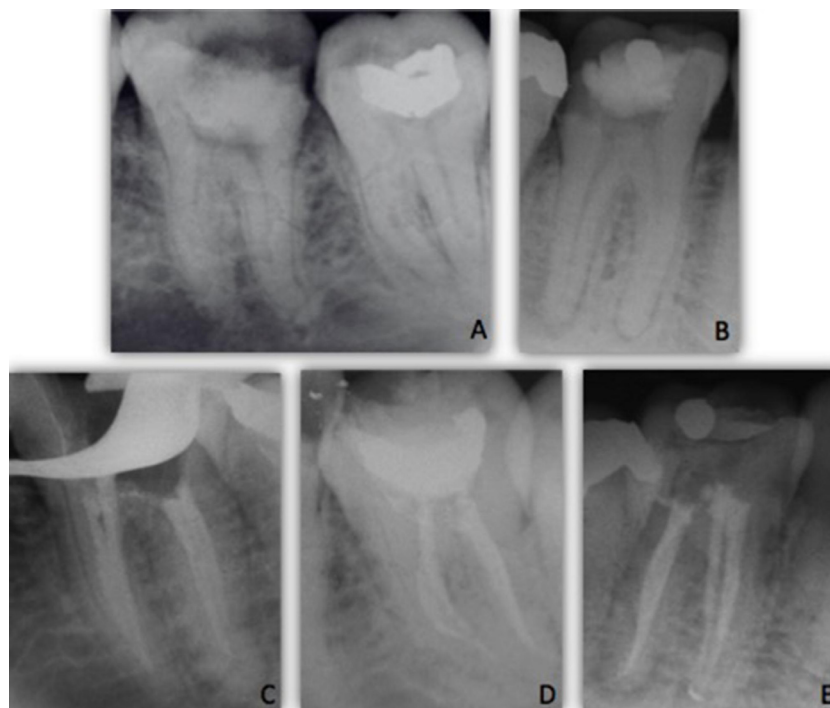
1A). Pulp response to cold thermal test was negative, so the diagnosis was pulp necrosis. Treatment was necropulpectomy at one session. For chemical-mechanical preparation, Race system was employed (FKG Dentaire, La Chaux-de-Fonds, Switzerland). Apical enlargement was performed up to size #35 for distal canal and size #30 for mesial canals. The obturation of root canals employed the size #40 thermo-compactor for distal canal and size #30 for mesial canals.

Tooth #36: At radiographic examination, all structures showed normal signs (figure 1A). Pulp response to cold thermal test was negative, so the diagnosis was pulp necrosis. Treatment was necropulpectomy at one session. For chemical-mechanical preparation Mtwo rotary system (VDW, Munich, Germany) was used, complemented by hand instrumentation. All root canals were enlarged up to size #30. The obturation of root canals employed the size #30 thermo-compactor (21 mm).

Tooth #46: At radiographic examination, the distal root showed a diffuse radiolucent area at the apical (figure 1B). Pulp response to cold thermal test was negative, so the diagnosis was pulp necrosis. Treatment was necropulpectomy. For chemical-mechanical preparation Protaper rotary system (Dentsply-Maillefer, Ballaigues, Switzerland) was used. The root canals were enlarged with F4 instrument in distal canal and F3 in mesial canals. The obturation of root canals employed respectively the size #45 and #40 thermo-compactors.

All three teeth had the endodontic filling performed with TC thermoplastification system, following the manufacturer's recommendations. After the root canal drying with aspiration followed by absorbent paper points (Dentsply Maillefer, Ballaigues, Switzerland), a thin cement layer (AH Plus - Dentsply Maillefer, Ballaigues, Switzerland) was put on the canal walls with the aid of compactor (Dentsply Maillefer, Ballaigues, Switzerland). The thermo-compactor was covered with gutta-percha, inserted into the canal and powered at 20,000 RPM, with movements at the canal long axis until reaching the 1 mm below the working length or until reaching a curvature. This procedure took about 5 seconds for each canal.

Next, the gutta-percha was gently vertically condensed with Paiva condensers to prevent cooling shrinkage. The cut of gutta-percha excess was executed with the aid of cold curettes. The crown sealing was performed with glass ionomer cement (FGM, Joinville, Brazil). The periapical radiograph shots were standardized with the aid of radiographic holders (figures 1C, D, E).



**Figure 1** - A) Initial radiograph of teeth #36 and #37; B) Initial radiograph of tooth #46; C) Final radiograph of tooth #36; D) Final radiograph of tooth #37; E) Final radiograph of tooth #46

## Discussion

The main purpose of endodontic filling is to fill the space of root canals with the best possible adaptation to the walls, through the use of a homogeneous mass of gutta-percha and a thin layer of endodontic cement. Piati *et al.* [5] state that the seal must be sufficient to prevent reinfection by fluids and bacterial byproducts. The obturation techniques assist in this process, but the strong influence of the anatomical variability of root canals may lead to failure.

The TC system consists of a low intensity heater. Once connected, this device has an automatic temperature control that keeps between 95°C and 100°C. According to the manufacturer, the syringes with gutta-percha can be reused without harming its physical properties, until all the material is used, due to two major factors. The first is the dual plasticization of the filling material: one at the heater and the other at the insertion of gutta-percha through the McSpadden compactor. This process enables lower temperatures to obtain the plasticization. The second is in respect of the vertical position of the needle during heating which is uniform throughout the cartridge [1, 2].

A portion of the filling material is "lost" in the first use after the heating of each cartridge. Yet, the technique is affordable and accessible, in view of the use of Brazilian technology and the cost to buy new syringes.

According to the manufacturer, the use of both accessories and main cones is optional. In cases where the test cone is hindered by the anatomy of the canals, bending may occur, so the alternative of not using gutta-percha cones in such circumstances is an advantage. A prior training in extracted teeth is essential, particularly because the working time is reduced by about 5 seconds per canal compared to other filling techniques.

The obturation technique has some limitations. The short McSpadden compactor (#30) of 21 mm provided with the system did not reach adequate results in the treatment of tooth #36, which had more than 20 mm long. Unlike other 25-mm compactors, this length cannot be achieved because the technique advocates use the compactors 1 mm below the working length or until reaching the curvature.

This observation highlights the importance of odontometry, since the technique do not require

either the radiographic or electronic proof of gutta-percha cone or to make sure about the measure.

The manufacturer recommends the use of McSpadden compactor (#30) of 21 mm he manufacturer recommends the use of McSpadden compactor (#25) 21 mm only for thinner and curved canals such as mesial-buccal, distal-buccal, mesial-lingual canals of molars, lower incisors, and pre-molars with two canals.

Although the manufacturer states that filling material leakage can be controlled, it will be favored when there is presence of apical periodontitis, if the operator stay longer time periods than that indicated, activating the instrument inside the canal, or if the compressor exceeds the safety limit of 1 mm short of the working length.

Current research investigated about leakage and filling obtained with TC system. Ribeiro *et al.* [6] found that at 2 mm short of the apex, TC system and lateral condensation was better than Thermafil; at 4 mm, no significant differences were found. Pereira *et al.* [4] concluded that the results obtained with TC system were better than modified McSpadden technique, and these latter were better than lateral condensation when filling was considered. Concerning to apical microleakage, Damasceno *et al.* [1] found no statistically significant differences between TC system and Protaper single cone.

This case report suggests that TC system provides satisfactory endodontic fillings, since the particularities of each clinical situation are observed. The system presents advantages and limitations that imply the need for more studies on the device.

## Conclusion

The TC system of thermoplastification filling was effective in different clinical situations, regardless of the number of root canals, proving its versatility. The technique was fast contributing for a shorter working time, if previous training was delivered. Radiographically, the results were satisfactory, but further studies are necessary to prove the behavior of this system in relation to microorganism leakage and root canal filling.

## References

1. Damasceno JLN, Silva PG, Queiroz ACFS, Vardasca de Oliveira PT, Pereira KFS. Estudo comparativo do selamento apical em canais radiculares obturados pelas técnicas do cone único Protaper e termoplástica sistema TC. RGO. 2008;56(4):417-22.
2. Fracassi LD, Ferraz EG, Albergaria SJ, Sarmiento VA. Comparação radiográfica do preenchimento do canal radicular de dentes obturados por diferentes técnicas endodônticas. RGO. 2010;58(2):173-9.
3. Ito DL, Shimabuko DM, Aun CA, Brum TB. Avaliação da infiltração bacteriana em técnicas de obturação do canal radicular. Revista de Odontologia da Universidade Cidade São Paulo. 2010;22(3):198-215.
4. Pereira KFS, Zanella HVN, Silva PG, Queiroz ACFS, Vardasca de Oliveira PT, Chita JJ. Análise comparativa da porcentagem da área preenchida pela obturação no terço apical dos canais radiculares em três diferentes técnicas. Pesq Bras Odontoped Clín Integr. 2010;10(2):217-23.
5. Piati DCK, Pereira KFS, Vargas Ramos CR, Ferreira LC, Arashiro FN, Zafalon EJ. Avaliação de técnicas de obturação para canais instrumentados pelo sistema Reciproc. Pesq Bras Odontoped Clín Integr. 2013;13(2):205-12.
6. Ribeiro MA, Queiroz ACFS, Silva PG, Yoshinari GH, Guerisoli DMZ, Pereira KFS. Estudo comparativo da área apical preenchida pela gutta-percha nas técnicas de obturação TC, Thermafil e condensação lateral. Revista de Odontologia da UNESP. 2009;38(1):65-71.
7. Schilder H. Filling root canals in three dimensions. Dent Clin North Am. 1967;11:723-44.
8. Tanomaru-Filho M, Bier CAS, Tanomaru JMG, Barros DB. Evaluation of thermoplasticity of different gutta-percha cones and the TC System. J Appl Oral Sci. 2007;15(2):131-4.