



ISSN:
Electronic version: 1984-5685
RSBO. 2017 Apr-Jun;14(2):80-5

Original Research Article

In vitro analysis of the internal anatomy of lower incisors by cone beam computerized tomography

Fabio de Almeida Gomes¹
Renata Ferreira Pinto Barbosa¹
Yvelise Aquino Mesquita¹
Cláudio Maniglia Ferreira¹
Renata Cordeiro Teixeira¹
Luiz Carlos Trévia Morais Correia Viana¹

Corresponding author:

Fabio de Almeida Gomes
Rua Paula Ney, 925, ap. 501 – Aldeota
CEP 60140-200 – Fortaleza – Ceará – Brasil
E-mail: fabiogomesce@yahoo.com.br

¹ Department of Dentistry, University of Fortaleza – Fortaleza – CE – Brazil.

Received for publication: March 13, 2017. Accepted for publication: April 12, 2017.

Keywords:

cone beam computer tomography; lower incisors; dental anatomy.

Abstract

Introduction: For the success of endodontic treatment, the knowledge of the internal anatomy becomes essential. **Objective:** to analyze the prevalence of lower incisor canals in a clinical and tomographic analysis. **Material and methods:** 148 lower incisors were used, measured, and evaluated through periapical radiograph and computed tomography. **Results:** in relation to the number of canals, 107 teeth (72.3%) presented a single canal, while 41 teeth (27.7%) presented two canals. Of the 41 teeth presenting 2 canals, 3 teeth presented independent canals (2.03%) and 38 teeth had 2 canals that joined at some point of the canal path (25.67%). **Conclusion:** The prevalence of two canals in the lower permanent human incisors was 27.7%; of these, 2.03% were independent. The main point of root canal union was at the apical third (20.94%). The most commonly found root canal shape was round in cervical third, flattened in middle third, and round in third apical.

Introduction

The success of endodontic treatment is the result of several technical steps ranging from the correct choice of the case to the filling of the canal [1].

All Endodontic therapy needs the manipulation of the pulp cavity, which is not displayed macroscopically and directly, in the totality. Therefore, it is necessary to have a broad knowledge on the morphology of root canals, as well as possible and constant variations, which can interfere with treatment successful [9, 18].

The anatomical feature, although following a certain pattern between the different tooth groups, may suffer some changes. One of the variations found in teeth is the number of roots or root canals [13].

The lower incisors are challenging due to the small size and anatomy [11]. The lower incisors' crown has a trapezoidal shape with little length difference between the two bases [6]. These are single-rooted teeth, showing only one canal - wide at labial-lingual direction and narrow at mesial-distal direction [2]. Because of marked mesial-distal flattening of the root, the lower incisors have the bifurcation of the canals and the labial and lingual ramifications are joined apically ending in a single foramen, in most cases. However, the complete separation is rare and, in such cases, separated apical foramina may exist [14].

The failure in endodontic treatment of lower incisors can be caused by lack of knowledge on the internal anatomy or the inability to detect the presence of a possible second canal [7]. The presence of the untreated second canal may result in the emergence or persistence of clinical symptoms [18].

A good preoperative radiographic evaluation is necessary and indispensable for the success of endodontic therapy [16]. The difficulties presented by the radiographic method are related to one-dimensional images, superposition of the anatomical structures and variation at the vertical and horizontal angles. These difficulties may not allow the precise diagnosis in relation to the number of roots and canals [10]. This limitation can be discussed with the use of cone beam computed tomography (CBCT) in Dentistry. This method produces three-dimensional images with the absence of anatomical superposition and less radiation exposure of the patient.

Additionally, to imaging tests, the knowledge on the internal morphology of the pulp cavity enables the formation of a three-dimensional image of the pulp cavity in the dentists' mind, making it able to intervene in the endodontium [14].

This study aimed to analyze, by tomographic images, the internal anatomy of the human permanent lower incisors, evaluating the amount of root canals, the root third of bifurcation, the union of the canals, and the shape of the cross section at each third.

Material and methods

This research was conducted after the approval of the Institutional Review Board of the University of Fortaleza (Unifor) regarding ethical aspects under Protocol no. 375/2011. This is a laboratorial, cross-sectional, quantitative study.

Obtaining and selection of specimens

The study was conducted with the use of 158 permanent human lower incisors extracted in dental clinic of Unifor and stored in saline solution until the time they were used. These teeth were randomly numbered.

All teeth were extracted due to a) aggressively periodontal disease with large clinical insertion loss; b) orthodontic reasons; c) prosthetic reason; d) extensive decay; whose detailed histories are part of the records of patients who read and signed the informed consent form of the biorepository, after the approval of the Institutional Review Board of the University of Fortaleza.

All the following procedures were carried out by the same operator.

Previous measurements of the size of the teeth

Each tooth was measured from the most prominent tip of incisal edge to the root apex through digital caliper (Mitutoyo; CD-6 CS; 0002616; Japan) and tabled by Microsoft Excel software (MacOffice 2014). Then, the average size was calculated. Teeth with destroyed crowns did not take part of this evaluation.

Assembly of teeth on fixation platform

Each tooth was mounted on a 14-cm square Styrofoam platform with 10 cm in height (figure 1). These teeth were numbered from 1 to 158, and each one was inserted into a hole previously made on that platform.



Figure 1 - Sample on fixation platform

Cone beam computed tomography (CBCT)

The images of the teeth were acquired by tomographic device GX-CB 500 Powered, a system of volumetric cone beam cat scan, of the Department of Radiology, School of Dentistry, Unifor. Before the acquisition of the images, the tomographic device was calibrated through i-CAT Vision® 1.9.5 software. The tomographic device was set at: 14 cm of diameter, 23 seconds of exposure, and 0.20 voxel. The specimens were located in a Styrofoam platform. The kilovoltage was automatically adjusted in 120 kVp and the milliamperage at 7 mA, 0.5 focal point distance from source to sensor: 71.4 cm. Then, the images were converted to DICOM format and reformatted on the i-CAT Vision® 1.9.5 software. The images were opened on the computer that runs with Windows platform®, with 32-inch plain screen. The room was darkened during the analysis of the CT scans, for better visualization.

Analysis of the images

The obtained images were analyzed by the same system software, on which the following topics were assessed:

- Number of canals;
- If two canals, verification if they are independent or not;
- If the two canals are linked, the third of union (cervical, medium, or apical);

- If the two canals, the point of appearance of the two canals;
- Axial cut of the canal shape at the cervical, medium, and apical thirds. Classified in round, oval, and flattened (figure 2).

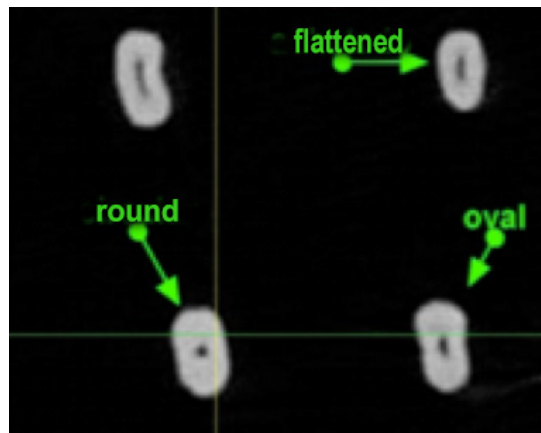


Figure 2 - Example of canals with round, flattened, and oval shape

Analysis and tabulation of the results

All the results were analyzed and described by descriptive statistics and tabulated in Microsoft Excel software (MacOffice 2014).

Results

In total, 158 teeth were analyzed; ten teeth were excluded from the analysis for presenting or calcified canals or broken crowns, remaining 148 teeth.

The medium size of the evaluated teeth with the use of digital caliper was of 21.30 mm.

Regarding the number of canals, of the 148 analyzed teeth, 107 teeth (72.3%) had only one canal, while 41 teeth (27.7%) had two canals.

Table 1 - Tooth number and percentage of one and two canals

Canal number	Absolute number	Percentage
1 canal	107	72.3%
2 canals	41	27.7%

Of the 41 teeth showing two canals, three had independent canals, i.e. 2.03% of the total sample, and 38 teeth had two canals that joint at some point along the path of the canal (25.67% of the sample).

Table II - Tooth number and percentage of one and two canals

Canal number	Absolute number	Percentage
1 canal	107	72.3%
2 dependent canals	38	25.67%
2 independent canals	3	2.03%

Taking into consideration the total sample (148 teeth), four teeth (2.7%) had the two canals at the cervical third; 35 teeth had two canals at medium thirds (23.65%); and two teeth had two canals at the apical third (1.35%).

Table III - Root thirds of emergence of two root canals

Root third	Absolute number	Percentage
Cervical	4	2.7%
Medium	35	23.65%
Apical	2	1.35%

Of the 38 teeth with two canals that ended in one canal, seven had the union point at the medium third, that is, 4.73% of the total sample, and 31 canals had the union point at the apical third (20.94%).

Table IV - Root thirds of emergence of two root canals

Root third	Absolute number	Percentage
Cervical	0	0
Medium	7	4.73%
Apical	31	20.94%

With respect to the canal shape at the axial cut, at the cervical third, 29 teeth had flattened shape (19.6%), 64 round shape (43.24%), and 55 oval shape (37.16%). At the medium third, 64 teeth had flattened shape (43.24%), 57 round (38.52%), and 27 oval (18.24%). At the apical third, 23 were flattened (15.54%), 111 round (75%), and 14 oval (9.46%).

Table V - Root canal shape at axial cut (absolute number/percentile)

Root third	Flat	Round	Oval
Cervical	29 (19.6%)	64 (43.24%)	55 (37.16%)
Medium	64 (43.24%)	57 (38.52%)	27 (18.24%)
Apical	23 (15.54%)	111 (75%)	14 (9.46%)

Discussion

The knowledge on the endodontic anatomy and its variations are of basic importance for the success of the endodontic treatment. As time goes by, the endodontist acquires innovative ways to aid in the diagnosis of these variations, among them, the tomographic examination is one of the most used for this purpose. In this study, through this examination, it was possible to observe clear aspects of the internal anatomy of the root canal system, as the number of root canals, the independence or not of the canal, as well as the point of emergence and union of canals, and their shapes.

Endodontic Anatomy, although following a certain pattern among the tooth groups, can suffer major changes, which may negatively affect the preparation and filling of canals with consequence in the prognosis of treatment [1].

The lower incisors have more than one canal, therefore, the results of this study consider showing this variation in the morphology and to point out the importance of the knowledge on the endodontic anatomy by the dentist.

In the present study, a sample of 148 lower permanent human incisors was used, of which, 27.7% (41 teeth) had two canals through the radiographic analysis.

In literature, the rates on the prevalence of two canals in lower incisors vary. The results of Vertucci and Gainesville [16] come closer to those obtained in the present study, where in a sample of 200 teeth, 30% of the lower incisors had two canals. Gomes *et al.* [6] showed that in a sample of 100 teeth, 28% had two canals.

In a sample of 133 teeth, it was found that 18% of teeth had two root canals. Studies reported by Campbell *et al.* [3] assessed 141 specimens, in which 60.9% presented two canals. Oliveira *et al.* [11], in a sample of 2,115 teeth, obtained 10.3% (218 teeth) of the lower incisors with two canals.

The discrepancies between the two studies may be related to the number of specimens or the different methods used for the diagnosis because some studies used the diaphanization method and others used the radiographic method [6].

The success of endodontic treatment can be related to the point of union of the canals, since the more cervical is the union point, the lower is the chances of failure [6]. Oliveira *et al.* [11] pointed out that, when two canals are presented in lower incisors, they usually join at 1 mm or 2 mm below the apex, these data corroborated the results of Kartal and Yanikoglu [7], Gomes *et al.* [6] and the present study.

The root canal system is of extreme complexity. Such complexity was observed through the variations in relation to the number of canals in the lower incisors in diverse studies. The detailed investigation of the number canals, the point of union of these canals, and the amount of foramen openings justify new research and highlights the importance of the knowledge on the anatomy by the dentist.

Conclusion

According to the employed methodology, it can be concluded that:

- The prevalence of two canals in human permanent lower incisors occurred in 27.7% of the specimens, of which 2.03% were independent;
- In the cases of teeth with two dependent root canals, the main union point of these root canals was the apical third;
- The root canal shape most found in axial cut was: round at cervical third; flat at medium third; and round at apical third.

References

1. Almeida-Gomes F, Santos RA, Maniglia-Ferreira C, Guimarães NLSL, Vitoriano MM. "C-shape canal": uma variação anatômica de interesse clínico. *UFES*. 2010;12(2):57-60.
2. Benjamin KA, Dowson J. Incidence of two root canals in human mandibular incisor teeth. *Oral Sug Oral Med Oral Pathol*. 1974;38(1):122-6.
3. Campos PSF, Albergaria SJ, Panella J, Fagundes D. Avaliação da relação entre a imagem radiográfica da câmara pulpar e o número de canais radiculares dos incisivos inferiores. *RPG*. 2001;8(2):116-20.
4. Duque TM. Incidência de dois canais radiculares em incisivos inferiores tratados endodonticamente por alunos da graduação: análise radiográfica, por microscopia óptica e diafanização. Piracicaba. Monografia [Especialização] – Faculdade de Odontologia da Unicamp; 2011.
5. Galafassi D, Lazzaretti DN, Spazzin AO, Vanni JR, Silva SO. Estudo da anatomia interna do canal radicular em incisivos inferiores pela técnica de diafanização. *RSBO*. 2007;4(1):7-11.
6. Gomes F, Amorim S, Fernandes T, Souza L, Vitoriano M, Ferreira C. Prevalência de dois canais em incisivos inferiores permanentes humanos. *Full Dent Sci*. 2016;7(26):134-8.
7. Kartal N, Yanikoglu FÇ. Root canal morphology of mandibular incisors. *J Endod*. 1992;18(11):562-4.
8. Leonardo MR. Aspectos anatômicos da cavidade pulpar: relações com o tratamento de canais. In: Leonardo MR, Leal JM. *Endodontia: tratamento de canais radiculares*. 2. ed. São Paulo: Panamericana; 1991. p. 126-40.
9. Mancilha FAB, Vance R, Habitante SM, Simões S. Estudo comparativo da anatomia interna de dentes anômalos pelos métodos radiográficos e diafanização. *Sotau*. 2008;5(ano 2):22-9.
10. Mauger MJ, Waite RW, Alexander JB, Schindler WG. Ideal endodontic access in mandibular incisors. *J Endod*. 1999;25:206-7.
11. Oliveira SHG, Faig-Leite H, Madeira MC. Estudo radiográfico da incidência de bifurcações do canal radicular de incisivos inferiores. *Rev Odontol Unesp*. 1999;28(2):465-73.
12. Silva KT, Soares RG, Melo TAF. Tratamento endodôntico em molar em forma de "C". *RSBO*. 2010 Mar;7(1):100-4.
13. Silveira DM, Paiva JG. Configuração interna dental. In: Paiva JG, Antoniazzi JH. *Endodontia: tratamento de canais radiculares*. 2. ed. Porto Alegre: Artes Médicas; 1993. p. 455-83.
14. Soares IJ, Goldberg F. *Endodontia: técnicas e fundamentos*. Porto Alegre: ArtMed; 2001. p. 41-55.
15. Tiku AM, Kalaskar RR, Damle SG. An unusual presentation of all the mandibular anterior teeth with two root canals – a case report. *J Indian Soc Pedod Prev Dent*. 2005;3(4):204-6.

16. Vertucci FJ, Gainesville F. Root canal anatomy of the human permanent teeth. *Oral Surg.* 1984;58(5):589-99.
17. Vier FV, Limongi O, Agnoletto A, Susin GC. Estudo da morfologia do canal radicular de incisivos inferiores empregando-se a técnica de diafanização. *Stomatos, Canoas.* 2001;7(12/13):25-32.
18. Warren EM, Laws AJ. The relationship between crown size and the incidence of bifid root canals in mandibular incisor teeth. *Oral Surg.* 1981;52:425-9.