

The Effects of Gender and Age on the Cerebral Ventricles / Brain Ratio Morphometric Study

Alaa Suliman Mohammed Suliman^{a*}, Alfadil Osman Alawad^b, Caroline Edward
Ayad^c, Amel Alsaied Hasan AbdAlrahem^d

^{a,d}*Faculty of radiological sciences, University of medical sciences and technology, Khartoum, Sudan*

^b*quality hospital, Khartoum, Sudan*

^c*Sudan University of Science and Technology, College of medical radiology science P.O box. 1908,
Khartoum, Sudan*

Abstract

The evaluation of the normal measurements of the cerebral ventricles in the living human has great importance in the diagnosis and monitoring of several pathologies, some previous studies reported variable results concerning the measurements of ventricles. But, and to best of our knowledge, and what was found in the open literature; there is no enough data concerning normative Sudanese measurement for cerebral ventricles. The aim of the study to analyze the morphometric measurements of the Lateral Ventricles of the brain, in different age group individuals of both genders by MR imaging. descriptive analytical study were done to show the sizes of brain lateral ventricles on Axial Brain MRI section, in which 80 normal adult Sudanese patients (40 male, 40 female), were measured (1.5 Tesla). MR Image were acquired in T1 weighted image using axial view of the cerebral hemisphere, the following vertical and longitudinal dimensions of both lateral ventricles, Anterior Horn (A.H), body, Posterior Horn (PH), Brain Width (B.W), Brain Length (B.L), Lateral Ventricle Length (V.L), were measured. Data statistical analyzed were conducted using SPSS (Statistical Presentation System Software) for windows version 14.0 Evaluation, where student test and chi-square test was used for analysis for statistical significance and an α -level of 0.05 were considered with a 95% confidence level and intervals. The results revealed that sex-related difference was detected between genders where the body was found to be larger in male than female, while the age related changes seen in all parts of lateral ventricle when it was increase with increasing age.

* Corresponding author.

This study concluded that regarding sex related difference in Sudanese population our finding reported there is significant statistical difference between genders where the body of lateral ventricle was found to be larger in male than female .Thus, no significant statistical difference between genders concerning the anterior horn and posterior horn. Regarding the age effect on the size of the lateral ventricle, in our study in Sudanese population, the size of the right and left anterior horn of lateral ventricle was increasing with age, this fact also true concern the posterior horn in both sides.Regard ventricular / brain ratio, we found that in our results there is unexplainable decrease in the ratio in group C (36-48 years), and increase in group E (62 – 74 years) (due to brain atrophy).In other hand this ratio remains equal in both genders, and in two sides.

Keywords: Morphology; MRI.

1. Introduction

1.1 Lateral ventricle

It is the cavity of the telencephalon (cerebral hemisphere).

Shape: It is (Y- or C-shaped).

Parts and site:

It is formed of a body and 3 horns; anterior, posterior and inferior.

1. Body (central part): lies in the parietal lobe.
2. Anterior horn: lies in the frontal lobe.
3. Posterior horn: lies in the occipital lobe.
4. Inferior horn: lies in the temporal lobe [4].

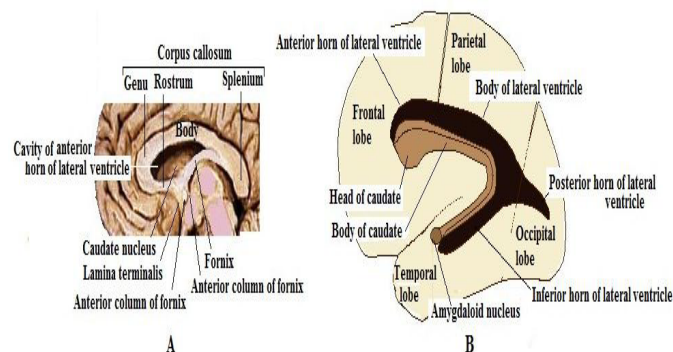


Figure 1.2: Parts of lateral ventricle A) Relation to parts of corpus callosum and B) Relation to caudate nucleus.(source Lectures of Human Anatomy Neuroanatomy Ventricular System and CSF By DR. Abdel-MonemAwadHegazy MB, BCh with honor 1983, Diploma)

Relations:

1.2 Anterior horn

Anterior wall: genu of corpus callosum.

Roof: body of corpus callosum.

Floor: rostrum of corpus callosum.

Medial wall: septum pellucidum.

Lateral wall: Head of caudate nucleus.

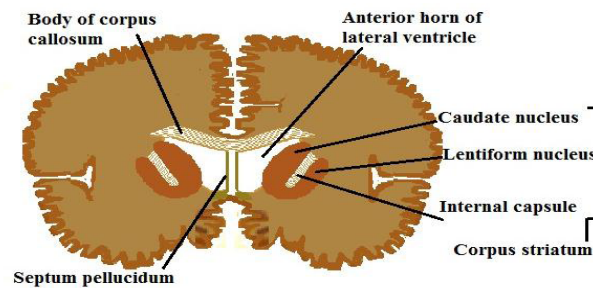


Figure 1.3: Coronal section in the cerebral hemispheres showing relations of anterior horn of lateral ventricles.(source Lectures of Human Anatomy Neuroanatomy Ventricular System and CSF By DR. Abdel-MonemAwadHegazy MB, BCh with honor 1983, Diploma)

1.3 Central part

lies behind the level of interventricular foramen.

Roof: body of corpus callosum.

Inferio-lateral wall: The lateral wall is sloping towards the floor.

The inferiolateral wall is formed (from lateral to medial) by body of caudate nucleus, thalamo-striate groove (containing thalamo-striate and stria terminalis), thalamus and body of fornix.

N.B.: Stria terminalis is a band of white matter extending along the whole length of caudate nucleus. It arises from the amygdaloid nucleus at the tail of caudate, passing along it to end in the anterior hypothalamic and septal nuclei.

The choroid plexus invaginates the body of the ventricle through a fissure in the medial wall lying between the fornix and thalamus.

Lateral wall: septum pellucidum[5].

2. Literature Review

Ranging across a broad spectrum of neurobehavioral disorders, magnetic resonance images of the brain have revealed neuroanatomic differences among various diagnostic and demographic groups. In particular, enlargement of the lateral ventricles has been observed in alcoholism, normal aging, depression, dementia, and schizophrenia [9].

Changes in the brain with ageing have been the focus of many studies. (Barron and his colleagues 1976) [10] studied ventricular size during aging and found a gradual progressive increase in ventricular size from first to the sixth decade followed by a dramatic increase in the eighth and ninth decades. They found that the range of normal ventricular size was relatively wider in the eighth and ninth decades than in the first seven. Of those that have, two found no gender differences within an aged sample of normals (20% male subjects) [11].

The brains of 100 normal adults were examined with 160 X 160 matrix computed tomography (CT). The left lateral ventricle was found to be larger than the right in both sexes, and both lateral ventricles were larger in the male. There was a statistically significant increase of all cerebral parameters with age, and the cella media index showed a correspondingly small decrease with age. The linear measurements of the lateral ventricles demonstrated positive correlation to cranial size, while the widths of the third ventricle and of the hemispheric Sulci were independent of the size of the skull [12].

According to a review by Le May (1984) the brain grows rapidly early in life and reaches maximum weight by the third decade, thereafter regression soon begins. She also noted that regression of the brain in an individual is a normal process and could result in compensatory enlargement of the ventricles [13].

Galwer J and his colleagues (1975) found that, (a) the ventricles appear slightly smaller in Computerized Tomography than in a fixed specimen of normal brain. (b) There is a degree of asymmetry in the lateral ventricular contour. (c) A clear delineation of temporal horns of lateral ventricles implied that they are dilated. [14]

Gyldensted C (1977). Study the brains of 100 normal adults with Computed Tomography. In his study he found that the left lateral ventricle was larger than right in both sexes and both lateral ventricles are larger in males. The linear measurement of lateral ventricles demonstrated positive correlation to cranial size while width of third ventricle was independent of size of the skull [15].

According to Monte SM (1988). There was enlargement of ventricular system in chronic alcoholics. The absolute increase in the size of the ventricles in alcoholic groups was roughly equal to the amount of tissue loss in the cerebral white matter [16].

Bandiera P and his colleagues (1996) conducted the morphometric study of lateral ventricles using MRI scan and values obtained were in accordance with the range of normal values reported from literature [17].

D'souza and his colleagues (2007). Study the morphometric measurement of ventricular system of brain by CT which has clinical correlation in diagnosis, treatment and surgical interventions [18]. Garret WJ and his colleagues (1980) studied the width of bodies of both lateral ventricles in 833 children using B-mode echography. The normal ventricular ratio (LVR) was 0.24-0.36[19]. Erturk M and his colleagues (2004) studied the morphometry of anterior third ventricular region as a guide for the transcallosal-interforncial approach to localize and totally remove space occupying lesions around anterior third ventricular region [20].

3. Material and Methods

1- Study design

Descriptive analytical study was conducted.

2- Study Area & population and duration:

- **Study area:**

The Department of Radiology in Elzaytona Hospital (Khartoum-Sudan).

- **Study Population**

The study group going to be drawn, from patients referred for head MRI examination for various indications, from all Sudanese subjects examined.

- **Study Duration**

From March to August 2016.

3- Sample Size and Sampling

80 patients (40males, 40 females).

4- Inclusion Criteria

The following patients took part in the study:

- Patients who had no pathologic evidence (free of any neurological signs).
- Patients had normal head MRI.

5- Exclusion Criteria

Patients have any of the followings, were being excluded on the basis of MRI findings:

- Space-occupying lesions.

- Intracranial bleeding.
- Recent infarction.
- Trauma.
- Postoperative scanning.
- Incomplete clinical information.
- Or any pathological conditions that may affect the ventricles measurements.

6- Variable under Study

- Age
- Sex
- Body Mass Index.
- Anterior Horn of lateral ventricle.
- The body of lateral ventricle.
- Posterior Horn of lateral ventricle.
- Brain Width.
- Brain Length.
- Lateral Ventricle Length.

4. Methods

1- MRI technique of brain

Patient positioning

The patient lies supine on the examination couch with their head within the head coil. The head is adjusted so that the inter-pupillary line is parallel to the couch and the head is straight. The patient is positioned so that the longitudinal alignment light lies in the midline, and the horizontal alignment light passes through the nasion. Straps and foam pads are used for immobilization.

Equipment

- Head coil (quadrature or multi-coil array).
- Immobilization pads and strips.
- Earplugs/headphones.

2- Data collection tools and techniques

All data was collected from patients referred for head MRI examination for various indications, from all Sudanese subjects examined in the Department of Radiology in Elzaytona hospital (Khartoum-Sudan), by selection randomly according to age group.

3- Methods of Measurements

All patients were scanned by the following guideline MR examinations acquired on:

- I. 1.5 – Tesla magnet unit.
- II. Measurements were obtaining from conventional spin-echo sequence Axial T1-weighted image.
 - **TR:** Repetition time range from (400-600ms).
 - **TE:** Echo Time 20ms.
 - Number of excitations:2
- III. A 5mm section slices thickness, a 1.5-mm gap.
- IV. A 256×192 matrix.
- V. Each image was recalled from the MR computer's hard disk; brightness and contrast were set to approximate images used for measurements of the area of interest was computed with standard MR software.

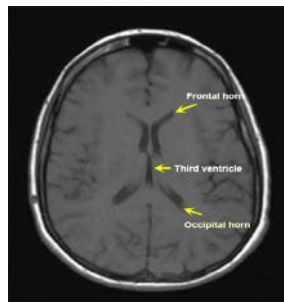


Figure (2A): shows measurements of lateral ventricle/brain

- *AH = Anterior Horn of lateral ventricle.
- *B.L=Brain Length.
- *PH=Posterior Horn of lateral ventricle.
- *B.W=Brain Width.
- *V.L=Lateral Ventricle Length

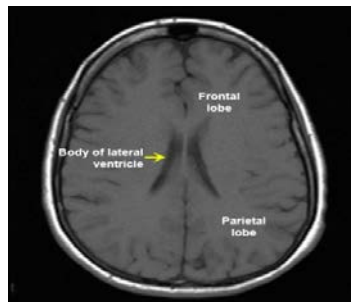


Figure (3A): shows measurements of the body of the lateral ventricle

5. Data Analysis

Statistical analysis was conducted using SPSS (Statistical Presentation System Software) for windows version 16.0 Evaluation. Data was represented in Bar & Pie diagram.

Ethical considerations:

- Clearance from faculty & SUMASRI Institutional Review Board (SIRB) technical and ethical of UMST was approved.
- Informed consent was obtained by chief of radiology department from Elzaytona hospital (Khartoum-Sudan) hospital.
- All patients in the study going to be Inform:
 - I. His MRI scan underwent morphometric studying as part of research (in simple language).
 - II. Patient acceptance was taken before any measurement.
 - III. This study not related to any tribe, or ethnic group.

6. Results

1. Descriptive Statistics

Regarding the weight, there is significant statistical difference, when (mean \pm Std.Deviation) of males was (74.0750 \pm 11.19612), in females was (76.000 \pm 11.38825), with p-value .169 (table 5.1).

Less than 2cm of height differences (mean \pm Std.Deviation) between males and females in the group (169.0750 \pm 8.58857) & (167.8000 \pm 8.30878) respectively, giving p-value .072, where males looks a little bit longer (table 5.1).

Furthermore the Body Mass Index (BMI), almost the same in the both gender, were in males (.002590 \pm .0004217); and in females (.002625 \pm .0003470), with p-value .650 (table 5.1).

Regarding the gender samples of Sudanese patient represented in the research equally (40 males & 40 females). Thus they appear in the pie chart (50%-50%), look to (figure 5.1).

There is no significant statistical difference between male and female where the right anterior horn (R.A.H), and left anterior horn (L.A.H), were found almost similar in both sex; while in male (R.A.H) = (.6475 \pm .23857) and (L.A.H) = (.6675 \pm .23467), in female (R.A.H) was found (.6300 \pm .23772) and (L.A.H) was (.6375 \pm .23717), with difference (.0175) and (.0300) respectively, giving p-value of .000 in both situation (table 5.2).

The body of lateral ventricles in both sides showed significant statistical differences between males and females, in right & left side; While (mean \pm Std.Deviation) in males was (1.1300 \pm .28212) with p-value .937; (1.1525 \pm .28101) with p-value .548 respectively. Were in females (1.1250 \pm .28442) with p-value .937; (1.1150 \pm .27414) with p-value .548 respectively. Also in males the left side was slightly bigger compared with right side

and vice versa in females as you see in (table 5.3)

Table 5.1: Shows Statistics of weight & height & Body Mass Index (BMI)

	Gender	N	Mean	Std. Deviation	
weight (kg)	Male	40	74.0750	11.19612	.448
	Female	40	76.0000	11.38825	
Height (cm)	Male	40	169.0750	8.58857	.502
	Female	40	167.8000	8.30878	
BMI (Wt/height ²)	Male	40	.002590	.0004217	.686
	Female	40	.002625	.0003470	

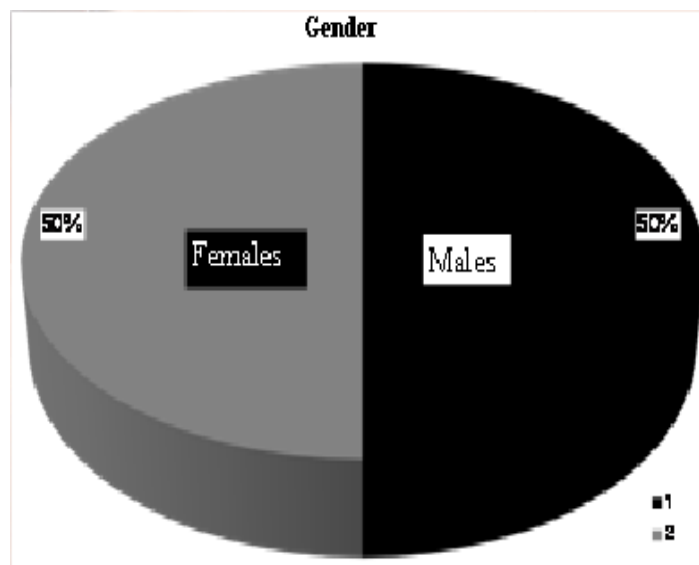


Figure 5.1: shows statistics of cerebral ventricles in sudanese according to gender

Table 5.2: shows statistics of right and left Anterior Horn (A.H)

	Gender	N	Mean	Std. Deviation	
RT side(A.H)	Male	40	.6475	.23857	.743
	Female	40	.6300	.23772	
LT side(A.H)	Male	40	.6675	.23467	.571
	Female	40	.6375	.23717	

In the other hand, the size of right and left anterior horn increases with increasing age in different age group, while in RAH group A = .4062, in group E = .9188, since in LAH, group A= .4625, we found in group E = .9250, with p-value .000 for both. From mentioned data, we can realize that, left anterior horn slightly big than right one in all age group (because it is a dominant hemisphere), (figure 5.2&5.3).

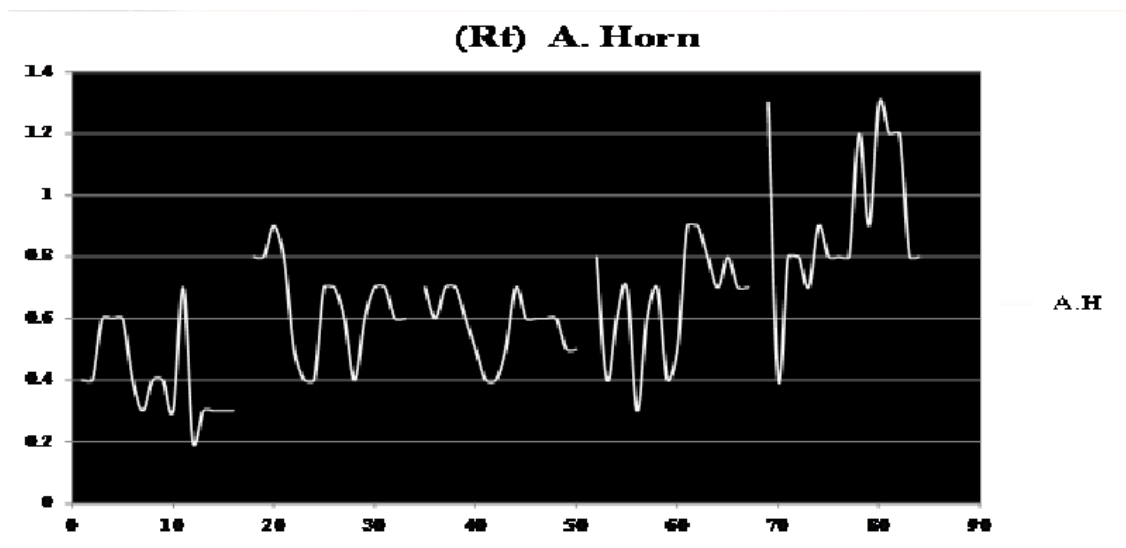


Figure 5.2: represent detailed statistics of right anterior horn (A.H) in both genders

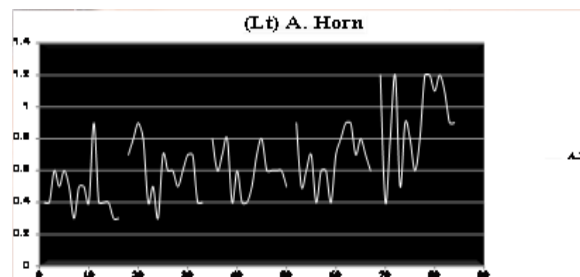


Figure 5.3: represent detailed statistics of left anterior horn (A.H) in both genders

Table 5.3: shows statistics of bodies of lateral ventricles In both genders

(Rt) body	Male	40	1.1300	.28212	.937
	Female	40	1.1250	.28442	
(LT) body	Male	40	1.1525	.28101	.548
	Female	40	1.1150	.27414	

Moreover, obviously you can see significant reduction in size of the body of lateral ventricle in Group C (36-48 years), in right side (mean±Std.deviation) was (.8938±.19138), and in left side was (.9313±.16621) giving p-value for each see (table 5.4).

Table 5.4: represents statistics of (RT & LT) body Of lateral ventricles

	Age /year	No	MEAN	STDV			P-value
(Rt) body	10-22	16	1.0187	.14705	.70	1.30	.000
	23-35	16	1.1625	.23345	.80	1.50	
	36-48	16	.8938	.19138	.60	1.40	
	49-61	16	1.0938	.19483	.70	1.40	
	62-74	16	1.4687	.26260	1.10	1.90	
	Total	80	1.1275	.28149	.60	1.90	
(Lt) body	10-22	16	1.0063	.14818	.80	1.40	.000
	23-35	16	1.1875	.17842	.80	1.40	
	36-48	16	.9313	.16621	.60	1.20	
	49-61	16	1.0688	.21823	.70	1.60	
	62-74	16	1.4750	.28402	1.10	2.00	
	Total	80	1.1338	.27648	.60	2.00	

When you look in the results of the posterior horn (P.H), obviously you can realize that no big differences between males and females in the statistics, while in male (mean±Std.deviation) was (1.0150±.27037), in female = (1.0425±.30541), giving p-value.671 (table 5.6)

Table 5.5: shows statistics of Posterior Horn (P.H) In both genders

P.H	Male	40	1.0150	.27037	.671
	Female	40	1.0425	.30541	

Beside that the size of posterior horn increase gradually with age, since in the right P.H Group A (10 – 22 Yrs), (mean±Std.deviation) was (.8438±.14127), in group E (62-74 Yrs) = (1.4375±.24187), with

P-value = .000 for both; we found in left P.H Group A (10 – 22 Yrs), (mean±Std.deviation) was .8563±.17115), in group E ages between (62-74 Yrs) = (1.4500±.28983), with p-value = .000 for both. (Table 5.7)

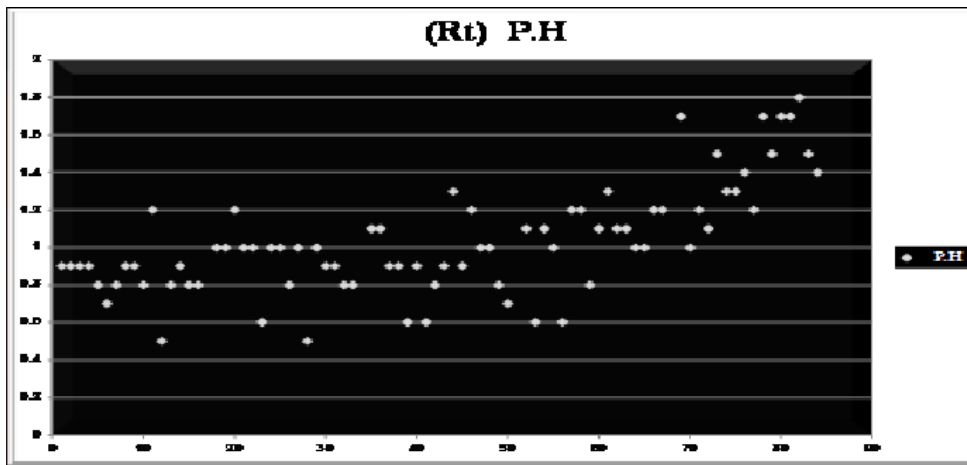


Figure 5.4: represent statistics of (Rt) posterior horn (P.H) in different age group

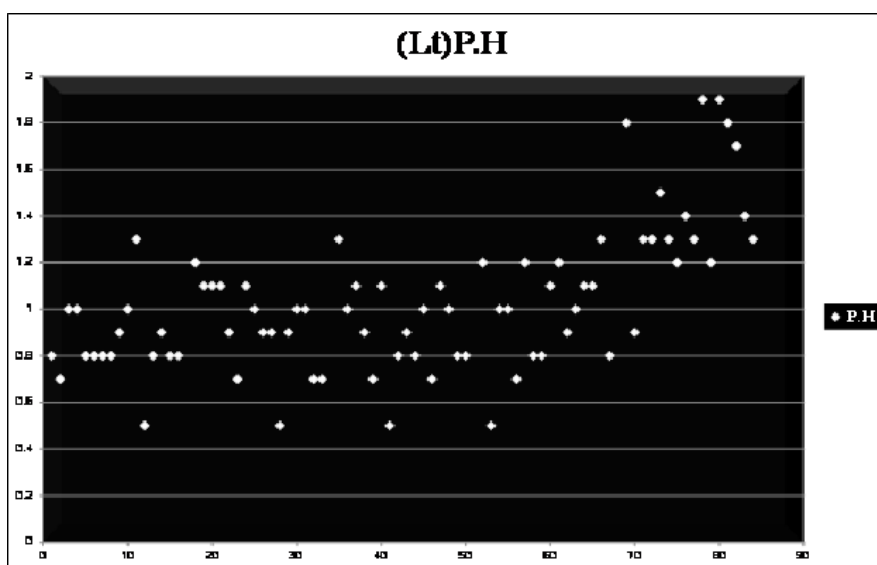


Figure 5.5: Represent statistics of (Lt) posterior horn (P.H) in different age group

As regard brain width (B.W), the statistics being almost the same, in both sex, while (mean± Std.Deviation) in male was (6.1075± .36048), in female (6.0250±.26866), with p-value = .249 (table 5.8).Also no big difference between all age group, when (mean± Std.Deviation) in Group A was (6.2188±.31458), in group E = (6.1000±.35214) (table 5.9).

Table 5.6: Shows statistics of Brain Width (B.W) In both genders

B.W	Male	40	6.1075	.36048	.249
	Female	40	6.0250	.26866	

Table 5.7: Represent statistics of Brain Width (B.W) In both sides and in different Age group

B.W Rt. side	Group A	16	6.1750	.21448	5.70	6.40	.599
	Group B	16	6.0688	.23866	5.60	6.60	
	Group C	16	5.9938	.36782	5.40	6.90	
	Group D	16	6.0437	.26825	5.40	6.70	
	Group E	16	6.0500	.45314	5.40	6.70	
	Total	80	6.0663	.31860	5.40	6.90	
B.W Lt. side	Group A	16	6.2188	.31458	5.70	6.90	.294
	Group B	16	6.1625	.13102	6.00	6.60	
	Group C	16	6.0125	.20616	5.70	6.30	
	Group D	16	6.1063	.30653	5.40	6.70	
	Group E	16	6.1000	.35214	5.40	6.60	
	Total	80	6.1200	.27623	5.40	6.90	

No obvious changes can be noted in ventricular length (V.L) between both sex and two sides in all age group, when (mean ± Std.Deviation) in male was (8.4800 ± .99207), in female (8.2225±.81193) with p-value = .208 for both (table 5.10), and figure 5.6.

Table 5.8: shows statistics of Ventricular length (V.L) In both genders

V.L	Male	40	8.4800	.99207	.208
	Female	40	8.2225	.81193	

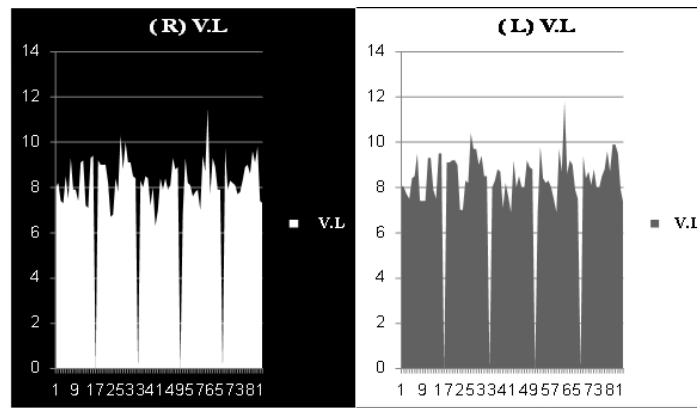


Figure 5.6: Represents detailed statistics of ventricular length (V.L) of two sides in different age group

Regarding ventricular / brain ratio, we found that in our results there is an unexplainable decrease in the ratio in group C (36-48 years), and an increase in group E (62 – 74 years) (due to brain atrophy). On the other hand, this ratio remains equal in both genders, and in two sides (table 5.9&5.10).

Table 5.9: represents cerebral ventricles / brain ratio in both sides and in both genders

RT Ventricle to Brain Ratio In Total Sample (80)	Lt Ventricle to Brain Ratio In Total Sample (80)
1.1 / 6.12	1.1 / 6.15
RT Ventricle to Brain Ratio In Males (40)	Lt Ventricle to Brain Ratio In Males (40)
1.13 / 6.11	1.15 / 6.13
RT Ventricle to Brain Ratio In Females (40)	LT Ventricle to Brain Ratio In Females(40)
1.13 / 6.03	1.12 / 6.11

Table 5.10: represents right and left cerebral ventricles / brain ratio in different age groups

Age group	RT ventricle to brain Ratio	Age group	LT ventricle to brain Ratio
A	1.02/6.18	A	1.01/6.21
B	1.16/6.07	B	1.19/6.16
C	0.89/5.99	C	0.93/6.01
D	1.09/6.04	D	1.07/6.01
E	1.46/6.05	E	1.48/6.1

7. Discussion

The ventricular system is a cavity of the brain, the two largest ventricles are the lateral ventricles in the cerebrum; the third ventricle is in the diencephalon of the forebrain between the right and left thalamus; and the fourth ventricle is located at the back of the Pons and upper half of the medulla oblongata of the hindbrain.

Regards sex-related differences, and according to our findings, there is significant statistical difference between genders where the body of lateral ventricles in both sides was found bigger in males than females Sudanese population, although no significant statistical difference between genders concerning anterior horn of the lateral ventricles. Moreover the size of right and left anterior horn increases with increasing age in different age group, and from mentioned statistical data, we can realize that, left anterior horn bigger than right one in all age group (dominant hemisphere).

Besides that, the body of lateral ventricles in both sides for all age groups, was found there is no significant statistical difference, except obvious reduction in size of the body of lateral ventricle in Group C (36-48 years), in both sides; and increase in its size in group E (62- 74 years).

However, regarding the posterior horn (P.H) sex-related differences, obviously you can realize that no big differences between genders in our statistics, despite that the size of posterior horn increase gradually with age.

Although no significant statistical difference in the brain length in all age group, it is bigger in males than females' Sudanese population. In the other hands in our statistical data, brain width and ventricular length of the lateral ventricles, both share no significant statistical differences between genders and in all age group.

Most of the morphometric studies on the effect of gender and age on the cerebral ventricles /brain ratio were carried out in western countries on the Caucasian population and a few studies were performed in the East Asian and Indian population.

Although many of the studies in these areas have noted increments in lateral ventricle size associated with advancing age, few studies have addressed the issue of gender differences in this measure (Barron and his colleagues 1976)[10].Of those that have, two found no gender differences within an aged sample of normals (20% male subjects) [11]. And within a sample of schizophrenic subjects [9]. Early studies utilizing linear measures found that men had larger lateral ventricular dimensions than women [12-15]. a recent publication recommends controlling for skull size, which is reported to reduce the gender differences to statistically non significant levels [11].

In another study carried out in 100 normal brain adults with Computed Tomography by Gyldensted C and his colleagues (1977). [15] In his study he found that the left lateral ventricle was larger than right in both sexes and both lateral ventricles are larger in males. The linear measurement of lateral ventricles demonstrated positive correlation to cranial size while width of third ventricle was independent of size of the skull.

In our study the size of the anterior horn of lateral ventricle was increasing with age, and no significant

differences between gender and this results was similar in concern of age to those done by Barron and his colleagues 1976). And different related genders; but (Earnest and his colleagues 1979) , state that no gender differences within an aged sample of normals, which was similar to our results.

Our results regard the body of the lateral ventricles was that, the body of lateral ventricles in both sides has significant difference between males and females, and right & left side, which similar to the study carried out by Hang and his colleagues 1977). In our study we found that in males the left side was slightly bigger compared with right side and vice versa in females, which not fully similar as Gyldensted C and his colleagues (1977). Studied the brains of 100 normal adults with Computed Tomography. In his study he found that the left lateral ventricle was larger than right in both sexes and both lateral ventricles are larger in males.

Regard ventricular / brain ratio, we found that in our results there is unexplainable decrease in the ratio in group C (36-48 years), and increase in group E (62 – 74 years) (due to brain atrophy).

In other hand this ratio remains equal in both genders, and in two sides. This resembles results done by Earnest and his colleagues 1979).

8. Conclusion

The advent of MRI scanning resolved the problem of volumetric measurement performed on normal subjects. The ventricles of the brain are well visualized, and their overall configuration can be reconstructed from a series of contiguous slices. The evaluation of the normal measurements of the cerebral ventricles in the living human has great importance in the diagnosis and monitoring of several pathologies.

Morphometric studies of human brain ventricles have been under focus by many scholars recently due to it is relation with pathologies evidences such as hydrocephalus, schizophrenia, tumors, Trauma... etc., as well as gender and aging which could lead to dementia and or brain geriatric.

This study concluded that regarding sex related difference in Sudanese population our finding reported there is significant statistical difference between genders where the body of lateral ventricle was found to be larger in male than female. Thus, no significant statistical difference between genders concerning the anterior horn and posterior horn.

Regarding the age effect on the size of the lateral ventricle, in our study in Sudanese population, the size of the right and left anterior horn of lateral ventricle was increasing with age, this fact also true concern the posterior horn in both sides.

Concerning the body of lateral ventricle, there is slight increase in its size with age, with marked reduction in size of the body of lateral ventricle in Group C (36-48 years), and this results not found in literature, so that our study concluded that variability regarding lateral ventricle parameter in Sudanese population and different area in the world could be due to racial/ ethnic factors, especially in Sudanese.

Regarding ventricular / brain ratio, we found that in our results there is an unexplainable decrease in the ratio in group C (36-48 years), and increase in group E (62 – 74 years) (due to brain atrophy). In other hand this ratio remains equal in both genders, and in two sides.

9. Limitations of study

- Small sample size

10. Recommendations

- Large sample size studies for future.
- Further studies should be performed in order to estimate differences among various ethnic/races especially in Sudan and to establish the normal standard data in Sudanese population.
- We need to settle out the changes occurred in lateral ventricle in specific group as alcoholic ones, just only to shed light for this neglected sector of society.

References

- [1,2,3] Medscape Drugs & Diseases Author: Elena Crisan, MD; Chief Editor: Selim R Benbadis, MD: Sep 04, 2013.
- [4,5,6,8] Lectures of Human Anatomy Neuroanatomy Ventricular System and CSF By DR. Abdel-MonemAwadHegazy MB, BCh with honor 1983, Diploma.
- [9] Enlargement of the lateral ventricles has been observed in alcoholism, normal aging, depression, dementia, and schizophrenia (Carlen et al. 1978; Luchins et al. 1979; Weinberger et al. 1979, 1982; Andreasen et al. 1982; Frangos and Athanassenas 1982; Jernigan et al. 1982a, b; Schulz et al. 1983; Luchins et al. 1984; Scott et al. 1984; Targum et al. 1984).
- [10] Gender differences in lateral ventricle measurement (Barron et al. 1976; Haug 1977; Gyldensted 1977; Earnest et al. 1979; Zatz et al. 1982). <https://www.books.google.com/books>.
- [11] In cross-sectional studies of healthy aging, lateral ventricle size increases (Earnest, Heaton, Wilkinson, &Manke, 1979; Gyldensted, 1977; Hughes &Gado, 1981; Schwartz et al., 1985; Soininen, Puranen, &Riekkinen, 1982; Zatz, Jernigan, &Ahumada, 1982).
- <https://www.books.google.com/books>.
- [12] Measurements of the normal ventricular system and hemispheric Sulci of 100 adults with computed tomography (Hang et al.1977). *Neuroradiology*. 1977 Dec 31; 14(4):183-92.
- [13] Marjorie Le May'1984 this article appears in the May 1 June 1984 issue of AJNR and the August 1984 issue of AJR. Received November 19.1982; accepted after revision November 1. 1983.1 Department of

Radiology, Massachusetts General Hospital and Harvard Medical School, Boston, MA 02114. *AJNR* 5:269-275, May 1 June 1984

[14] Galwar J, Bull JWD, Du Boulay GH, Marshall J. Computerized axial tomography: the normal EMI scan. *Jour of Neurol, Neurosurgery and Psy* 1975;38:935-47.

[15] Gyldensted, C. and Kosteljanetz, M. (1977) Measurements of the Normal Ventricular System and Hemispheric Sulci of 100 Adult Patients with Computed Tomography. *Neuroradiology*, 14, 138-192. <http://dx.doi.org/10.1007/BF00496982>

<http://link.springer.com/article/10.1007%2FBF00496982>

[16] Monte SM. Disproportionate atrophy of cerebral matter in chronic alcoholics. *Arch Neurol* 1988 Sep;45(9):990-2

[17] Bandiera P, Pirino A, Conti M, Achene A, Montella A. Morphometric analysis of the lateral ventricles in living human. *Ital J Anat Embryology* 1996 Jul-Sep; 101(3):203-9.

[18] D'Souza DMC, Natekar PE. Morphometric study of the ventricular system of Brain by Computerised Tomography. *J AnatSoc India* 2007;56(1):19-24

[19] Garret WJ, Kossoff G, Warren PS. Cerebral ventricular size in children: a two dimensional ultra sonic study. *Radiology* 1980 Sep;136(3):711-5.

[20] Erturk M, Kavalioglu G, Ozer MA, Ozgur T. Morphometry of the anterior third ventricle region as a guide for the transcallosal-interforniceal approach. *Neuro Med Chir* 2004 Jun;44(6):288-92.