



POLITECNICO DI TORINO  
Repository ISTITUZIONALE

ON THE ASSOCIATION BETWEEN HELICAL BLOOD FLOW AND ATHEROSCLEROTIC PLAQUE GROWTH IN CORONARY ARTERIES

*Original*

ON THE ASSOCIATION BETWEEN HELICAL BLOOD FLOW AND ATHEROSCLEROTIC PLAQUE GROWTH IN CORONARY ARTERIES / DE NISCO, Giuseppe; Hoogendoorn, Ayla; Kok, Annette; Chiastra, Claudio; Gallo, Diego; Morbiducci, Umberto; Wentzel, Jolanda J.. - ELETTRONICO. - (2019). ((Intervento presentato al convegno 25th Congress of the European Society of Biomechanics (ESB 2019) tenutosi a Venna nel July 7-10, 2019.

*Availability:*

This version is available at: 11583/2743656 since: 2019-07-26T15:34:00Z

*Publisher:*

25th Congress of the European Society of Biomechanics (ESB 2019)

*Published*

DOI:

*Terms of use:*

openAccess

This article is made available under terms and conditions as specified in the corresponding bibliographic description in the repository

*Publisher copyright*

(Article begins on next page)

# ON THE ASSOCIATION BETWEEN HELICAL BLOOD FLOW AND ATHEROSCLEROTIC PLAQUE GROWTH IN CORONARY ARTERIES

Giuseppe De Nisco (1), Ayla Hoogendoorn (2), Annette Kok (2), Claudio Chiastra (1), Diego Gallo (1), Umberto Morbiducci (1), Jolanda J. Wentzel (2)

1. PoliTo<sup>BIO</sup> Med Lab, Department of Mechanical and Aerospace Engineering, Politecnico di Torino, Turin, Italy; 2. Department of Biomedical Engineering, Erasmus MC, Rotterdam, The Netherlands

## Introduction

Previous findings suggest an atheroprotective role for helical flow, as it mitigates shear stress disturbances in several arterial districts [1][2][3]. Moreover, early stage atherosclerosis in carotid arteries has been shown to be inversely associated to helical flow[2]. In this study, we investigate the possible relationship between helical flow intensity and temporal changes in wall thickness (WT), an hallmark of atherosclerotic plaque growth, in pig coronary arteries.

## Methods

The three main coronary arteries of adult familial hypercholesterolemic pigs on a high fat diet were imaged by computed tomography (CT) angiography and intravascular ultrasound (IVUS) at two time points (baseline - after 3 months on the diet; T2 - after 6.4±1.9 months). Baseline geometries of the imaged coronary arteries (n=15) were reconstructed by fusing CT and IVUS [4]. Navier-Stokes equations were numerically solved using the finite volume method by prescribing personalized boundary conditions derived from individual velocity ComboWire Doppler measurements [3]. For the analysis, each arterial segment was divided into 3mm/45° sectors.

Over each 3mm/45° sector, the cycle- and volume-averaged intensity of helical flow structures ( $h_2$ , given by the integral value of the unsigned internal product of velocity  $\mathbf{v}$  and vorticity  $\boldsymbol{\omega}$  vectors [2][3]) in the near-wall region (10% of the local radius, volume  $V_{NW}$ ) was computed (Eq. 1) according to:

$$h_2 = \frac{1}{TV_{NW}} \int_T \int_{V_{NW}} |\mathbf{v} \cdot \boldsymbol{\omega}| dV dt \quad (1)$$

WT at time points T1 and T2 was measured by subtracting the distance from the lumen center of the semi-automatically segmented outer and inner wall boundaries. For each sector, the mean values of the difference between T2 and baseline WT measurements were evaluated ( $\Delta WT$ ) and normalized to follow-up time. Near-wall  $h_2$  and  $\Delta WT$  data were divided into artery-specific tertiles (low, mid and high). A generalized-estimators equation model was used to perform the statistical analysis of helicity data. Significance was assumed for  $p < 0.05$ .

## Results

The obtained 2D maps of  $\Delta WT$ /month and near-wall  $h_2$  over 3mm/45° sectors values are displayed in Figure

1A, for an explanatory case (Figure 1B). The 2D maps show an appreciable co-localization (63.7% of high helicity sectors) between high near-wall  $h_2$  (light blue) and low  $\Delta WT$ /month (dark blue).

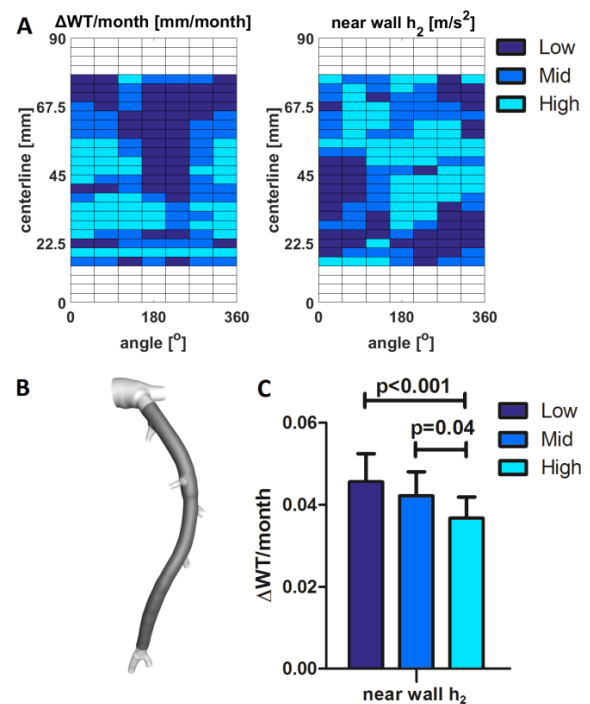


Figure 1: A) 2D map of the plaque growth and near-wall  $h_2$  levels; B) 3D artery model - IVUS imaged arterial segment in dark grey; C) near-wall  $h_2$  vs.  $\Delta WT$ /month.

Overall, coronary segments exposed to high baseline levels of near-wall  $h_2$  exhibit a lower plaque growth per month compared to regions with either mid or low  $h_2$  (Figure 1C).

## Discussions

These findings confirm the physiological significance of helical flow in coronary arteries [3], revealing its protective role against atherosclerotic plaque growth and its potential in predicting regions undergoing WT growth in atherosclerosis progression.

## References

1. Morbiducci et al., J.Biomech., 40:519-534, 2007.
2. Gallo et al., J. R. Soc. Interface, 15(147), 2018.
3. De Nisco et al., Ann. Biomed. Eng., 47(2):425-438, 2019.
4. van der Giessen et al., Int. J. Cardiovasc. Imaging, 26:781-796, 2010.

