



POLITECNICO DI TORINO  
Repository ISTITUZIONALE

Scleral buckling biomaterials and implants for retinal detachment surgery

*Original*

Scleral buckling biomaterials and implants for retinal detachment surgery / Baino F.. - In: MEDICAL ENGINEERING & PHYSICS. - ISSN 1350-4533. - 32(2010), pp. 945-956.

*Availability:*

This version is available at: 11583/2432981 since:

*Publisher:*

*Published*

DOI:10.1016/j.medengphy.2010.07.007

*Terms of use:*

openAccess

This article is made available under terms and conditions as specified in the corresponding bibliographic description in the repository

*Publisher copyright*

(Article begins on next page)

## Scleral buckling biomaterials and implants for retinal detachment surgery

Francesco Baino\*

This is the author post-print version of an article published on *Medical Engineering and Physics*, Vol. 32, pp. 945-956, 2010 (ISSN 1350-4533).

The final publication is available at

<http://dx.doi.org/10.1016/j.medengphy.2010.07.007>

This version does not contain journal formatting and may contain minor changes with respect to the published edition.

The present version is accessible on PORTO, the Open Access Repository of the Politecnico of Torino, in compliance with the publisher's copyright policy.

Copyright owner: *Elsevier*.

*Materials Science and Chemical Engineering Department, Politecnico di Torino, Corso Duca degli  
Abruzzi 24, 10129 Torino, Italy.*

\*Corresponding author: Francesco Baino

Tel.: +39 011 564 4668

Fax: +39 011 564 4699

## **Abstract**

Scleral buckling is a widely used surgical procedure that aims at repairing retinal detachments. Many materials and procedural techniques have been variously proposed and tested in an attempt to find the best combination for providing optimal results to the patient. This review highlights the evolution of scleral buckling implants and chronicles the main advances that have been made in such a context. Specifically, the limitations of the materials and implants fallen in disuse, as well as the advantages of currently adopted devices are critically examined and discussed. Future directions for the research are considered, underlining in particular the great potential carried by the development of accurate mathematical models for describing the postoperative evolution of buckled eye. These analytical models, supported by a comprehensive data set provided by advanced techniques of medical investigations, may become useful tools for helping surgeons to choose, and to design if necessary, the best buckling material and configuration to be used in each specific clinical case.

*Keywords:* Retina; Scleral buckle; Biocompatibility; Eyeball deformation.

## 1. Introduction

Retinal detachment (RD) is a serious pathological condition which can eventually lead to total vision loss in the affected eye if it is not promptly treated [1-3]. In order to treat the RD and depending on its extent, size and features, the surgeon may decide to perform surgical procedures of pneumatic retinopexy, scleral buckling or vitrectomy combined or not with scleral buckling [4-10]. During these surgical procedures, all the retinal holes, if present, must be sealed by laser photocoagulation or cryotherapy in order to preclude the fluid flow into the subretinal space, thereby preventing retinal re-detachments.

Scleral buckling is a widely used procedure for treating RDs: its effect is to maintain the neurosensory retina and the retinal pigment epithelium (RPE) attached to each other until the healing process accompanied by scarring has taken place, thereby ensuring that the retina remains tightly attached thereafter to prevent further RD; in addition, it also contributes to relieve vitreo-retinal tractions [6].

A wide range of natural or synthetic materials has been proposed and tested in the course of scleral buckling procedures carried out on animal models and humans and, at present, most surgeons considers permanent silicone buckle(s) as the “gold standard” choice. However, further improvements can be achieved: for instance, the design and development of resorbable buckles could be very suitable for treating RD in children, as such implants do not carry the need for surgical removal, which is necessary for non-absorbable buckles to allow the normal growth of child’s eye. In addition, recent advances concerning the modelling of eyeball deformation under scleral cerclage open new perspective towards the design of an optimal and tailor-made buckle depending on the peculiar features of each clinical case.

This article, after giving a short overview on eye anatomy and physiology, as well as on the methods commonly adopted in retinal detachment surgery, focuses specifically on scleral buckling procedures and provides a comprehensive picture – at the best of the author’s knowledge – about

the materials used for manufacturing scleral implants. For the first time, the suitability, advantages and drawbacks of the materials currently in use, with particular emphasis on silicone implants, are outlined and extensively discussed and, finally, a forecast for the future is presented.

## **2. Anatomy and functions of the eye: short overview**

The eyeball, or ocular globe, is approximately a spherical shell that is transparent at the front portion and opaque (or nearly so) over the remaining 80% of its surface [11]. The main structures of the eye are represented in Fig. 1. The optical path consists of a series of transparent liquids and solids: beginning from the exterior and proceeding towards the retina, it is possible to find in succession the cornea, the anterior chamber containing the aqueous humour, the iris, the posterior chamber (also containing aqueous humour), the crystalline lens, the large chamber containing the vitreous humour and, finally, the retina. Six extraocular muscles attached to the outer sclera alter the position of the eye and consequently the optical axis; focusing ability (often termed as accommodation) is accomplished by the crystalline lens, which is suspended by ligaments (the so-called zonules) attaching to the inner fibres of the ciliary muscle. Variations in the tone of these muscle fibres allow the zonules to tug on the lens, so that it can change shape to alter the focal length of the eye.

Focusing on the posterior segment of the eye, Fig. 1 shows that the vitreous cavity is surrounded by three different tissue layers, i.e. the retina, the choroid and the sclera. The sclera is an opaque, semi-rigid and stable layer of connective tissue, which provides mechanical support and protection to the intraocular structures and imparts the shape to the eyeball. Choroid is a highly vascularised tissue which is attached to the sclera on its outer side and to the RPE on its inner side. Choroid nourishes the RPE and the other retinal layers. The retina is a highly specialized multi-layered tissue that lines the inner eye wall and is responsible for vision. The light is first absorbed by photoreceptors (rods and cones), then converted to an electrochemical signal and transferred through the neural retinal

cells to the optic nerve, that eventually transmits the impulses to the visual cortex in the brain [12-14]. The vitreous cavity is filled by a transparent gel (vitreous humour or simply vitreous) consisting of water (over 98%wt.), hyaluronic acid, collagens (mainly type II collagen) and small amounts of plasma proteins and ascorbic acid [15-19]. Vitreous can play a significant role in RD phenomenology [19-21]. Age-related changes occur in the vitreous, including the aggregation of collagen fibres into thicker bundles: in this process, called liquefaction, the hyaluronan molecules, previously located around the collagen fibres, become dissociated and form adjacent liquid lacunae [22,23]. These progressive changes evoke a decrease of shock-absorbing ability of vitreous; in addition, due to liquefaction, the vitreous mass gradually shrinks and collapses, separating and falling away from the retina in the course of a phenomenon called posterior vitreous detachment (PVD). PVD may cause problems in the retinal areas where attachment is tight, as the tractional forces can create retinal breaks allowing the access of vitreous fluid into the sub-retinal space.

### **3. Features and treatment of retinal detachment**

#### *3.1. Retinal detachment*

According to the specific pathogenic mechanism, RDs can be divided in three groups [1,6]: (i) rhegmatogenous RD (RRD), (ii) tractional RD (TRD) and (iii) exudative RD (ERD). In RRD, fluid from vitreous cavity enters the sub-retinal space through a full-thickness retinal break; in TRD, the retina is mechanically lifted up as a result of vitreous tractions, for instance induced by the presence of vitreoretinal membranes in the case of diabetic retinopathy; ERD is caused by fluid leakage from blood vessels due to inflammatory diseases. It is worth to underline that TRD and ERD are featured by no retinal holes.

The natural course of RD may vary widely, from asymptomatic self-healing of local detachments to a rapidly occurring total detachment with large retinal tears [3,6,24-26]. The outcome of surgically

treated RD should take into account the evaluation of both anatomic success (retina re-attachment) and functional success (visual acuity recovery) [27]. With modern techniques, anatomic success occurs in more than 90% of cases with one or multiple operations. However, if the detachment includes the macular region, despite a good postoperative anatomical result, the possibility of a correct functional recovery is less than 40% [6].

Usually, RRD occurs in middle-aged or elderly subjects due to the development of retinal tears at sites of abnormal vitreo-retinal adhesion and retinal weakening following PVD; a more limited number of cases derives from accidental ocular trauma [3,6,22,23]. In general, there is an increased risk in patients with severe myopia, lattice degeneration and aphakia/pseudoaphakia, as well as in the subjects affected by the retinopathy of prematurity or inherited retinopathies [1,4,6,28]; specifically, proliferative diabetic retinopathy and proliferative vitreo-retinopathy (PVR) are serious risk factors for TRD [1,6,29-31].

### *3.2. Current methods for treating retinal detachment*

Treatments of RD aim either at preventing further progression of retinal break(s) or at re-attaching the neural retina to the underlying RPE. The first option, essentially based on laser photocoagulation, is used mainly for treating small localized detachments without significant PVR [1,4-6]. For the surgical treatment of RD, three approaches are currently in clinical use [6,7,32]: (i) scleral buckling procedure, (ii) vitrectomy and (iii) pneumatic retinopexy. In any case, it is essential a careful examination and localization of all retinal breaks, that must be sealed to stop the passage of fluid from the vitreous cavity into the sub-retinal space, thereby preventing retinal re-detachments [6].

Scleral buckling involves the support of retinal break area(s) by means of a scleral buckle (Fig. 2), that may be localized on a limited portion of the eye wall (the so-called plombage) or spread on the whole circumference of the eye in the case of multiple or giant breaks (the so-called 360° buckling)

[10]. The implant, which can be placed either episclerally or intrasclerally, creates a buckling effect (indentation) which apposes the neural retina to the underlying RPE. Retinal breaks can be treated by a cryoprobe or laser to achieve local scar formation in order to seal the hole and to maintain the neurosensory retina attached to the RPE. The location and depth of indentation can be monitored during surgery, and it is securely maintained in the desired place by suturing the buckle *in situ*. Normally, the sub-retinal fluid is gradually re-absorbed by the active transport through the RPE, but drainage can be also performed during operation. In the course of a normal follow-up, the implant is progressively surrounded by a collagenous, tough and avascular capsule, that becomes translucent with time. Scleral buckling can be also combined with vitrectomy or, more rarely, air injection in the course of the so-called D-ACE (Drain, Air, Cryotherapy, Explant) procedure. Alternative approaches to buckle implantation, which involved the use of a peribulbarly-placed inflatable silicone balloon for 1-2 weeks in order to achieve a temporary indentation, are also reported [33,34]; today, these procedures have been generally abandoned due the poor long-term results in comparison with the other surgical techniques.

Vitrectomy involves the removal of vitreous humour and its temporary substitution with a gaseous or liquid tamponade agent [8,9,35,36]. This complex surgical procedure may be necessary to completely remove retinal tractions, for instance in the case of TRD and/or if surgeon's view is hindered by bleeding inside the vitreous cavity – which can also results in blurred vision for the patient. The development of an ideal vitreous substitute which can be left in place is a challenging and attractive field of research in ophthalmology; this topic has been reviewed in detail by other authors [8,9,37]. In the course of vitrectomy, the retinal breaks can be treated by cryotherapy, diathermy or laser endophotocoagulation.

Pneumatic retinopexy involves the injection of an expansive gas into the vitreous cavity to flatten the retina for allowing the sub-retinal fluid to be pumped out from beneath it [1,6,7]. The patient's head is properly positioned so that the gas bubble floats exactly to the detached area and presses



against it; cryopexy or laser photocoagulation can be used to seal the retinal tear. The gas bubble is gradually absorbed by the eye while a scar forms around the retinal hole, thereby sealing it securely.

### *3.3. Retinal re-detachment*

Apart from surgical inaccuracies, such as incorrect positioning of buckle(s), incomplete sealing of all retinal breaks and undetected holes, the most common reason of the anatomical failure of retinal reattachment is PVR [29-31]. PVR involves the formation of contractile membranes on both sides of the detached retina and even within the vitreous, that can exert tractional forces on the retina itself thereby preventing its successful reattachment. In addition, already attached retinal regions could re-detach due to the forces of these contractile membranes, formed by proliferating cells, such as RPE cells, fibroblasts, macrophages and glial cells, that have migrated and become attached to the retina. The cells can gain access to the vitreous cavity through retinal breaks but also during surgery. In the course of surgical procedures, it is essential not only to close all the breaks, but also to relieve the retinal tractions, as well as to prevent the formation of new tractions [38]. Especially in the case of severe PVR, the relief of retinal tractions can be successfully achieved by vitrectomy; in milder PVR, less invasive methods can be sufficient, such as external support by scleral buckling implants. PVR causes shrinkage of the retina, making the retinal surface area smaller than that of the underlying choroid; scleral buckles are able to decrease retinal stresses by decreasing the circumference of the eye wall through a proper indentation and provide local support to the area(s) of retinal breaks. Therefore, it should be taken into account that the removal of scleral buckles, due to infection, pain, intrusion or other complications, may carry the risk of retinal re-detachment as there is no longer the relief of retinal tractions induced by the implant [39].

## **4. Biomaterials for scleral buckling**

In the beginning, the design of scleral buckling materials and implants was quite easy: essentially, the surgeon needed an element that would encircle the eye partially or totally along globe equator, thereby creating an indentation that would approximate the neurosensory retina to the underlying RPE. Progressively, surgeons developed new element shapes and styles in order to improve the outcome of the specific applications they had in mind.

Table 1 chronicles the development of scleral buckling materials and implants, that will be described in detail in the following sections: specifically, the advantages and drawbacks of each option will be underlined and discussed. The materials used for scleral buckling (refer to Table 1) were generally experimented in human patients; if studies in animals were also performed, the animal recipient(s) will be specified. Particular emphasis will be devoted to silicone (solid or porous) implants, that, at present, are the only buckles commercially available on the market and routinely used in the clinical practice. Almost 100 style options are currently available to ophthalmic surgeons seeking an implant designed to achieve a particular width, height or shape of buckle. The evolution continues today as surgeons develop new surgical procedures, identify new needs and suggest new styles to meet specific requirements.

## **5. Permanent implants**

### *5.1. Polyviol*

In the early 1950s, Custodis implanted the first permanent buckle by using polyviol as buckling material [40,41]. Polyviol was a red rubber, constituted by poly(vinyl alcohol), Arabic gum and Congo red, that could be compressed over the sclera to about half of its original thickness; the buckle was held in place by means of silk sutures. Over the next few hours after surgery, the explant expanded thereby creating a high buckle that closed the retinal breaks and reattached the retina without drainage of sub-retinal fluid. However, polyviol was abandoned soon as it induced serious

tissue reactions, such as severe scleral infection; in addition, polyviol buckles were considered too bulky, needing long intrascleral sutures along the implants.

### 5.2. Polyethylene

In 1957 Schepens used polyethylene (PE) tubes as either segmental or encircling implants, placing them either intrasclerally or in the equatorial eyeball plane with scleral resection, respectively [42]. PE was attractive due to its easy manufacturing to produce tubes with different diameters, from a surgical viewpoint, a suture could be easily into the tubing lumen for regulating buckle tension and height [42,43]. However, PE tubing was very stiff and exerted a too severe pressure on the ocular globe; therefore, thin tubes (external diameter up to 2 mm) were tested to overcome such drawback, but, in this way, only a poor buckling effect was achieved [10,43]. In addition, the PE rigidity increased *in vivo* with time and the narrow bearing surface of tubes eventually caused erosion of the underlying sclera and choroid [44].

### 5.3. Silicone

At present, silicone is commonly considered the material of choice in scleral buckling procedures due to its excellent biocompatibility, chemical inertness and long-term stability *in vivo*. Silicone implants have been extensively reported to be well tolerated by ocular tissue [6,10,45,46]: in general, a slight inflammatory reaction occurs during the first months after surgery, whereas only a capsule layer without inflammatory cells is detected around the implant after long-term follow-up periods (18-204 months [47]). However, even with careful operative techniques and appropriate materials/implants design, evidences of adverse local tissue reactions and postoperative long-term complications have been occasionally reported, such as persistent inflammation, dramatic increase of intraocular pressure (IOP), scleral thinning/erosion under the implant, intrusion into the vitreous

cavity, migration/extrusion of the implant, alteration of ocular blood circulation, diplopia, pain and foreign body sensation [48-59].

A wide range of style options is currently available for ophthalmic surgeons seeking an implant able to achieve a specific width, depth or shape of buckle. The following sections give a short overview of the different silicone implants developed over time.

### *5.3.1. Solid silicone implants*

The first use of a silicone buckle was reported by Girard [60], who employed a simple cylindrical solid element (Fig. 3a): its softness and elasticity overcame the problem of scleral erosion that featured its predecessor, the PE tube [44]. However, the rod-like shape of the Girard's solid silicone element allowed only a very localized buckling effect on ocular circumference, thereby limiting its actual usefulness [61]. Therefore, a new design was conceived and in 1965 flat bands of various width (Fig. 3b) were proposed and tested as encircling elements [10]. The silicone bands answered the need for a greater lateral support and their flattened configuration (thickness within 0.5-1.0 mm) stretched better and more evenly than rods under the influence of IOP. Today, the typical width of solid silicone bands is within 2.0-2.5 mm; broader silicone strips (3-5 mm) are particularly indicated when the surgeon wants to achieve a wide buckling effect, such as in the cases of serious PVR. In 1993 Gray tested a modified circling band, commonly called silicone lace, that involved the presence of a removable stainless steel aglet attached to one of its ends [62]. The aglet provides a solid place to firmly grasp the band without damaging the silicone and to facilitate the threading of the lace around the globe either intrasclerally through scleral tunnel or episclerally by sutures.

The use of silicone encircling bands led the surgeons to develop a new method of securing the elements in place. In fact, if with previous PE tubing buckles the surgeons could pass the securing suture through the tube lumen to tie the two ends of the element in place [42,43], this approach was no longer possible with solid silicone elements. Hence, tantalum clips were specifically developed

to meet this need: these metal elements were found to be highly biocompatible, ductile and less bulky than sutures, thereby allowing the surgeon to easily adjust the tension of the band; in addition, being tantalum a non-magnetic material, the clips do not cause problems if MRI investigations need to be performed on patients. Another method for holding the band in place, which was developed by Watze in 1963 [63], involves the use of round silicone sleeves (Fig. 3c), through which the ends of the circling elements are threaded from opposite directions.

Grooved silicone strips (Fig. 3d,e) were tested for the first time by Regan et al. in combination with the basic encircling band as versatile means for creating different buckling configurations [64]. In fact, by placing a grooved element under a silicone band, it is possible to increase the width of the scleral region that can be engaged by using an encircling band alone. Furthermore, different buckle configurations could be achieved by changing the geometry of the grooved underlying element (Fig. 3d,e). At present, the grooved strips are manufactured by an extrusion process in several appropriate sizes and shapes, and their choice depends on the specific height, width and profile required by the final buckle.

As an expansion of the concept of grooved strips, Schepens et al. [61] proposed the use of encircling silicone “tyres” having a groove in their outer surface for the placement of a silicone band (Fig. 3f); often, only a small segment of the tyre is necessary. Silicone tyres are stiffer than grooved strips, as they are manufactured by moulding the silicone rubber into a particular shape; this is a significant advantage because it is possible to impart such implants an inner curvature approximating that of the eyeball. Therefore, silicone tyres are easy to be placed and, although they remain soft and pliable, the moulded geometry can create a buckle of a desired shape. Silicone tyres, which are commercially available in different configurations (basically convex, concave and asymmetric geometry), are particularly suitable for treating multiple retinal breaks spread on a large area and for counteracting the vitreous tractions in the case of TRD.

Meridional implants (Fig. 3g) were introduced with the aim of minimizing the postoperative problems associated to retinal puckering along the posterior edge of a large retinal tear [64]. In

order to prevent these complications, a wide buckle is required in the critical region around the retinal break(s): meridional implants, used in conjunction with a traditional silicone band, can successfully broaden the buckling area for preventing retinal folding after sub-retinal fluid release. Silicone wedges, which are properly shaped to follow the eyeball curvature [65,66], can be also used for high and wide local buckles (Fig. 3h).

### *5.3.2. Sponge silicone implants*

In 1965, Lincoff was seeking an elastic implant that, like polyviol one, would create a buckle able to increase in height postoperatively so that IOP returned to normal. Solid silicone rods seemed to be too stiff and, therefore, porous silicone elements (sponges) with different pores content were experimentally tested [67,68]. The tissue reactions to silicone sponge were substantially analogous to those observed for solid implants; in addition, the elastic properties of sponge made external drainage of sub-retinal fluid unnecessary in most RD operations, thereby simplifying the surgical procedure. Radially placed round (Fig. 4a) or oval (Fig. 4b) sponges were found to be more effective in closing retinal breaks than the traditional circumferentially oriented implants [69]. Large tears, however, can be treated only with a circumferential buckling; for this purpose, an oval sponge can be successfully used as encircling band in combination with grooved sponge elements with proper thickness able to perform an extensive indentation (Fig. 4c,d). Today, sponges with different length and diameter are commercially available; it should be underlined that sponge thickness has been progressively reduced in modern implants (from 5-6 mm for traditional sponge to 2-3 mm for the so-called “half sponge” shown in Fig. 4e) to minimize the risk of extrusion and subsequent infection at the implant site [70]. In addition, too thick sponges were found to cause problems of ocular motility postoperatively.

Hollow (or tunnel) sponge (Fig. 4f) was designed to be used with a circling band threaded internally through the whole length of the sponge: this allows a high and localized buckle with little reduction of eyeball volume and minimizes the risk of buckle migration.

Oblong (or ellipsoidal) sponge (Fig. 4g) is useful for procedures in which a wide buckle is indicated; in the past, surgeons tried to fulfil this requirement by placing two sponge pieces together in parallel.

Snyder et al. developed the so-called L-shaped sponge (Fig. 4h) for repairing complicate RDs, such as tears that fall slightly behind the buckle [71]. The L-shaped sponge is positioned radially and its function is the same as the meridional solid silicone implants, i.e. the broadening of the area of scleral indentation in the meridian of retinal tear(s).

Silicone sponges were also implanted after impregnation with antibiotics to limit the bacterial colonization of the buckle, but this procedure was demonstrated to be substantially unnecessary and unhelpful [72,73].

#### *5.4. Polytetrafluoroethylene*

The use of solid polytetrafluoroethylene (PTFE) as scleral buckle material was proposed in the mid 1960s by Wolter et al. [74,75], who used Teflon tubes as cerclage elements. However, such implants showed analogous drawbacks to those of PE buckles, as also reported by Deodati et al. [76].

Porous expanded PTFE (e-PTFE), commercially known as Goretex, has been more recently proposed by several authors for scleral buckling procedures [77-81]. Many studies reported the colonization of porous PTFE buckles by fibrocellular tissue, as well as the adhesion to surrounding conjunctival tissue [77-79,81]: colonization by fibrovascular tissue can represent an extra-challenge for the surgeon if implant removal is required in the case of re-operation. Adverse or inflammatory responses of tissues to e-PTFE were minimal or very mild [77-80]: the material was generally well-

tolerated, thereby demonstrating a good biocompatibility, except for the study of Sheu et al. who reported complications associated to massive strong adhesion [81].

In the early 2000s, silicone bands coated with porous e-PTFE have been tested with quite opposite outcomes. Roldan-Pallares et al. [82] used e-PTFE-coated silicone buckles in 32 patients affected by RRD and reported an excellent material biocompatibility without complications throughout the whole follow-up period (11 months). On the contrary, Mortemousque et al. [83,84] reported massive adhesions between material and surrounding tissue accompanied by local inflammatory reaction; the porous e-PTFE layer was also colonized by inflammatory cells and granulomas with calcium deposits were observed.

### 5.5. Hydrogels

Since the early 1970s, three type of hydrogels, i.e. poly(glyceryl methacrylate) (PGMA), poly(2-hydroxyethyl acrylate) (PHEA) and poly[methyl methacrylate-*co*-(2-hydroxyethyl methacrylate)] (MAI), have been widely tested in scleral buckling procedures [10,85-91] and MAI has been commercially available under the name of Miragel for several years. Hydrogels, thanks to their softness, ease of shaping and defined swelling under hydration, have been considered for many years as the revolutionary materials in scleral buckling surgery. Some authors also emphasized the potential of hydrogels to act as devices for the *in situ* release of hydrophilic drugs, which could be an additional advantage over solid silicone implants in controlling infections [92]. After the initial enthusiasm, however, many surgeons realized progressively that hydrogel buckles could induce severe mid-term and long-term complications [93-99]. Specifically, PGMA was found to suffer from a lack of tensile strength when swollen and PHEA exhibited a dramatic tendency to fragment after swelling [95]. MAI implants, which could be placed both intrasclerally and episclerally, seemed to offer better bulk features and were found to promote the formation of a strong surrounding capsule of connective tissue [45,47,100,101]; although after 3 weeks from implantation



a mild inflammatory response was generally detected, after 3 months almost no inflammatory cells were found [88]. In spite of their excellent biocompatibility, however, in many cases MAI buckles need to be removed due to foreign body sensation, ocular motility limitations, subconjunctival bulge or pain complained by patients [96,97,99]. These drawbacks were essentially ascribable to hydrogel overexpansion: Oshitari et al. quantified this problem and reported that the cross-sectional area of MAI implant could increase up to 185% due to excessive swelling [97]. In addition, experimental studies carried out in both rabbits and humans demonstrated that MAI implant became surrounded by a capsule of connective tissue, but the inner surface of this capsule was irregular due to the presence of hydrogel debris and foreign body giant cells, which indicated material fragmentation [45,47,100,101]. Therefore, also MAI implants have been progressively fallen in disuse, particularly due to buckle degradation and friability occurring after about 10 years, as reported by several researchers [93,94,98].

#### *5.6. Other non-absorbable buckling materials*

Materials different from those described in the previous sections have been occasionally used for permanent buckles manufacturing (Table 1).

In 1937 a cotton gauze pad was used to temporarily indent the eye wall for approximating the retinal layer with the choroid: this is considered the first procedure of scleral buckling, but tissue reactions to the material were not studied [102].

In 1958 Arruga tested nylon braided threads, commercially known as Supramid<sup>®</sup>, as encircling elements to overcome the drawbacks related to PE tubes [103]. It should be underlined that these threads were not properly used as a “buckle” but rather for suturing the wall of the eye to create a “fold” which then created a buckling effect. Moderate inflammatory reaction was observed by both Arruga [103] and Witschel et al. [104] around the implant, but the material could cause erosion of the underlying sclera, thereby leading to intrusion to the choroid (the so-called “string-syndrome”).

Commercially available polyester bands (Mersilene<sup>®</sup>) with broadness of ~5 mm were also tested as buckling materials [104-106]; such implants were generally well-tolerated by tissues, but in some cases scleral erosion occurred.

In most cases, surgeons selected polymeric materials as buckling elements, due to their easy manufacturing, shaping and versatility in the course of surgical procedures; an unusual approach was followed by Gloor [107], who indented the eyeball by an episclerally-placed silver clasp. After 6 months, however, it was necessary to remove the cerclage clasp to avoid serious deformation of the ocular globe due to the too high buckling effect.

## **6. Absorbable implants**

A wide range of absorbable materials of biological or synthetic origin has been tested to achieve a temporary buckling effect. Biological materials have been derived from human or animal tissues, and they could be used for performing transplants (autografts, allografts and xenografts) or properly treated for obtaining suitable substances, e.g. collagen or fibrin. Biological materials carry some problems, such as limited availability and morbidity at the harvest site for autologous tissues and risks of viral infections and disease transmission for donor (living or cadaver) tissue; in addition, the resorption rate of such materials can vary greatly depending on their origin.

Synthetic polymers, which have recently re-attracted the interest of researchers, can successfully overcome most problems typical for biological grafts, offer more controllable and predictable absorption kinetics and can be easily tailored to obtain an implant of desired size and shape.

### *6.1. Biological materials*

#### *6.1.1. Tissue transplants*

#### *6.1.1.1. Autografts*

Tendon autograft provided indentation for 3-4 months with good tissue tolerance [108]. Autologous transplants from temporalis muscle and fascia lata evoked minimal histological responses without inflammatory reaction and foreign body giant cells [109-111]. These autologous materials, however, could carry the drawback of morbidity at the donor site. Autologous tarsus was placed by Mortada et al. in a scleral pocket as a segmental buckle, thereby creating an indentation lasting for 2-8 weeks [112].

#### *6.1.1.2. Allografts and xenografts*

Rolled scleral tissue from donor was placed episclerally to create an indentation lasting for a few months [113,114]. Mild and localised inflammatory reaction was observed, without toxicity or necrosis of surrounding tissues; indentation became progressively flatter with time and finally disappeared in about 8 months-1 year [113,114]. Lyophilized sclera with histoacryl tissue adhesive was also tested, and it evoked only a localised inflammatory reaction with good clinical results [115,116].

Dura mater was used by Winter et al. in 76 patients and no complications due to the material were reported [117].

Weissgold et al. successfully used pericardial patch grafts from cadavers for rescuing exposed scleral buckles [118].

Also skin was used as an episcleral and intrascleral implant by Chien et al. [119] and Zeng et al. [120] with generally good clinical results: the local reactions were slight and well-tolerated in most cases, although there were a few patients who experienced serious inflammatory complications.

Donor collagen prepared from cattle tendons was used in form of sheets and placed intrasclerally by L'Esperance [121]. The indentation effect maintained unchanged for 6-8 weeks, then started to

flatten and eventually disappeared in about 10 months; it was observed that the material became part of the surrounding tissues. More recently, Wu et al. [122] prepared and tested collagen/glycosaminoglycan polymers as buckling materials with promising clinical results.

### *6.1.2. Gelatin*

Gelatin is prepared by partial hydrolysis of collagen from animal tissues such as skin or bones; it has been normally used for scleral buckling procedures in form of sheets of adjustable width and thickness within 0.5-1.0 mm [123-130]. Many surgeons found gelatin very versatile and suitable as buckle material due to its ease of shaping to fulfil a wide range of specific surgical needs; however, gelatin presented some drawbacks. For instance, gelatin needed to be hydrated before implantation even for as long as 1 hour, which led to a significant increase of operation time. The major problem associated to the use of gelatin was the persistence of the buckle indentation on the eye wall: the material created a buckle which remained for 1-2 months and then completely disappeared in about 6 months [123-125], but after only 3-4 weeks the implant started to soften and to fragment [124]. In addition, gelatin could induce a mild but persistent inflammatory reaction in ocular tissues; however, it was well defined and localised and no damage to sclera, choroid or retina were generally detected [123,125].

### *6.1.3. Surgical gut*

In the course of experiments performed in dogs and reported by Dellaporta, surgical gut was used as suture material for creating a temporary indentation on the eye wall [131-135]. Specifically, one or two sutures were placed intrasclerally or as encircling elements within scleral folds; a remarkable inflammatory reaction was observed to occur for about 10 days in the choroid and in the ciliary body within the operation site [132-135]. This tissues response could be ascribable either to the

extensive operative technique, as the securing mattress sutures were placed all the way along the encircling scleral folds, or to the presence of intrasclerally-placed gut sutures. The indentation persisted from 5 weeks up to 2 months and then became progressively flatten. The surgical gut was surrounded by fibroblasts, lymphocytes and giant inflammatory cells before its total degradation in 5-6 months [132,134,135] and, finally, after 1 year the sclera was found to be normal again [134,135].

#### *6.1.4. Fibrin*

Fibrin was used in form of a single rod (diameter of 0.6, 0.8 or 1.1 mm) or open-cell sponge and placed intrasclerally in humans [136,137]. The indentation persisted only up to 1 month postoperatively and the clinical results were not very good. In fact, the inflammatory reaction of tissues to the buckling material was mild – histological evaluations carried out after 12 days showed few foreign body giant cells around the implant –, but the retina remained detached in some areas, thereby demonstrating the substantial uselessness of such a buckle [136].

#### *6.1.5. Injectable materials*

Temporary buckles based on injections of different substances into the suprachoroidal space have been also attempted: these procedures produced an adequate buckling effect only for a short time (< 15 days). Smith injected air subsclerally, but the tissue reactions and clinical outcomes were not reported [138]. Sachsenweger et al. used homogenized autologous fat, that was reabsorbed slowly but incompletely from subscleral tissue [139]. Sodium hyaluronate was also tested and it was found to create a temporary buckling effect lasting up to 14 days [140,141]; no inflammatory cells were observed, but there was evidence of a few intrachoroidal cysts and fibrosis in the choroid [141].

A serious problem related to these techniques, which today have been abandoned, was the risk of choroidal perforation during surgery, with subsequent haemorrhage. In addition, the control of buckle shape and size by injection was very poor.

## *6.2. Synthetic materials*

### *6.2.1. Urethane-based polymers*

Polyurethane (PU) sponges were used by Kothe et al. experimentally in rabbits and clinically in human patients [142,143]. In both cases, follow-up studies showed fibrocytes growth and evidences of foreign body reaction after 24 weeks from implantation; however, the buckle structure still remained well distinguishable after 48 weeks. In general, PU sponge was considered to have been incorporated rather than bioabsorbed by surrounding tissues, although PU is known to be slowly reabsorbable [144]. In most patients, after 72 weeks the materials was well-tolerated and no evidences of inflammation were observed [143]; however, PU sponge often exerted a too high buckling effect, thereby inducing a dramatic increase of IOP postoperatively.

Foulds et al. tested an urethane-based polymer as suprachoroidal buckle material [145]: an acute inflammatory reaction was observed after few hours, as well as the persistence of macrophages at the implantation site around the material after a 10-month follow-up period. After 13 months, the material disappeared but local scleral thinning and choroidal fibrosis were detected.

### *6.2.2. Poly(lactic acid), poly(glycolic acid), polydioxanone and related copolymers*

In 1983 Wilson used for the first time absorbable materials, i.e. poly(lactic acid) (PLA), poly(glycolic acid) (PGA) and polydioxanone (PDO), as scleral buckling elements in rabbits [130]. Specifically, the implants were made of braided fibres of PGA, PLA/PGA composite (PLGA) and

PDO (diameter of the final encircling element ~0.5 mm); 1-mm wide bands of PDO were also used. The indentation persisted for 1 month with PLGA and PGA buckles, and for 10 weeks in the case of PDO implants. Minimal foreign body reactions, with giant cells and fibroblasts, were detected for all the implants; the buckles were visible no longer after 6 months. In addition, PLGA buckles were tested in 20 patients as encircling bands: examinations via indirect ophthalmoscopy showed that after 4 weeks there was little or no indentation in 12 patients; in all cases, the indentation has completely flattened by 2 months.

Marti et al. used commercially available absorbable synthetic sutures as rolled nets made of polyfilaments of PGA and PLGA in rabbits and monofilaments of PDO in humans [146-148]. In the animal model, PLGA was completely absorbed by the second month and PGA by the third month after implantation. In patients, PDO absorption began after the fourth month, then the indentation progressively reduced and eventually flattened after 6 months. In general, a mild chronic inflammatory reaction was seen around the implantation site but the materials were described as well-tolerated by ocular tissues.

In the early 1990s, Guthoff et al. tested cylindrical implants made of PLGA and PDO (weight ratio: 7 : 1) in rabbits [149]. The buckles created an indentation that decreased rapidly to ~50% and ~20% of its original size after 15 days and 5 weeks, respectively. A slight inflammatory reaction was observed at the implantation site, but no scleral thinning or infiltration by giant foreign body cells was noticed.

Biardzka et al. used PDO as a single encircling suture placed episclerally in rabbits and human patients: the indentation started to flatten after 3 months and completely disappear in about 5 months [150]. The local tissue reaction around the implant involved the presence of mononuclear and giant foreign body cells up to 3 months after surgery, whereas the suture was replaced by connective tissue by 6 months and, eventually, the sclera returned normal.

Recently, Lansman et al. tested fibrous poly(LD-lactide) (PLDLA) implant as an episcleral buckle in rabbits [151,152]. The tissue reactions were studied in detail in follow-up periods ranging from 3

days to 48 weeks after surgery and, in addition, the results were compared to those obtained with a silicone sponge buckle implanted by analogous procedure up to a 21-week follow-up. In both groups, the depth of indentation decreased over time with comparable rate: specifically, after 21 weeks the indentation was found ~75% of its initial size, and after 48 weeks implant degradation was not complete yet [151]. It is worth underlining that the scar formed by the cryoprobe normally matures during the first postoperative month, keeping the retina attached thereafter; hence, the indentation of PLDLA buckle persisted more than it should have been strictly necessary, but this can be a further “guarantee of security” for a successful long-term outcome.

## **7. Summary of the present strategies**

The procedure to be followed by surgeons for treating RD has to be carefully selected depending on each specific clinical case. Non-invasive procedures based on laser photocoagulation are usually adopted for preventing further enlargements of small retinal hole(s), thereby preventing RRD. [1,4-6]. Pneumatic retinopexy or scleral buckling are commonly used for treating uncomplicated RRDs, whereas in the case of multiple retinal breaks, giant tears or TRD, vitrectomy by itself or the combination between vitrectomy and scleral buckling are adopted [6,7,32,35,36,153].

In most cases, the failure of RD treatment by using scleral buckling surgery is not due to an adverse interaction between tissue and buckle material, but it can be attributable to subsequent PVR complications [29-31,38]. Surgeons have proposed and tested many materials and implant designs (Table 1) in order to seek the best combination able to (i) be easily implanted, (ii) maximize the results for the patient and (iii) minimize adverse tissue reactions. In the author’s opinion, the development of scleral buckling design can be considered “evolutionary” rather than “revolutionary”, as surgeons progressively tried to improve buckle performances and clinical outcomes by overcoming step-by-step some specific drawbacks which featured the implants proposed by their predecessors.



All materials reported in Table 1 but silicone have been progressively abandoned or fallen into disuse. However, a particular mention should be dedicated to hydrogels: in fact, hydrogel implants have been considered for long time superior to silicone ones, especially as they were softer and seemed to carry a lower risk of infection (less than 1% vs. 2-5%) [45,47,92,100,101]. However, hydrogel buckles were found to fragment over time and to cause long-term complications, such as foreign body sensation due to overexpansion and pain for patients [93-99].

At present, silicone is commonly considered the best standard choice in scleral buckling procedures [6,10,45-47]. Silicone scleral implants are hydrophobic, soft, biochemically inert, non-allergenic, stable in a wide range of temperatures, economical and can retain their physical properties for an extended period of time *in vivo*. A tough, collagenous capsule is normally found to develop around the episcleral implants, thereby sealing off the buckle and helping to minimize the opportunity for later infection or migration of buckling element(s). With intrascleral implants, the capsule also grows between the implant and sclera, thereby protecting against tissue erosion. Because silicone does not allow tissue in-growth, the implant can be easily slid out of the capsule in one piece without trauma if cerclage revision does become necessary by a second operation [154-157]. In comparison with solid implants, silicone sponges are more elastic and they produce a high buckle that usually increases postoperatively; sponges are usually placed episclerally, but can be also sutured under scleral flaps if desired.

From surgeon's viewpoint, solid/sponge silicone implants are very versatile, as they are commercially available in a wide variety of shapes to fulfil – at least virtually – every buckling requirement (Fig. 3 and Fig. 4). In addition, such buckles do not require scleral resection and, therefore, allow conservative surgical procedure. If during surgery or postoperatively the buckle is found to be improperly placed, the implant can be re-positioned by moving the anchoring sutures so that the correct position is attained. Finally, if the buckling procedure is not successful, the eye remains sufficiently intact to permit other procedures to be performed.

The low complication rate associated to solid and porous silicone implants involves that there is relatively little demand for new materials, in contrast, for instance, with the situation of vitreous substitutes [8,9,37]. However, open fields of research still remain to be explored, such as the development and investigation of absorbable materials suitable for temporary buckles, that recently have re-attract researchers' interest [122,151,152]. In children and very young patients the use of a permanent silicone buckle could cause severe long-term complications, such as dramatic eyeball deformation of the ocular globe, local decrease of blood circulation and IOP rise while eye grows physiologically; for these reasons, at present a second operation for buckle removal is often necessary. The use of a temporary buckle, manufactured by using synthetic biodegradable polymer, seems to be a good option that allows to overcome all these drawbacks, although it can not be ignored that the short duration of buckle indentation may carry the risk of retinal re-detachment [39].

## **8. Towards an ideal scleral buckling material: an integrate approach**

Although silicone implants are commonly considered the “gold standard” choice and the high variety of styles and designs allows the surgeon to treat successfully a very wide range – at least virtually – of RD requiring a scleral buckling procedure, nonetheless new researches and experimentations are essential to further improve the clinical outcomes of such operations. In the author's opinion, the synergy between advanced techniques of medical investigation such as the high-resolution computerized tomography (CT), magnetic resonance imaging (MRI) and ultrasound imaging (USI), which are able to give accurate information on the buckle-induced geometric changes of the eyeball [158,159], and mathematical models describing such deformations [160-164] may provide a powerful and helpful tool for surgeons not only to optimize the RD treatment procedure, foreseeing in advance the “optimal” buckle configuration, but also to prevent postoperative complications that might occur in the patient's eye. The application of a stretched

buckling band, often coupled with local buckling elements, induces an indentation of the sclera and the choroid beneath the band, thereby causing a decrease of the eye volume and an increase of the IOP. After the surgery, in the course of a couple of days the IOP usually goes back to its nominal value by an autoregulated decrease of aqueous humour and vitreous production within the eye. When the pressure is eventually back to its normal value, the scleral indentation induced by the cerclage band is deeper than immediately after surgery. At present, it is left to surgeon's expertise to predict the final deformation of the eyeball, as well as the IOP rise caused by the buckling. A deep final indentation is desirable, but the IOP must be kept within a physiologically admissible range to avoid serious complications, such as acute glaucoma in the first days after surgery. Furthermore, in some cases the IOP stabilized postoperatively at a value higher than normal, thereby causing mild or even serious glaucoma in the patient. By evaluating through CT, MRI or USI the patient's eye initial geometrical, physical and mechanical features, as well as the RD peculiar characteristics, and then by implementing accurate biomechanical models of buckled eye, which some authors are recently developing [161-164], it could be eventually possible to simulate patient's eye deformation in response to different scleral buckle configurations and, therefore, it would be feasible to tailor an "ideal" scleral buckle – in terms of size, shape, elasticity, optimal position – for each single clinical case.

Besides the case of permanent buckles, an analogous approach could be carried out also for evaluating the optimal configurations of absorbable implants; for this purpose, it is also necessary to take into account the specific polymer formulation as it strongly affects the degradation kinetics of the material. Analytical models able to predict the persistence of buckle indentation as a function of polymer degradation rate, as well as the modifications of implant geometry with time, could actually be very useful tools to help the surgeon in choosing the optimal material/implant in particularly critical cases.

## **Acknowledgements**

Dr. Daniela Dolcino, Head of the Ophthalmology Ward at “SS. Antonio e Biagio” Hospital of Alessandria (Italy) is gratefully acknowledged for stimulating the author in writing this article.

In addition, the author wishes to acknowledge Prof. Pietro Rossi, Head of the Ophthalmology Ward at “San Martino” Hospital of Genova (Italy) for fruitful discussions, useful suggestions and really essential help.

### **Note of the author**

This article is gratefully dedicated to Prof. Giuseppe Heer, Head Emeritus of the Ophthalmology Ward at “Maria Vittoria” Hospital of Turin (Italy) and President of the Italian Foundation against the Retinopathies of Premature Children, who is celebrating 60 years of clinical activity in 2010. He has been a pioneer in treating retinal detachment, especially as far as the retinopathy of prematurity is concerned; the author was one of his patients.

### **References**

- [1] D’Amico DJ. Medical progress – Diseases of the retina. *New Engl J Med* 1994;331:95-106.
- [2] Ciulla TA, Danis RP, Harris A. Age-related macular degeneration: a review of experimental treatments. *Surv Ophthalmol* 1998;43:134-46.
- [3] Li X. Incidence and epidemiological characteristics of rhegmatogenous retinal detachment in Beijing, China. *Ophthalmology* 2003;110:2413-7.
- [4] Wilkes SR. Current therapy of diabetic retinopathy: laser and vitreoretinal surgery. *J Nat Med Assoc* 1993;85:841-7.

- [5] Krauss JM, Puliafito CA. Lasers in ophthalmology. *Lasers Surg Med* 1995;17:102-59.
- [6] Brinton DA, Wilkinson CP. Retinal detachment – Principles and practice. Oxford, University Press Inc, 2009.
- [7] Marcus DM, D’Amico DJ, Mukai S. Pneumatic retinopexy versus scleral buckling for repair of primary rhegmatogenous retinal detachment. *Int Ophthalmol Clin* 1994;34:97-108.
- [8] Chirila TV, Tahija S, Hong Y, Vijayasekaran S, Constable IJ. Synthetic polymers as materials for artificial vitreous body: review and recent advances. *J Biomater Appl* 1994;9:121-37.
- [9] Chirila TV, Hong Y, Dalton PD, Constable IJ, Refojo MF. The use of hydrophilic polymers as artificial vitreous. *Prog Polym Sci* 1998;23:475-508.
- [10] Schepens CL, Acosta F. Scleral implants: an historical perspective. *Surv Ophthalmol* 1991;35:447-53.
- [11] Ross Ethier C, Johnson M, Ruberti J. Ocular biomechanics and biotransport. *Ann Rev Biomed Eng* 2004;6:249-73.
- [12] Yamada E. Some structural features of the fovea centralis in the human retina. *Arch Ophthalmol* 1969;82:151-9.
- [13] Grierson I, Hiscott P, Sheridan C, Tuglu I. The pigment epithelium: friend and foe of the retina. *Proc Roy Microsc Soc* 1997;32:161-70.
- [14] Yokoyama S. Molecular evolution of vertebrate visual pigments. *Prog Retinal Eye Res* 2000;19:385-419.
- [15] Balazs EA. Fine structure and function of ocular tissues – The vitreous. *Int Ophthalmol Clin* 1973;13:169-87.
- [16] Sebag J, Balazs EA. Morphology and ultrastructure of human vitreous fibers. *Invest Ophthalmol Vis Sci* 1989;30:1867-71.
- [17] Sebag J. The vitreous. In: Adler’s Physiology of the Eye, Hart Jr WJ, ed. Mosby, St. Louis, MO (USA), 1992, pp. 268-292.

- [18] Chirila TV, Hong Y. The vitreous humour. In: Handbook of Biomaterial Properties, Black J, Hastings GW, eds. Chapman & Hall, London, 1998, pp. 125-131.
- [19] Sebag J. Macromolecular structure of the corpus vitreus. *Prog Polym Sci* 1998;23:415-46.
- [20] Foos RY. Posterior vitreous detachment. *Trans Am Acad Ophthalmol Otorinol* 1972;76:480-97.
- [21] Sebag J. Ageing of the vitreous. *Eye* 1987;1:254-62.
- [22] Byer NE. Natural history of posterior vitreous detachment with early management as the premier line of defense against retinal detachment. *Ophthalmology* 1994;101:1503-14.
- [23] Los LI, Van Der Vorp RJ, Van Luyn MJA, Hooymans JMM. Age-related liquefaction of vitreous body: LM and TEM evaluation of the role of proteoglycans and collagen. *Invest Ophthalmol Vis Sci* 2003;44:2828-33.
- [24] Haimann MH, Burton TC, Brown CK. Epidemiology of retinal detachment. *Arch Ophthalmol* 1982;100:289-92.
- [25] Hilton GF, McLean EB, Brinton DA. Pathogenesis and natural history. In: Retinal detachment – Principles and practice. San Francisco, American Academy of Ophthalmology, 1995, pp. 1-37.
- [26] Brod RD, Flynn HW Jr. Asymptomatic rhegmatogenous retinal detachment – Review. *Curr Opin Ophthalmol* 1996;7:1-6.
- [27] Anderson DH, Guerin CJ, Erickson PA, Stern WH, Fisher SK. Morphological recovery in the reattached retina. *Invest Ophthalmol Vis Sci* 1986;27:168-83.
- [28] Ivanisevi M, Bojic L, Eterovic D. Epidemiological study of nontraumatic phakic rhegmatogenous retinal detachment. *Ophthalmic Res* 2000;32:237-9.
- [29] Michels RG. Surgery of retinal detachment with proliferative vitreoretinopathy. *Retina* 1984;4:63-83.
- [30] Campochiaro PA. Pathogenic mechanisms in proliferative vitreoretinopathy. *Arch Ophthalmol* 1997;115:237-41.
- [31] Pastor JC. Proliferative vitreoretinopathy: an overview. *Surv Ophthalmol* 1998;43:3-18.

- [32] Norton EW. The past 25 years of surgery. *Am J Ophthalmol* 1975;80:450-9.
- [33] Binder S. Repair of retinal detachments with a temporary balloon buckling. *Retina* 1986;6:210-4.
- [34] Kreissig I, Failer J, Lincoff H, Ferrari F. Results of a temporary balloon buckle in the treatment of 500 retinal detachments and a comparison with pneumatic retinopexy. *Am J Ophthalmol* 1989;107:381-9.
- [35] Lean JS, Boone DC, Azen SP, Lai MY, Linton KLP, McCuen B et al. Silicone Study Group: Vitrectomy with silicone oil or sulfur hexafluoride gas in eyes with severe proliferative vitreoretinopathy. Results of a randomized clinical trial (Silicone Study Report No. 1). *Arch Ophthalmol* 1992;110:770-9.
- [36] McCuen B, Azen SP, Boone DC, Lai MY, Linton KLP, Lean J et al. Silicone Study Group: Vitrectomy with silicone oil or perfluoropropane gas in eyes with severe proliferative vitreoretinopathy. Results of a randomized clinical trial (Silicone Study Report No. 2). *Arch Ophthalmol* 1992;110:780-92.
- [37] Swindle KE, Ravi N. Recent advances in polymeric vitreous substitutes. *Expert Rev Ophthalmol* 2007;2:255-65.
- [38] Foster RE, Meyers SM. Recurrent retinal detachment more than 1 year after reattachment. *Ophthalmology* 2002;109:1821-7.
- [39] Schwartz PL, Pruett RC. Factors influencing retinal redetachment after removal of buckling elements. *Arch Ophthalmol* 1977;95:804-7.
- [40] Custodis E. Bedeutet die Plombenaufnahme auf die Sklera einen Fortschritt in der operativen Behandlung der Netzhautablosung? *Ber Dtsch Ophthalmol Ges* 1953;58:102-5.
- [41] Custodis E. Scleral buckling without excision with polyviol implant. In: Schepens CL, ed., *Importance of vitreous body with special emphasis on reoperations*. St Louis, CV Mosby Co., 1960, pp. 175-82.

- [42] Schepens CL, Okamura ID, Brockhurst RJ. The scleral buckling procedures. I. Surgical techniques and management. *Arch Ophthalmol* 1957;58:797-811.
- [43] Schepens CL, Okamura ID, Brockhurst RJ. The scleral buckling procedures. II. Technical difficulties of primary operations. *Arch Ophthalmol* 1958;60:84-92.
- [44] Regan CDJ. Erosion of the ocular wall by circling polyethylene tubing – A late complication of scleral buckling. *Trans Am Acad Ophthalmol Otolaryngol* 1963;67:335-9.
- [45] D’Hermies F, Korobelnik JF, Caputo G, Mashhour B, Chauvaud D, Pouliquen Y et al. Encapsulation of scleral buckling materials. *Ophthalmology* 1998;105:1079-86.
- [46] Brown DM, Beardsley RM, Fish RH, Kim RY, Wong TP. Long term stability of circumferential silicone sponge scleral buckling explants. *Retina* 2006;26:645-9.
- [47] D’Hermies F, Korobelnik JF, Chauvaud D, Pouliquen Y, Parel JM, Renard G. Scleral and episcleral histological changes related to encircling explants in 20 eyes. *Acta Ophthalmol Scand* 1999;77:279-85.
- [48] Russo CE, Ruiz RS. Silicone sponge rejection – Early and late complications in retinal detachment surgery. *Arch Ophthalmol* 1971;86:647-50.
- [49] Colosi NJ, Yanoff M. Intrusion of scleral implants associated with conjunctival epithelial ingrowth. *Am J Ophthalmol* 1977;83:504-7.
- [50] McMeel JW, Naegele JF, Pollalis S, Badrinath SS, Murphy PL. Acute and subacute infections following scleral buckling operations. *Ophthalmology* 1978;85:341-9.
- [51] Hahn YS, Lincoff A, Lincoff H, Kreissig I. Infection after sponge implantation for scleral buckling. *Am J Ophthalmol* 1979;87:180-5.
- [52] Spencer AF, Newton C, Vernon SA. Incidence of ocular motility problems following scleral buckling surgery. *Eye* 1993;7:751-6.
- [53] Maguire AM, Zarbin MA, Elliott D. Migration of solid silicone encircling element through four rectus muscles. *Ophthalmic Surg* 1993;24:604-7.



- [54] Saatci AO, Durak I, Tongal S, Ergin M. An extruded encircling band straddling the cornea and corneal groove formation – Case report. *Ophthalmol Surg Lasers* 1998;29:991-2.
- [55] Farr AK, Guyton DL Strabism after retinal detachment surgery. *Curr Opin Ophthalmol* 2001;11:207-10.
- [56] Nguyen QD, Lashkari K, Hirose T, Pruett RC, McMeel JW, Schepens CL. Erosion and intrusion of silicone rubber scleral buckle – presentation and management. *Retina* 2001;21:214-20.
- [57] Unlu N, Kocaoglan H, Acar MA, Aslan BS, Duman S. Intraocular intrusion of a scleral sponge implant. *Ophthalmic Surg Lasers Imaging* 2003;34:223-5.
- [58] Deokule S, Reginald A, Callear A. Scleral explant removal: the last decade. *Eye* 2003;17:697-700.
- [59] Lincoff H, Stopa M, Kreissig I, Madjarov B, Sarup V, Saxena S et al. Cutting the encircling band. *Retina* 2006;26:650-4.
- [60] Girard LJ, McPherson AR. Scleral buckling: full thickness and circumferential, using silicon rubber rodding and photocoagulation. *Arch Ophthalmol* 1962;67:409-20.
- [61] Schepens CL, Okamura ID, Brockhurst RJ. The scleral buckling procedures. V. Synthetic sutures and silicone implants. *Arch Ophthalmol* 1960;64:868-81.
- [62] Grey PJ. Tie up retinal surgery with silicone lace. *Retina* 1993; 13:269-70.
- [63] Watze RC. An encircling element connection for scleral buckling procedures. *Am J Ophthalmol* 1963;56:989-91.
- [64] Regan CDJ, Schepens CL, Okamura ID, Brockhurst BJ, McMeel JW. The scleral buckling procedures. VI. Further notes on silicone in primary operations. *Arch Ophthalmol* 1962;68:313-28.
- [65] Pruett RC. The fishmouth phenomenon. I. Clinical characteristics and surgical options. *Arch Ophthalmol* 1977;95:1777-81.
- [66] Pruett RC. The fishmouth phenomenon. II. Wedge scleral buckling. *Arch Ophthalmol* 1977;95:1782-7.

- [67] Lincoff H, Baras I, McLean J. Modifications to the Custodis procedure for retinal detachment. *Arch Ophthalmol* 1965;73:160-3.
- [68] Lincoff H, Mclean JM. Modifications to the Custodis procedure. II. A new silicone implant for large tears. *Am J Ophthalmol* 1967;64:877-9.
- [69] Lincoff H, Kreissig I. Advantages of radial buckling. *Am J Ophthalmol* 1975;79:955-7.
- [70] Olk RJ. Half-thickness sponges for retinal detachment surgery. *Arch Ophthalmol* 1987;105:745-6.
- [71] Snyder WB, Jost BF, Hutton WL, Vaiser A, Fuller DG, Spencer R. L-shaped accessory sponge explant. *Am J Ophthalmol* 1989;108:203-4.
- [72] Refojo MF. Sustained release of antibiotics from scleral buckling materials: II. Silicone sponge. *Ophthalmic Res* 1975;7:459-69.
- [73] Arribas NP, Olk RJ, Schertzer M, Okun E, Johnston GP, Boniuk I et al. Preoperative antibiotic soaking of silicone sponges. Does it make a difference?. *Ophthalmology* 1984;91:1684-9.
- [74] Wolter JR, Fralick FB. Use of teflon in retinal separation surgery. *Trans Am Ophthalmol Soc* 1966;64:185-203.
- [75] Wolter JR, Fralick FB. Use of Teflon in retinal detachment surgery. *Am J Ophthalmol* 1967;63:113-23.
- [76] Deodati F, Bec P, Camezind M. Use of Teflon as an indentation material in retinal detachment surgery. *Bull Soc Ophthalmol Fr* 1971;71:69-71.
- [77] Lobes LA Jr, Grand MG, Rehkopf PG, Johnson B. Polytetrafluoroethylene in experimental retinal detachment surgery. *Ann Ophthalmol* 1981;13:921-3.
- [78] Tawakol ME, Peyman GA, Liu KR, Kaufman KE. Gore-Tex soft tissue bands as scleral explants in rabbits: a preliminary histological study. *Ophthalmic Surg* 1989;20:199-201.
- [79] Korobelnik JF, D'Hermies F, Ducourneau D, Legeais JM, Chauvaud D, Hoang-Xuan T et al. e-PTFE as scleral buckling episcleral implants: an experimental and histopathologic study. *J Biomed Mater Res* 1999;48:807-13.

- [80] Korobelnik JF, D'Hermies F, Chauvaud D, Legeais JM, Hoang-Xuan T, Renard G. Expanded polytetrafluoroethylene episcleral implants used as encircling scleral buckling – An experimental and histopathologic study. *Ophthalmic Res* 2000;32:110-17.
- [81] Sheu SJ, Chou LC, Lee IY, Wang CC. Histopathology of polytetrafluoroethylene (Gore-tex) as a scleral buckle in humans. *Ophthalmic Surg Lasers* 2001;32:245-7.
- [82] Roldan-Pallares M, Awad-El Susi S. Politetrafluoroetileno en la cirugía de indentación escleral. *Arch Soc Esp Ophthalmol* 2000;75:605-9.
- [83] Mortemousque B, Diemer C, Leger F, Barach D, Legeais JM, Williamson W. Evaluation histologique chez le lapin de la biocompatible d'un matériel d'indentation episcleral : le S-PTFEe (noyau en silicone recouvert de polytetrafluoroethylene expansé). *J Fr Ophthalmol* 2001;24:467-73.
- [84] Mortemousque B, Leger F, Velou S, Graffan R, Colin J, Korobelnik JF. S/e-PTFE episcleral buckling implants: an experimental and histopathologic study. *J Biomed Mater Res* 2002;63:686-91.
- [85] Grignolo A, Refojo MF, Calabria GA, Zingirian M. L'emploi des hydrogels synthétiques dans la chirurgie du décollement de la rétine. *Mod Probl Ophthalmol* 1972;10 :153-9.
- [86] Refojo MF, Liu HS. Experimental scleral buckling with a soft xerogel implant: I. Properties of poly(hydroxyethylacrylate) compared with gelatine and other swelling implants. *Ophthalmic Surg* 1978;9:43-50.
- [87] Liu HS, Refojo MF, Henriquez A. Scleral buckling with a soft xerogel implant. II. Experiments in vivo. *Ophthalmic Surg* 1979;10:52-6.
- [88] Refojo MF, Natchiar G, Liu HS, Tolentino FI. New hydrophilic implant for scleral buckling. *Ann Ophthalmol* 1980;12:88-92.
- [89] Tolentino FI, Refojo MF, Schepens CL. A hydrophilic acrylate implant for scleral buckling: technique and clinical experience. *Retina* 1981;1:281-6.
- [90] Refojo MF, Leong FL. Poly(methylacrylate-co-hydroxy-ethyl acrylate) hydrogel implant material of strength and softness. *J Biomed Mater Res* 1981;15:497-509.

- [91] Ho PC, Chan IM, Refojo MF, Tolentino FI. The MAI hydrophilic implant for scleral buckling – A review. *Ophthalmic Surg Lasers* 1984;15:511-5.
- [92] Refojo MF, Leong FL, Chan IM, Tolentino FI. Absorption and release of antibiotics by a hydrophilic implant for scleral buckling. *Retina* 1983;3:45-9.
- [93] Marin JF, Tolentino FI, Refojo MF, Schepens CL. Long-term complications of the MAI hydrogel intrascleral buckling implant *Arch Ophthalmol* 1992;110:86-8.
- [94] Hwang KI, Lim JI. Hydrogel explant fragmentation 10 years after scleral buckling surgery. *Arch Ophthalmol* 1997;115:1205-6.
- [95] Roldan-Pallares M, Sanz JLD, Awad-El Susi S, Refojo MF. Long-term complications of silicone and hydrogel explants in retinal reattachment surgery. *Arch Ophthalmol* 1999;117:197-201.
- [96] Le Rouic JF, Bettembourg O, D'Hermies F, Azan F, Renard G, Chauvaud D. Late swelling and removal of Miragel buckles: a comparison with silicone indentations. *Retina* 2003;23:641-6.
- [97] Oshitari K, Hida T, Okada AA, Hirakata A. Long-term complications of hydrogel buckles. *Retina* 2003;23:257-61.
- [98] Li K, Lim KS, Wong D. Miragel explant fragmentation 10 years after scleral buckling surgery. *Eye* 2003;17:248-50.
- [99] Bernardino CR, Mihora LD, Fay AM, Rubin PA. Orbital complications of hydrogel scleral buckles. *Ophthal Plast Reconstr Surg* 2006;22:206-8.
- [100] D'Hermies F, Korobelnik JF, Savoldelli M, Chauvaud D, Pouliquen Y. Miragel versus silastic used as episcleral implants in rabbits – an experimental and histopathologic comparative study. *Retina* 1995;15:62-7.
- [101] D'Hermies F, Korobelnik JF, Meyer A, Chauvaud D, Pouliquen Y, Renard G. Experimental encircling scleral buckle with silicone and hydrogel: histopathologic and comparative study of 26 rabbit eyes. *Retina* 1999;19:148-57.
- [102] Jess A. Temporäre Skleraleindellung als Hilfsmittel bei der Operation der Netzhautablosung. *Klin Monatsbl Augenheilkd* 1937;99:318-9.

- [103] Arruga H. Le cerclage equatorial pour traiter le décollement rétinien. Bull Soc Fr Ophthalmol 1958;71:571-80.
- [104] Witschel H, Faulborn J. Gewebereaktionen auf Plomben- und Cerclage-material: Polyamid-Silikon-Polyester. Albrecht Von Graefes Arch Klin Exp Ophthalmol 1978;206:217-26.
- [105] Kommerell G. Cerclage mit 5 mm breiten Mersilene-Band. Ber Zusammenkunft Dtsch Ophthalmol Ges 1972;71:644-5.
- [106] Kommerell G, Dunzen R. Mersilene-Band-Cerclage bei prognostisch ungünstiger Netzhautablosung. Ber Zusammenkunft Dtsch Ophthalmol Ges 1977;74:371-6.
- [107] Gloor BP. Operation der Netzhautablosung bei Lochern im Bereich des hinteren Poles mit einfacher, lang vertraglicher Silberspange und Cerclage. Klin Monatsbl Augenheilkd 1977;171:271-7.
- [108] Scott AB. Autograft tendon for scleral buckling. Am J Ophthalmol 1964;57:564-7.
- [109] Havener WH, Olson RH. Encircling fascia lata strips for retinal detachment. Arch Ophthalmol 1962;67:721-6.
- [110] Chilaris G, Liaricos S. Fascia of the temporalis muscle in scleral buckling and keratoprosthesis operations. Am J Ophthalmol 1973;76:35-7.
- [111] Minning CA Jr, Havener WH. Host tolerance of homologous fascia lata in retinal detachment surgery. Arch Ophthalmol 1983;101:475-8.
- [112] Mortada A. Tarsus as buckling material in retinal detachment surgery. Br J Ophthalmol 1969;53:691-3.
- [113] Cibis PA, Knobloch WH. Scleral implants with preserved human sclera. Bibl Ophthalmol 1967;72:293-318.
- [114] Francois J, Verbraeken H, Hanssens M. Scleral pockets and lyophilized sclera in retinal detachments. Ophthalmologica 1979;179:153-7.
- [115] Vygantas CM, Kanter PJ. Experimental buckling with homologous sclera and cyanoacrylate. Arch Ophthalmol 1974;91:126-9.

- [116] Regenbogen L, Romano A, Zuckerman M, Stein R. Histoacryl tissue adhesive in some types of retinal detachment surgery. *Br J Ophthalmol* 1976;60:561-4.
- [117] Winter R, Khorram-Sefat C. Microchirurgie der Amotio retinae mit biologischen Plombenmaterial. *Klin Monatsbl Augenheilkd* 1988;193:611-4.
- [118] Weissgold DJ, Millary RH, Bochow TA. Rescue of exposed scleral buckles with cadaveric pericardial patch grafts. *Ophthalmology* 2001;108:753-8.
- [119] Chien YT. Human skin in retinal detachment surgery. *Chin Med J* 1978;4:277-9.
- [120] Zeng SQ, Shui YB, Hu CZ, Wei HR. Verwendung von homologer Kutis als Plombenmaterial in 1585 Fallenvon Ablatiooperation. *J Tongji Med Univ* 1992;12:54-9.
- [121] L'Esperance FA Jr. Absorbable collagen implant and encircling elements in retinal detachment surgery. *Trans Am Acad Ophthalmol Otolaryngol* 1966;70:212-34.
- [122] Wu WC, Lai CC, Chen HSL, Sun MH, Lee LM, Shih CP et al. Efficacy and safety of biodegradable collagen-glycosaminoglycan polymer as a material for scleral buckling. *Invest Ophthalmol Vis Sci* 2008;49:2673-8.
- [123] Borrás A. Inclusion of absorbable gelatin film between the scleral lamellae in the treatment of retinal detachment. *Am J Ophthalmol* 1961;52:561-5.
- [124] Jacklin HN, MacKenzie-Freeman H, Schepens CL, Tablante RT. Gelatin as an absorbable implant in scleral buckling procedures – A preliminary report. *Arch Ophthalmol* 1968;79:286-90.
- [125] Daniele S, Jacklin HN, Schepens CL, MacKenzie-Freeman H. Gelatin as an absorbable implant in scleral buckling procedures – An experimental study. *Arch Ophthalmol* 1968;80:115-9.
- [126] Levit R, Seelenfreund MH, Freilich DB. Use of ophthalmic gelfilm in retinal surgery. *Ann Ophthalmol* 1975;7:1613-6.
- [127] King LM Jr, Margherio RR, Schepens CL. Gelatin implants in scleral buckling procedures. *Arch Ophthalmol* 1975;93:807-11.
- [128] Tanenbaum HL, Chandra G. Gelatin implants in retina surgery. *Can J Ophthalmol* 1976;11:52-4.

- [129] Freilich DB, Morton H. Absorbable implants in nondrainage procedures for repair of retinal detachments. *Dev Ophthalmol* 1981;2:66-70.
- [130] Wilson RS. New absorbable exoplants using gelatine and synthetic materials. *Trans Am Ophthalmol Soc* 1983;81:966-1033.
- [131] Dellaporta A. Experimental studies on a scleral buckling operation. *Am J Ophthalmol* 1956;42:189-204.
- [132] Dellaporta A. Experiments in scleral buckling. I. Temporary scleral buckling with inclusion of plain surgical gut. *Am J Ophthalmol* 1962;53:593-602.
- [133] Dellaporta A. Experiments in scleral buckling. III. Scleral buckling with inclusion of chromic surgical gut. *Am J Ophthalmol* 1962;53:891-6.
- [134] Dellaporta A. Experiments in scleral buckling. V. Prolonged scleral buckling with chromic surgical gut. *Am J Ophthalmol* 1966;61:768-76.
- [135] Dellaporta A. Experimental and clinical studies on scleral encircling operations. *Trans Am Ophthalmol Soc* 1970;68:595-666.
- [136] Grosz ID, Vereb K, Kerényi G. Scleral buckling with Bioplast fibrin in retinal detachment. *Acta Ophthalmol* 1976;54:408-16.
- [137] Wollensak J, Engels T. Operation der Netzhautablosung bei Makulaforamen mit resorbierbarer Plombe. *Klin Monatsbl Augenheilkd* 1977;171:278-82.
- [138] Smith R. Suprachoroidal air injection for detached retina; preliminary report. *Br J Ophthalmol* 1952;36:385-8.
- [139] Sachsenweger R, Hartwig H. Suprachoroidale (subsklerale) Fettplomben bei Ablatiooperationen. *Klin Monatsbl Augenheilkd* 1975;167:191-8.
- [140] Poole TA, Sudarsky RD. Suprachoroidal implantation for the treatment of retinal detachment. *Ophthalmology* 1986;93:1408-12.
- [141] Mittl RN, Tiwari R. Suprachoroidal injection of sodium hyaluronate as an 'internal' buckling procedure. *Ophthalmic Res* 1987;19:255-60.

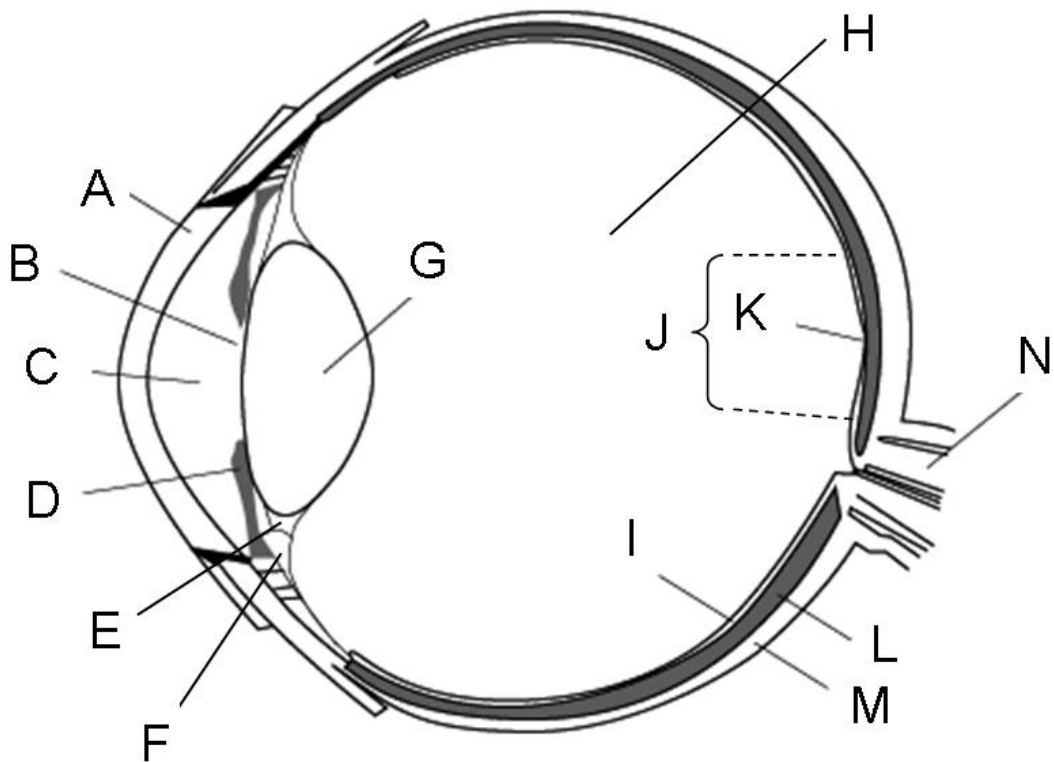
- [142] Kothe HW, Mahnke PF, Lommatzsch P. Tierexperimentelle Testung von Polyurethan-Weichschaum (SYSpur) als episclerales Plombenmaterial. *Klin Monatsbl Augenheilkd* 1985;187:209-11.
- [143] Kothe HW, Lommatzsch PK. Klinische Erfahrungen mit Polyurethan-Weichschaumplomben für die Netzhautchirurgie. *Klin Monatsbl Augenheilkd* 1985;187:273-5.
- [144] Tormala P, Pohjonen T, Rokkanen P. Bioabsorbable polymers: materials technology and surgical applications. *Proc Inst Mech Eng* 1998;212:101-11.
- [145] Foulds WS, Aitken D, Lee WR. Experimental suprachoroidal plombage with a urethane based hydrophilic polymer. *Br J Ophthalmol* 1988;72:278-83.
- [146] Marti R, Burgues L, Gabarro I, Mariella V, Guix M. Explant syntétique absorbable de PDS pour le traitement du décollement de la rétine. *J Fr Ophthalmol* 1986;9:373-9.
- [147] Marti R, Gabarro I, Burgues L, Mariella V, Guix M. New absorbable synthetic explant for the treatment of retinal detachment. *Retina* 1987;7:102-10.
- [148] Marti R, Gabarro I, Burgues LL, Asensi A, Bove JA, Casafont MC et al. Experience sur explants synthétiques pour le traitement du décollement de la rétine. *Ophthalmologie* 1988;2:403-5.
- [149] Guthoff R, Wagner T, Holste J, Winter R. Resorbierbare Plombenmateriale in der Amotiochirurgie – Erste tierexperimentelle Untersuchungen. *Klin Monatsbl Augenheilkd* 1993;202:43-8.
- [150] Biardzka B, Kaluzny J. Experimental and clinical investigations on the suitability of polydioxanone threads for cerclage of the eyeball. *Ophthalmologica* 1988;197:47-50.
- [151] Lansman SM, Karttunen AI, Hirvela HK, Palosaari JT, Kellomaki M, Ella V et al. Persistence of indentation with bioabsorbable poly-L/D-lactide versus silicone sponge scleral buckling implants. *Retina* 2005;25:581-6.
- [152] Lansman S, Paakko P, Ryhanen J, Hirvela H, Kellomaki M, Ella V et al. Hystologic analysis of bioabsorbable scleral buckling implants: an experimental study on rabbits. *Retina* 2005;25:1032-8.



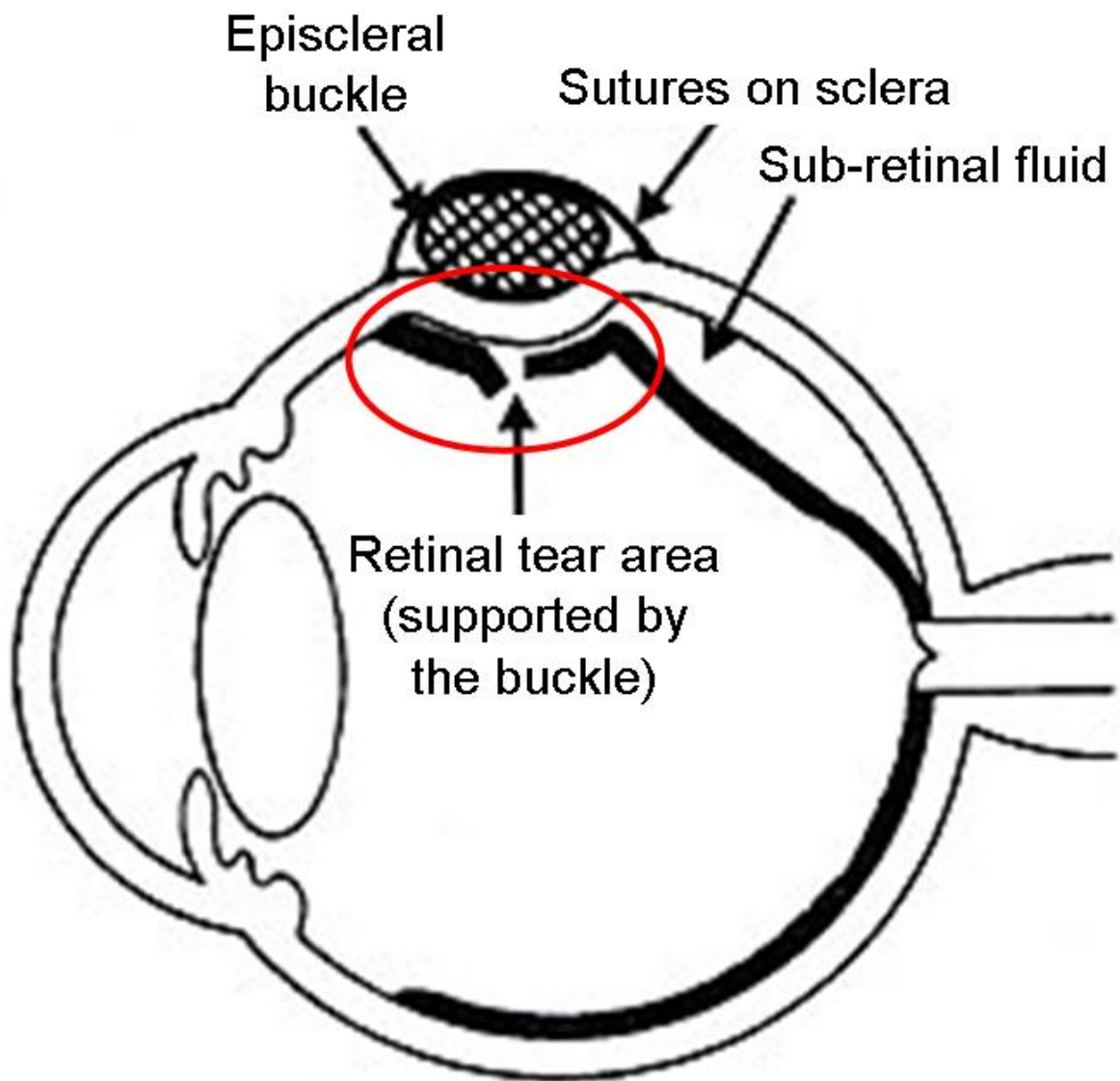
- [153] Heimann H, Bartz-Schmidt KU, Bornfeld N, Weiss C, Hilgers RD, Foerster MH. Scleral buckling versus primary vitrectomy in rhegmatogenous retinal detachment: a prospective randomized multicenter clinical study. *Ophthalmology* 2007;114:2142-54.
- [154] Schepens CL, Okamura ID, Brockhurst RJ. The scleral buckling procedures. III. Technical difficulties of reoperations. *Arch Ophthalmol* 1958;60:1003-12.
- [155] Hilton GF, Wallyn RH. The removal of scleral buckles. *Arch Ophthalmol* 1978;96:2061-3.
- [156] Lindsey PS, Pierce LH, Welch RB. Removal of scleral buckling elements. Causes and complications. *Arch Ophthalmol* 1983;101:570-3.
- [157] Wiznia RA. Removal of solid silicone rubber explants after retinal detachment surgery. *Am J Ophthalmol* 1983;95:495-7.
- [158] Malukiewicz-Winiewska G, Stafiej J. Changes in axial length after retinal detachment surgery. *Eur J Ophthalmol* 1999;9:115-9.
- [159] Wang F, Lee HP, Lu C. Biomechanical effect of segmental scleral buckling surgery. *Curr Eye Res* 2007;32:133-42.
- [160] Friberg TR, Fourman SD. Scleral buckling and ocular rigidity. *Arch Ophthalmol* 1990;108:1622-7.
- [161] Bauer SM, Tovstik PE, Katchanov AB. On the stability of the eye shell under an encircling band. *Tech Mech* 1995;15:183-190.
- [162] Seo JM, Park KS, Yu HG, Chung H. Geometric changes of the eye with an encircling scleral buckle. *J Korean Ophthalmol* 2002;43:1072-80.
- [163] Gonzalez G, Fitt A. The mathematical modelling of human eyes. *Math Today* 2003;39:20-5.
- [164] Keeling SL, Propst G. A mathematical model for the deformation of the eyeball by an elastic band. *Math Med Biol* 2009;26:165-85.

**Figure**

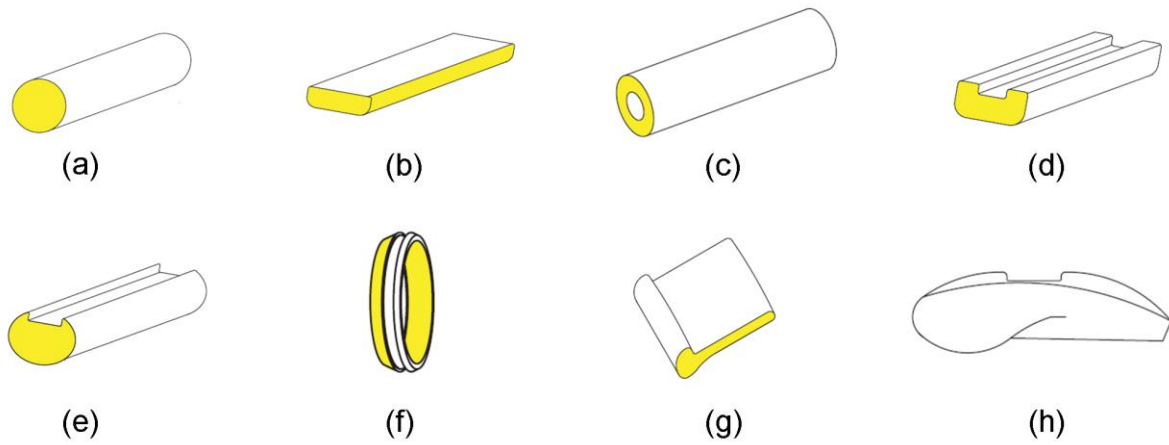
**Fig. 1.** Eye anatomy: A = cornea, B = pupil, C = anterior chamber, D = iris, E = zonules (lens ligaments), F = ciliary body, G = crystalline lens, H = vitreous body, I = retina, J = macular region, K = fovea, L = choroid, M = sclera, N = optic nerve.



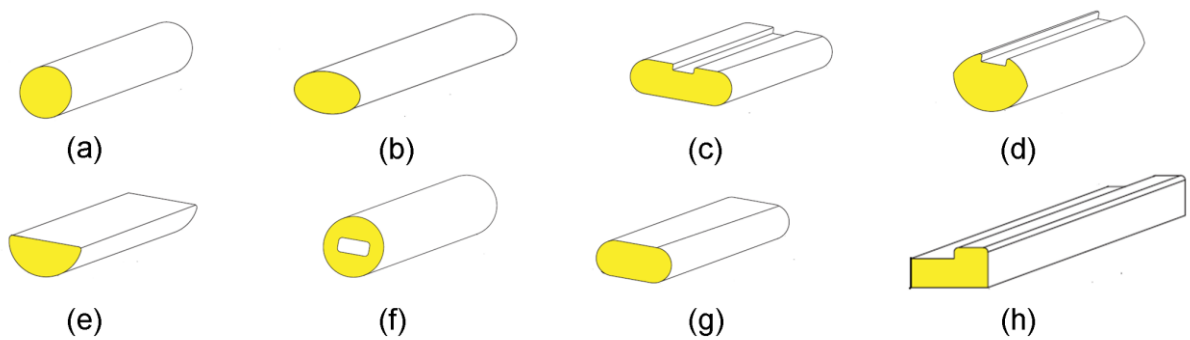
**Fig. 2.** Scleral buckling sutured on the outer sclera.



**Fig. 3.** Some examples of solid silicone implants and related accessories: (a) rod, (b) flat band, (c) round sleeve, (d) and (e) grooved strips with different geometry, (f) asymmetrical tyre, (g) meridional implant and (h) wedge.



**Fig. 4.** Some examples of porous silicone implants: (a) round sponge, (b) oval sponge, (c) and (d) grooved sponges with different geometry, (e) half-thickness sponge, (f) tunnel sponge, (g) ellipsoidal sponge and (h) L-shaped sponge.



## Tables

**Table 1**

Chronology of the key advancements/experimentations in selecting and designing materials and implants suitable for scleral buckling procedures.

Year (first use)	Buckling material	Implant <sup>a</sup>	Type <sup>b</sup>	References <sup>c</sup>
1937	Cotton gauze swab (first scleral buckling procedure)	B	R	[102]
1953	Polyviol	B	P	[40,41]
1956	Surgical gut	S	A	[131-135]
1957	Polyethylene tube	B	P	[42-44]
1958	Nylon threads (Supramid <sup>®</sup> )	S	P	[103,104]
1959	Solid silicone <sup>d</sup>	B	P	[48-50,52-56,58-66]
1961	Gelatin	B	A	[123-130]
1962	Fascia lata (temporalis muscle autograft)	B	A	[109-111]
1964	Tendon (autograft)	B	A	[108]
1965	Silicone sponge <sup>d</sup>	B	P	[48-52,54-59,67-73]
1966	Solid PTFE (Teflon)	B	P	[74-76]
1967	Sclera (allograft)	B	A	[113-116]
1969	Tarsus (autograft)	B	A	[112]
1972	Polyester (Mersilene <sup>®</sup> )	B, S	P	[104-106]
1972	Hydrogels	B	P	[85-101]
1976	Fibrin	B	A	[136,137]
1977	Silver clasp	B	R	[107]
1978	Skin (allograft)	B	A	[119-120]
1981	ePTFE (Goretex)	B		[77-81]
1983	PGA, PLGA, PDO	B, S	A	[130,146-150]

1985	Polyurethane foam	B	A	[142,143]
1988	Dura mater (allograft)	B	A	[117]
1989	Inflatable peribulbar balloon	(B)	R	[33]
2000	ePTFE-coated silicone implant	B	P	[82-84]
2001	Pericardial patch (allograft)	B	A	[118]
2005	PLDLA	B	A	[151,152]
2008	Collagen/glycosaminoglycan polymer	B	A	[122]

<sup>a</sup> B = buckle; S = suture(s) inducing the buckling effect.

<sup>b</sup> P = permanent, A = absorbable, R = surgically removed after a relatively short postoperative period (in general < 6 months).

<sup>c</sup> References numbering refers to the main text.

<sup>d</sup> For the detailed development of silicone implants, see the properly-devoted sections in the text, as well as Fig. 3 and Fig. 4.