

CASE REPORT

Dermatosis caused by *Corythuca ciliata* (Say, 1932) (Heteroptera, Tingidae). Diagnostic and clinical aspects of an unrecognized pseudoparasitosis

M. DUTTO, M. BERTERO*

Medical Entomology Consultant, Santa Croce e Carle General Hospital, Cuneo, Italy; *Chief of Dermatology, Santa Croce e Carle General Hospital, Cuneo, Italy

Key words

Entomodermatosis • Lace bug • *Corythuca ciliata* • Urban green

Summary

The present article discusses three cases of human infestation by *Corythuca ciliata* (Lace bugs), a parasite of plane trees. The cases were all in the Piedmont region of northwest Italy and the symptoms involved a large number of hives on the subjects' bodies which were scarcely or not at all itchy and

which spontaneously cleared up in all the cases in less than 24 hours. It can be concluded that the Lace bug can be an agent of insect-caused dermatosis and this should be considered in examining subjects who visit or live near wooded areas which are infested.

Introduction

Dermatosis caused by parasites is a dermatological pathology which correlates trophic or defensive activity in insects or arthropods and is in general limited to the dermoepidermal layer. Systemic reactions can occur in patients who have developed Type I allergic sensitization [1, 2]. From a clinical point of view classic entodermatitis is an acute inflammatory reaction with the symptoms typical of Lewis's triad: swelling, rash and itching [3]. The clinical picture is the result of several factors: pharmacological effects of substances in the arthropod's secretions or saliva which are toxic or cause itching, the organism's defensive and protective abilities [4], and the effects due to allergic sensitization.

The onset of dermatitis caused by insects is mainly determined by trophic activity of human and/or animal parasites (parasitological entodermatitis) or, more rarely, by phytoparasites [5], household pests [6] or by other arthropods in general (non-parasitological or pseudo-parasitological entodermatitis) [7, 8].

The best-known dermatitis caused by parasites are those caused by fleas, bedbugs [9] and mosquitoes [10], while those which are non-parasitic and caused by phytoparasites are less well-known [5, 11] and difficult to diagnose because it requires a high degree of general entomological and environmental knowledge.

Corythuca ciliata (Say, 1932) is a heteroptera belonging to the Tingidae family (Lace bug) originating from the Nearctic ecozone and is a parasite of plane trees (Fig. 1). It was first observed in Italy in Padua [12] and subsequently has spread all over Italy [13]; it infests (at times heavily) the tree-lined boulevards in cities.

On plants the insect punctures the leaves which results in areas of discoloration; heavily infested plants can sustain diminished photosynthesis and drop their leaves prematurely.

Despite the phytopathological importance, bites on humans from *C. ciliata* have not been reported, but we present here the cases of three such individuals from the Piedmont region of northwest Italy.

Case studies

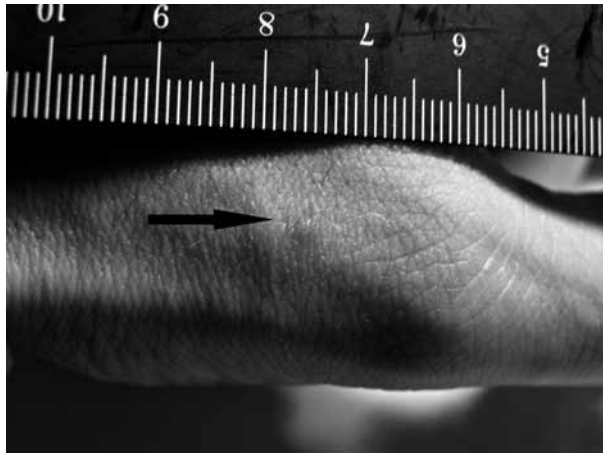
CASE 1

In August 2011 a 23 year old man and 18 year old woman residing in the ASL CN1 Health Services Offices territory presented at the emergency department of the local hospital after having developed a rash during the previous night on the hands, neck and head which was

Fig. 1. Adult specimens of *Corythuca ciliata* (photo M. Dutto).



Fig. 2. Single hive caused by *Corythuca ciliata* from subject in Case 1 after approximately 8 hours after onset (photo M. Dutto).



characterized by approximately 100 tiny hives, 1 mm in diameter (Fig. 2). The lesions were irregularly distributed and were not itchy at the moment the subjects came to the ED; nor did they have fever and during anamnesis nothing particular emerged with regards to exposure to or contact with something infectious or chemical.

Given the clinical conditions the subjects were sent to the dermatology department where the attending physician suspected dermatosis caused by insects though due to the lack of symptoms hesitated to prescribe any treatment prior to consulting with an entomologist. The following day the hives had almost completely cleared up in both subjects.

An entomologist investigated the home and areas where the subjects had been in the 24 hours preceding the onset of their symptoms. The subjects' homes were free of *Cimex lectularius*, *Pulex irritans* and *Ctenocephalides felis*, as well as the principle blood-sucking mites (*Argas reflexus* and *Dermanyssus gallinae*). The evening prior to the eruption of hives the subjects had sat for a significant amount of time on a boulevard, under some plane trees, which it turned out were acutely infested with *Corythuca ciliata*. Subsequent examination of the clothes worn by one of the subjects that evening revealed specimens of the insect.

CASE 2

A 48 year old woman residing in a second-floor apartment in the center of Turin was examined by her dermatologist in August of 2010 after noticing hives that had appeared and reappeared in the preceding two months on the dorsa of both feet. The hives were 1-2 mm in diameter and were neither itchy nor painful. The subject was in excellent health otherwise, without underlying conditions.

At anamnesis the dermatologist suspected the rash had been caused by insects and recommended that the subject be checked by an entomologist prior to prescribing treatment.

An entomological survey of the situation took into consideration the subject's home and other places she had

been when the hives flared up. The absence of hematophagous insects was confirmed, but on the subject's balcony (where she spent a lot of time), there was an extensive quantity of *Corythuca ciliata* specimens, most likely from the adjacent boulevard which was lined with plane trees.

At the suggestion of the entomologist no therapy was prescribed; however it was recommended that the floor of subject's balcony be periodically treated with a permethrin-based product until the infestation on the trees was under control. The subject had no subsequent dermatological flare-ups.

Conclusions

The cases presented here can be classified as insect-caused dermatoses caused by pseudoparasites as the insects involved (*C. ciliata*) are not typically known to be human parasites. In both cases the dermatosis arose from intense plant infestation which resulted in specimens falling onto nearby surfaces which were occupied by the subjects [14]. Insect-caused dermatoses due to pseudoparasites are fairly infrequent events and are distinguished from parasitological dermatoses in that in the former, human reactions are not a result of the insect's primary behavior. These pseudo-parasitoses are typically characterized by being accidental and short-term.

C. ciliata's bite is painless and results in a small (1-2 mm) welt which is usually slightly or not at all itchy. They develop within 2-3 hours of the subject's being bitten but often go unnoticed due to the lack of symptoms. Even the actual moment of the bite usually is unobtrusive enough that it can be unobserved; indeed only one subject (Case 2) complained of discomfort. Signs and symptoms disappear spontaneously within 12 hours without further complications.

Scant reactivity is due to atypical exposure in humans to this insect's bite in addition to the probable inoculation to secretions which in themselves are not particularly toxic. The reaction appears to be a simple inflammatory response to an external irritation.

One problem relative to bites from *C. ciliata* is the diagnosis, which should always involve an entomologist given that the dermatological symptoms are nonspecific and this can lead to inappropriate or ineffective disinfecting of the areas in which the insects are found. Bites from plant parasites can be misdiagnosed and be attributed to mosquitoes [5].

When the suspected cause of dermatosis is entomological it is important to consult with an entomologist who can analyze the case and the environment in order to ascertain what caused the hives [15]. Correct diagnosis is crucial to prescribing the correct therapy as well as deciding the preventative disinfestation measures required in each case.

In diagnosing the typology of dermatitis caused by Lace bugs which infest plane trees a useful clue is to trace back where the subject went prior to the outbreak of the hives and to be aware if it included being in or near

wooded urban areas with plane trees. Pharmacological treatment is not necessary given the that pathology is self-limiting and that the species is not a vector of patho-

genic agents. An emollient or moisturizing cream with or without plant extracts (e.g. aloe or calendula) is sufficient.

References

- [1] Frazier CA. *Allergic responses to biting and stinging insects*. J Asthma Res 1972;10:3-35.
- [2] Steen CJ, Carbonaro PA, Schwartz PA. *Arthropods in dermatology*. J Am Acad Dermatol 2004;50:819-42.
- [3] Saurat JH, Grosshans E, Laugier P, et al. *Dermatologia e malattie sessualmente trasmesse*. Milano: Masson 2006.
- [4] Veraldi S, Caputo R. *Dermatologia di importazione*. Milano: Poletto editore 2000.
- [5] Leigh G, Tiberio R, Filosa G, et al. *Thysanoptera dermatitis*. J Eur Acad Dermatol Venereol 2005;19:722-4.
- [6] Elston DM. *What's eating you? Psocoptera (book lice, psocids)*. Cutis 1999;64:307-8.
- [7] Artola-Bordas F, Arnedo-Pena A, Romeu-Garcia MA, et al. *Outbreak of dermatitis caused by pine processionary caterpillar (*Thaumetopoea pityocampa*) in schoolchildren*. An Sist Sanit Navar 2008;3:289-93.
- [8] Nikbakhtzadeh MR, Tirgari S. *Medically important beetles (Insecta: Coleoptera) of Iran*. J Venom Anim Toxins incl Trop Dis 2008;14:597-618.
- [9] Delaunay P, Blanc V, Dandine M, et al. *Bedbugs and healthcare-associated dermatitis, France*. Emerg Infect Dis 2009;15:989-90.
- [10] Longauer J. *[Insect-bite dermatitis caused by mosquitoes of the species *Culex pipiens molestus*]*. Cesk Dermatol 1966;41:184-5. [article in Slovak].
- [11] Waisman M. *Thrips bite dermatitis*. JAMA 1968;204:82.
- [12] Servadei A. *Un tingide neartico comparso in Italia (*Corythuca ciliata* Say)*. Bull Soc Ent It 1966;96:94-6.
- [13] Binaghi G. *Sulla presenza in Italia del tingide americano del platano *Corythuca ciliata* (Say) (Hemiptera, Tingidae)*. Bull Soc Ent It 1970;102:162-6.
- [14] Tremblay E. *Entomologia applicata*. Collemboli-Rincoti. Napoli: Liguori Editore 1995.
- [15] Stibich AS, Carbonaro PA, Schwartz RA. *Insect bite reactions: an update*. Dermatology 2001;202:193-7.

■ Received on July 20, 2012. Accepted on November 21, 2012.

■ Correspondence: Moreno Dutto, Hygiene and Public Health Service, Local Health Unit CN1, vicolo del Follone, 12037 Saluzzo (CN), Italy - E-mail: moreno.dutto@gmail.com