

Effect of *Irvingia gabonensis* (Aubry-Lecomte ex O'Rorke) Seeds on the Liver and Gonads of Male Albino Rats

Hannah Edim Etta*, Cornelia Chinomso Olisaeke and Cletus Inah Iboh

Biological Sciences Department, Cross River University of Technology, P.M.B. 1123, Calabar, Cross River State, Nigeria.

Email:sarahrhoda@yahoo.co.uk

Abstract

The effect of *Irvingia gabonensis* seeds, on the liver and gonads of male albino rats, was investigated. This investigation was prompted by the increasing international acceptance of the seeds of the African bush mango as being an effective weight reducing herbal medication. Thirty-two (32) male albino rats, were divided into eight groups (A1,A2, B1,B2, C1, C2, D1 and D2), with four rats in each group in a completely randomized design. The treatment regime for the groups were 0mg/kg BW (control) –A1 and A2, 50mg/kg BW – B1 and B2, 100mg/kg BW –C1 and C2 and 150mg/kg BW – D1 and D2 of the test substance respectively. The extract was administered by oral intubation for fourteen (14) days, after which the organs, to be investigated were collected for further histological processing. Photomicrographs of collected organs showed mild to severe degenerative effects on the histology of the organs investigated. The seed extract of *Irvingia gabonensis* had a dose-dependent effect on the organs. Some of the histopathological effects observed in the liver were, sinusoidal dilations (SD), hemorrhaging of the central vein (HCV), inflammation (I) and abnormal distribution of hepatocyte (ADH). Others were, macrosteatosis(M) and macrovesicular fatty infiltrations (MFI). In the testes, arrested spermatogenesis (AS), degenerated germinal epithelium (DGE), absent interstitial cells (AIC), hardened basal cells (HBC) and empty seminiferous tubules(EST) were some of the effects of the seed extract observed. This indicates that seed extracts of *Irvingia gabonensis* could cause degeneration of both liver and testes in the male mammal at high concentrations.

Keywords: *Irvingia gabonensis* seeds, histopathological effects, liver, gonads, and African bush mango

1. Introduction

In recent times, there have been claims verified by clinical trials that the seed extracts of *Irvingia gabonensis* commonly known as 'African Bush Mango' is an effective weight reducing herbal medication, with no known side effects (Ngondi *et al.*, 2009). *Irvingia gabonensis* is a genus of African and south-east Asian trees in the family Irvingiaceae. Other names commonly attributed to it are "Wild Mango" or "Bush Mango"(Matos *et al.*, 2009) . In Nigeria, where both the seeds and fruits are well consumed, it is commonly called "Ogbonno" by the Igbos (Nosiri *et al.*, 2011), "Mbukpabuyo" by the Efik and Ibibio, "Aapon" by the Yorubas, "Ogwi" by the Benin people, "Apioro" by the Deltians and "Goronor" by the Hausas(Oral communication). The seeds are especially valued for their fat and protein rich nut (Ajuk *et al.*, 1999). The genus, *Irvingia* comprises of seven species which include *Irvingia gabonensis*, *Irvingia excels*, *Irvingia gradifolia*, *Irvingia malayaria*, *Irvingia giarobur*, *Irvingia smithii* and *Irvingia wombolu*(Ladipo *et. al.*, 1996).The plant, *Irvingia gabonensis*, bears edible mango-like fruits, and are especially valued for their fat and protein rich nut (Ajuk *et al.*, 1999).

Ethnomedicinal treatments utilize the bark, kernels, leaves, or roots for a variety of ailments (Lowe *et al.*, 2000). The bark is mixed with palm oil for treating diarrhea and for reducing the breast-feeding period. The shavings of the stem bark are consumed by mouth to treat hernias, yellow fever, and dysentery, and to reduce the effects of poison in French Equatorial Africa. The antibiotic properties of the bark help heal scabby skin, and the boiled bark relieves tooth pain also, in certain parts of Africa, the bark extract is ingested to produce an analgesic effect (Okolo *et al.*, 1995). The seeds have been found to reduce fasting blood glucose levels in obese subjects (Ngondi *et al.*, 2005). The powdered kernels act as an astringent and are also applied to burns (Nosiri, 2011). The stems of the tree have been used as chewing sticks to help clean teeth (Fajimi *et al.*, 2007). In Nigeria and Cameroun, the seeds of *Irvingia gabonensis* are used as a condiment in soup (Ndjouenekeu, 1996). Preliminary phytochemical screening of the aqueous leaf extract of *Irvingia gabonensis* revealed the presence of saponins, tannins, phenols and phlobatanins. It has been reported that saponins are of great pharmaceutical importance because of their relationship to compounds such as the sex hormones, diuretics, steroids, vitamin D and cardiac glycosides (Adedapo *et al.*, 2009).

Owing to its' household acceptability as both medicine and soup condiment in many parts of Africa especially, and the world at large (Agbor *et al.*, 2005; Ndoeye *et al.*, 1997; Ngondi *et al.*, 2005), it became necessary to investigate other non-researched effects of the seeds of the African Bush Mango. Hence, this research on the effect(s), if any, on the histology of the liver and the gonads in male albino rats.

2. Materials and Methods

The seeds of African bush mango (*Irvingia gabonensis*) were dried at room temperature for three days and

pulverized using an electronic blender (Laprivia 3000, China). The powdered form of the seeds, was soaked in 1000ml of 90% ethanol, for the period of 24hours, after which the mixture was filtered using a Whatmann filter paper. The filtrate was brought to dryness using a rotary evaporator (model: 4250 Braun company). The paste obtained was used as the stock material for the investigation. Thirty-two(32) healthy male albino rats of about 6weeks old, weighing between 140-360g were purchased from the Department of Physiology, College of Medical Science, University of Calabar to be used as the mammalian model. The experimental animals were randomized into eight groups (A1,A2, B1,B2, C1, C2, D1 and D2), with four rats in each group and were kept in standard cages under standard laboratory conditions (ambient temperature of 25±3°C; relative humidity: 50-55%; 12:12 dark: light cycle) for 14 days with free access to food (rodent chow) and water. Those in group A1 and A 2 served as the control groups. They were not fed with ethanolic seed extract of *Irvingia gabonensis*, while those in groups B1 and B2, C1 and C2 and D1 and D 2 were the treatment groups. The ethanol extract of the seeds of *Irvingia gabonensis* was administered by oral intubation to the treated rats. Groups B1 and B 2 rats were fed 50mg/kg bw, groups C1 and C2 rats were fed 100mg/kg bw and groups D1 and D2 rats were fed 150mg/kg bw of the test substance.

24 hours after last feeding, tissues of liver and gonads were harvested and fixed in 10% formal saline, immediately on removal to avoid autolysis and putrefaction and allowed to fix for about 24 hours, afterward they were surgically grossed and put in tissue cassettes for tissue processing. During surgical grossing representative bits of about 3-4mm were taken from each of the organs. Tissue processing was done according to the methods described by Humason, 1972.

3. Results and Discussion

The control tissues – groups A1 and A2 - (Plates A and B) were still intact showing normal hepatic parenchyma and normal histo-morphology of the testis at low magnification. Liver tissues at the lowest dose (50mg/kg BW) – groups B1 and B2- were also still intact (plate C) showing normal histology of the liver and testes; but at the higher doses – 100mg/kg BW and 150mg/kg BW – the tissues (groups C1 and C2; D1 and D2), showed degenerative changes (plates E - H). Effects of the extracts observed were hemorrhaging of the central vein (HCV; plate E), sinusoidal dilations(SD; plate G) and inflamed hepatocytes (IH; plate E and G). Others were macrosteatosis (M) and microvascular fatty infiltrates.

Effects on the testes observed were also more degenerative at higher doses (groups C1 and C2; D1 and D2). At 100mg/kg BW, testes showed vacuolated seminiferous tubules(VST; plate D), absent leydig cells (ALC; plate D) and hardened basal cells (HBC; plate D and H). Broken spermatids (BS), arrested spermatogenesis (AS) and absent interstitial cells (AIC) were observed at 150mg/kg BW (plate F).

The results presented in the figures A- H show the histopathological effects of the ethanol seed extract of *Irvingia gabonensis* (Aubry-Lecomte ex O'Rorke) on the liver and testes tissues of albino rats. The effects were dose-dependent indicating possible reversibility at withdrawal of administration of the extract (Etta *et al*, 2009). Phytochemical contents of extracts of *I. gabonensis* show a high presence of fatty acids and oils (Adedapo *et al*, 2009). The oils are rich in plant saponins. It has been reported that saponins are of great pharmaceutical importance because of their relationship to compounds such as the sex hormones, diuretics, steroids, vitamin D and cardiac glycosides (Adedapo *et al*, 2009). The effects *I. gabonensis* has on the testis could be due to the steroids-related saponins they contain in their oily fraction. The heamorrhaging of the Central Vein (plate E) in the liver observed may also be caused by the saponins present in the seeds. Haemolysis of red blood cells which results in the heamorrhaging observed in the central veins in the higher treatment groups, seems to result from saponin ability to form complexes with cell membrane cholesterol leading in consequence to pore-formation and cell permeabilization, and also to cause alterations in the negatively charged carbohydrate portions on the cell surface (Abe *et al*. 1981; Melzig *et al*. 2001). The effect *I. gabonensis* had on the morphology of the testis is typical of most medicinal plants in high doses in the testes (Singh and Gupta, 2009). In group D, (150kg/mg) there was arrested spermatogenesis with broken spermatids in the tubules (plate F). This may be as a result of secondary spermatocytes degeneration, which might have in turn, exerted action both in pre- and post-meiotic germ cell activities (Udoh and Kehinde, 2000). Effects observed in group C testes,(100kg/mg), include vacuolated seminiferous tubules, detached germinal epithelium, absent interstitial cells and hardened basal cells(plate D). Occurrence of vacuolization in serminiferous tubules after treatment with extract of *I. gabonensis* seeds, may be due to non-specific reaction caused by testicular damage, in agreement with Chainarong *et al*. (2005) and Grover *et al*. (2005). This could have also resulted in the hardening of the basal cells and detached germinal epithelium (Etta *et al*, 2009). The absent interstitial cells would have also affected spermatogenesis because the Leydig cells produce the teststicular androgen needed for the completion of spermatogenesis, thus, degeneration of the Leydig cells caused by the *I.gabonensis* seed extract, will disrupt spermatogenesis due to insufficient production of testicular androgen (Ekaluo *et al*, 2005). In the liver, inflamed hepatocytes, macrosteatosis and microvascular fatty infiltrates were observed at the highest dose. These effects are known to be induced by the deficiency of methionine and choline, essential amino acids which confer hepatic protective effects on the liver (Rivera *et al*.2008). The microvascular fatty infiltrates observed could have been as a result

of the relatively high fraction of fat recorded to be present in the seed extract of *I. gabonensis* (Ayeni, 2010). Sinusoidal dilations were observed in group C liver, (100kg/mg). This is suggestive of early cell injury caused by a component or components of the administered seed extract. This agrees with reports by Adeline *et al.*, 2010 on their findings when they studied the histopathology and biochemistry analysis of the interaction between sunitinib and paracetamol in mice. Moreover, the oil of *Irvingia gabonensis* is 90% made up of saturated fatty acid and it is known that saturated fat increases the cholesterol concentration, in particular LDL-cholesterol and exposes one to the risks of the cardiovascular diseases. Saturated fatty acids are thought to increase cardiovascular disease risk because they elevate serum total and LDL-cholesterol concentrations relative to monounsaturated and polyunsaturated fatty acids (Ginsberg *et al*, 1998).

4. Conclusion

From the results observed it can be concluded that the ethanol seed extract of *Irvingia gabonensis* had degenerative effects on the histo morphology of both liver and testes tissues of male albino rats at high doses. Despite the beneficial properties of *I.gabonensis* (Akubor, 1996; Ainge and Brown, 2001; Ayeni, 2010, Adeline *at al*, 2010; and Nosiri, 2011), consumption of these seeds should be with caution as it presents as both a potential antifertility and antihepatic agent in the male. Purification and further processing of the sample may also present a less harsh feed meal for consumption.

5. References

- Abe H., H. Konishi, H. Komiya, et al.(1981) Effects of saiko saponins on biological membranes. *Planta Med.*;42:356–363.
- Adedapo A.A. et al.(2009) Blood Pressure Lowering Effect of *Adenanthera pavonina* Seed Extract on Normotensive Rats. *Records of Natural Product* 3:2 82-89.
- Adeline Y.L. L , S. Ignacio, C. Srikumar, A. Sufyan and J. P. Judson (2010). Histopathology and biochemistry analysis of the interaction between sunitinib and paracetamol in mice. *BMC Pharmacology* , 10:14
- Agbor G. A, J. E. Oben, J. Y. Ngogang, X. C. Xin, & J. A. Vinson (2005). Antioxidant capacity of some herbs/spices from Cameroon: A comparative study of two methods. *J. Agric. Food Chem*, 53, 6819-6824.
- Ainge L. and N. Brown (2001). *Irvingia gabonensis* and *Irvingia wombolu* . A State of Knowledge Report undertaken for The Central African Regional Program for the Environment. Oxford Forestry Institute. Department of Plant Sciences. University of Oxford. United Kingdom. <http://carpe.umd.edu/resources/Documents/report-aingebrown2001.pdf>
- Ajuk E.T., B. Duguna, J. Kengue, M. Mouet, T. Tiki Mango and P. Zenkeng, (1999).Uses, management and economic of *Irvingia gabonensis* in the humid lowlands of Cameroon. *Forest ecological management* 113:1-9.
- Akubor P.L.. (1996). The suitability of Africa bush mango juice for wine production. *Plant food human nutrition*, 49.213-219.
- Albert A. (2010) *Irvingia gabonensis* (African/Bush mango). Global Institute for BioExploration – Gibex.
- Chainarong T., R. Jeenapongsa, T. Teakthong, & Y. Smitasiri, (2005). Effects of long-term treatment of *Butea superba* on sperm motility and concentration. *Naresuan University Journal*, 13(2): 11-17.
- Ekaluo U. B., E. A. Udokpoh, U. U. Udofia and O. R. Ajang (2005). Comparative Toxicology of Five Commonly Used Analgesics and Rats Sperm Count And Sperm Morphology. *Global Journal of Pure and Applied Science*, 11:81-84.
- Etta H. E., P. B. Udoh, S. E. Udo, B. Okon and E. E. Eneobong. (2009) Anti- spermatogenic effects of ethanol extract of *Mucuna urens*. Elsevier Journal of Reproduction and Contraception. 20(3) 161-168.
- Fajimi O., M. B. Sarumi, M. N. Olayode, E. O. Gamra, S. I. Sanusi, (2007). *In vitro* propagation of *Irvingia gabonensis*. *African journal of biotechnology*, 6(8): 976-978.
- Ginsberg HN, P Kris-Etheton, B Dennis, PJ Elmer, A Ershow, M Lefevre, T Pearson, P Roheim, R Ramakrishnan, R Reed, S Kent, P Katherine and N Anderson. (1998) Effects of reducing dietary fatty acids on plasma lipids and lipoproteins in healthy subjects. *Anterioscler Tromb Vasc Biol.*;18:441–449.
- Grover A., C.E. Smith, M. Gregory, D.G. Cyr, M.R. Sairam and L. Hermo, (2005). Effects of FSH receptor deletion on epididymal tubules and sperm morphology, numbers and motility. *Mol. Reprod. Dev.*, 72: 135-144.
- Humason G. L., (1972). *Animal tissue techniques*. New York: W. H. Freeman.
- Ladipo D.O., J.M. Foundun, N. Ganaga (1996).*Domestication of bush mango (Irvingia gabonensis): some exploitable intraspecific variations in west and central Africa. Food and agriculture organization*, Rome. Italy.
- Lowe A.J.A. et al. (2000) Conservation genetics of bush mango from central/west Africa: Implications from random amplified polymorphic DNA analysis. *Molecular Ecology*, 9:831-841.
- Matos L., J.M. Nzikou, E. Matouba, V.N. Pandzou-Yembe, T.G. Mapepoulou, M. Linder, S. Desobry (2009). Studies of *Irvingia gabonensis* seeds kernels: Oil technological applications. *Pak. J. Nutr.* 8: 151-157.
- Melzig MF. , G. Bader and R. Loose.(2001). Investigations of the mechanism of membrane activity of selected triterpenoid saponins. *Planta Med.*;67:43–48.

- Ndjouenkeu R., FM Goycoolea, ER Morrisa, JO Akingbala. (1996) Rheology of okra (*Hibiscus esculentus* L.) and dika nut (*Irvingia gabonensis*) polysaccharides. *Carbohydrate Polymers* .;29(3):263-269.
- Ndoye O., M. R. Pérez, & A. Eyebe (1997). *The markets of non-timber forest products in the humid zone of Cameroon*. Network No. 22 Rural Development Forest Network, Overseas Development Institute, London.
- Ngondi J. L, J. E. Oben, & S. R. Minka (2005). The effect of *Irvingia gabonensis* seeds on body weight and blood lipids of obese subjects in Cameroon. *Lipids in health and Disease* 4, 12-15.
- Ngondi J. L, B. C Etoundi., C. B Nyangono., C. M.F. Mbofung and J. E. Oben (2009) (<http://creativecommons.org/licenses/by/2.0>).
- Nosiri I., I. Abdu-Aguye, M.I. Hussaini, E. Abdurahaman(2011) Leaf Extracts Of *IrvingiaGabonensis* Increase Urine Output And Electrolytes In Rats. *The Internet Journal of Alternative Medicine*. Volume 8 Number 2. DOI: 10.5580/223b
- Okolo C. O. et al. (1995) Analgesic effect of *Irvingia gabonensis* stem bark extract. *Journal of Ethnopharmacology*, 45 (2): 125-129.
- Rivera L., R. Moron, M. Sánchez, A. Zarzuelo and M. Galisteo (2008). Quercetin ameliorates metabolic syndrome and improves the inflammatory status in obese Zucker rats. *Obesity*;16: 2081-7
- Singh J. and Gupta D.K.(2009) Corrosion Inhibitive Properties of different plant extract. *Archives of Applied Science Research*;1 (1): 51-56
- Udoh P., and A. Kehinde, (2000). Studies of Anti-fertility Effect of Pawpaw Seed, on the Gonads of Male Albinos Rats. *Phyto-therapy Research* 13: 226-228.



FIG. 1 *Irvingia gabonensis* seeds



FIG. 2 Pulverized *Irvingia gabonensis* seeds

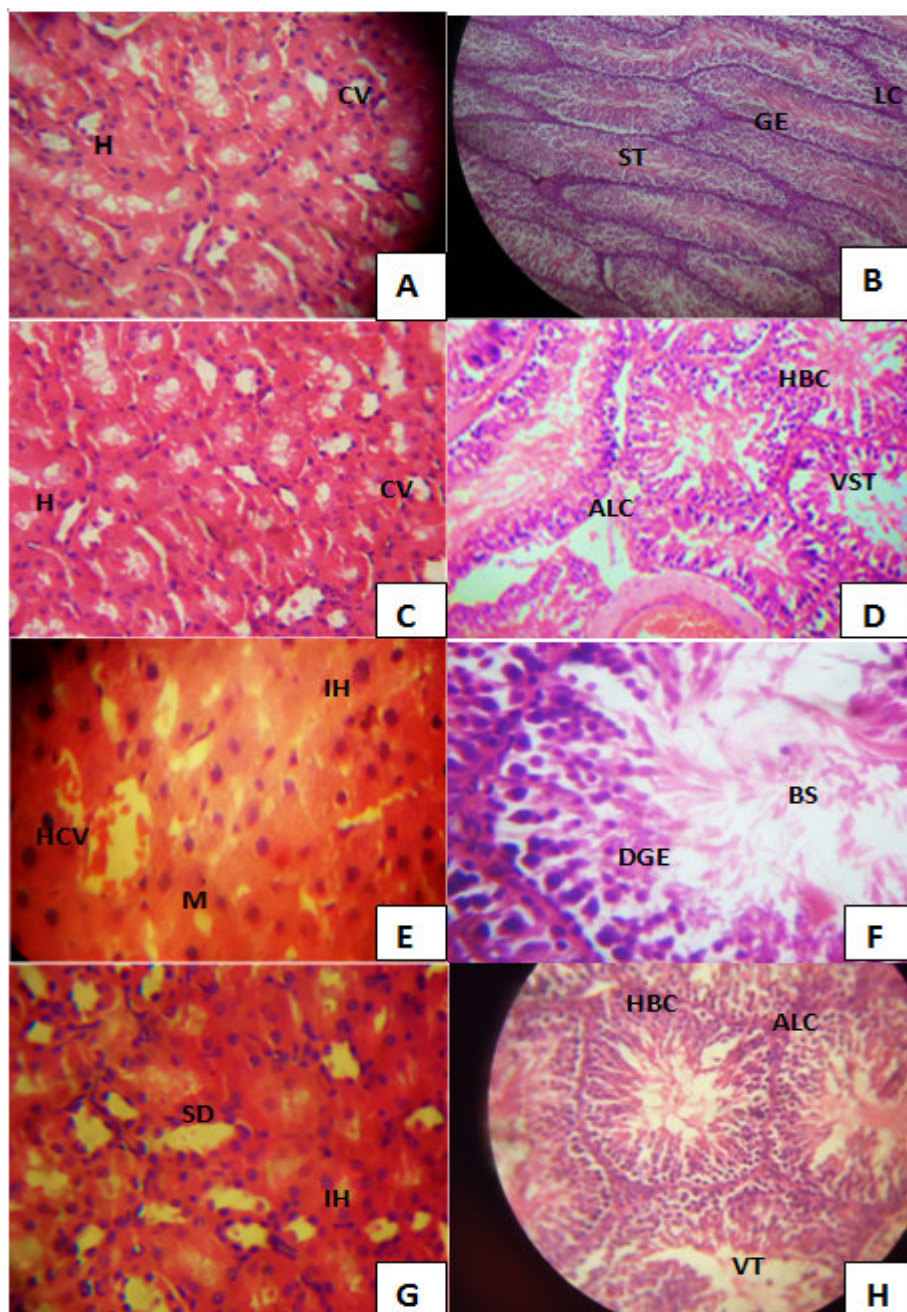


Fig. 3

Legend:

A – Control Liver showing normal hepatocytes(H) and normal central veins(CV).(X 10)

B – Control testes showing normal seminiferous tubule(ST), leydig cells(LC), germinal epithelium(GE) and spermatozoa(S). (X 10).

C - Liver tissue of rats fed 50mg/kg BW of Irvingia extract showing normal hepatic parenchyma(HP).(X 10)

D – Testis of rat fed 100mg/kg BW of Irvingia extract showing vacuolated seminiferous tubules(VST), absent leydig cells(ALC) and hardened basal cells(HBC).(X 40)

E – Liver of rat fed 100mg/kg BW of Irvingia showing hemorrhaging of the central vein(HCV), macrosteatosis (M) and inflamed hepatocytes(IH).(X 40).

F - Testis of rat fed 150mg/kg BW of Irvingia showing Broken spermatids (BS), arrested spermatogenesis(AS), degenerated germinal epithelium(DGE) and absent interstitial cells (AIC).(X 40)

G – Liver of treated rat showing sinusoidal dilations (SD) and inflamed hepatocytes (IH). (X 40)

H – Testis of treated rat showing absent leydig cells(ALC), vacuolated tubules(VT) and hardened basal cells(HBC).(X 10).