

Biochemical and Histopathological Changes in Wistar Rats Following Chronic Administration of Diherbal Mixture of *Zanthoxylum leprieurii* and *Piper guineense*

Kpomah, E.D¹; Arhoghro, E.M² and Uwakwe, A.A¹.

1. Biochemistry Department, University of Port Harcourt, Choba, Rivers State, Nigeria;
2. Department of Medical Biochemistry, Niger Delta University, Wilberforce Island, Bayelsa State, Nigeria.

* E-mail of the corresponding author: denniskpomah@yahoo.com

* Corresponding authors phone number: +234(0)8034173608

Abstract

The effects of chronic administration of three oral doses (50, 100 and 150 mg/kg body weight) of ethanol extract of diherbal mixture of *Zanthoxylum leprieurii* and *Piper guineense* on some biochemical parameters, liver and testicular histology of male wistar rats weighing between 190 – 230 g was investigated. The twenty rats used for the study were randomly divided into four groups of five rats each, group A (Control) were orally administered once daily with 1ml of distilled water (vehicle), the test groups B, C and D received 50, 100 and 150 mg/kg body weight of the extract once daily in 1ml of the vehicle. At the end of the treatment period of 42 days the animals were sacrificed with blood samples, liver and testes collected for analysis. There were significant increase ($P < 0.05$) in aspartate aminotransferase (AST), alanine aminotransferase (ALT) and alkaline phosphatase (ALP) in all test groups in a dose related manner except the 50mg/kg body weight on AST levels. Serum total protein was not influenced significantly ($P > 0.05$), serum albumin (ALB), globulin (GLO), albumin globulin ratio (A/G), total bilirubin (TB) and conjugated bilirubin (CB) were all significantly affected ($P < 0.05$) in a dose related manner except the 50mg/kg body weight on conjugated bilirubin levels. Histopathological examination of testes of the treated group's revealed distortion of seminiferous tubules with no proper coordination between boundaries and delay in the maturation of germ cells which may adversely affect reproductive function, the liver of the treated groups showed micro to macrovesicular steatosis (fatty change) which is an obvious signs of toxicity.

Keywords: Biochemical, Histopathology, Diherbal, *Zanthoxylum leprieurii* and *Piper guineense*

1. Introduction

Plants are able to synthesize a wide variety of chemical compounds and these compounds exhibit marked physiological and pharmacological activities, hence their use as food and as a treasure base of plant drugs for the treatment and management of various disease conditions such as sexual dysfunction, diabetes, rheumatism and hypertension. The use of plant medicine dates back to ancient times, the nearly all year round availability and the relatively cheaper cost of medicinal plants in sub Saharan Africa makes them more attractive as therapeutic agents when compared to the orthodox medicine. (Agbor and Ngogany, 2005; Ojinaka, 2011). The use of herbal medicine is on the increase globally (WHO, 1996), hence the increased interest on research on herbal formulations and preparations (Tilburt and Kaptchuk, 2008).

All through history many herbal preparations have been used as sex invigorators (aphrodisiacs) in the Southern part of Nigeria, one of such is the diherbal mixture of the bark of *Zanthoxylum leprieurii* plant and the seeds of *Piper guineense*.

Zanthoxylum leprieurii locally called Prickly ash or toothache tree occurs in the forest Savanna mosaic of the lowland rainforest and coastal areas. It belongs to the family *Rutaceae*, it is an aromatic, spiny, thicket forming deciduous tree, and the alternate branches are armed with strong brown prickles about 2 - 3cm long, cone shaped with a broad base and found irregularly throughout the tree (Todd, 2008). Ethnomedicinally it is used in the treatment and management of muscle spasm, varicose vein, Raynaud disease, arthritis, rheumatism, neuralgia, flu, fever, sickle cell anaemia, constipation, gastric deficiency, dysentery, diarrhea, toothache and gum disease (Tilloston, 2011).

Piper guineense commonly called climbing pepper are found in the high forest where it cling on trees, it is a slender climber up to 12 m high with prominent nodes and clasping roots, the leaves are elliptic in shape about 15 cm long and 7cm broad, the flowers are small borne on common stalk as clusters opposite the leaves. The fruits are red and turns black when dry (Iwu, 1988). The leaves are used for respiratory infections while the seeds are commonly used as spices and as aphrodisiacs.

Considering the ethnomedicinal use of *Zanthoxylum leprieurii* and *Piper guineense* in the treatment and management of various diseases and the diherbal mixture as an aphrodisiac, the present study was therefore aimed at investigating the effects of chronic administration of the ethanol extract of the diherbal mixture on liver

function, liver and testicular histology of Wistar rats.

2. Materials and Methods

The plant samples were bought in a local herb market in Warri, Delta State, Nigeria. Both species were identified and confirmed at the Herbarium of the Department of Plant Science and Biotechnology of the University of Portharcourt, Rivers State.

2.1 Preparation of Plant Extract

The bark of *Zanthoxylum leprieurii* plant and the seeds of *Piper guineense* were thoroughly washed with distilled water to remove debris and contaminants, they were then dried in an oven at 40°C until a constant weight was reached, and then pulverized using an electric blender (Blender, 462 Nakai Japan). 200 g of the powdered mixture (i.e 100 g each of *Zanthoxylum leprieurii* and *Piper guineense*) was extracted in 600ml of absolute ethanol for 24 hours at room temperature with constant shaking using a flask shaker (Model, Denly A - 500). The extract was filtered with Whatman No 1 filter paper and the resulting filtrate evaporated to dryness using a rotatory evaporator at 40°C to give 5.74 g, the resultant concentrate was then reconstituted in distilled water to give the required doses used in the study.

2.2 Experimental Animals

A total of twenty healthy male rats (*Wistar strain*), 2.5 - 3 months old, weighing between 190 – 230 g were obtained from the animal house unit of the Department of Biochemistry, University of Portharcourt, Rivers State. The animals were kept in a clean cage and housed in a well ventilated room at temperature 28 - 30°C under natural light and dark cycle with free access to grower's mash and water.

2.3 Experimental Design

The twenty male rats were randomly divided into four groups (A - D), consisting of five rats each. Group A were orally administered once daily with 1ml of distilled water (vehicle), groups B, C, and D were orally administered with 50, 100 and 150 mg/kg body weight of the extract in 1ml of the vehicle for 42 days.

2.4 Method of Collection and Handling of Serum, Liver and Testes

At the end of the treatment period of 42 days, the animals were anaesthetized in a chloroform chamber and blood samples collected from the jugular vein into sample bottles, the blood samples were allowed to clot for 10 minutes at room temperature and subsequently centrifuged to obtain serum for biochemical analysis, the liver and testes were excised and kept in 10% formaldehyde.

2.5 Biochemical Assay

The following liver function tests were conducted to investigate derangement in the liver of the animals used for the study, aspartate aminotransferase (AST), alanine aminotransferase (ALT) were determined by the colorimetric method of Reitman and Frankel, 1957 using a commercial assay kit from Randox Laboratories Ltd, Co. Antrim, United Kingdom. Alkaline phosphatase (ALP) was estimated by the colorimetric method of REC, 1972 using assay kits from Randox Laboratories Ltd. Serum protein and serum albumin were estimated by Biuret method and Bromocresol Green (BCG) binding method respectively using a commercial assay kit from Randox Laboratories Ltd. Serum globulin level was calculated as the difference between total protein and albumin, albumin globulin (A/G) ratio was obtained from the division of the values of albumin and globulin. Total and conjugated bilirubin was determined using commercial kits from Randox Laboratories Ltd, using colorimetric method described by Jendrassik and Grof, 1938.

2.6 Histopathological Studies of the Liver and Testes

Histopathological examination of the liver and testes for inflammation, degeneration and dearrangement was done using the method described by Krause (2001).

2.7 Statistical Analysis

The results are expressed as the mean of five replicates \pm standard deviation (S.D), means were analysed using one way analysis of variance (ANOVA) followed by Posthoc (Turkey). $P < 0.05$ was regarded as significant. The Statistical Package for Social Sciences (SPSS) Computer software version 16 was used for data analysis.

3. Results

3.1 Effects of Diherbal Mixture of *Zanthoxylum leprieurii* and *Piper guineense* on Some Biochemical Parameters of Rats

All doses of the ethanol extracts of the diherbal mixture of *Zanthoxylum leprieurii* and *Piper guineense* had significant increase ($P < 0.05$) in a dose related manner on aspartate aminotransferase (AST), alanine aminotransferase (ALT) and alkaline phosphatase (ALP) activity except the 50mg/kg body weight of the extract on AST activity of the wistar rats when compared to the control (Table 1.0).

Table 2.0 shows the serum concentration of total protein, albumin, globulin, albumin/globulin ratio, total bilirubin and conjugated bilirubin. Total protein was not significantly ($P > 0.05$) influenced in any way, albumin and albumin globulin (A/G) were all significantly decreased ($P < 0.05$) when compared to the control. All doses

of the extract under study significantly increased ($P < 0.05$) the serum levels of globulin, total bilirubin and conjugated bilirubin except the 50mg/kg body weight effect on conjugated bilirubin. The effects of this extract on these biochemical parameters were dose dependent.

Table 1.0: Effects of Diherbal Mixture of *Zanthoxylum leprieurii* and *Piper guineense* on Enzyme Activity of Rats

EXPERIMENTAL GROUP	AST (U/L)	ALT (U/L)	ALP (U/L)
CONTROL 1 ml distilled H ₂ O	20.20 ± 1.92 ^a	21.00 ± 2.00 ^a	30.40 ± 2.70 ^a
A 50 mg/kg body weight	25.00 ± 2.55 ^a	26.80 ± 2.39 ^b	43.60 ± 3.05 ^b
B 100 mg/kg body weight	29.00 ± 2.74 ^b	30.00 ± 2.55 ^c	52.20 ± 2.86 ^c
C 150 mg/kg body weight	36.00 ± 2.24 ^c	35.60 ± 2.70 ^d	60.20 ± 3.49 ^d

Values are mean of five replicates ± standard deviation, values in the same column with different superscript letters are significantly different ($P < 0.05$), (One way ANOVA followed by Posthoc turkey). AST: Aspartate aminotransferase; ALT: Alanine aminotransferase; ALP: Alkaline phosphatase.

Table 2.0: Effects of Diherbal Mixture of *Zanthoxylum leprieurii* and *Piper guineense* on Serum Chemistry of Rats

EXPERIMENTAL GROUP	TP (g/dL)	ALB (g/dL)	GLO (g/dL)	A/G	TB (nmol/L)	CB (nmol/L)
CONTROL 1ml distilled H ₂ O	6.60 ± 0.23 ^a	4.12 ± 0.33 ^a	2.54 ± 0.43 ^a	1.69 ± 0.50 ^a	6.60 ± 1.14 ^a	1.10 ± 0.16 ^a
A 50mg/kg body weight	6.68 ± 0.16 ^a	3.26 ± 0.29 ^b	3.42 ± 0.43 ^b	0.98 ± 0.22 ^b	12.80 ± 1.30 ^b	1.32 ± 0.16 ^a
B 100mg/kg body weight	6.74 ± 0.11 ^a	3.00 ± 0.29 ^c	3.74 ± 0.23 ^c	0.81 ± 0.13 ^c	13.80 ± 1.30 ^c	1.70 ± 0.16 ^b
C 150mg/kg body weight	6.76 ± 0.21 ^a	2.50 ± 0.29 ^d	4.26 ± 0.30 ^d	0.59 ± 0.11 ^d	15.80 ± 1.79 ^d	2.06 ± 0.17 ^c

Values are mean of five replicates ± standard deviation, values in the same column with different superscript letters are significantly different ($P < 0.05$), (One way ANOVA followed by Posthoc turkey). TP: total protein; ALB: albumin; GLO: globulin; A/G: albumin globulin ratio; TB: total bilirubin; CB: conjugated bilirubin.

3.2 Effects of Diherbal Mixture of *Zanthoxylum leprieurii* and *Piper guineense* on Histopathology of Testes
 Histological examination of the testes of the control rats showed well layered seminiferous tubules containing orderly maturation of germ cells and indicated normal spermatogenesis (Figure 1A), however chronic administration of the extract caused dose dependent lesion on the testes. 50, 100 and 150 mg/kg body weight of the extract caused mild to severe distortion of seminiferous tubules with no proper coordination between boundaries and also showing delay in the maturation of germ cells (Figure 2A, 3A and 4A) respectively.

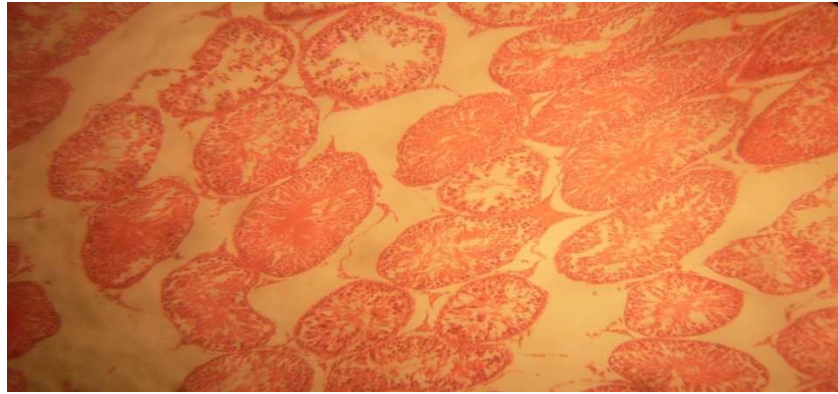


Figure 1A: Photomicrograph of testes administered with distilled water (control). (H & E \times 200). Testes with seminiferous tubules containing orderly maturation of germ cells (Normal spermatogenesis).

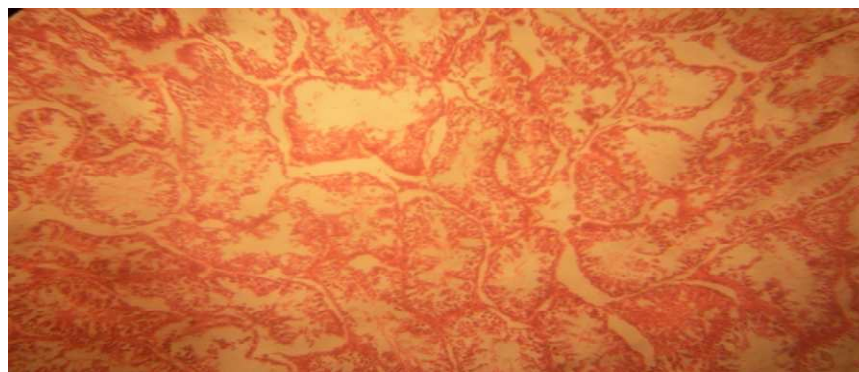


Figure 2A: Photomicrograph of testes administered with 50 mg/kg body weight of diherbal mixture of *Zanthoxylum leprieurii* and *Piper guineense* (H & E X 200). Testes showed mild distortion of seminiferous tubules

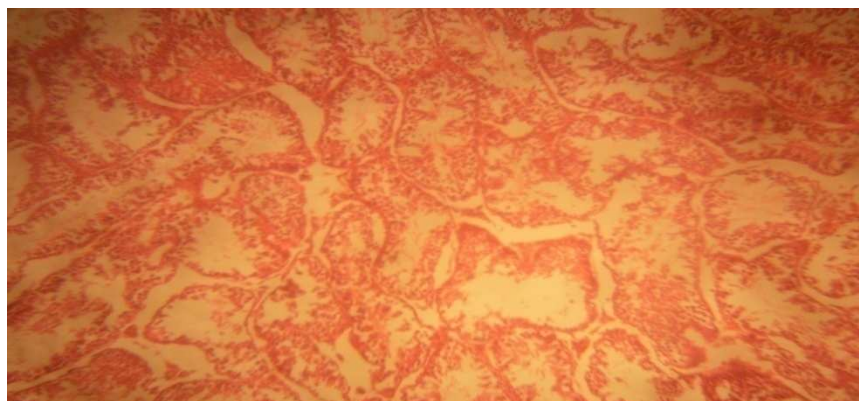

Figure. 3A: Photomicrograph of testes administered with 100 mg/kg body weight of diherbal mixture of *Zanthoxylum leprieurii* and *Piper guineense* (H & E X 200). Testes showed severe distortion of seminiferous tubules and delayed maturation of germ cells.

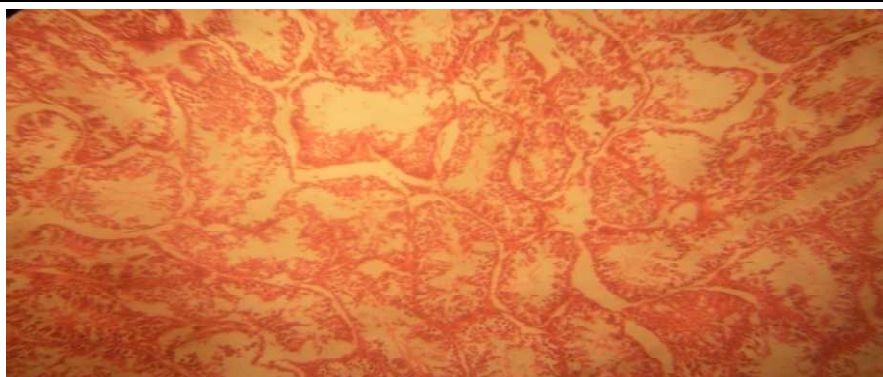

Figure. 4A: Photomicrograph of testes administered with 150 mg/kg body weight of diherbal mixture of *Zanthoxylum leprieurii* and *Piper guineense* (H & E X 200) Testes showed severe distortion of seminiferous tubules and delayed maturation of germ cells.

3.3 Effects of Diherbal Mixture of *Zanthoxylum leprieurii* and *Piper guineense* on Histopathology of Liver

Histological examination of the control liver shows normal liver with well preserved lobular architecture, normal hepatocytes, normal central vein and capsule with no indication of adhesion and inflammation. (Figure 1B), extract administration at 50, 100 and 150 mg/kg body weight caused to exhibit micro to macrovesicular steatosis (fatty change). (Figure 2B, 3B and 4B) respectively.

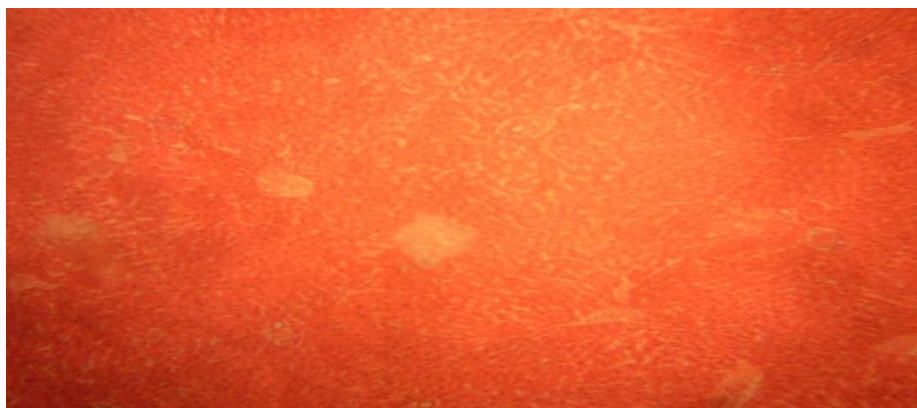


Figure 1B: Photomicrograph of liver administered with distilled water (control). (H & E X 200). Normal liver with well preserved lobular architecture, normal hepatocytes, normal central vein, capsules with no indication of adhesion or inflammation.

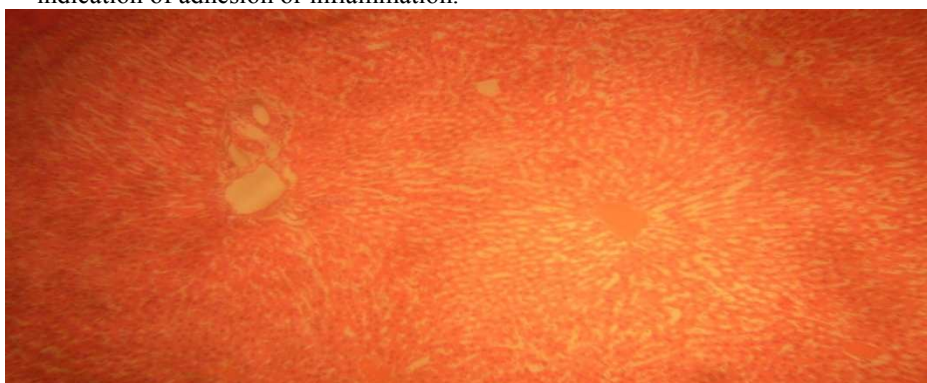


Figure 2B: Photomicrograph of liver administered with 50 mg/kg body weight of diherbal mixture of *Zanthoxylum leprieurii* and *Piper guineense* (H & E X 200). Liver showing microvesicular steatosis

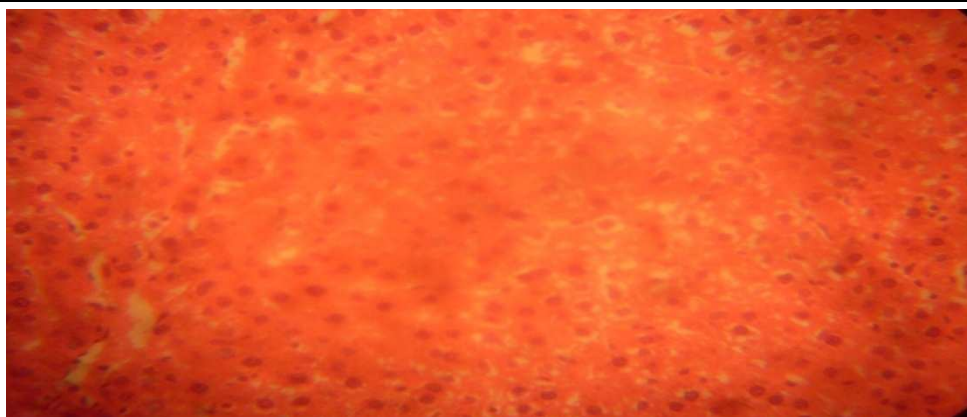

Figure 3B: Photomicrograph of liver administered with 100 mg/kg body weight of diherbal mixture of *Zanthoxylum leprieurii* and *Piper guineense* (H & E X 200). Liver showing macrovesicular steatosis (fatty change).

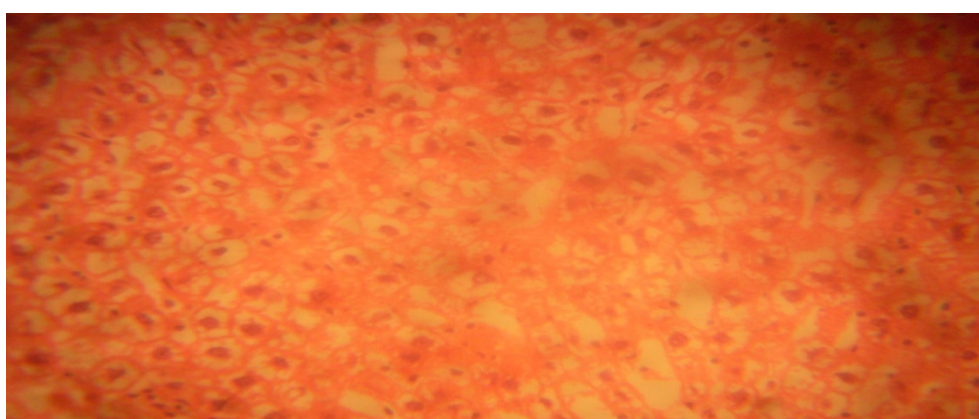


Figure 4B: Photomicrograph of liver administered with 150 mg/kg body weight of diherbal mixture of *Zanthoxylum leprieurii* and *Piper guineense* (H & E X 200). Liver showing macrovesicular steatosis (fatty change).

4. Discussion

The liver plays a key role in the metabolic process of itself as well as other tissues in maintaining the internal body environment (homeostasis). Hepatic injury due to some toxic phytochemicals found in medicinal plants and failure to eliminate these metabolic products by the liver often results in marked distortion of the normal function of the liver (Geidam *et al*, 2004). Aspartate aminotransferase (AST) and alanine aminotransferase (ALT) in the serum are often associated with hepatocellular damage (Lyoussi *et al*, 2004). Serum alkaline phosphatase (ALP) is a sensitive detector in biliary cirrhosis, hepatitis and in diseases characterized by inflammation, regeneration, intrahepatic and extrahepatic bile obstruction (Mayne, 1994; Panthong *et al*, 2003). After 42 days of treatment, all doses investigated of the extract had significant effect ($P < 0.05$) on AST, ALT and ALP levels and one can suggest that the extracts after 42 days had marked adverse effect on the liver of the treated rats.

Albumin plays an important physiological role by maintaining osmotic pressure, transport of both endogenous and exogenous substance and serving as protein reserves. (Saidu *et al*, 2007). The liver's ability to synthesize albumin and globulin is reduced if the synthetic function of the liver is tempered with (Whitby *et al*, 1989) and it is an indication of hepatitis and liver cirrhosis (liver damage). After 42 days of extracts dosing serum albumin, globulin and Albumin/globulin ratio were all significantly affected ($P < 0.05$), which is an indication of the liver's impairment to carry out its normal metabolic functions as a result of plant chemicals found in the herbal extract.

Bilirubin is formed by the breakdown of haemoglobin in the liver, spleen and bone marrow (Vasudevan and Sreckumari, 2005). An increase in tissue or serum bilirubin concentration results in jaundice and it occurs in toxic or infectious disease of the liver e.g. hepatitis or bile obstruction (Eden and Usuh, 2009). Bilirubin measurement is also a useful index of determining the excretory function of the liver and assessment of haemolytic anaemia. After the 42 days treatment, both total and conjugated bilirubin were significantly affected ($P < 0.05$) and it is an indication of adverse haemoglobin metabolism and liver function of the treated rats.

Histopathological examination of the testes of the controlled group showed cells with seminiferous tubules containing orderly maturation of germ cells and normal spermatogenesis, however the various doses (50, 100, and 150 mg/kg) after 42 days of treatment showed testes with mild distortion, slight delay in maturation of germ cells, to severe distortion and delay in maturation of germs cells and this may have a negative effect on gametogenesis. Histopathological examination of the liver of the controlled group showed well preserved lobular architecture, normal hepatocytes and capsules with no evidence of adhesion and inflammation. However, the 42 days treatment groups by the graded dose of the extracts showed slight, moderate to severe difference between the control and the extract challenged rats, the slides showed micro vesicular steatosis for the 50 mg/kg body weight of the diherbal mixture, while the 100 and 150 mg/kg body weight showed macro vesicular steatosis (fatty change) an indication that these extracts at 42 days are quite toxic and thus impaired the normal functioning of the liver.

5. Conclusion

Prolonged usage of this herbal extracts at the various dose studied can interfere with normal reproductive function of male rats and can also impair the metabolic function of the liver.

References

- Agbor, A.E. & Ngogany, Y.J. (2005). Toxicity of herbal preparations. *Cam. J. Ethnobot* **1**, 23-28
- Edem, D.O. & Usuh, I.F. (2009). Biochemical changes in Wistar Rats on oral doses of Mistletoe (*Loranthus micranthus*). *American Journal of Pharmacology and Toxicology* **4**(3), 94 – 97.
- Geidam, M. A., Pakiman, I. & Laminu, H. (2004). Effects of aqueous stem bark extract of *Mormordica balsamina* linn on serum electrolytes and some haematological parameters in normal and alcohol fed rats. *Pak. J. Biol. Sci* **7**,1430 – 1432
- Iwu, M. (1988). *Handbook of African Medicinal Plants*, CRC Press. Florida.
- Jendrassik, L., Grof, P. (1938). *Biochem. Z* **297**:81
- Krause, W.J. (2001). *The Art of Examining and Interpreting Histologic Preparations. A Student Handbook*. Partheton Publishing Group. United Kingdom Pp. 9 – 10.
- Lyoussi, B., Hilaly, J. E. & Israili, Z. H. (2004). Acute and chronic toxicological studies of *Ajuva iva* in experimental animals. *Journal of Ethnopharmacology* **91**, 43 – 50.
- Mayne, P.D. (1994). *Clinical Chemistry in diagnosis and treatment*. 6th edn. Hodder Arnold (International Students Edition). London Pp. 301-309.
- Ojinnaka, C.M (2011). In defence of traditional/herbal medicine. University of Portharcourt Valedictory Lecture series No. 3, University of Portharcourt Press.
- Panthong, A., Witthawaskul, P., Kanjanapothi, D., Taesothikul T. & Lertprasertsuke, N. (2003). Acute and sub – acute toxicities of the sapoin mixture isolated from *schefflera leucantha*. Viguier. *Journal of Ethnopharmacology* **89**, 115 -121.
- Rec. GSCC (DGKC) (1972). *J. Clin. Chem. Clin. Biochem.* **10**, 182.
- Saidu, Y., Bilbis, L.S., Lawal, M., Isezuo, S.A. Hassan, S.W. & Abbas, A.Y. (2007). Acute and sub-chronic toxicity studies of Crude aqueous extract of *Albizzia Chevalieri* Harms (Leguminosae). *ScienceAlert*. <http://scialert.net/fulltext/?doi=ajb.2007.224.236&org=10>.
- Tilburt, C.J., Kaptchuk, J.T. (2008). *Herbal Medicine Research and Global Health: an ethical analysis*. Bull. World Health Organization. **86**,594-599.
- Tillotson, A. (2001). *The One Earth Herbal Sourcebook*. New York Twin stream/Kensington.
- Todd, C. (2008). Prickly ash. <http://www.toddcaldecott.com/pricklyas.html>. November 6, 2009.
- Vasudevan, D.M. & Sreekumari (2005). *Textbook of Biochemistry (for Medical Students)*. 4th edn., Jaypee Brothers Medical Publishers (P) Ltd., New Delhi, Indian Pp 502-503.
- Whitby, L.G., Smith, A. F. & Becket, G.J. (1989). *Lecture Notes on Clinical Chemistry* 9th ed. Blackwell Scientific Publications, Oxford. London, Edinburgh, Boston, Melbourne.
- World Health Organization (WHO). (1996). WHO Guideline for the Assessments of herbal medicines. WHO Expert Committee on Specification for pharmacological preparations. Technical Report Series No. 863, Geneva.

This academic article was published by The International Institute for Science, Technology and Education (IISTE). The IISTE is a pioneer in the Open Access Publishing service based in the U.S. and Europe. The aim of the institute is Accelerating Global Knowledge Sharing.

More information about the publisher can be found in the IISTE's homepage:

<http://www.iiste.org>

The IISTE is currently hosting more than 30 peer-reviewed academic journals and collaborating with academic institutions around the world. **Prospective authors of IISTE journals can find the submission instruction on the following page:**

<http://www.iiste.org/Journals/>

The IISTE editorial team promises to review and publish all the qualified submissions in a fast manner. All the journals articles are available online to the readers all over the world without financial, legal, or technical barriers other than those inseparable from gaining access to the internet itself. Printed version of the journals is also available upon request of readers and authors.

IISTE Knowledge Sharing Partners

EBSCO, Index Copernicus, Ulrich's Periodicals Directory, JournalTOCS, PKP Open Archives Harvester, Bielefeld Academic Search Engine, Elektronische Zeitschriftenbibliothek EZB, Open J-Gate, OCLC WorldCat, Universe Digital Library, NewJour, Google Scholar

