

Todd's Syndrome: An Arabic Single Case of Prolonged Motor Impairment Presentation with Neuropsychological Tests Validation

Muwafak H. Al-Eithan*

Consultant Clinical Neuropsychologist, at Clinical Psychology, and at Rehabilitation Medicine, Prince Sultan Military Medical City, Riyadh, Saudi Arabia

Abstract: This paper presents a rare case of postictal hemiplegia for a prolonged period. The patient has no brain abnormality of vascular nature or any evidence of abnormality on MRI and EEG, but he had a single GTC seizure two months ago. This is the first Arabic case report of prolonged Todd's syndrome. The patient has no psychological problems either. We tested the hypothesis that there is no motivation factor in his presentation. The patient was totally normal on cognitive neuropsychological tests and on two Symptoms Validity Tests (SVT). This is also the first time SVTs are used with Todd's syndrome, as far as we are aware.

This rare case raises awareness and enhances our knowledge of clinical presentations, reducing the amount of diagnostic procedures and unnecessary therapies. It also helps clinicians to avoid 'psychologising' the clinical presentation as hysteria or psychogenic hemiplegia, in the absence of such evidence.

Keywords: Saudi Arabia, Todd's syndrome, Postictal hemiplegia, Symptom validity tests, Neuropsychology, Epilepsy, Malingering, Psychogenic.

INTRODUCTION

Neurological disorders may present a wide range of clinical abnormalities, some are very common, while others are rare. Seizure disorders or epilepsy is one such common neurological disease and clinically, has significant variations. After major seizures, patients present with physical (motor and sensory) and psychological (mood and behavioural) as well as cognitive (language, memory, consciousness) abnormalities [1]. Often some of these postictal abnormalities disappear soon after while others remain for some time. Some patients can show such abnormalities following a single seizure or after several seizures over the years [2]. All of these postictal conditions need clinical management and understanding [3]. Depending on localisation and intensity, motor abnormality is common postictally. This could be in the form of partial weakness of upper or lower limbs, or hemiplegia and paralysis. Certainly, it can be seen in clinics and rehab units that many symptoms disappear after a while and some may remain as residual, either postsingle seizure, or post many heavy consecutive fits. Postictal motor abnormality is common. Although there are many psychological presentations, all have a direct relation to seizures. This is not at all related to hysterical psychological problems that may cause motor problems with no physical reasons.

Occasionally, some patients show hemiplegia following one or more seizures but they disappear after a few hours. This has also been the attention of few clinicians in the 19th century. R. Todd reported postictal hemiplegia that lasts between few hours to a day or two. It was initially named as (hemiplegia epileptique), but later came to be known as Todd's syndrome, or Todd's hemiplegia, Todd's paralysis [4], we will use the term Todd's Syndrome here (TS)^a. The major feature of this rare clinical presentation is that patients show hemiplegia for a few hours or less postictally. Most of old and recent few reports suggest that patients show short-lived motor abnormality postictal [4]. There is very rare information about the long-term effect of postictal hemiplegia. We have also to consider that the TS can affect cognitive as well as motor domains. But it is important that there is agreement among clinicians that TS is a clinical entity of transient postictal impairment.

R. Todd himself talked about exhaustion as a cause of the syndrome, but it is still not known. There is a notion of a neuronal problem (e.g. energy and anoxia) that causes such abnormality. We are not addressing the evidences for pathological explanations here, as the aetiology is not clear yet (see good review, [4]).

^a Please note that this is not what some have talked about by mistake as (Alice in Wonderland syndrome). The latter is related to body size perception only by patients themselves. Todd's syndrome is related to motor impairment (or cognitive) after seizures with no physical abnormality evident. In writing or clinical discussion some physicians mistakenly make no distinction.

*Address correspondence to this author Dr M Al-Eithan PhD Consultant Clinical Neuropsychologist, at Clinical Psychology, and at Rehabilitation Medicine, Prince Sultan Military Medical City, Riyadh, Saudi Arabia; E-mail: al_eithan@yahoo.com

Most cases in the literature presented adult patients, but there are some child clinical cases too [5].

Case Study (HS)

A case of a prolonged Todd's syndrome, is presented here from an Arabic population.

The patient (HS) is a right-handed, 41 year old married military man with 8 children. He was presented to the rehab department for evaluation and treatment after admission to hospital in Riyadh. He was initially seen in the ER after a major single GTC seizure 2 months ago, in which he suffered many physical complications and loss of consciousness, while he was at home off duty.

He presented good recovery soon after fit, GCS was 15/15, but showed right sided weakness only. Patient was intact in everything else, physically and psychologically. Language, memory was also intact on assessment. His mood was normal and he showed good motivation.

The patient had left sided weakness, both lower and upper limbs were weak, and his motor ability was intact on the right side.

The patient was seen and evaluated in many departments at the hospital, including neurology and rehab medicine. All neuroimaging was negative. He had normal MRI and CT scan. There was also normal EEG, and normal CSF. There was no evidence of any vascular abnormality (ischemic or haemorrhagic). Medical evaluation showed no physical abnormalities, but persistent left sided weakness. One physician reported "no organic cause of his symptoms". He was then diagnosed with a number of possible reasons for his motor abnormalities by many physicians, including: "conversion syndrome", "adjustment disorders", "malingering" and was referred to the clinical psychology and mental health team. He was also started on antidepressant.

Initially he received rehab intervention but showed little progress. He was in the absence of positive MRI and other imaging and lab work, he was again diagnosed initially as a (conversion) hysteria. Then this was proved to be not valid, because he was very motivated for rehab and insightful. He was later diagnosed with (malingering) disorder. He was referred for neuropsychological evaluation and management for his "psychological" condition.

The patient was referred for clinical neuropsychology evaluation and neuropsychological assessment. He was seen on a number of sessions, as well as his family members for information, history and comments. Medical history was indicative of TB 20 years ago, and treated brucellosis. There was negative history of mental health problems, psychological or substance abuse. The patient enjoyed a very healthy active life style and was practicing sport as well.

Psychological Evaluation

The patient showed full cooperation and motivation with psychological and neuropsychological assessments procedures. He also showed normal mood and there was no abnormality on Hospital Anxiety Depression Scale-Arabic (HADS).

The patient showed normal level of cognitive skills on Wechsler Adult Intelligence Scale (WAIS-Arabic) verbal subtest (all within average range). He was also normal on the Memory Story Recall, from Wechsler Memory Scale WMS (Arabic). All his language tasks performances, including verbal fluency task, were within the normal level for his age and education. He has normal visual and spatial skills. He showed no executive dysfunctioning on testing either.

When the patient was assessed on his insight and needs, he showed healthy insight and that he wants to be better to go back to work. He was not happy with the possibility of loss of employment (retirement due to ill health), because that would reduce his income while he stated clearly he needs his current income. His brother also confirmed that. In fact, his brother stated that the patient has currently normal mood, though patient is frustrated with his condition and lack of physical progress while doing his best in rehab. He also reported that the patient had normal history of psychological well-being pre morbidly. There was no evidence of abnormal motivation or impaired insight.

We tested the hypothesis that HS has no motivational factor(s) in his clinical presentation, with or without awareness. We assumed that if the patient has motivational factor, he will do badly on Symptoms Validity Tests. There is good scientific and clinical rational for such examination (see [6]).

Symptoms Validity Tests

Further, in order to experimentally rule out any psychological needs and motivations that may have contributed to development or maintenance of the

hemiplegia, the patient, with his consent, underwent a couple of symptom validity tests. This was done in one session as a small experiment. SVTs measure and assess the extent to which an individual is providing valid responses during cognitive or neuropsychological testing. It illustrates the level of the patient's efforts. Performance below established cut-off scores on one or more SVTs designed to measure exaggeration or fabrication of cognitive or physical deficits suggests insufficient effort to do well (see for a review, [6, 7]).

Use of SVTs is generally recommended in evaluations of individuals with medically unexplained symptoms that include cognitive impairment (e.g. cognitive symptoms related to concentration, memory, or slowed thinking in patients with fibromyalgia or other medically unexplained pain syndromes) [8, 9]. This can equally apply to motor impairment with no physical abnormality evident.

Further discussion of the following tests can be found in a number of text books, (e.g. [6]). These tests can be used with patients suspected of functional disorders (vs. organic) complaining of psychological, cognitive or physical abnormalities. These tests are also chosen for easy access and administration, and do not burden the patient on testing, with good validity and reliability (see: [6]).

The Rey 15-Item Memory Test

This is a simple visual task, in which the patient is presented with five rows, each has three figures, numbers or letters in order to recall. Usually, even children can recall it. Literature showed that those with psychological motivation may exaggerate their

responses and show poor performance on this very simple task [6].

HS has showed intact performance on the Rey 15-Item-memory task, scoring 12/15, close to matched normal control subjects' performance ($p=0.277$). This suggests that there is no evidence of exaggerating or motivation to present an invalid clinical picture. This is compared to the matched six normal controls' performance Figure 1.

2 Forced-Choice Task (Red and Green Pencil Experiment) (50 % chance level):

In this small task, a subject is presented with 100 trial of repeated forced-choices performance. The subject is to guess the colour of the next pencil to be presented randomly. The patient is aware that there are only 2 colours (red and green pencils). Usually, normal subjects will be performing within or close to 50% statistical chance level. However, there is evidence that other subjects with possible malingering or other psychological needs, may show deliberate deviation from chance level. So they score within very low range, much less than statistical chance level (e.g. 25%, or 30 % level or less), by consciously answering against the expected next possible colour (see [6]).

This small 2-forced-choice SVT task compared HS's performance to the normal controls (6 matched people, and data from a recent malingering case on the same task, with reasonable matched background between all groups).

Again, the patient (HS) here has performed within the 46 % level on the task (in the figure referred to as

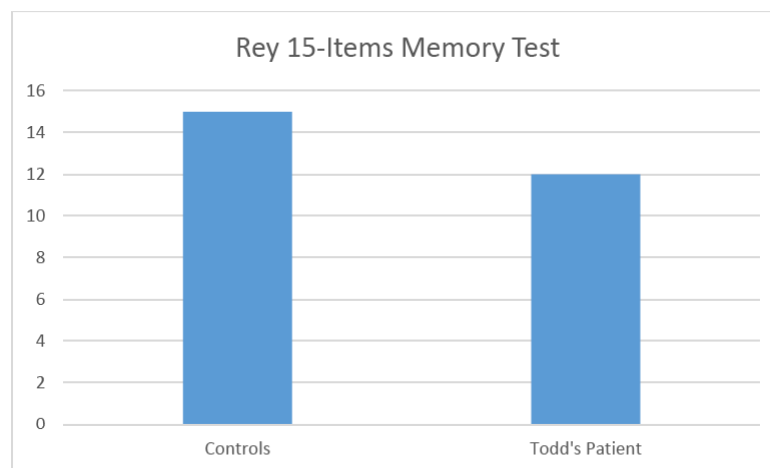


Figure 1: Patient performance on the Rey 15-Item Memory Test compared to normal controls. * $p = .277$.

Todd's). This also supported the notion that he has no motivation to mangle or exaggerate his symptoms. His performance is relatively close to normal controls' but much better than that of the malingering Case ($p=0.011$) Figure 2.

On a number of clinical sessions, and discussions with other therapists in the rehab setting, they all also stated that there is no evidence of exaggerating but he has "odd clinical presentation" related to absent lab evidence of physical abnormality. We can totally agree with their observation. He has a rare neurological, not psychological phenomena. In which he has a persistent- long term- effect of hemiplegia after a single major GTC seizure. This is in fact, we argue, a rare prolonged motor Todd's Syndrome.

DISCUSSION

We presented here a case of prolonged Todd's syndrome TS in a patient who suffered a GTC seizure 2 months ago, in the absence of any brain abnormality on imaging. Further, the patient has no psychological, cognitive or motivational abnormalities evident on testing. Though most of few cases from the inception of the TS [4] and the notion that patient can develop postictally motor impairment for short hours or days, here we see a prolonged presentation.

As recently reported in another case [10], the fact that the prolonged presentation is rarer, does not invalidate the condition at all. It shows more clinical presentation of a rare postictal motor abnormality. Here we also share this rare prolonged case of TS, in an Arabic patient.

Our hypothesis that there is no motivational (psychological) factor in HS's clinical presentation has been validated on testing. Here we also show clinical validation based on a simple neuropsychological assessment (SVT) that assesses motivation of the patient. This is a new presentation as far as we aware in the literature of Todd's syndrome. Perhaps more assessments are needed to validate the clinical presentations of such patients in the future.

Such awareness will save the patient much unwelcoming and annoying statements such as, "You can walk, and so do it..." etc. Furthermore, it will reduce the chance of wrong diagnoses and labelling, such as hysteria and malingering. Such misdiagnoses will expose the patient (and families) to much unneeded embarrassment and confusion. In addition, understanding such abnormality will reduce unnecessary lab work and imaging.

Better diagnosis helps patients and clinicians to develop perhaps more specific rehabilitation training and reduce the burden of disability on the patient. We need more studies in rehab though there is some recent progress [11].

CONCLUSIONS

This case study (HS) presents a first time Arabic patient with Todd's Syndrome. The case of a patient who suffered left hemiplegia following single seizure. The hemiplegia is both prolonged and comes in the total absence of imaging evidence of brain abnormality. HS also showed no psychological, cognitive or behavioural abnormalities.

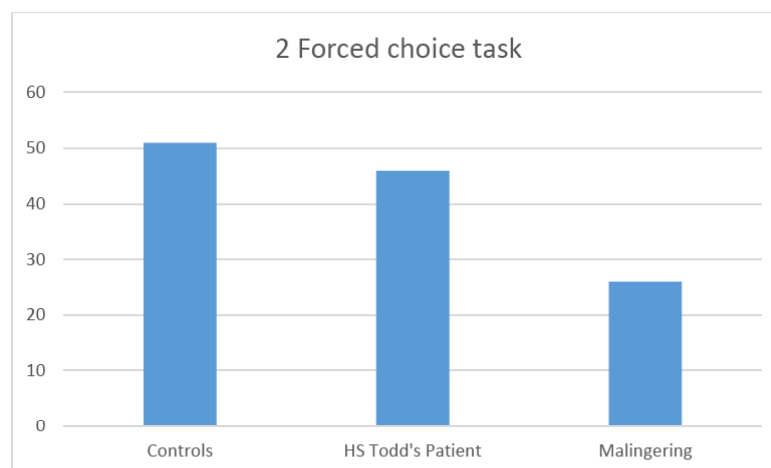


Figure 2: HS performance on the 2 forced-choice task compared to 3 matched control subjects and a single malingering case.

** $p=0.011$

*The malingering case above is for a recent clinical case, outside the context of this paper. But results clearly show low performance on the test by the malingering case.

This paper also is the first to use the Symptom Validity Tests to examine the psychological aspects of such (single) patient. The SVT proved that there is no motivational factor in the presentation. This paper invites future research to utilize such experimental approach to validate the absence of psychological factors in organically unexplained symptoms.

This single case study paper by the nature of the disorder is retrospective and nothing further can be done. The fact that it is a single case may limit both our understanding of the core issues of the disorder and the conclusions we may make. In addition there are more tests that can be done to use neuropsychological tools for group work in the future. It is hoped that this case adds more information to this small area of seemingly rare cases, but perhaps will show growing research. May be we will discover that there are more TS cases that will render further studying to understand such a fascinating phenomena. We also still need more work on understanding the medically (organically) unexplained symptoms.

ACKNOWLEDGMENT

I would like to thank A Khan for editorial help my thanks also to the two referees.

REFERENCES

- [1] Werhahn KJ. Weakness and focal sensory deficits in the postictal state. *Epilepsy and Behaviour* 2010; 19: 138-139. <https://doi.org/10.1016/j.yebeh.2010.06.029>

- [2] Rolak LR, Rutecki P, Ashizawa T, Harati Y. Clinical features of Todd's post-epileptic paralysis. *Journal of Neurology, Neurosurgery, and Psychiatry* 1992; 55: 63-64. <https://doi.org/10.1136/jnnp.55.1.63>
- [3] Fisher RS, Schachter SC. The postictal state: a neglected entity in the management of epilepsy. *Epilepsy Behav* 2000; 1(1): 52-9. <https://doi.org/10.1006/ebep.2000.0023>
- [4] Binder D. A History of Todd and His Paralysis. *Neurosurgery* 2004; (2)54: 480-487. <https://doi.org/10.1227/01.NEU.0000103490.49537.37>
- [5] Zamora CA and Kontzialis M. Susceptibility-weighted imaging in Todd paralysis. *Neurology* 2015; 21(85): 3-297. <https://doi.org/10.1212/wnl.0000000000001770>
- [6] Lezak MD, Howieson DB, Bigler ED and Tranel D. *Neuropsychological assessment* (5th ed.). New York: Oxford University Press 2012.
- [7] Bush SS, Ruff RM, Troster AI *et al.* Symptom validity assessment: Practice issues and medical necessity. *Archives of Clinical Neuropsychology* 2005; 20: 419-426. <https://doi.org/10.1016/j.acn.2005.02.002>
- [8] Greiffenstein M, Gervais R, Baker J, Artiola L, and Smith H. Symptom Validity Testing in Medically Unexplained Pain: A Chronic Regional Pain Syndrome Type 1 Case Series. *The Clinical Neuropsychologist* 2013; 27(ISS. 1): 138-147. <https://doi.org/10.1080/13854046.2012.722686>
- [9] Johnson-Greene D, Brooks L, Ference T. Relationship between performance validity testing, disability status, and somatic complaints in patients with fibromyalgia. *Clin Neuropsychol* 2013; 27(1): 148-58. <https://doi.org/10.1080/13854046.2012.733732>
- [10] Degirmenci Y and Kececi H. Prolonged Todd Paralysis: A Rare Case of Postictal Motor Phenomenon. *J of Neurology And Neuroscience* 2016; 7(3): 103 <https://doi.org/10.21767/2171-6625.1000103>
- [11] Kumar S and Lama TN. Targeted exercises in Todd's Palsy. *International Journal of Therapies and Rehabilitation Research* 2014; 3(4): 1-3. <https://doi.org/10.5455/ijtr.00000036>

Received on 29-03-2017

Accepted on 18-04-2017

Published on 28-04-2017

<http://dx.doi.org/10.15379/2409-3564.2017.04.01.02>

© 2017 Muwafak H. Al-Eithan; Licensee Cosmos Scholars Publishing House.

This is an open access article licensed under the terms of the Creative Commons Attribution Non-Commercial License

(<http://creativecommons.org/licenses/by-nc/3.0/>), which permits unrestricted, non-commercial use, distribution and reproduction in any medium, provided the work is properly cited.