

# The Therapeutic Approach of the May-Thurner Syndrome without Deep Venous Thrombosis: a Systematic Review

REVIEW

Thaís Abreu Luedy<sup>1</sup>,  
Isadora Rodrigues da Costa<sup>2</sup>,  
João Vitor Pimentel<sup>1</sup>,  
Francisco Henrique  
Peixoto da Silva<sup>1</sup>

1 Faculdade de Medicina. Universidade Federal do Cariri, UFCA, Barbalha, Ceará, Brazil.

2 Faculdade de Medicina. Universidade Federal do Ceará, UFC, Fortaleza, Ceará, Brazil.

## Abstract

May-Thurner Syndrome is a clinical condition which causes a variety of vascular symptoms, resulting from pelvic and lower extremity venous flow obstruction caused by the compression of the iliac vein by overlying iliac artery. Treatment paradigms have changed as experience with endovascular modalities has evolved, making traditional surgical treatment strategies essentially obsolete and a endovascular treatment with angioplasty and stenting along selective thrombolysis has become the standard for symptomatic the syndrome. The objective of this present study is to show the therapeutic approach in treatment when there's no presence of Deep Venous Thrombosis (DVT) symptoms. To accomplish this purpose, a systematic review of articles about May-Thurner Syndrome and its management therapies, published from January 1, 2005 to September 20, 2015, on PubMed and SCOPUS databases, was carried out. Search terms were "may-thurner syndrome" (medical subject headings [MeSH term]), "ilio-caval compression syndrome" (MeSH), "cockett syndrome" (MeSH), "peripheral vascular diseases" (MeSH), and "treatment" (keyword). Of the 89 retrieved studies, 14 met the eligibility criteria. Retrieved studies covered that without correction of this syndrome, patients are at continued risk for recurrent deep vein thrombosis and post-thrombotic syndrome. Considering the therapy, systemic anticoagulation is the first component, and endovascular treatment appears to be superior to conventional surgical treatment. It should be the first line of therapy. Furthermore, there has been multiple advances in the recent years for chronic arterial occlusions using techniques such as blunt micro dissection, radiofrequency energy and laser. In the absence of deep venous thrombosis, conservative treatments are

## Contact information:

Thaís Abreu Luedy.

**Address:** Universidade Federal do Cariri, UFCA/Faculdade de Medicina.

 [thaisluedy@gmail.com](mailto:thaisluedy@gmail.com)

preferred. To conclude, based on the review of the literature, a combination of conservative and endovascular therapy usually provides the best treatment in most cases. Thus, further researches must be done to advance in the matter of therapeutic of the non-DVT form of May-Thurner Syndrome.

#### Keywords

May-Thurner Syndrome;  
Iliocaval Compression  
Syndrome; Cockett Syndrome;  
Peripheral Vascular Disease;  
Treatment.

## Introduction

Iliac vein compression syndrome (IVCS), also known as May-Thurner or Cockett syndrome, is a clinical condition which causes lower extremity swelling, pain, varicosities and other symptoms, resulting from pelvic and lower extremity venous flow obstruction caused by the compression of the iliac vein by overlying iliac artery. [1] This compression may present symptomatically or be an incidental finding. [2]

The incidence of IVCS is extremely difficult to accurately estimate due to the high percentage of patients who are asymptomatic, and thus the denominator is unknown. [3] While the estimated incidence of this underlying anatomic variant is approximately 22-24%, the actual risk of progression to thrombosis is believed to be influenced by other factors affecting a patient's coagulation profile. [4]

In the past, open vascular surgery was necessary and included vein-patch angioplasty with excision of intraluminal bands, division of the right common iliac artery and relocation behind the left common iliac vein or inferior vena cava, and contralateral saphenous vein graft bypass to the ipsilateral common femoral vein with creation of a temporary arteriovenous fistula (Palma crossover). [5] Treatment paradigms have changed as experience with endovascular modalities has evolved, making traditional surgical treatment strategies for IVCS essentially obsolete. Meanwhile, endovascular treatment with angioplasty and stenting along selective thrombolysis has become the standard for symptomatic IVCS. [3]

Therefore, this review intends to analyze the approach of the current literature about the therapeutic management of IVCS treatments when there's no presence of Deep Venous Thrombosis (DVT) symptoms.

## Methods

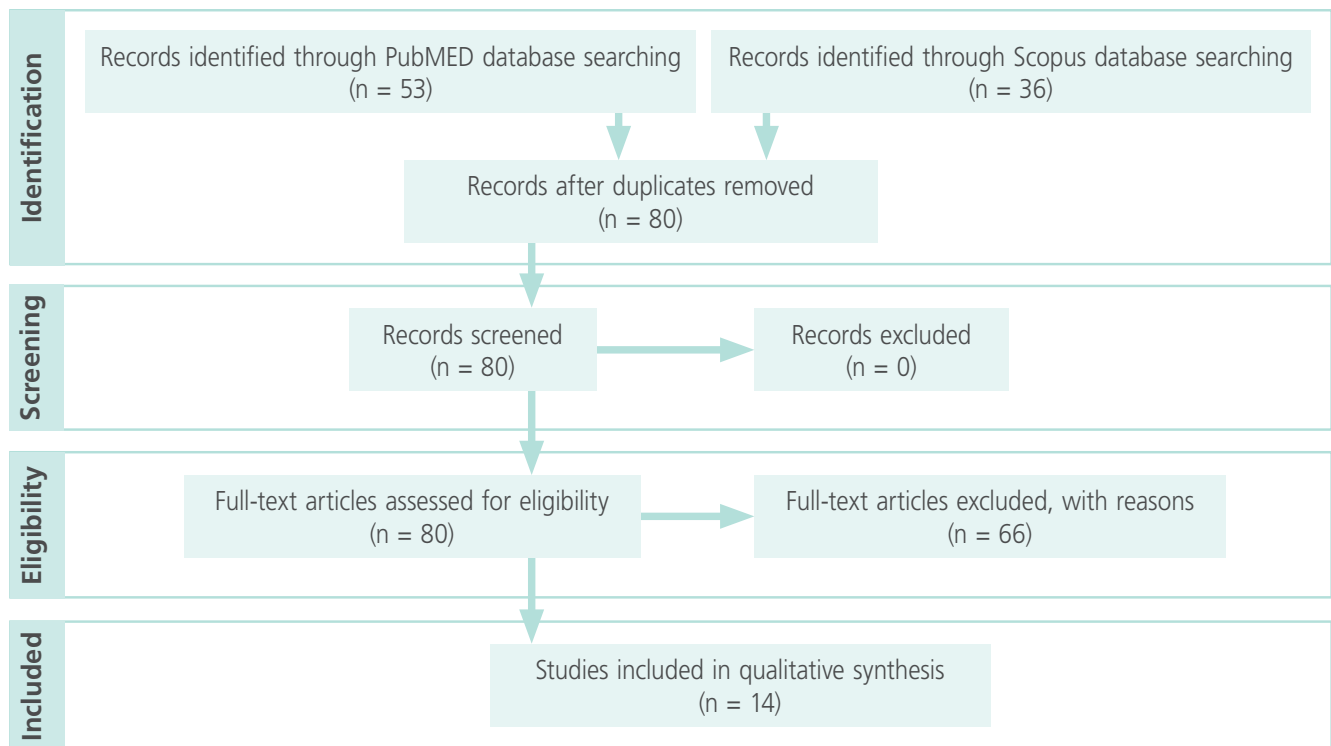
It was performed a qualitative review of the articles about May-Thurner Syndrome and its management therapies, especially those focusing this syndrome without Deep Venous Thrombosis (DVT), published in electronic databases previously selected. We have also included the articles that aimed to discuss the syndrome after DVT due to the little quantity of available articles in the databases.

It was conducted a search in the literature through the online electronic PubMed and Scopus databases, limiting it to published articles from January 1 of 2005 to September 20 of 2015. The reason to delimitate this research time is that there is little approach in literature about this theme, which means it is important to demonstrate that the current literature has few productions about patients with May-Thurner Syndrome that did not presented Deep Venous Thrombosis (DVT), and how they were managed to achieve a great therapy. Thus, it was aimed to perform a brief but sufficient analysis of the articles published.

Initially, the following descriptors were used:

1. "May-Thurner Syndrome" (Medical Subject Headings [MeSH] descriptor);
2. "Iliocaval Compression Syndrome" (Medical Subject Headings [MeSH] descriptor);

**Figure 1:** PRISMA Flow diagram summarizing the selection process of studies for review.



3. "Cockett Syndrome" (Medical Subject Headings [MeSH] descriptor)
4. "Peripheral Vascular Disease" (Medical Subject Headings [MeSH] descriptor)
5. "Treatment" (Keyword)

The research was performed using all these descriptors together, following the order: 1 AND 2 AND 3 AND 4 AND 5. The keyword "Treatment" was used focusing the gathering of the maximum number of publications related to the therapeutic management of the patients with this syndrome. All articles wrote in English were collected.

The results analysis was followed by the application of the inclusion criteria, which were:

- articles that had in title or in abstract at least one combination of the described terms in the search strategy;
- publications wrote in English language;
- studies that discussed the focus theme;
- observational prospective and retrospective studies (analytical or descriptive), clinic essay and case reports.

The exclusion criteria were:

- other study designs, such as reviews and book chapters;
- non-original studies including editorials, preface, brief communication and letter to editor;
- studies that did not focus the May-Thurner Syndrome and its treatment;
- unavailable study abstract or full text.

Each article of the sample was read, filtered and, accordingly, included in this review's sample.

## Results

The implementation of the previously described search strategy resulted in 89 articles, from which 53 were from PubMed and 36 were from Scopus. 9 of these studies were presented in both Scopus and PubMed databases, so these duplicated ones were excluded. After an insightful analysis of the found studies, 66 were excluded because they matched one of the previous cited exclusion criteria. 14 were included in the final sample. A better summary of the found articles is shown in **Figure 1**. In addi-

**Table 1.** Overview of selected articles.

Authors	Year	Journal	Sample	Main findings
Mahnken, A.H.	2014	CardioVascular and Interventional Radiology	The current evidence on ilio caval vein recanalization and provides standards of practice for ilio caval stenting in primary and secondary causes of chronic venous disease	While compression therapy is the basis of therapy in CVI, in many cases, venous recanalization or correction of obstructive iliac vein lesions may result in resolution of symptoms
Liu Z	2014	Annals of Vascular Surgery	48 consecutive patients diagnosed with	Identify the benefits of music in the approach of patients with Alzheimer's disease and describe the improvements
Pandit, A.S.	2014	Annals of Vascular Surgery	A case of MTS resulting from placement of an aortic stent graft for aneurysm repair	A higher index of suspicion and a more comprehensive initial venous duplex investigation, which should include the suprainguinal veins, should be considered in those patients with new onset of unilateral limb swelling after endovascular aneurysm repair (EVAR)
Budnur SC.	2013	Cardiovasc Interv Ther	We present a case of 24-years old female with left lower limb deep venous thrombosis (DVT)	Pharmaco-mechanical catheter directed thrombolysis-thrombectomy followed by left iliac vein stent placement restored patency to the venous system, with resolution of symptoms
Hager, E.S.	2013	Journal of Vascular Surgery, Venous and Lymphatic disorders	A retrospective review of MTS patients treated between 2006 and 2010 was conducted at two institutions	Stenting of MTS has proven to be safe, efficacious, and durable for up to 36 months and both the postthrombotic patient as well as those treated for edema alone
Smeds MR.	2011	Vasc Endovascular Surg.	A 47-year-old female with an occluded iliac vein stent originally placed for deep venous thrombosis and May-Thurner syndrome presented to our clinic with complaints of left lower extremity pain and swelling	We were able to cross the lesion with the Wildcat catheter. Subsequent directional laser atherectomy and balloon angioplasty followed by stent placement resulted in a patent stent and resolution of her symptoms
Abboud G.	2010	Cardiovasc Intervent Radiol	A 26-year-old woman was admitted to our institution with acute edema of the right lower limb	The diagnosis of May-Thurner syndrome was done by CT scan and confirmed by phlebography. An endovascular treatment with stenting was carried out, with good patency and clinical result at 12-month follow-up
Suwanabol PA.	2010	Perspect Vasc Surg Endovasc Ther	This study presents current management of these disorders, including diagnostic and interventional strategies	Endovascular techniques have evolved and now play a significant role in the treatment of both phlegmasia cerulea dolens and May-Thurner syndrome. However, endovascular therapy for nutcracker syndrome remains untested.
Lou, W.S.	2009	Korean Journal of Radiology	Three groups of patients, IVCS without DVT (group 1, n = 39), IVCS with fresh thrombosis (group 2, n = 52) and IVCS with non fresh thrombosis (group 3, n = 34) were detected by Doppler ultrasonography, magnetic resonance venography, TC or venography	This study suggests that endovascular treatment of IVCS, with or without thrombosis, is effective

Authors	Year	Journal	Sample	Main findings
Murphy, E.H.	2009	Journal of Vascular Surgery	The occurrence of 7 adolescent patients with previously undiagnosed May-Thurner syndrome who presented with DVT after the initiation of oral contraceptive steroids (OCP) use	There have been no long-term complications related to surgical treatment or anticoagulation. All 7 patients have experienced resolution of left leg swelling and pain and have no evidence of post-thrombotic syndrome or DVT recurrence to date
Loukas, M.	2008	Folia Morphologica	Describe a very rare case in which a previously asymptomatic patient presented with May-Thurner syndrome	Anticoagulation therapy in symptomatic patients as a sole treatment has not been very effective. It has prevented migration of the thrombi, although without managing or reducing the mechanical obstruction caused by the intimal hyperplasia. Recent treatment utilizing intraluminal venous stents has been associated with greater success, as it deals with thrombus formation and the mechanical obstruction
Knipp, B.S.	2007	Journal of Vascular Surgery	There were 50 women and 8 men, with a mean age of 42 years (median, 39 years; range, 17-71 years). Primary, assisted primary, and secondary patency rates were determined. Patient characteristics and clinical variables were evaluated by univariate and multivariate analysis to determine association with vein patency	Iliac vein obstruction was treated with pharmacologic thrombolysis (31% of patients) and mechanical thrombus fragmentation (17% of patients). The primary, assisted primary, and secondary patency rates of angioplasty/stenting were 74.1%, 79.7%, and 85.8% at 1 year and 38.1%, 62.8%, and 73.8% at 5 years, respectively
Ludwig B.	2006	Chest	We describe a case of May-Thurner syndrome that involved a complicated treatment course (...)	(...) and a review of current options for diagnosis and therapy
Oguzkurt L.	2006	Cardiovasc Intervent Radiol	A 10-year-old boy presented to our clinic with left lower extremity swelling present for 1 year with deterioration of symptoms during the prior month. Laboratory investigation for deep vein thrombosis was negative	After venography, endovascular treatment was planned. The stenosis did not respond to balloon dilatation and a 12 mm Wallstent was placed with successful outcome. The patient's symptoms improved but did not resolve completely, probably due to a chronically occluded left superficial femoral vein that did not respond to endovascular recanalization. To the best of our knowledge, this is the first case of successful endovascular treatment of iliac vein compression syndrome with stent placement in a pediatric patient

tion, the collected data were addressed in a table showing each study authors, publication year, sample description and main findings (**Table 1**).

## Discussion

IVCS is an independent etiologic factor affecting the pathogenesis of iliac venous outflow obstruction and appears to play an important role in the clinical expression of chronic venous insufficiency, particu-

larly by producing pain. [6] Symptomatic IVCS occurs predominantly in young to middle-aged women (20-40 years). Patients present with either sudden onset of symptoms or with a long-standing history of venous congestion with or without deep venous thrombosis (DVT). [7] Therapy for May-Thurner syndrome has evolved over the years. Conservative therapy with compressive stockings has been largely unsuccessful, likely due to the proximal mechanical nature of the obstruction. Many surgical procedures

for the relief of obstruction have been described. [8] Recent imaging data indicate that compression of the LCIV (Left Common Iliac Vein) at the arterial crossover point may be present in 66% of the general population without any venous symptoms [9] and without correction of this compression, patients are at high risk to develop a recurrent deep vein thrombosis and post-thrombotic syndrome.

The goal of treating May-Thurner in the setting of iliofemoral DVT is to prevent or attenuate symptoms of post-thrombotic syndrome, including chronic leg swelling, venous claudication, stasis dermatitis, and ulcers, as well as varicosities associated with valve damage and iliac venous outflow obstruction. Considering the therapy, systemic anticoagulation is the first component. However, that alone is not adequate for the treatment of DVT with May-Thurner, as it fails to address any of the long-term sequelae in this group of patients. [10] May-Thurner syndrome, in which the overriding right iliac artery compresses the left iliac vein, will rarely respond to conservative treatments, [11] including anticoagulation and fibrinolysis [12], given the physical etiology of the disease. [11] Patients with iliofemoral thrombosis and May-Thurner should be treated aggressively with catheter directed thrombolysis, percutaneous mechanical thrombectomy and angioplasty and stent placement across the common iliac stenosis. It should be stressed that stent placement is an essential component to therapy as May-Thurner is an acquired disorder from mechanical obstruction. [10] The treatment of May-Thurner syndrome has also leaned toward endovascular therapy involving thrombolysis followed by balloon angioplasty and stenting. [11]

Authors of other studies have reported successful endovascular treatment of common iliac vein compression by stent placement. [7] This type of therapy is a minimally invasive approach to treating venous lesions and is feasible and effective for treating left-sided IVCS with a high technical success rate and an acceptable complication pro-

file. Therefore, endovascular treatment appears to be superior to conventional surgical treatment and should be the first line of therapy for many patients suffering from IVCS. [8] An endovascular mechanical thrombectomy, combined with guiding catheter suction, can substitute most of the surgical embolectomy. [1] In addition, it appears that balloon venoplasty and stenting of the iliac vein in chronically obstructed limbs is a safe, minimally invasive method with a minimal complication rate, no mortality, and an acceptable 1-year patency rate. [8] Overall, balloon angioplasty and stenting is safe and effective, and the complication rate is likely to decrease as technology evolves and experience increases. [8] Multiple advanced endovascular have been developed in recent years for chronic arterial occlusions using techniques such as blunt micro dissection, radiofrequency energy and laser. [11] In this context, is important to mention that there are only few absolute contraindications for ilio caval stenting including uncorrectable coagulopathy and local or systemic infection. [13]

Operative intervention for May-Thurner with acute thrombosis includes thrombectomy with adjunctive arteriovenous fistula and relief of the distal iliac obstruction via dissection of the right common iliac artery off the left common iliac vein. [10]

Therefore, early recognition and endovascular treatment of iliac vein compression could prevent a DVT and an improvement in the symptoms. [1]

The treatment, however, depends on the presence of DVT. It is difficult to find isolated iliac vein compression without thrombosis in a clinical setting, but it does not indicate the low incidence of iliac vein compression. [1] In the absence of DVT, conservative treatments are preferred. Compression stockings alone may be effective. However, this review showed that the literature about May-Thurner Syndrome without DVT does not mention the specific treatment used in the conservative therapy.

## Conclusion

The data obtained from the evaluated patients suggest that those ones who have the May-Thurner syndrome are more likely to present thrombosis. Treatment involves both open surgical and endovascular interventions. Open procedures include venous patch angioplasty, division and reallocation of the right common iliac artery, and placement of a silicon elastic bridge over the iliac vein. [14] The data also suggests that endovascular treatment for IVCS, with or without DVT, is safe and effective, although it is still not certain what the best treatment is. [1] Further clinical trials are required to define the optimal treatment strategy [8], especially in the May-Thurner Syndrome cases in the absence of DVT.

Finally, based on the review of the literature, a combination of conservative and endovascular therapy usually provides the best treatment in most cases.

## References

1. Lou WS, Gu JP, He X. Et al. Endovascular Treatment for Iliac Vein Compression Syndrome: a Comparison between the Presence and Absence of Secondary Thrombosis. *Korean J Radiol.* 2009; 10:135-143.
2. Budnur SC, Singh B, Mahadevappa CN. Et al. Endovascular treatment of iliac vein compression syndrome (May-Thurner). *Cardiovasc Interv and Ther.* 2013; 28:101-105.
3. Hager ES, You T, Tahara R. Et al. Outcomes of endovascular intervention for May-Thurner syndrome. *J Vasc Surg: Venous and Lym Dis.* 2013; 1:270-5.
4. Murphy EH, Davis CM, Journeycake JM. Et al. Symptomatic ileofemoral DVT after onset of oral contraceptive use in women with previously undiagnosed May-Thurner Syndrome. *J Vasc Surg.* 2009; 49:697-703.
5. Pandit SA, Hayes M, Guiney-Borgelt S. Et al. Iatrogenic May-Thurner Syndrome After EVAR. *Ann Vasc Surg.* 2014; 28: 739. e17-739.e20.
6. Liu Z, Gao N, Shen L. Et al. Endovascular Treatment for Symptomatic Iliac Vein Compression Syndrome: A Prospective Consecutive Series of 48 Patients. *Ann Vasc Surg.* 2014; 28: 695-704.
7. Oguzkurt L, Tercan F, Sener M. Successful Endovascular Treatment of Iliac Vein Compression (May-Thurner) Syndrome in a Pediatric Patient. *Cardiovasc Intervent Radiol.* 2006; 29:446-449.
8. Ludwig B, Han T, Amundson D. Postthrombotic Syndrome Complicating a Case of May-Thurner Syndrome Despite Endovascular Therapy. *CHEST.* 2006; 129:1382-1386.
9. Loukas M. Et al. A case of May-Thurner syndrome. *Folia Morphologica.* 2008; 67: 214-217.
10. Suwanabol PA, Tefera G, Schwarze ML. Syndromes Associated With the Deep Veins: Phlegmasia Cerulea Dolens, May-Thurner Syndrome, and Nutcracker Syndrome. *Perspectives in Vascular Surgery and Endovascular Therapy.* 2010; 22(4) 223-230.
11. Smeds MR, Jacobs DL. Treatment of Chronic Venous Stent Occlusion With a Wildcat Catheter. *Vascular and Endovascular Surgery.* 2011; 45(5) 453-456.
12. Abboud G, Midulla M, Lions C. "Right-Sided" May-Thurner Syndrome. *Cardiovasc Intervent Radiol.* 2010; 33:1056-1059.
13. Mahnken AH, Thomson K, de Haan M, O'Sullivan GJ. CIRSE Standards of Practice Guidelines on Iliocaval Stenting. *Cardiovasc Intervent Radiol.* 2014; 37:889-897.
14. Knipp BS, Ferguson E, Williams DM. Factors associated with outcome after interventional treatment of symptomatic iliac vein compression syndrome. *J Vasc Surg.* 2007; 46:743-9.

### Publish in International Archives of Medicine

International Archives of Medicine is an open access journal publishing articles encompassing all aspects of medical science and clinical practice. IAM is considered a megajournal with independent sections on all areas of medicine. IAM is a really international journal with authors and board members from all around the world. The journal is widely indexed and classified Q2 in category Medicine.