

Aortic Root abscess repair in a patient with previous mechanical aortic valve replacement, mitral regurgitation and ischemic heart disease (Case Report).

Ahmed Fouad ^a

a= Cardiothoracic surgery Department, faculty of Medicine, Ain Shams University. Abbassia, 11381 Cairo, Egypt. Tel.: +2 01114567874; email: afouad38@yahoo.com. Received 25 January 2016; received in revised form 6 April 2016; accepted 2 July 2016.

Abstract

A complex case of aortic root abscess and fistula between the aorta and left ventricle after mechanical aortic valve replacement. The underlying pathology was concomitant severe rheumatic mitral regurgitation and ischemic heart disease with non viable anterior wall and apex. Our management plan was to treat the abscess, patch the fistula and replace the mitral valve and not to re replace the mechanical aortic valve to use its cuff to fix the patch. We decided not to graft the LCX territory to avoid extensive dissection and to minimize the aortic cross clamp time; simplifying the complex case and positively affected the outcome.

Key Words: aortic root abscess, infective endocarditis, rheumatic heart disease.

INTRODUCTION:

The surgical treatment of aortic root abscess is a challenging operation and is associated with a high early morbidity and mortality [1]. We report one of those cases with fistula between the aorta and left ventricle. The case

was also associated with myocardial ischemia with the need for revascularization to the LCX territory non-viable anterior wall and apex. In addition, the patient had rheumatic affection of the native mitral valve causing severe mitral regurgitation. The complexity of the case and the decision whether to re replace the mechanical

aortic valve and/or to graft the LCX territory was a real challenge.

CASE REPORT:

A 47-year old ex-smoker male patient with the background history of rheumatic heart disease, hypertension and dyslipidemia had undergone aortic valve replacement with mechanical bileaflet valve 20 years back. The patient gave a recent history of infective endocarditis related to the prosthetic mechanical aortic valve and presented to our department in class 3 NYHA dyspnea and class 2 CCS angina. echocardiographic even examination showed an aortic root abscess cavity below the right coronary artery origin with fistula between the aorta and left ventricle. The picture was mimicking severe para-valvular aortic regurgitation. Other findings included: severe mitral regurgitation due to rheumatic affection, a dilated left ventricle reaching 53 mm in systole and 64 mm in diastole and a low ejection fraction percentage of 40%. The patient was receiving anti failure measures and intravenous antibiotics. His

preoperative work up included coronary angiography a 90% LCX lesion and an 80% lesion in LAD that supplies non viable anterior wall and apex, as confirmed by perfusion scan. PCI was done for significant RCA lesion using bare metal stent. The decision for the LCX was either a vein graft during surgery or drug eluting stent after surgery to avoid clopidogrel before bypass. Intraoperatively, the abscess was drained with debridement of the necrotic tissues and Gelweave patch repair from cuff of the prosthetic aortic valve up to just below the RCA origin. (Fig. 1). The mechanical aortic valve was kept without change as it was free from any vegetations and movement restriction. The mitral valve was replaced with a size 27 St. Jude mechanical prosthesis with preservation of the posterior mitral leaflet. The aortic cross clamp time was 110 minutes and the lowest core temperature was 28 degrees centigrade. The decision was taken not to graft the LCX territory to avoid full dissection of the back of the heart and minimize the cross clamp

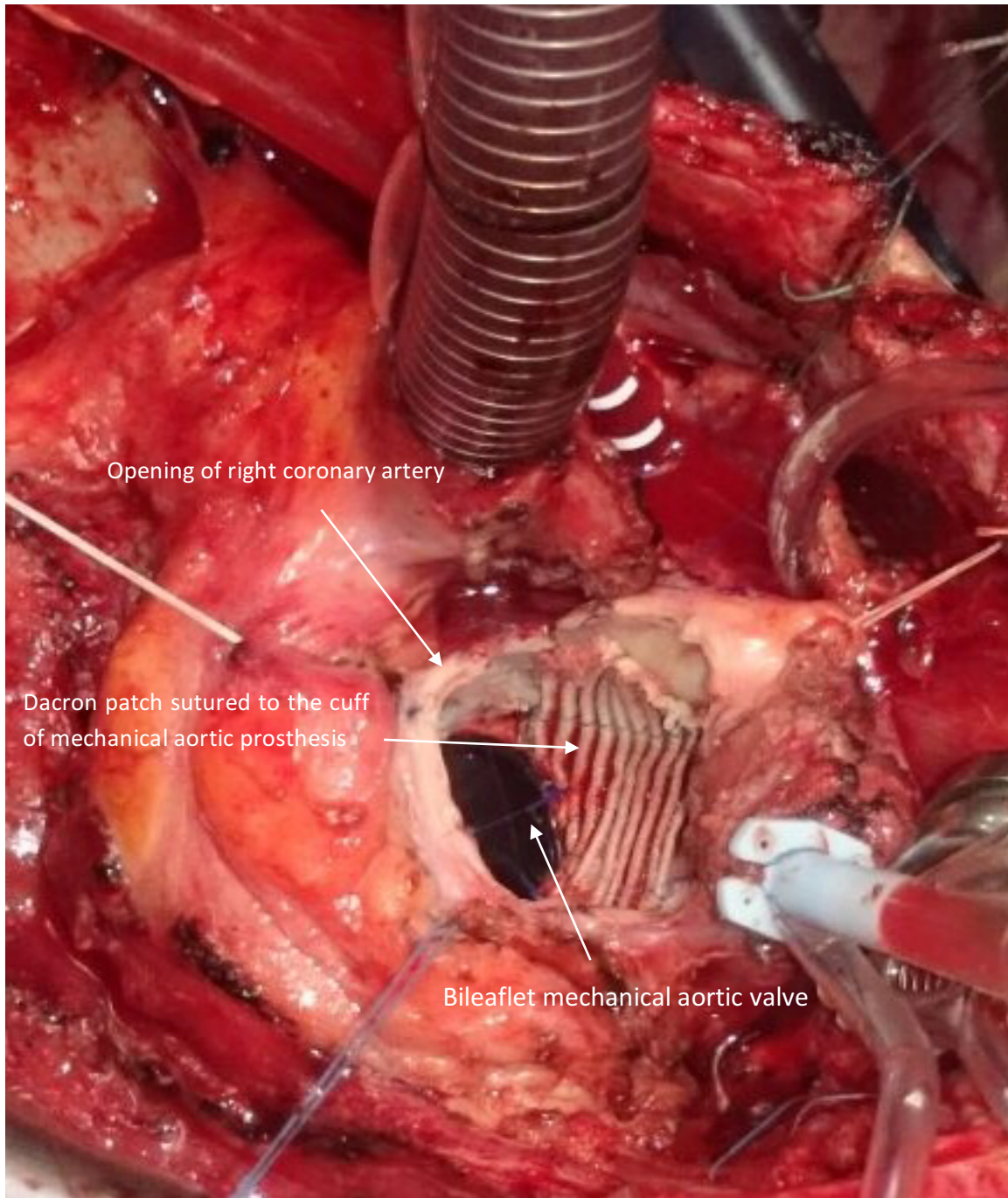


Figure 1: closure of fistula by Dacron patch extending till just below the opening of the right coronary artery and sutured to the edge of cuff of mechanical aortic prosthesis

time. In the postoperative period the patient was on the mechanical ventilation for 20 hours with inotropic support for 141 hours and overall ICU stay of 161 hours. He received IV antibiotics for 6 weeks as well as warfarin, antiplatelets, diuretics and ACE inhibitors. His post operative Echocardiography showed an EF of 38%, well functioning both mitral and aortic mechanical valves, no residual fistula between the aorta and left ventricle. The patient was referred back to the cardiology service for drug eluting stent for the LCX.

DISCUSSION

The complexity of the presented case was a challenge in the decision making whether to keep the prosthetic aortic valve in place or to re replace it and it was decided to keep it in place because it was free of vegetations, was moving freely, its cuff was quite useful in sewing the patch to its border which simplified the procedure and shortened the clamp time. Also the decision not to graft the marginal branch of the LCX helped to minimize the dissection and

shortened the ischemic time too. The reason behind our patient developing aortic root abscess following infective endocarditis remained obscure. Shiraswa reported a rare case of aortic root abscess after percutaneous coronary intervention [2]. In a thirteen - years study that included as much as 1199 patients who underwent aortic valve surgery for aortic valve endocarditis, Leontyev and colleagues concluded that the surgical treatment of aortic root abscess is a challenging operation and is associated with a high early morbidity and mortality. However, the long-term survival and freedom from reoperation was satisfactory [1]. The retrospective study of Musci and collaborators identified 1313 with active infective endocarditis over 22 years. Like native endocarditis, the study concluded that early prosthetic valve endocarditis was associated with higher rates of complications and mortality compared to late endocarditis [3]. The late presentation of endocarditis, the decision not to replace the aortic prosthesis and to delay the

management of LCD lesion have positively affected the outcome of this patient.

REFERENCES

1- Leontyev S, Davierwala PM, Krogh G, Feder S, Oberbach A, Bakhtiary F, Misfeld, M, Borger MA, Mohr FW, Early and late outcomes of complex aortic root surgery in patients with aortic root abscesses, *Eur J Cardiothorac Surg.* 2015 Apr 12. pii: ezv138. [Epub ahead of print].

2- Shirasawa B, Suzuki R, Murakami M, Kobayashi T, Itoh H, Mikamo A, Hamano K, Aortic root abscess after percutaneous coronary intervention, *Kyobu Geka.* 2007 Nov; 60(12):1062-5.

3- Musci M, Hubler M, Amiri A, Stein J, Kosky S, Meyer R, Weng Y, Hetzer R, Surgical treatment for active infective prosthetic valve endocarditis: 22-year single-centre experience, *Eur J Cardiothorac Surg.* 2010 Nov;38(5):528-38. doi: 10.1016/j.ejcts.2010.03.019. Epub 2010 May 23.