

# The MMP-2, MMP-9 Expression and Collagen Density of the Ambonese Banana Stem Sap Administration on Wound Healing

*by* Hendrik Setia Budi

---

**Submission date:** 19-Aug-2019 10:50AM (UTC+0800)

**Submission ID:** 1161255649

**File name:** nas\_The\_MMP-2,\_MMP-9\_Expression.pdf (661.62K)

**Word count:** 3724

**Character count:** 19788

## The MMP-2, MMP-9 Expression and Collagen Density of the Ambonese Banana Stem Sap Administration on Wound Healing

Hendrik Setia Budi<sup>1\*</sup>, Eha Renwi Astuti<sup>2</sup>

1. Department of Oral Biology, Faculty of Dental Medicine Universitas Airlangga, Surabaya, Indonesia.

2. Department of Dentomaxillofacial Radiology, Faculty of Dental Medicine Universitas Airlangga, Surabaya, Indonesia.

### Abstract

Matrix metalloproteinases (MMP) will degrade of the extracellular matrix and proteins, including collagen, elastin, gelatin, matrix glycoproteins and proteoglycans. It affects the BMP in the process of differentiation and new bone tissue remodeling. Ambonese banana (Musa paradisiaca var. Sapientum) have potency to accelerate wound healing through platelet derived growth factor (PDGF-BB) signaling.

The research was conducted to prove the role of ambonese banana stem sap gel (GEGPA) on the MMP-2 and MMP-9 expression affected to collagen density of tooth extraction wound healing. This study used 24 male wistar rats were divided into 2 groups: one is a control without being treated, and the other one is 3 group GEGPA dose 60 mg in 4% Hydroxypropyl Methylcellulose. All groups were examined for the expression of MMP-2, MMP-9, and collagen density in alveolar socket areas on day 7 and 14.

The results showed there were significant differences in the expression of MMP-2, MMP-9, and collagen density in the alveolar socket healing between day 7 and 14 ( $p=0.00$  and  $p=0.00$ ). There was a strong correlation  $p=0.963$  between the inhibition of MMP-2, MMP-9 and the increasing of collagen density.

It is concluded that GEGPA increases collagen density on wound healing of tooth extraction through inhibition MMP-2 and MMP-9.

Experimental article (J Int Dent Med Res 2019; 12(2): 492-497)

**Keywords:** immunohistochemistry, MMP-2, MMP-9, collagen density.

**Received date:** 29 July 2018

**Accept date:** 27 October 2018

### Introduction

Wound healing process is basically the same, but the infection, surgical interventions, and medications that can affect accelerate of healing. The purpose of local therapy to inhibit the excessive bleeding then the healing process is not disturbed, and minimise systemic side effect.<sup>1,2</sup> Normal wound healing is quite complex, involving inflammatory cells and growth factors that influence each other in every phase of the healing. It begins with formation of a blood clot consisting of fibronectin and fibrin. A blood clot is a crucial stage in the process of wound healing.

The phase of inflammation is dominated by neutrophils and macrophages, followed by reepithelial and granulation cell formation. The next stage is the remodeling of granulation tissue by replacing it with connective tissue dominated by fibroblasts.<sup>3,4</sup> In the healing of infected wounds or in patients with diabetes mellitus, the tissue around the wound is dominated by inflammatory cells such as neutrophils and macrophages in a long term, so the formation of connective tissue is inhibited.<sup>5,6,7</sup>

Neutrophils and macrophages are producing Matrix metalloproteinase (MMP) cells. MMP is a proteolysis enzyme involved in extracellular matrix degradation.<sup>8</sup> MMP is a family of zinc-dependent endopeptidase, a large collection of enzymes responsible for tissue remodeling and degradation of various components of the extracellular matrix, including collagen, elastin, gelatin, matrix glycoproteins and proteoglycans.<sup>9,10</sup> Bone remodeling is formed from collagen scaffold that stimulates osteoblasts to grow through the Bone

#### \*Corresponding author:

Hendrik Setia Budi

Department of Oral Biology

Faculty of Dental Medicine, Airlangga University

Surabaya, Indonesia, Tel. +628123273272

e-mail : hendrik-s-b@fkg.unair.ac.id

Morphogenetic Protein (BMP). In the process of healing wounds, the high MMP level can inhibit healing in remodeling. The medical treatment to inhibit or decrease MMP around the wound are necessary. In the case of periodontal diseases such as periodontitis aggressive, MMP produced in the surrounding tissue causes damage of periodontium tissue and alveolar bone. It is also related to an increase in bacterial colonies such as *Actinobacillus actinomycetemcomitans*. Tetracycline is the right choice to inhibit MMP activity as anticollagenase.<sup>11</sup>

Ambonese banana (*Musa paradisiaca* var. *sapientum*), is a plant found in Indonesia, especially in areas with a lot of sunshine. Plants that contain lectins with high concentrations can be used for wound healing through the process of coagulation or blood clot formation.<sup>12</sup> Previous study of galectin-3 which is a class of lectins, showed an increase in Vascular Endothelial Growth Factor (VEGF) and Basic Fibroblast Growth Factor (bFGF) on angiogenesis response.<sup>13</sup>

The topical administration of banana stem sap with 30 and 60 mg doses in the socket area showed an increase of fibroblasts and osteoblasts through the expression of PDGF-BB, BMP-4 and BMP-7 in the wound healing process of rats tooth extraction.<sup>14</sup> This aims of study to prove the role of Ambonese banana stem sap gel (GEGPA) on the MMP-2 and MMP-9 expression affected to collagen density of tooth extraction wound healing.

### Materials and methods

This study was approved by the Ethical Committee of the Faculty of Dental Medicine, Universitas Airlangga, Indonesia. This study use the post-test only control group design. The sample was male rats (*Rattus norvegicus*) Strain Wistar, 3 months of age, weighing 200-300 grams, in healthy condition, and obtained from the Biochemistry Laboratory, Faculty of Medicine, Airlangga University.

The sap can be obtained in large quantities by weighing the banana stems about 200 grams and putting them into a blender by adding 200 cc of sterile distilled water. Blend for 5 minutes until smooth, and then conduct filtration using Whatman filter paper no.1. The filtrate was dried using a freeze dry. The dry powder was obtained from different types of

stocks above, and then gel form was created with hydroxypropylmethylcellulose (HPMC) so that the content of the active compound can easily be attached to the injured area and quickly absorbed, with a dose of 60 mg in 4% HPMC.

Rats were anesthetized according to the weight (30 mg / kg theoflurane). Tooth extraction was performed on mandibular incisor using special pull pliers. In the control group socket administrated topically of 4% HPMC. Treatment group socket were administrated 60 mg in 4% HPMC. The gingival mucosa was sutured using a 5-0 vicryl (Ethicon; Johnson & Johnson do Brasil, São Jose dos Campos, SP, Brazil). Each group was observed for the MMP-2 and MMP-9 expression as well as collagen density on day 7 and 14 after tooth extraction.<sup>5</sup>

Immunohistochemistry examination of MMP-2 and MMP-9 expression. The slide was blocked with 3% H<sub>2</sub>O<sub>2</sub> in PBS incubation for 20 minutes and at room temperature. Slides were washed with PBS pH 7.4 and blocked with 1% BSA in PBS for 60 minutes. Slide was labeled with a primary antibody anti MMP-2 or MMP-9 in 1% BSA overnight at 4° C. Slides were washed with PBS pH 7.4 three times for 5 minutes. The slide labeled with secondary antibody goat anti rat IgG biotin for 1 hour at room temperature. The washing was done with with PBS pH 7.4 three times for 5 minutes. Slide incubation was performed with SA-HRP (Streptavidin-Horseradish Peroxidase) 1:500 for 40 minutes at room temperature. Slides were washed with PBS pH 7.4 three times for 5 minutes. The slide was dripped with substrate chromogen DAB (diamino benzidine tetrahydrochloride 3.3) for 20 minutes. Slides were washed with PBS pH 7.4 three times for 5 minutes and proceeded with dH<sub>2</sub>O three times each for 5 minutes. Counterstain was performed with Methyl Green 1% at room temperature. The slide was soaked with tap water for 5 minutes and dried overnight at room temperature. Mounting and cover with a cover glass. The slide was viewed with a light microscope.<sup>15</sup>

Formation of collagen in the wound healing process can be observed in histopathological tissue, using Masson Tricome staining. The area of collagen fibers is a percentage (%) of collagen density calculated by dividing the area of connective tissue collagen fibers formed at the center of healing (healing

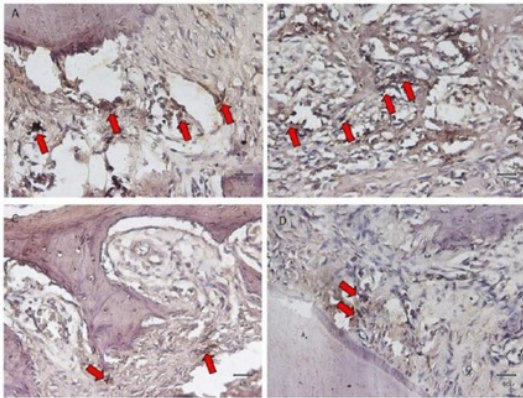


center) with a total area of measurement<sup>16,17</sup>.

Data were represented as Mean  $\pm$  Standard deviation (SD) of each group. Statistical significance was determined by one-way ANOVA, and correlation test between variables  $p < 0.05$ .

## Results

Data examination of MMP-2 and MMP-9 expression on the socket healing day 7 and 14 with immunohistochemical staining were showed brown color cell (figures 1 and 2). The number of brown cells were calculated and compared between the treatment group and the control group.



**Figure 1.** Expression of MMP-2 (red arrow) on the healing sockets day 7 and 14 with 400x magnification microscope. A.B. The control group day 7 and 14. C.D. The treatment group day 7 and 14.

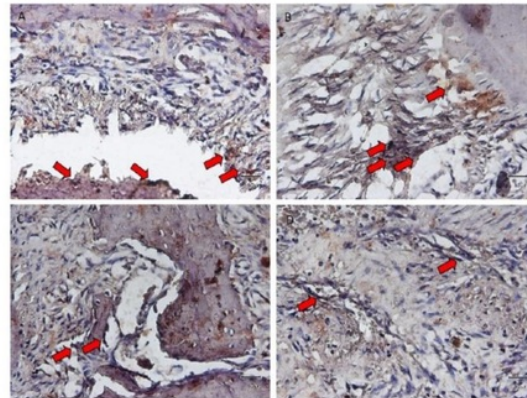
The cells number expressing MMP-2 and MMP-9 showed a significant difference between treatment and control groups with  $p < 0.05$  ( $p = 0.00$  and  $p = 0.00$ ) (table 1).

The collagen fibers showed on alveolar sockets healing area (Figure 3). Extensive collagen fibers in the alveolar socket healing day 7 and 14 showed a significant difference between treatment and control groups with  $p < 0.05$  ( $p = 0.00$  and  $p = 0.00$ ) (Table 1).

GROUPS	MMP-2		MMP-9		Collagen	
	Day 7	Day 14	Day 7	Day 14	Day 7	Day 14
Control	23,33 2,06 <sup>a</sup>	$\pm$ 31,00 $\pm$ 0,89 <sup>a</sup>	27,83 $\pm$ 2,32 <sup>a</sup>	31,50 2,26 <sup>a</sup>	$\pm$ 24,26 $\pm$ 3,07 <sup>a</sup>	$\pm$ 75,95 $\pm$ 2,58 <sup>a</sup>
Treatment	15,67 1,96 <sup>b</sup>	$\pm$ 17,83 $\pm$ 2,13 <sup>b</sup>	16,50 $\pm$ 2,35 <sup>b</sup>	20,00 1,41 <sup>b</sup>	$\pm$ 60,52 $\pm$ 5,40 <sup>b</sup>	$\pm$ 82,92 $\pm$ 4,45 <sup>b</sup>

Description: difference on superscript showed there were significant differences.

**Table 1.** The cells expressing MMP-2 and MMP-9 on the alveolar sockets healing day 7 and 14.



**Figure 2.** Expression of MMP-9 (red arrow) on the healing sockets day 7 and 14 with 400x magnification microscope A.B. The control group day 7 and 14. C, D The treatment group day 7 and 14.

Function	Eigenvalue	% of Variance	Cumulative %	Canonical Correlation
1	12.654 <sup>a</sup>	100.0	100.0	.963

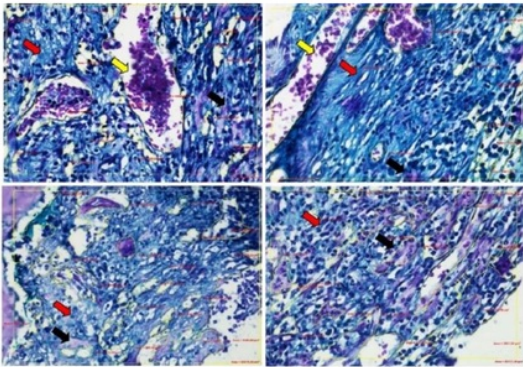
a. First 1 canonical discriminant functions were used in the analysis.

**Table 2.** Correlation test between groups.

## Discussion

The alveolar healing process post tooth extraction and implant are similar in bone regeneration. Inflammation and alveolar bone resorption are response post tooth extraction. Inflammation is a response which occurs as a result of injuries, and the cause of inflammation should be immediately removed so not to interfere even inhibit the regeneration.<sup>18,19</sup>





**Figure 3.** Collagen formation in the healing socket day 7 and 14 with 400x magnification microscope A,B. The control group day 7 and 14. C, D The treatment group day 7 and 14. Red arrow collagen, black arrow new bone, and yellow arrow blood cloth.

Inflammatory cells and fibroblasts will migrate to the socket, especially at the bottom end in day 2 after tooth extraction, and then fibroblasts will synthesize collagen fibrils gradually. Both chondroblasts and fibroblasts will form capillaries and granulation tissue, then fill the matrix extracellular in order to be stable.<sup>20,21,22</sup>

On day 1 socket was only filled by a blood clot containing fibrin and blood cells. Periodontal ligament cells were dominant in the socket, and began to rise rapidly on the day 2.<sup>23,24</sup> The process of bone resorption starts on the alveolar crest which coincides with bone apposition in the socket. Mesenchymal cells, which are an embryo of the periodontal ligament and bone cells, differentiated into osteoblasts and secretes bone matrix on the day 7 of healing socket. At the end of the healing socket, a thin layer of trabecular bone was produced at the start of day 14 and continued for several months.<sup>25</sup>

On the healing process at day 7 showed many areas not filled bone matrix (Figure 1, 2 and 3). The treatment group seen fairly dense fibroblasts that indicates the material is capable to inhibit the inflammation that occurs after rats tooth extraction compared to the control group. This result similar with Vieira et al. study,<sup>26</sup> which explains that the degradation of connective tissue, especially caused TGF- $\beta$ 1 bind to receptors of Smad2 become reduced, thereby affecting the activation of BMP in the process of differentiation and new bone tissue remodeling.

The healing socket on the 7th day showed increased expression of PDGF-BB compared to the 2nd day.<sup>14</sup> PDGF-BB showed activity after being attached to a receptor that is PDGFR- $\alpha$  and PDGFR- $\beta$  as chemotaxis and differentiation of mesenchymal cells.<sup>27</sup> Once attached to a receptor on the cell membrane, it occurred to phosphorylate the protein signaling of Ras-Raf-MAPK pathways which led to the proliferation and the synthesis of extracellular matrix and the Jak-Stat pathway to control the synthesis of inflammatory cytokines.

As chemotaxis and strong differentiation in some cells, the fibroblasts and osteoblasts seem to accumulate at the injured area and then will form the bone matrix. The accumulation of fibroblasts and osteoblasts showed healing activity in the socket, and can be characterized by decreasing MMP around the wound.<sup>26</sup> This is consistent with research that shows the expression of MMP-2 and MMP-9 in the control group was higher than the group that was given GEGPA.

The content of some of the active compounds in ambonese banana stem sap can help in the healing process of wounds. Lectins are proteins that have the effect as an antitumor drug with Human Immunodeficiency Virus (HIV), antimicrobial, mitogenic, and specifically binds to specific carbohydrate part of the glycolipid or glycoprotein molecules.<sup>28</sup> The binding of lectins on bacterial cell membrane glycoprotein will form a bond mannose Binding Lectin (MBL) and then will activate the complement C1 for deposited C3b on the bacterial. The increased disposition C3b will activate C3a and C5a to attract leukocytes to destroy bacteria. Complement C3b binds to C3b-receptor on phagocytes to activate the phagocytosis process. Additionally, C3b deposition will form MAC (Membrane Attack complex) that plays a role in lyse bacteria, thus minimizing the occurrence of infection and speed the wound healing.<sup>29</sup>

In addition to the content of lectins, in extracts of ambonese banana stem sap there are also saponins, flavonoids, saponins and tannins that contribute to wound healing process. Saponins and lectin can cause hemostatic and antibacterial effects that contribute to the process of wound healing. Saponins and lectins on banana stem sap modulate the immune response to an increase in T cell lymphocytes with markers CD3 +, CD4 + and CD8 + T cells

and hematopoietic systems so as to minimize the occurrence of infections.<sup>30</sup> The role of T cells is a lymphocyte activation of B cells, NK cells and macrophages when there was antigen.<sup>31</sup> In healing process, the tannin content in the sap of banana trees acts as a hemostatic and antibacterial through the protein precipitation mechanism of blood cells and bacteria then causes coagulation.

Besides, tannins and anthraquinone also serve as a donor to the free radical and Reactive Oxygen Species (ROS). Free radicals cause lipid peroxidation to form with the final result of malondialdehyde (MDA), which is a compound that causes damage of cell proteins and DNA.<sup>32,33</sup> The content of flavonoids in the banana stems, such as leucocyanidin and anthocyanins, have the ability as antiinflammation through the barriers of the enzyme cyclooxygenase, thus inhibiting prostaglandin synthesis and as an antioxidant by oxidizing free radicals. Inhibition of free radicals in inflammatory disorders can reduce oxidative stress, and cell damage is not widespread.<sup>34</sup>

### Conclusions

The conclusion that GEGPA increased collagen density on wound healing of tooth extraction through inhibition MMP-2 and MMP-9.

### Declaration of Interest

The authors report no conflict of interest.

### References

- Joseph AM, Mary JU, and William AC. Nutrition and chronic wounds. *Adv Wound Care (New Rochelle)* 2014;3(11): 663–81.
- Petersen JK, Krogsgaard J, Nielsen KM, Nørgaard EB. A comparison between 2 absorbable hemostatic agents: gelatin sponge (Spongostan) and oxidized regenerated cellulose (Surgicel). *Int J Oral Surg* 1984;13(5):406-10.
- Matthew P. Caley, Vera L.C. Martins, and Edel A. O'Toole. Metalloproteinases and wound healing. *Adv Wound Care (New Rochelle)* 2015;4(4): 225–34.
- Terukazu S, Takao F, Urara T, Kyosuke T, Takaharu T, Fusanori N. Spry2 is a novel therapeutic target for periodontal tissue regeneration through fibroblast growth factor receptor signaling and epidermal growth factor signaling. *Receptors Clin Investig* 2015;2(2): 1-4.
- Lan C-CE, Wu C-S, Huang S-M, Wu I-H, Chen G-S. High-glucose environment enhanced oxidative stress and increased interleukin-8 secretion from keratinocytes: New insights into impaired diabetic wound healing. *Diabetes* 2013;62(7):2530-8.
- Ira Arundina, Indeswati Diyatri, Theresia Indah Budhy, Foo Yau Jit. The effect of brotowali stem extract (*Tinospora Crispa*) towards increasing number of lymphocytes in the healing process of traumatic ulcer on diabetic wistar rat. *Journal of International Dental and Medical Research* 2017;10 (3):975-80.
- Mady Crusoé-Souza, Karina Quadros Carmel, Luciana Soares de Andrade Freitas Oliveira, et al. Osteoporosis delays the bone healing after mandibular distraction osteogenesis in postmenopausal Osteoporosis model. *Journal of International Dental and Medical Research* 2015;8(2):51-60.
- Amalinei C, Caruntu ID, Giusca SE, Balan RA. Matrix metalloproteinases involvement in pathologic conditions. *Rom J Morphol Embryol* 2010;51(2): 215-28.
- Verma RP & Hansch C. Matrix metalloproteinase (MMPs) : Chemical-biological function and (Q)SARs. *Bioorg & Med Chem* 2007;15: 2223-68.
- Basi DL, Hughes PJ, Thumbigere-Math V, Sabino M, Lunos SA, Jensen E, Gopalakrishnan R. Matrix metalloproteinase-9 expression in alveolar socket of zoledronic acid-treated rats. *J Oral Maxillofac Surg* 2011;69(11): 2698-07.
- Sachin S, Santosh K, Namrata D, and Rushabh JD. Effect of tetracycline HCl in the treatment of chronic periodontitis – A clinical study. *J Int Soc Prev Community Dent* 2014;4(3): 149–53.
- Cooposamy RM. In-vitro studies on lectin derivatives of *Aloe excelsa* (Berger). *J Med Plants Res* 2010;4(17): 1738-42.
- Anna, I.M., Fu-Tong, L, and Noorjahan, P. Galectin-3 is an important mediator of VEGF- and bFGF-mediated angiogenic response. *J exp med* 2010;207(9): 1981-93.
- Hendrik SB. PDGF-BB, BMP-4 and BMP-7 expression of ambonese banana stem sap (*Musa paradisiaca* var. *sapientum*) extract on tooth extraction wound healing. Surabaya. 2013. Dissertation, Airlangga University.
- Boenisch T. Immunochemical staining methods. 3ed. California : DAKO corp.; 2001:26-2.
- Klopfleisch R. Multiparametric and semiquantitative scoring systems for the evaluation of mouse model histopathology- a systematic review. *BMC Vet Res* 2013;9:123.
- Luciano Trevisan Moraes, Paula Cristina Trevilatto, Ana Maria Trindade Grégio, Maria Ângela Naval Machado, Antônio Adilson Soares de Lima. Quantitative analysis of mature and immature collagens during oral wound healing in rats treated by Brazilian propolis. *Journal of International Dental and Medical Research* 2011;4(3):106-10.
- Avila-Ortiz G, Elangovan S, Kramer KWO, Blanchette D, & Dawson DV. Effect of Alveolar Ridge Preservation after Tooth Extraction: A Systematic Review and Meta-analysis. *J Dent Res* 2014;93(10): 950–8.
- Mescher AL. Macrophages and fibroblasts during inflammation and tissue repair in models of organ regeneration. *Regeneration* 2017;4:39–53.
- De Oliveira G., Miziara, M., Silva, E. d., Ferreira, E., Biulchi, A. and Alves, J. Enhanced bone formation during healing process of tooth sockets filled with demineralized human dentine matrix. *Aust Dent J* 2013;58: 326–32.
- Koh TJ and DiPietro LA. Inflammation and wound healing: The role of the macrophage. *Expert rev mol med* 2011;13:e23.
- Wifaq M.Ali Al-Wattar, Warkaa M.Ai-Wattar, Afya Sahib Diab Al-Radha. Microbiological and cytological response to dental implant healing abutment. *Journal of International Dental and Medical Research* 2017;10(3):891-8.
- Hendrik SB, Indah LK, Sri Agus S. Ambonese banana stem sap (*Musa paradisiaca* var. *sapientum*) effect on PDGF-BB expressions and fibroblast proliferation in socket wound healing. *Int J ChemTech Res* 2016;9(12): 558-64.
- Jae-jin A and Hong-in S. Bone Tissue Formation in Extraction Sockets from Sites with Advanced Periodontal Disease : a histomorphometric study in humans. *Int j oral maxillofac implants* 2008; 23:1133-8.
- Farina R, and Trombelli L. Wound healing of extraction sockets. *Endo topics* 2011;25(1):16–43.
- Vieira A.E., Repeke C.E., Ferreira S.B., et al. Intramembranous Bone Healing Process Subsequent to Tooth Extraction in Mice: Micro-Computed Tomography, Histomorphometric and Molecular Characterization. *PLOS ONE* 2015;10(5):e0128021.



27. Chang PC, Seol YJ, Cirelli JA, Pellegrini GR, Jin Q, Franco LM, Goldstein SA, Chandler LA, Sosnowski B, Giannobile WV. PDGF-B gene therapy accelerates bone engineering and oral implant osseointegration. *Gene Ther* 2010;17(1):95-04.
28. Lam SK & Ng, TB. Lectins: production and practical applications. *Appl Microbiol Biotechnol* 2011;89:45-5.
29. Singh SS, Devi SK, Ng TB. Banana lectin: a brief review. *Molecules* 2014;19:18817-27.
30. Swanson MD, Winter HC, Goldstein IJ and Markovitz DM. A lectin isolated from bananas is a potent inhibitor of HIV replication. *J Biol Chem* 2010;285:8646-55.
31. Corthay A. How do Regulatory T Cells Work ?. *Scand J Immunol* 2009;70(4):326-36.
32. Antonio A, Mario FM, and Sandro A. Lipid peroxidation: production, metabolism, and signaling mechanisms of malondialdehyde and 4-hydroxy-2-nonenal. *Oxid Med Cell Longev* 2014;e360438.
33. Gocmen G, Gonul O, Oktay NS, Yarat A, Goker K. The antioxidant and anti-inflammatory efficiency of hyaluronic acid after third molar extraction. *J Craniomaxillofac Surg* 2015;43(7):1033-7.
34. Agarwal PK, Singh A, Gaurav K, Goel S, Khanna HD, Goel RK. Evaluation of wound healing activity of extracts of plantain banana *Musa sapientum* var. *paradisiaca*) in rats. *Indian J Exp Biol.* 2009;47:32-40.

# The MMP-2, MMP-9 Expression and Collagen Density of the Ambonese Banana Stem Sap Administration on Wound Healing

## ORIGINALITY REPORT

19%

SIMILARITY INDEX

18%

INTERNET SOURCES

10%

PUBLICATIONS

0%

STUDENT PAPERS

## PRIMARY SOURCES

1	<a href="https://es.scribd.com">es.scribd.com</a> Internet Source	4%
2	<a href="https://old.oalib.com">old.oalib.com</a> Internet Source	2%
3	<a href="https://bmcvetres.biomedcentral.com">bmcvetres.biomedcentral.com</a> Internet Source	1%
4	<a href="https://www.ncbi.nlm.nih.gov">www.ncbi.nlm.nih.gov</a> Internet Source	1%
5	<a href="https://www.termidia.pl">www.termidia.pl</a> Internet Source	1%
6	<a href="https://www.veterinaryworld.org">www.veterinaryworld.org</a> Internet Source	1%
7	<a href="https://www.medicinaoral.com">www.medicinaoral.com</a> Internet Source	1%
8	<a href="https://media.neliti.com">media.neliti.com</a> Internet Source	1%
9	Zameer, A.. "Increased ICAM-1 and VCAM-1	



---

expression in the brains of autoimmune mice",  
Journal of Neuroimmunology, 200309 1%

Publication

---

10 [repositorio.unesp.br](http://repositorio.unesp.br) 1%

Internet Source

---

11 Wolisi, G. O., Godwin O. Wolisi, J. Majekodunmi, G. B. Bailey, and P. Urso. "IMMUNOMODULATION IN PROGENY FROM THYMECTOMIZED PRIMIPAROUS MICE EXPOSED TO BENZO(a)PYRENE DURING MID-PREGNANCY", Immunopharmacology and Immunotoxicology, 2001. 1%

Publication

---

12 Ruth Sum. "Wound-healing properties of trehalose-stabilized freeze-dried outdated platelets", Transfusion, 4/2007 1%

Publication

---

13 [www.karger.com](http://www.karger.com) 1%

Internet Source

---

14 [www.jscimedcentral.com](http://www.jscimedcentral.com) <1%

Internet Source

---

15 Starlinger, Veronika, Olaf Wendler, Monika Gramann, and >Bernhard Schick. "Laminin expression in juvenile angiofibroma indicates vessel's early developmental stage", Acta Oto-Laryngologica, 2007. <1%

Publication

---

16	<a href="http://repo.lib.tokushima-u.ac.jp">repo.lib.tokushima-u.ac.jp</a> Internet Source	<1%
17	<a href="http://akademik.unsoed.ac.id">akademik.unsoed.ac.id</a> Internet Source	<1%
18	<a href="http://repository.unair.ac.id">repository.unair.ac.id</a> Internet Source	<1%
19	<a href="http://www.tandfonline.com">www.tandfonline.com</a> Internet Source	<1%
20	<a href="http://ftp1.economics.smu.edu">ftp1.economics.smu.edu</a> Internet Source	<1%
21	<a href="http://ejh.it">ejh.it</a> Internet Source	<1%
22	A. A. Kompiang Martini, Agung Nova Mahendra. "Administration of 50% propolis ethanolic extract increases the number of gingivitis fibroblast in H2O2-induced rats", AIP Publishing, 2019 Publication	<1%
23	<a href="http://www.scielo.edu.uy">www.scielo.edu.uy</a> Internet Source	<1%
24	<a href="http://www.science.gov">www.science.gov</a> Internet Source	<1%
25	<a href="http://jurnal.ugm.ac.id">jurnal.ugm.ac.id</a> Internet Source	<1%

---

R.K. Yadav. "Recent Advances in Studies on

26 Hydroxamates as Matrix Metalloproteinase Inhibitors: A Review", Current Medicinal Chemistry, 04/01/2011 <1%  
Publication

---

27 The ACL Handbook, 2013. <1%  
Publication

---

28 Yabing Wang, Haoxuan Li, Yanhuizhi Feng, Peilin Jiang, Jiansheng Su, Chen Huang. " <1%  
Dual micelles-loaded gelatin nanofibers and their application in lipopolysaccharide-induced periodontal disease  
", International Journal of Nanomedicine, 2019  
Publication

---

Exclude quotes Off

Exclude matches Off

Exclude bibliography On