

Osteogenic Ability of Combined Hematopoietic Stem Cell, Hydroxyapatite Graft and Platelet Rich Fibrin on Rats (*Rattus Novergicus*)

by Dwi Rahmawati

Submission date: 18-Feb-2018 03:28PM (UTC+0800)

Submission ID: 917574249

File name: JKIMSU,_Vol._6,_No._4,_October-December_2017_Page_88-95.pdf (184.72K)

Word count: 2803

Character count: 15448

ORIGINAL ARTICLE

Osteogenic Ability of Combined Hematopoietic Stem Cell, Hydroxyapatite Graft and Platelet Rich Fibrin on Rats (*Rattus Novergicus*)

Dwi Rahmawati¹, Retno Indrawati Roestamadji^{2*}, Ernie Maduratna Setiawati³, Anita Yulianti⁴,
Taufan Bramantoro⁵

¹Oral and Dental Science, ²Department of Oral Biology, ³Department of Periodontic, ⁴Department of Dental Material and Technology, ⁵Department of Dental Public Health, Faculty of Dental Medicine, Universitas Airlangga, Surabaya-Indonesia

Abstract:

Background: In Indonesia, the incidence rate of tooth extraction as the main form of dental treatment reached as high as 79.6% in 2014. Teeth extraction leads to periodontal tissue defect whose treatment, incorporating the use of graft material Hydroxyapatite (HA) and Platelet Rich Fibrin (PRF) with stem cells, has become increasingly widespread. The stem cell potentially put to therapeutic use is the Hematopoietic Stem Cell (HSC). **Aim and Objectives:** to examine the effect of hematopoietic stem cell addition to HA graft and PRF post-tooth extraction on the number of osteoblasts and amount of Osteoprotegerin (OPG) in periodontal defect treatment. **Material and Methods:** This study constituted laboratory-based experimental research with a post test-only control group. Twenty four rats (*Rattus novergicus*) represented the animal study model in this research. Alveolar bone defect in the animal study model was induced by extracting the first molar of the mandible using sterile needle holder clamps. The sample population was divided into four groups: K0: the untreated control group; K1: socket filled with HA Graft and PRF. K2: socket filled with HSC 10⁵ cells. K3: the socket filled with HA Graft and PRF with HSC 10⁶ cells. **Results:** The K3 group had both the highest number of osteoblasts when compared with the control group (350.17 ± 33.42; P < 0.001) and the strongest OPG expression of all treatment groups (11,36 ± 0,54; P < 0.01). **Conclusion:** A combination of HA graft, PRF and HSC significantly increases the

expression of OPG and the number of osteoblasts rendering it a potential treatment for tissue engineering-based periodontal defect.

Keywords: Osteoprotegerin, Osteoblast, Bone regeneration, Bone graft, Tissue Engineering

Introduction:

Tooth extraction is one of the most common dental treatments carried out in Indonesia and can lead to bone defects. According to health-related statistics, 2014 witnessed the percentage of dental treatment culminating in tooth extraction reaching as high as 79.6% [1]. Previous research highlighted the prevalence of tooth extraction-related complications such as fractures - 31.82%, bleeding - 4.54%, and swelling - 2.27% [2]. Tooth extraction can lead to alveolar bone resorption and the destruction of alveolar bone components. Moreover, it may lead to resorption of the jawbone [3].

The most up-to-date treatment performed for periodontal defects is the use of Hydroxyapatite (HA) graft materials and Platelet Rich Fibrin (PRF). A combination of HA and PRF materials produces encouraging bone regeneration therapy results. According to a previous study, HA and PRF significantly improved the clinical outcomes resulting from the treatment of infrabony defects.

The use of HA may enhance the effect of PRF through the maintaining of space for tissue regeneration by inducing an osteoconductive effect in the infrabony defect region [4].

The formation of osteoblasts is preceded by pre-osteoblasts which subsequently undergo a process of maturation which also differentiates osteocytes. Osteocytes are bone cells found in canaliculi which form a bone matrix. Bone formation is associated with increased expression of Osteoprotegerin (OPG) or reduced expression of the activator Nuclear Factor kappa β ligand receptor (RANKL). Pathological bone resorption is also known to involve increased expression of RANKL ratio and diminished expression of OPG. During the inflammatory response, proinflammatory cytokines, such as Interleukin (IL-1b), IL-6, IL-11 and IL-17 and Tumor Nuclear Factor (TNF- α) osteoclastogenesis, can be induced by increasing RANKL expression, while simultaneously reducing OPG production in osteoblasts / Stroma cells [5].

Periodontal defect treatment involving graft material HA and PRF with stem cells has become increasingly popular. The stem cell potentially used as a form of therapy is the Hematopoietic Stem Cell (HSC) used in the treatment of leukemia and other blood and immune system diseases [6]. However, HSC concepts have been evolved to the extent that reports exist of their ability to also induce non-hematopoietic cell lineage, such as muscle cells, blood vessel cells and osteoblasts [7].

At the time of writing, bone regeneration therapy is usually restricted to a combination of HA graft and PRF with no research into the effects of Hematopoietic Stem Cell addition having been conducted. Therefore, further investigation is

needed to elucidate the benefits of HSC with HA and PRF graft on the post-extraction tooth socket with regard to the degree of osteoblasts and OPG expression within periodontal defect treatment.

Material and Methods:

This study received approval through an ethical clearance letter from the Faculty of Dental Medicine, Universitas Airlangga number 042/HRECC.FODM/IV/2017. This study was a laboratory-based experimental research with a post test-only control group. Twenty four rats (*Rattus novergicus*) were used as the animal study model in this research. The sample was divided into four groups; K0: control group without treatment; K1: sockets filled with HA graft and PRF. K2: sockets filled with HSC 10^5 cells. K3: sockets filled with HA graft and PRF with HSC 10^5 cells. The study of alveolar bone defect in the animal model was affected by extracting the first molar of the mandible using sterile needle holder clamps. Before tooth extraction was performed, the animal models were injected with 0.05-0.1ml/10g body Intra-muscular (IM) rodent anesthesia (ketamine, xylazine, acepromazine and sterile isotonic saline).

Following tooth extraction, all wounds were stitched with silk 3.0 and a period of 21 days elapsed before the animal study models were sacrificed. An osteoblast and OPG marker kit (Sigma Aldrich™, Germany) was then used to conduct Hematoxylin Eosin (HE) and Immunohistochemistry (IHC) examinations.

Statistical analysis was performed using Statistical Package for the Social Sciences (SPSS) 20.0 software for windows 8.1 (SPSS™, Chicago, United State). Data obtained from the OPG expression and osteoblast cell count was then subjected to ANOVA analysis and, in cases of any

difference between the treatment groups, a subsequent Tukey test.

Results:

Characterization of Hematopoietic Stem Cell:

Characterization of Hematopoietic stem cells was performed by means of immunohistochemical examination using monoclonal antibodies CD105 (negative) and CD45 (positive). The hematopoietic stem cell characteristics of the blood sample were highlighted by use of a CD45 marker employing a fluorescent green light (Fig. 1).

Number of Osteoblast Cell Count using HE Staining:

The K3 group histopathologic features confirmed a higher osteoblasts cell count compared with that of the K0, K1 and K2 groups (Fig. 2). The use within this study of a statistical Analysis of Variance (ANOVA) test produced significant results 0.000 ($p < 0.05$). Tukey test was subsequently employed to analyze the relative significance of the number of osteoblasts within each group. The K3 group recorded the highest number of osteoblasts when

compared with its K0, K1 and K2 counterparts (Table 1.). The Tukey test results revealed a very significant difference between the negative control group and all treatment groups ($p < 0.05$), as was also the case with the positive control group ($p < 0.05$) (Table 2.).

Osteoprotegerin (OPG) expression with Immunohistochemistry (IHC) Examination:

OPG expression is characterized by brown coloration in osteoblasts due to antigenic binding and the presence of OPG antibodies. The K3 group experienced high OPG expression characterized by a stronger brown color than the other three K groups. Group K0 contained fewer OPG expressions than K1, K2, and K3 (Fig. 3). The ANOVA test result confirmed significant OPG expression in all groups ($p < 0.05$), while that of the subsequent Tukey test revealed strong ANOVA Expression across them ($p < 0.05$).

The mean results confirmed the K3 group as having the highest average expression of OPG. Based on statistical analysis, the K3 group

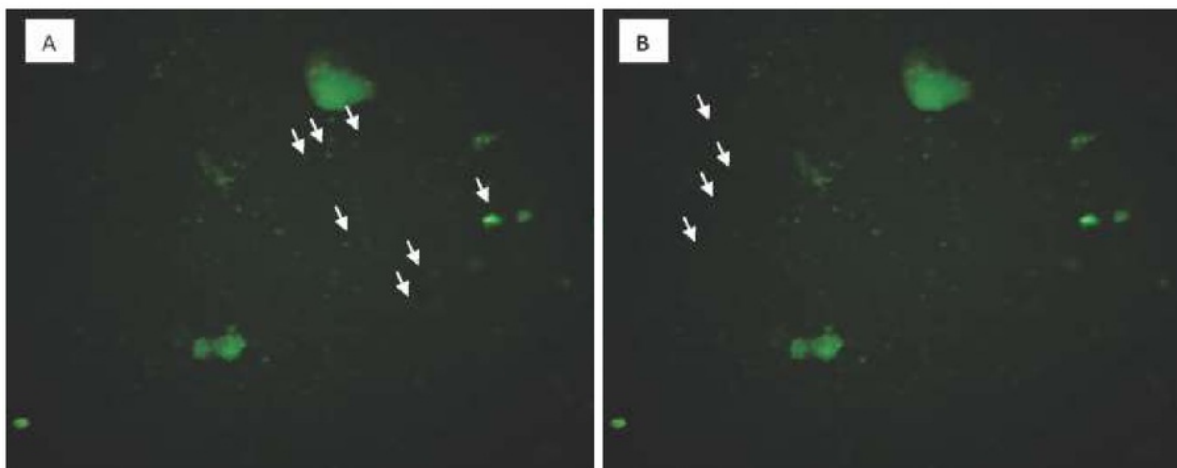


Fig. 1: Fluorescence Result of Blood Samples on 5th Day (A) Strongly Positive against CD45 Marker; (B) Appeared Negative against CD105 Marker (200 x Magnification, Olympus Microscope CKX53, Olympus Corporation™).

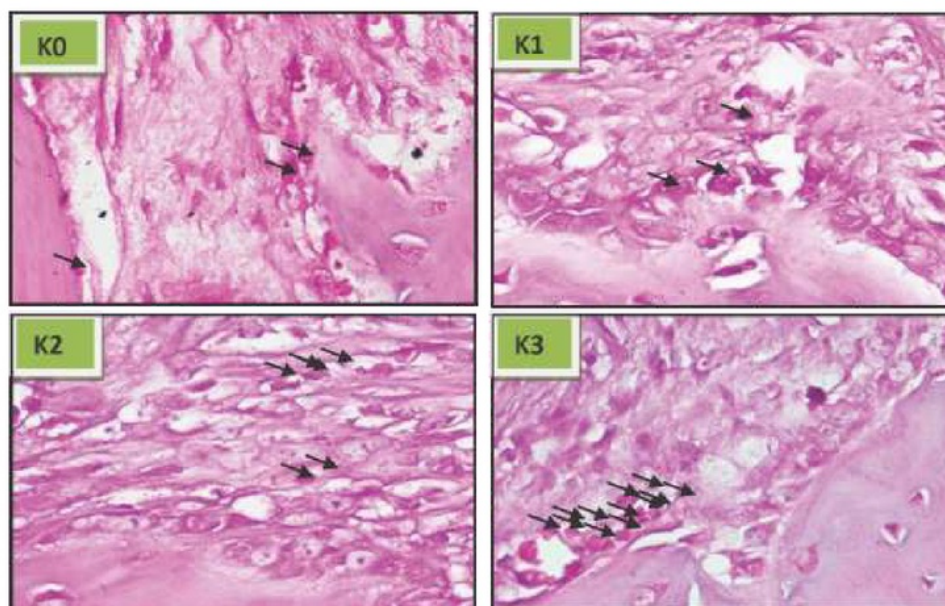


Fig. 2: Histopathology Features using HE Staining. The Number of Osteoblast in Each Group (K0, K1, K2, K3) with 1000x Magnification Using Microscope

achieved the most significant result compared to the others (Table 3). Comparison of each treatment group with the control group revealed a marked difference ($p < 0.05$). This finding paralleled the outcome of a comparison between

the K1 element within the positive control group and the K2 group ($p < 0.05$). Similarly, the last-mentioned group posted significant results ($p < 0.05$) when compared to those of its K3 counterpart (Table 4).

Table 1: Mean Number of Osteoblasts in Each Group

Group	Mean \pm SD	p Value
K0	84.83 ^a \pm 50.38	0.00
K1	254.17 ^b \pm 83.08	
K2	291.67 ^{bc} \pm 30.44	
K3	350.17 ^c \pm 33.42	

^aSignificant in value ($p < 0.05$).

Table 2: Tukey's Test Result of the Number of Osteoblast in Each Group with HE Staining Examination

Group	Comparison Group	p Value
K0	K1*	0.000
	K2*	0.000
	K3*	0.000
K1	K2	0.627
	K3*	0.026
K2	K3	0.263

^aSignificant in value ($p < 0.05$)

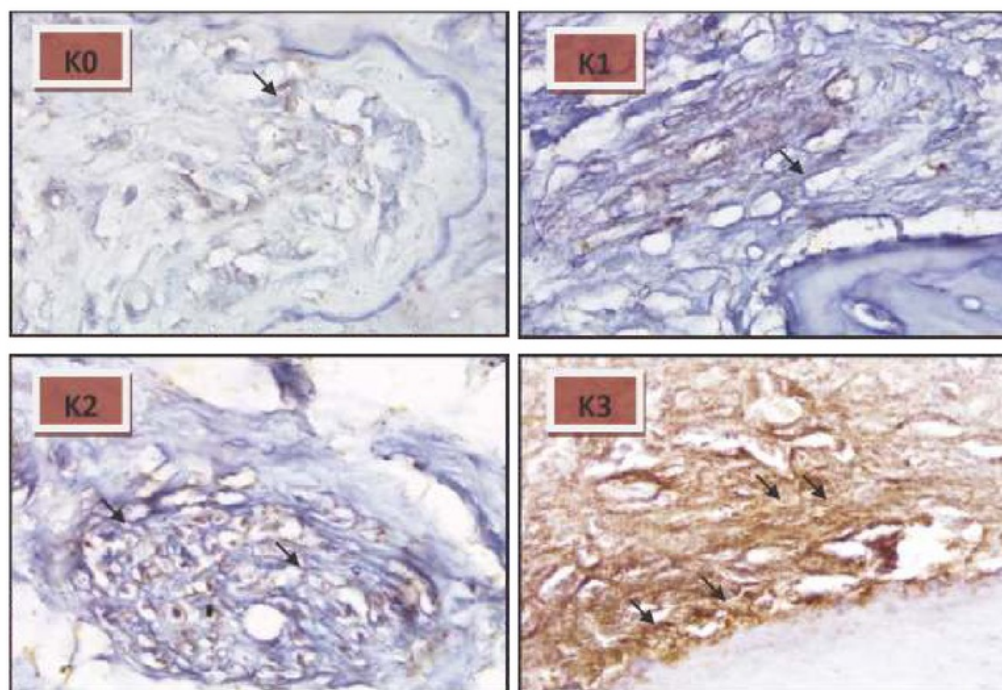


Fig. 3: OPG Expression in Each Group (K0, K1, K2, K3) with 1000x Magnification Using Microscope (IHC Staining)

Table 3: Mean OPG Expression in Each Group

Group OPG	Mean ± SD	p Value
K0	1,36 ^a ± 0,46	0.00
K1	5,03 ^b ± 0,61	
K2	8,70 ^c ± 0,73	
K3	11,36 ^d ± 0,54	

^aSignificant in value ($p < 0.05$).

Table 4: Tukey's Test Result of OPG Expression

OPG Expression	Comparison Group	p Value
K0	K1*	0.000
	K2*	0.000
	K3*	0.000
K1	K2*	0.000
	K3*	0.000
K2	K3*	0.000

^aSignificant in value ($p < 0.05$).

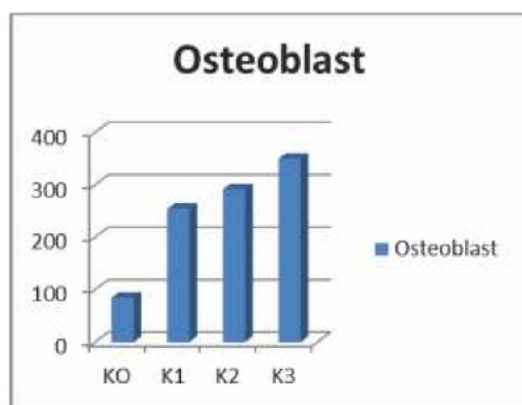


Fig. 4: Osteoblasts Mean in Each Group

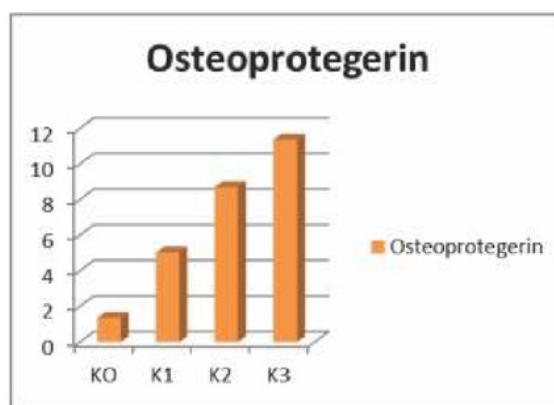


Fig. 5: Osteoprotegerin Mean in Each Group

Discussion:

Hematopoietic Stem Cells (HSCs) can differentiate into specific cells which allows them to move from bone marrow into the bloodstream. HSCs and have been the subject of extensive study with particular regard to their potential to differentiate into non-hematopoietic cells. Based on in vitro and in vivo, previous research asserted that HSCs change into blood cells when in vivo. It has also been demonstrated that an increase in smooth muscle cells, neuron cells, and bone cells in the Endothelial Progenitor Cell (EPC) occurs. The application of HSCs for the purposes of this study incorporated a characterization stage employing a CD45 monoclonal antibody observed through a fluorescent microscope [8].

IHC examination results indicated that the K3 group expressed OPG at the highest rate, producing an OPG expression characterized by stronger brown color, compared to groups K0, K1 and K2. In group K0, there was lower OPG expression than in the K1, K2, and K3 groups. The addition of HSCs produces the effect of increasing osteoblasts which, in turn, results in rapid bone regeneration. According to Calvi (2006), HSCs

possess self-renewal properties, the various lanes identified being Sonic Hedgehog, Wnt, and Notch. All of these pathways manifest the interaction of HSC surface receptors with cell-bound ligands resulting in physiological pathway activation and self-renewal occurrence [9].

Wnt proteins stimulate endurance and proliferation by working directly on hematopoietic progenitors. Pathway Signaling Notch plays a role in ligand and membrane bonding, in addition to HSC self-renewal. Jagged1 expression is detected in self-renewal murine osteoblasts and osteoblast cells during bone regeneration. Nobta *et al.*, (2005) showed that Jagged is capable of improving bone mineral deposition. The other previous studies suggested that signaling notch activation can facilitate osteoblastic cell differentiation [10].

OPG expression, according to ANOVA test results, demonstrated a notable contrast ($p < 0.05$) across all treatment groups. Meanwhile, the Tukey test revealed a significant difference in K0 as a negative control compared to the other groups. One treatment for large bone defect applies the principle of tissue engineering in the form of

graft/scaffold, growth factor and cell [11]. The PRF combined with HA graft stimulated significant bone growth and clinical level attachment gain. PRF enhances phosphorylated Extracellular Signal-Regulated Protein Kinase (p-ERK) expression and stimulates OPG production. Furthermore, it will lead to osteoblast proliferation and the stimulating of osteogenic differentiation [4].

OPG expression in the K1 group as compared to that of the K2 and K3 groups was markedly different ($p < 0.05$). This suggests that the addition of HSCs to the HA and PRF graft can accelerate tissue repair owing to the fact that the HA and PRF graft execute immune functions, for example; leukocyte chemotaxis with degranulation activation of PRF. PRF and HA graft release cytokines such as IL-1, IL-4, IL-6 and TNF- α . Consequently, the increased OPG expression and osteoblasts secretion modulated by various metabolic regulators such as IL-1, TNF α and TGF β inhibit the bone resorption process by various stimulators, for example, PTH, PGE2 and 1,25D3. A previous investigation found that OPG may inhibit the release of osteoclasts on the bone surface to compensate for such resorption [12].

The K2 and K3 groups produced significant results ($p < 0.05$) and the average OPG expression

figure in the K3 group represented the highest mean. Therefore, OPG expression in the K3 group increased compared with that of the other group. This suggests that the addition of HSCs to HA and PRF supports hematopoietic cells with regard to self-renewal and produces adult cells. The differentiation of osteoprogenitor cells, initiated through BMP and Wnt signaling molecules, binds them to osteoprogenitor cell receptor membranes. These signals will mediate the decrease of transcription factors such as Lef1 and major regulator enhancements, for instance, Runx2 / cbfa1, Osx and Dlx. These factors induce pre-osteoblastic differentiation and mediate maturation and differentiation in osteocytes [7].

Conclusion:

A combination of HA graft, PRF and HSC significantly increases the expression of OPG and the number of osteoblasts, thereby enhancing its potential for periodontal defect treatment based on tissue engineering.

Acknowledgements

The authors would like to thank the Universitas Airlangga (UNAIR), Faculty of Dental Medicine and Faculty of Veterinary Medicine.

References

1. Ministry of Health Republic of Indonesia. Health Profile in Indonesia 2014. Ministry of Health Republic of Indonesia. Sekretaris Jenderal. 2015. Jakarta.
2. Lande R, Kepel BJ, Siagian KV. Profile of Risk Factor and Complication of Tooth Extraction at RSGM PSPDG-FK Unsrat. *Jurnal E-Gigi (Eg)*. 2015; 3(2): 1-6.
3. Hamzah Z and Kartikasari Nadia. Irrational Tooth Extraction increasing structural and functional bone resorption. *Stomatognathic (J. K. G Unej)* 2015; 12 (2): 61-6.
4. Chang IC, Tsai CH, Chang YC. Platelet-rich fibrin modulates the expression of extracellular signal-regulated protein kinase and osteoprotegerin in human osteoblasts. *J Biomed Mater Res A* 2010; 95:327-32.
5. Choukroun JA, Diss A, Simonpieri. Platelet-rich fibrin (PRF): a second-generation platelet concentrate. Part IV: clinical effects on tissue healing. *Oral Surg Oral Med Oral Pathol Oral Radiol Endod* 2006; 101:56-60.
6. Albertus WW, Stephen JS. Mini Review Hematopoietic Stem Cell dan Progenitor Cell. *Stem Cell Technol* 2015: 1-10.

-
7. Aggarwal R, Vincent JP, Das H. Hematopoietic Stem Cells and Bone Regeneration. Springer Netherland. 2014; 11:189-200.
 8. Reya T. Regulation of hematopoietic stem cell self-renewal. *Recent Prog Horm Res* 2003; 58: 283-95.
 9. Calvi LM. Osteoblastic activation in the hematopoietic stem cell niche. *Ann NY Acad Sci* 2006; 1068: 477-88.
 10. Nobta M, Tsukazaki T, Shibata Y, Xin C, Moriishi T, Sakano S, Shindo H, Yamaguchi A. Critical regulation of bone morphogenetic protein-induced osteoblastic differentiation by Delta1/Jagged1-activated Notch1 signaling. *J Biol Chem* 2005; 280(16):15842-8.
 11. James NF, Giuseppe MP, Scotti C. Stem Cells for Bone Regeneration: From Cell-Based Therapies to Decellularised Engineered Extracellular Matrices. *Stem Cells Int* 2016; 2016:9352598.
 12. O'Brien EA, Williams JH, Marshall MJ. Osteoprotegerin is produced when prostaglandin synthesis is inhibited causing osteoklass to detach from the surface of mouse. *Bone* 2011; 28(2): 208-14.
-

**Author for Correspondence: Retno Indrawati Roestamadji, Department of Biology Oral, Faculty of Dental Medicine Universitas Airlangga. Jl. Mayjend. Prof. Dr. Moestopo 47 Surabaya 60132, Indonesia.
E-mail : retnoindrawati@fkg.umair.ac.id*

Osteogenic Ability of Combined Hematopoietic Stem Cell, Hydroxyapatite Graft and Platelet Rich Fibrin on Rats (*Rattus Novergicus*)

GRADEMARK REPORT

FINAL GRADE

GENERAL COMMENTS

/100

Instructor

PAGE 1

PAGE 2

PAGE 3

PAGE 4

PAGE 5

PAGE 6

PAGE 7

PAGE 8

Osteogenic Ability of Combined Hematopoietic Stem Cell, Hydroxyapatite Graft and Platelet Rich Fibrin on Rats (*Rattus Novergicus*)

ORIGINALITY REPORT

13%

SIMILARITY INDEX

10%

INTERNET SOURCES

9%

PUBLICATIONS

5%

STUDENT PAPERS

PRIMARY SOURCES

- 1 [Pliotas, C., R. Ward, E. Branigan, A. Rasmussen, G. Hagelueken, H. Huang, S. S. Black, I. R. Booth, O. Schiemann, and J. H. Naismith. "PNAS Plus: Conformational state of the MscS mechanosensitive channel in solution revealed by pulsed electron-electron double resonance \(PELDOR\) spectroscopy", Proceedings of the National Academy of Sciences, 2012.](#) 1%

Publication
- 2 [documents.irevues.inist.fr](#) 1%

Internet Source
- 3 [www.ncbi.nlm.nih.gov](#) 1%

Internet Source
- 4 [tede.pucrs.br](#) 1%

Internet Source
- 5 [repository.unair.ac.id](#) 1%

Internet Source

6	www.dovepress.com Internet Source	1%
7	grants2.nih.gov Internet Source	1%
8	mdpi.com Internet Source	1%
9	pdfs.semanticscholar.org Internet Source	1%
10	article.sciencepublishinggroup.com Internet Source	1%
11	Faramarz Naeim. "Morphology of Abnormal Bone Marrow", Hematopathology, 2008 Publication	1%
12	www.hematology.org Internet Source	<1%
13	PawLowski, L.. "Temperature distribution in plasma-sprayed coatings", Thin Solid Films, 19810710 Publication	<1%
14	www.decisiononecorporate.com Internet Source	<1%
15	www.faqs.org Internet Source	<1%
16	L. M. CALVI. "Osteoblastic Activation in the	<1%

Hematopoietic Stem Cell Niche", Annals of the New York Academy of Sciences, 04/01/2006

Publication

17

vriinvestigacion.unmsm.edu.pe

Internet Source

<1%

18

delibra.bg.polsl.pl

Internet Source

<1%

19

"13th European Congress of Clinical Microbiology and Infectious Diseases", Clinical Microbiology and Infection, 2003

Publication

<1%

20

Recent Results in Cancer Research, 2012.

Publication

<1%

Exclude quotes On

Exclude matches < 5 words

Exclude bibliography Off