

# Dental Journal

Majalah Kedokteran Gigi

Vol. 43. No. 4 December 2010

## Case Report

# Multidisciplinary management of a mandibular buccal plate perforation

Yuli Nugraeni<sup>1</sup> and Chiquita Prahasanti<sup>2</sup>

<sup>1</sup>Department of Conservative Dentistry, Dentistry Study Program, Brawijaya University, Malang - Indonesia

<sup>2</sup>Department Periodontic, Faculty of Dentistry, Airlangga University, Surabaya - Indonesia

## ABSTRACT

**Background:** Endodontists often have difficulty in the management of endo-perio cases, because they cannot visually detect the condition of outer root surfaces, especially in bucco-lateral roots. The bone defect is rare and its treatment needs collaboration of endodontists and periodontists. An endodontist treats cases based on dental history, radiograph of root canals to measure root canals, to uncover abnormalities and to diagnose, but as the endodontists cannot directly see the affected parts, the unseen portion of the tooth could only be seen after flap surgery. **Purpose:** This case presents the importance of multidisciplinary approach by the endodontist and periodontitis to treat buccal plate perforations in endo-perio cases. **Case:** The first patient, a 47-year-old female had endodontic treatment and a porcelain crown restoration; however, after several months she felt pain. The second patient, a 45 year-old female had endodontic treatment and after six months she feel painful. **Case management:** The first patient, was referred to a periodontist. The opening flap surgery has been done, a bone defect was found in tooth 45. Subsequently, the exposed crater was filled with a bone graft and the pain disappeared. The second patient, with improper endodontic treatment. The flap surgery was conducted, there was found a bone defect in tooth 36. The last treatment, a bone graft has been covered and then the pain was not present. **Conclusion:** Proper diagnosis and treatment of perforations on the buccal aspect of a root was able to eliminate pain and avoid tooth extraction.

**Key words:** Bucco-lateral defect, endo-perio lesion, management

## ABSTRAK

**Latar belakang:** Endodontis sering mengalami kesulitan dalam menangani kasus endo-perio karena secara visual kondisi ini tidak tampak diluar permukaan akar, khususnya pada akar bukolateral. Defek tulang sangatlah jarang dan perawatannya membutuhkan kolaborasi endodontis dan periodontis. Seorang endodontis merawat kasus-kasus berdasarkan riwayat gigi, radiografis saluran akar untuk melihat saluran akar, melihat abnormalitas dan diagnosis, tetapi ketika endodontis tidak dapat secara langsung melihat bagian yang terlibat, bagian gigi yang tidak terlihat ini hanya dapat dilihat setelah dilakukan bedah flap. **Tujuan:** Kasus ini menunjukkan pentingnya pendekatan multidisipliner oleh endodontis dan periodontis dalam menangani perforasi aspek bukal akar pada kasus endo-perio. **Kasus:** Pasien pertama, seorang wanita 47 tahun telah mendapatkan perawatan endodontik dan restorasi mahkota porselen, akan tetapi selama beberapa bulan pasien tersebut mengeluh nyeri. Pasien kedua, seorang wanita 45 tahun telah mendapatkan perawatan endodontik dan setelah 6 bulan juga mengeluh nyeri pada gigi tersebut. **Tatalaksana kasus:** Pasien pertama dirujuk ke periodontis. Bedah pembukaan flap dilakukan dan ditemukan defek tulang pada gigi 45, kemudian crater yang terbuka diisi graft tulang dan nyeri berangsur hilang. Pada pasien kedua ditemukan perawatan endodontik yang kurang baik. Pada pasien ini dilakukan bedah flap dan ditemukan defek tulang pada gigi 36, pada akhir perawatan graft tulang dipasang dan nyeri berangsur hilang. **Kesimpulan:** Diagnosa dan perawatan perforasi yang tepat pada aspek bukal akar dapat menghilangkan nyeri dan menghindari ekstraksi gigi.

**Kata kunci:** Defek bukolateral, lesi endo-perio, manajemen

**Correspondence:** Yuli Nugraeni, c/o: Bagian Konservasi Gigi, Program Studi Kedokteran Gigi, Universitas Brawijaya. Jl. Veteran 1 Malang. E-mail: yulinugraeni@yahoo.com.

## INTRODUCTION

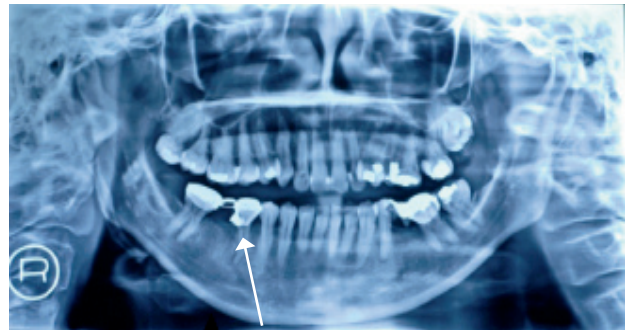
Endodontics represents a real challenge in daily practice and establishing an accurate diagnosis is the first step in successful endodontic therapy. It is well known that clinical endodontic diagnosis is based on the patient's dental history, clinical evaluation and the radiographic appearance of the inflamed tissue. The diagnosis of necrotic pulps may be difficult to establish due to signs and symptoms being inconclusive and to abnormal root positions.<sup>1</sup> Endodontists may not directly see a problem and need to take great care in patient management such as using a series of radiography to decide on optimal treatment. In many cases the diagnosis is easy to established, but there are certain cases where it becomes more complex, especially when problems co-exists with periodontal diseases.

Sometimes root perforations may occur during endodontic treatment and bring difficulties in its successful completion. If the perforation occurs below the level of the periodontal attachment, infection with loss of attachment and pocketing can spread.<sup>2</sup> In this case, the patient had been treated endodontically and a porcelain crown was fitted. The radiography showed that the apical obturation looked hermetic as well. Unfortunately, after nearly two years, the periodontal symptoms appeared and a radiography showed a lesion which had expanded along the lateral of the root. Consequently, the periodontal surgery was conducted and it was determined that there was a bone defect, a perforation on a bucco-lateral aspect.

The diagnosis of tooth with a defect which also accompanied by a periodontal lesion after the endodontic treatment is rare and may be difficult to establish for reasons of inconclusive signs and difficult location.<sup>3</sup> In this case, the perforation was localized in bucco-lateral aspect of the root, involving the alveolar bone, so called an endo-perio lesion. Therefore the poor prognosis of these infections requires an interdisciplinary approach between endodontics and periodontics specialists.

The relationship between periodontal and pulpal disease was first described by Simring and Goldberg in 1964.

Since then the term of endo-perio lesion has been used to describe lesions due to inflammatory products found in varying degrees in both the periodontium and the pulpal tissues. The simultaneous existence of pulped problems and inflammatory periodontal disease can complicate diagnosis and treatment planning. An endo-perio lesion can have a varied pathogenesis which ranges from quite simple to relatively complex.<sup>4</sup>



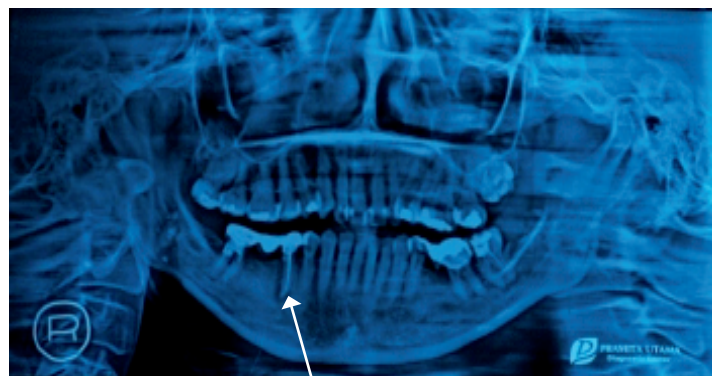**Figure 1.** Tooth 45 within crown and bridge before endodontic treatment (arrow).

This study reports a rare case of root perforation on the bucco-lateral aspect, involving the alveolar bone. The treatment of root perforation with associated periodontal defects can be challenging to the most clinician. In these cases, a multidisciplinary approach between endodontist and periodontist was performed to treat the problems.

## CASE

**Case 1:** A 47 year-old-female patient came with referred pain and bad condition on tooth 45 within crown and bridge. In examination, there was a sensitivity on palpation. The radiography showed a periapical lesion around apical of tooth 45, and the tooth was diagnosed as necrotic pulps and treated endodontically (Figure 1).

Two years later, patient reported with a chief complaint about spontaneous pain, swelling, and pus from 45. The



**Figure 2.** Tooth 45 within a new crown and bridge after endodontic treatment and showed that there was a widening lesion a year forward (arrow).

radiography showed a widening of the periodontal ligament in the lateral of root. The periodontal probing of the remaining teeth was within normal range. An endo-perio lesion associated with 45 was diagnosed (Figure 2). In spite of this, patient had asked to take some medicine for reducing the pain while preparing for periodontal surgery procedure. The treatment plan involved exploratory periapical surgery. The patient was made aware of a high possibility of a root perforation.

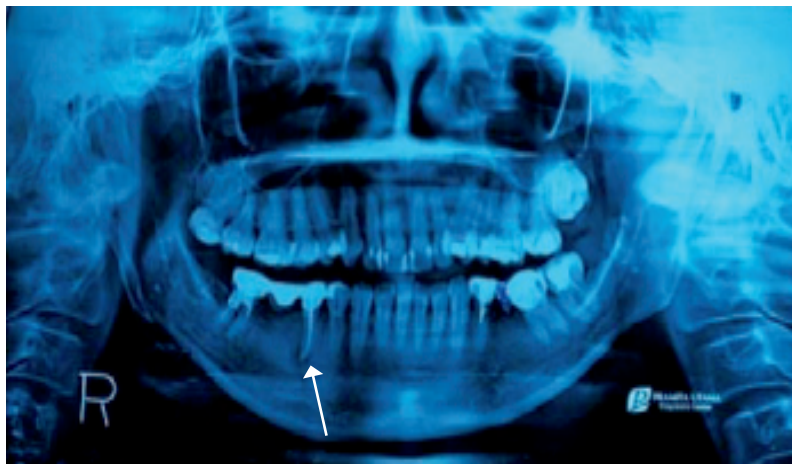**Case 2:** A 45 year-old-female patient came with persistent pain after root canal treatment and porcelain crown restoration. There was a sensitive response on palpation. However, six months later the patient felt pain and taken analgesic for relief of pain. Sometimes, this patient has a spontaneous pain, swelling and pus came through and on its buccal aspect there was a deep pocket on probing. The radiographic showed that there was a widening lesion area around furcation of tooth 36 and the apical obturation was improper (Figure 4). The tooth was diagnosed as an endo-perio lesion. Consequently the periodontist had to check with the probe, the tooth was in uncommon condition. Subsequently, the flap surgery was

planned soon and then followed by retreatment. While preparing for periodontal surgery procedure, some medicine should be prescribed for relief of pain.

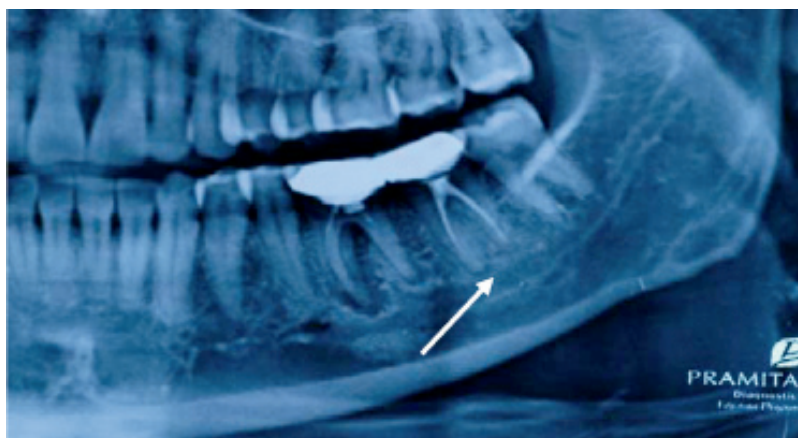#### CASE MANAGEMENT

**Case 1:** Endodontic treatment was done on tooth 45. An access cavity was prepared and the root canal system was cleaned in the first session with 5.25% sodium hypochlorite irrigation and shaped by using Protaper™. The canal was given temporary dressing with rockless and the access cavity was sealed with cavite cement. On the fourth visit there was an absence of pain or signs of inflammation therefore obturation was done with gutta-percha and a root canal sealer. Finally, a new crown and bridge was placed. A one-month recall revealed a stable mastication and there were no pain reported.

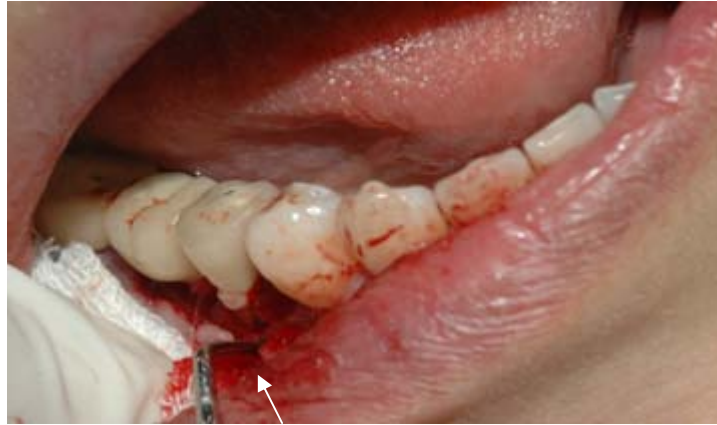However, two years later, the patient reported with chief complaint of pain, swelling, and pus discharge from the right mandibular second premolar. The tooth was previously sensitive, but there was no any pockets persisted around the



**Figure 3.** At three month later, the radiographic showed that there was alveolar bone gain (arrow).



**Figure 4.** The tooth 36 was diagnosed as an endo-perio lesion. The endodontic treatment showed improper obturation.



**Figure 5.** The opening of flap operation on a first management showed that there was a bone defect as a crater (arrow).

tooth. Based on the case and radiography, a periodontist decided to correct the problem by opening flap surgery, and the crater was filled by using bone graft substitute. One week after the surgery, the patient returned and there was asymptomatic. At three month later as showed at the figure 3, patient reported, there was no pain and the radiographic showed that there was alveolar bone gain.

**Case 2:** on the other patient, the tooth 36 was diagnosed as an endo-perio lesion that showed at figure 4. Based on the situation, patient was referred to the periodontist immediately. Periodontal surgery was done first, which included scaling and root planning and apical curettage on the tooth. While the operation has been exploring, there was a defect as a crater on the buccal plate. Consequently the inflammation area was cleaned-up and the crater was packed by bone graft substitution and some antibiotics was taken. The defect was packed with an autobone graft. A week later, the patient was recalled and reported that there was not any symptom. Then the retreatment was followed by an endodontist. After the cavity access was done, the root canal was cleaned with 5.25% sodium hypochlorite irrigation and shaped properly by using Protaper™ for several visits. As the final point, the canal was completed by apical obturation. Finally, both the endodontist and the periodontist advised the patients to take evaluation in several visits to make sure that the bone was healed properly.

## DISCUSSION

The dental pulp is closely connected with the periodontal ligament through the apical foramen, accessory canals and dentinal tubules. Due to this relationship, pulp diseases may influence periodontal health, and the periodontal infection may affect the pulp integrity. It is estimated that pulp and periodontal problems are responsible for more than 50% of tooth mortality.<sup>5</sup>

The apical dental foramen could serve as an open way of entrance for periodontal bacteria in the dental pulp, promoting situations of degenerative and necrotic nature.

Some studies had suggested that the communication between pulp and periodontal tissue can occur not only by apical dental foramen. Rubach and Mitchell<sup>6</sup> in 1965 suggested that the periodontal disease may affect pulp health when it has exposition of the accessory canals to the oral cavity, what it would allow bacteria proceeding from this region to invaded the pulp provoking a chronic inflammatory reaction followed by necrosis to the pulp.

The relationship between pulp and periodontal disease can be traced from embryological development, since the pulp and the periodontium are derived from a common mesodermal source. The pulp can be invaded from the periodontium through dentin tubules, lateral and accessory canals and the apical foramen; although evidence exists for such canals of communication, a mechanism for the direct transmission of periodontal infection into the pulpal tissues remains unclear.<sup>6</sup>

In both of cases, defect on alveolar bone area of teeth 45 and 36 could be a sign of a lateral canal accessory existence that had not been detected during root canal treatment. The origin of the endo-perio lesion was rarely unknown and establishing the original cause is not usually straightforward. Serial radiographs and the state of the pulp on first entering the root canal system can provide useful clues. The patient was diagnosed as an endo-perio lesion and treated endodontically and followed by regenerative therapy to treat the defect. In most cases of endo-perio lesions, clinical symptoms disappear following successful endodontic therapy. However, it becomes essential to correct the periodontal defect simultaneously in these cases to prevent recurrence, and to improve the functional status of the tooth.<sup>3</sup>

The majority of accessory canals are found in the apical part of the root and lateral canals in the molar furcation regions. Tubular communication between the pulp and periodontium may occur when dentinal tubules become exposed to the periodontium due to the absence of overlying cementum. These are the pathways that may provide the means by which pathological agents pass between the pulp and periodontium, thereby creating the perio-endo lesion.<sup>3</sup>

Both endodontic and periodontal diseases are caused by mixed anaerobic infections. Bacteria and their inflammatory by-products can penetrate through the pathways connecting the periodontium and the pulp. Lateral and accessory canals appear mainly in the apical area and in the furcation area of molars.<sup>4</sup> Both of these cases, bone defects were found that assumed from lateral canal accessory. It has been suggested to be direct pathways between the pulp and the periodontium which contain connective tissue and blood vessels that connect the circulatory systems of the two tissues. The presence of patent accessory canals is a potential pathway for the spread of bacteria and toxic substances from the pulp, resulting in an inflammatory process within the periodontal ligament.<sup>7</sup> Therefore, a great success of the obturation on the radicular space is necessary to eliminate leakage. The obturation prevents coronal leakage and bacterial contamination, seals the apex from the periapical tissue fluids, and seals the remaining irritants in the canal.<sup>15</sup>

The root perforations due to the existence of canal accessory are undesired complications of endodontic treatment which result in loss of integrity of the root and further destruction of the adjacent periodontal tissues.<sup>9</sup> Root perforations adversely affect the prognosis of teeth. Inadequacy of the repair materials has been a contributing factor to the poor outcome of repair procedures. Mineral trioxide aggregate (MTA) is a relatively new material that is being successfully used to repair perforations.<sup>13</sup> Several *in vitro* and *in vivo* studies have shown that MTA has good sealing ability, biocompatible, and can promote tissue regeneration when placed in contact with the dental pulp or periapical tissue.<sup>14</sup>

The closing of defects can be packed by bone graft substitute. The ideal bone graft material would be biocompatible, completely biodegradable, osteo-conductive, inexpensive, easy to handle, and able to support the defect area until bone growth is complete.<sup>8</sup> The destruction in both of the cases involve the alveolar bone which create a crater. Therefore the autogenous bone graft has been regarded as an ideal material for bone defect. On the second case, the root perforation especially in furcal area was restored with MTA, the root surface was chemically conditioned with tetracycline and the defect was filled with bone graft and then prescribed post-op medications: clindamycin 300 mg qid for 10 days, mouth rinse and mefenamic acid as needed for pain. Three months post-op clinical evaluation showed significant periapical bone fill with periodontal probing depth of 2 mm.

The prognosis and treatment of each endodontic periodontal disease type varies. Primary endodontic disease should only be treated by endodontic therapy and has a good prognosis. Primary periodontal disease should only be treated by periodontal therapy. Both of these cases, the prognosis depends on the severity of periodontal disease and patient response. Both of the patient were in good condition. Nevertheless, on the second case, open flap surgery should be done first due to the pus discharge

and deep pocket. At typical situation, the lower first molar showed a sign of periodontal disease with loss of attachment on the buccal aspect root. Commonly, in this case, the symptom was misinterpreted and the diagnosis was of localized periodontitis; consequently, the applied treatment consists of scaling and root-planning, associated with local antiseptics and irrigations with chlorhexidine was recommended. Actually, as a primary endodontic disease with secondary periodontal involvement should first be treated with endodontic therapy.<sup>10</sup>

In the present cases, as the radiography examination the healing of bone was getting healthy. However, because of the high resorption rate of the autogenous bone graft, a longer observation interval may be needed to confirm the stability of the clinical outcome, as observed after six months.<sup>11</sup>

Healing was uneventful and the three months post-op clinical evaluation showed significant periapical bone fill with no evidence of a sinus tract and labial periodontal probing depth of 2 mm. Guided tissue regeneration and guided bone regeneration can prove invaluable in endodontic-periodontal cases that may otherwise have a poor prognosis which may ultimately lead to tooth loss. Augmentation materials can assist in the regeneration of new attachment cells and bony support for previously compromised cases.<sup>12</sup> The tooth anatomy and the etiology of endodontic-periodontal lesions offer a strong base for establishing a correct diagnosis. Endodontists often misdiagnosed just because of the limitation in management, they can treat based on the history taking, the symptoms and the radiography proved, also even especially of a common sense. On the other hand, the periodontist can treat clearly by opening flap surgery. Therefore, multidisciplinary approach of endodontist and periodontist is mandatory in especially endo-perio lesion cases. Moreover, due to the complexity of these affections, an interdisciplinary approach with a good collaboration between endodontists, periodontologists and microbiologists, is recommended.<sup>6</sup>

Furthermore, the endodontists is responsible for the improvement of their knowledge through the management. However, essential collaboration between endodontists and periodontists to correct the periodontal defect simultaneously in these cases was aimed to prevent the recurrence, and to improve the functional status of the tooth.

In conclusion, an endo-perio lesion consequent, retreatment or collaboration with periodontist should be done to prevent further tooth extraction. The proper diagnosis and treatment of root perforation involving bone defect was able to eliminate pain symptoms, thus preventing from tooth extraction.

## REFERENCES

1. Koyees E, Fares M. Referred pain: A confusing case of differential diagnosis between two teeth presenting with endo-perio problems. Case report. *Int Endodon J* 2006; 39: 1-2.

2. Shuman IE. Repair of a root perforation with a resin-ionomer using an intentional replantation technique. *General Dentistry* July–August 1999; 47(4): 21–5.
3. Singh S. Management of an endo-perio lesion in a maxillary canine using platelet-rich plasma concentrate and an alloplastic bone substitute. *Case report*. 2009; 13(2): 97–100.
4. Nadir B. The pathogenesis and treatment of endo-perio lesions. The Preliminary Program for IADR Saudi Arabian Section Meeting January, 2006; p. 28–31.
5. Didilescu A, Iliescu R, Rusu D, Iliescu AA, Ogolescu A, Ogolescu E, Stratul S. Current concepts on the relationship between pulpal and periodontal disease. *TMJ* 2008; 58(1): 99–103.
6. Silva MF, Piva, Reinheimer, Dejean. **Spread of odontogenic infection originating from endo-periodontal-case report**: Available at: [saqmartins@hotmail.com/www.actiradentes.com.br/.../19RevistaATO-Spread\\_of\\_odontogenic\\_infection-2009.pdf](mailto:saqmartins@hotmail.com/www.actiradentes.com.br/.../19RevistaATO-Spread_of_odontogenic_infection-2009.pdf). Accessed January 16, 2009.
7. Trombelli L, Annunziata M, Belardo S, Farina R, Scabbia A, Guida L. Autogenous bone graft in conjunction with enamel matrix derivative in the treatment of deep periodontal intra-osseous defects: a report of 13 consecutively treated patients. *J Clin Periodontol* 2006; 33: 69–75.
8. White Jr C. Combined therapy of mineral trioxide aggregate and guided tissue regeneration in the treatment of external root resorption and an associated osseous defect. *J of Periodontol* 2002; 73(12): 1517–21.
9. Agrawal PK. Combined periodontal endodontic lesion. Sr. Prof and Head Dept. Of Periodontia Govt. Dental College, Jaipur. Available at: [www.gdcaaj.comwww.gdcaaj.com/articles%20pdf/pkagrawal.pdf/2006](http://www.gdcaaj.comwww.gdcaaj.com/articles%20pdf/pkagrawal.pdf/2006). Accessed December 17, 2006.
10. Yildirim G, Dalci KK. Treatment of lateral root perforation with mineral trioxide aggregate: a case report. *Oral Surgery, Oral Medicine, Oral Pathology, Oral Radiology, and Endodontology*, 2006. 102(5): e55–e58.
11. Mamidwar SS, Ricci JL, Alexander H. Bone regeneration with calcium-sulfate-based bone grafts. *Inside Dentistry* 2006; 2: 1–8.
12. Gold A. Guided tissue regeneration (GTR) can promote or guide the proliferation of periodontal ligament cells and attachments onto denuded root surfaces. *J Indian Soc Periodontol* 2009 Oct; 13: 97–100.
13. Main C, Mirzayan N, Shabahang S, Torabinejad M. Repair of root perforations using mineral trioxide aggregate: A long-term study. *J of Endod* 2001; 30(2): 80–3.
14. Chong. *Harty's endodontics in clinical practice*. 6<sup>th</sup> ed. Elsevier; 2010. p. 146.