



THE AGA KHAN UNIVERSITY

eCommons@AKU

Department of Radiology

Medical College, Pakistan

April 2006

Sentinel lymph node scintigraphy and radioguided dissection in breast carcinoma: an initial experience at Aga Khan University Hospital

Maseeh Uz Zaman

Aga Khan University, maseeh.uzzaman@aku.edu

Shaista Khan

Aga Khan University, shaista.khan@aku.edu

Riffat Hussain

Aga Khan University, riffat.hussain@aku.edu

M Nadeem Ahmed

Follow this and additional works at: https://ecommons.aku.edu/pakistan_fhs_mc_radiol



Part of the [Radiology Commons](#)

Recommended Citation

Zaman, M. U., Khan, S., Hussain, R., Ahmed, M. N. (2006). Sentinel lymph node scintigraphy and radioguided dissection in breast carcinoma: an initial experience at Aga Khan University Hospital. *Journal of Pakistan Medical Association*, 56(4), 153-156.

Available at: https://ecommons.aku.edu/pakistan_fhs_mc_radiol/259

Sentinel Lymph Node Scintigraphy and Radioguided Dissection in Breast Carcinoma: An initial experience at Aga Khan University Hospital

Maseeh uz Zaman¹, Shaista Khan¹, Riffat Hussain², M. Nadeem Ahmed²

Dept. of Surgery¹, Dept. of Radiology², Aga Khan University Hospital, Karachi.

Abstract

Objective: To evaluate the efficacy of SLN biopsy using imaging and gamma probe in breast cancer and to establish this technique at Aga Khan University Hospital.

Methods: Thirty two patients (mean age 33-76 yrs) with operable breast carcinoma (4 with post-neo adjuvant therapy) with clinically negative axilla were studied. In 28 patients simultaneous axillary dissection was performed. Sentinel lymph nodes (SLN) scintigraphy was performed a day before surgery by injecting Tc-99m labeled nanocolloid sub-dermally in the peri-areolar region in 24 and peri-tumoral in remaining 8. First lymph node (LN) to appear to on the scan was labeled as SLN and marked on the skin. Blue dye was also injected in all patients and blue and hot LN was explored in the axilla using gamma probe.

Results: The sentinel LN was identified in 31 patients (96.9% success rate) while in one patient (3.1%) SLN was not visualized on the scan (negative study) and this was a post-neo-adjuvant therapy case. The blue dye successfully localized the sentinel LNs in all 32 cases. The gamma probe guided localization was successful in all 31 while in one case with post-neo-adjuvant chemotherapy it failed. In 9 out of 32 (28.1%) cases SLN was positive for metastasis and in 6 out of these 9 (66.6%) the SLN was the only metastatic node. This includes the post-neo-adjuvant case as well. There was no case of skip metastasis, i.e. negative SNL and positive other axillary nodes. In remaining 23 (71.9%) cases SLN was negative for metastasis and in all, axilla was free of disease (NPV of 100%).

Conclusion: Lymphoscintigraphy with gamma probe guided SNL biopsy is safe, simple and highly reliable technique. With blue dye technique it reduces the blindness of the procedure if performed independently but increases the cost. Finally, this can accurately stage the axilla, possibly allowing axillary dissection to be foregone in patients where the SLN is clear (JPMA 56:153;2006).

Introduction

Axillary dissection has been an essential component of the surgical treatment of infiltrating breast carcinoma for a century. The development of imaging and screening examinations detect small and early stage primary cancers. In recent years it has been increasingly noted that axillary dissection finds only healthy lymph nodes.¹ Nevertheless it is mandatory to stage the axilla for obtaining as much prognostic information as possible.

The question, therefore arises, whether lymph node removal is always necessary in patients with a clinically negative axilla. The ideal solution would be to diagnose lymph node involvement through non-invasive techniques which seem unrealistic at present.² A promising alternative appears to be the identification, removal and pathological examination of the first lymph node that first receives lymph from the area of breast harbouring the tumor. This

lymph node is called sentinel lymph node (SLN). The assumption is that if SLN is negative, all other axillary lymph nodes will be negative. The technique of SLN biopsy was first used by Morton et al^{3,4} in melanoma with encouraging results. In last few years this technique has been extensively used in breast cancers with quite promising results and in many centers in the developed countries it has become an essential part of the breast cancer management. It involves the peri-tumoral or sub dermal injection of radiolabelled colloid followed by lymphoscintigraphy, and a gamma ray detecting probe can be used to locate the skin projection of SLN and assist biopsy.

The purpose of this study was: a) to establish the lymphoscintigraphy technique in association with gamma probe for SLN removal and biopsy in breast cancer at Aga Khan University Hospital, Karachi; b) to compare this technique with blue dye injection in the same patient; and c)

technique with blue dye injection in the same patient; and c) compare SLN status with the definitive histologic result of all axillary lymph nodes after complete axillary dissection.

Patients and Methods

We studied 32 patients with operable breast cancers diagnosed by physical examination, mammogram and fine needle aspiration with clinically negative axillary metastasis (4 with post neo-adjuvant chemotherapy). Exclusion criteria included lactation, pregnancy, previous excisional biopsy of breast and clinically palpable axillary lymph nodes. The average age of the patients was 52 years (range 33-76 years). Tumour size was less than 4.5 cm and 16 were in the right while remaining 16 in the left breast (14 upper outer, 12 upper inner, 3 lower outer, 1 lower inner and 2 in the central quadrants). In 28 patients simultaneous axillary dissection was performed with either quadrantectomy or modified radical mastectomy. In remaining 4 patients axillary LN dissection was not done as these patients opted for a secondary procedure, if SLN biopsy was positive (SLN were negative for metastasis in all of them).

The day before surgery, 37 MBq (1 mCi) of Tc-99m Nannocolloid (Nannocol, Amersham) in 2 cc of saline were injected in 4 aliquots of 0.5 ml sub-dermally in the peri-areolar region in 24 patients and peri-tumoral in remaining 8 patients. Planar scans of the involved breast and axillary region, in anterior and anterior oblique projections, were obtained at 10 minutes, 1 hour and 18 hours after the radio-colloid injection. After acquisition of 1 hour image, skin projection of the first visualized node (defined as the sentinel LN) was marked with a pen while the patient was supine with arm extended laterally at 90° to the body. To mark the body contour a rectangular Co-57 flood phantom source was placed posteriorly.

Radioactivity was detected by the gamma ray probe (Gamma Sonic®) (Figure 1) transduced into digital readout and acoustic signals. The intensity and frequency of the acoustic signals were directly proportional to the level of radioactivity. The probe was used in the imaging room and theater pre-operatively to confirmation of the skin projection of the SLN seen on the scintiscan.

After the primary tumor had been removed, the gamma probe (in a sterile glove) was used to precisely locate the skin projection of the node emitting the greatest radioactivity, using the skin mark as a guide. The skin was incised directly over this point and using the gamma probe to guide dissection. The node emitting the highest activity was placed in the container labeled as sentinel lymph node. This was followed by complete axillary dissection in 28 patients. In 4 patients simultaneous axillary dissection was not performed as these patients decided to defer it till

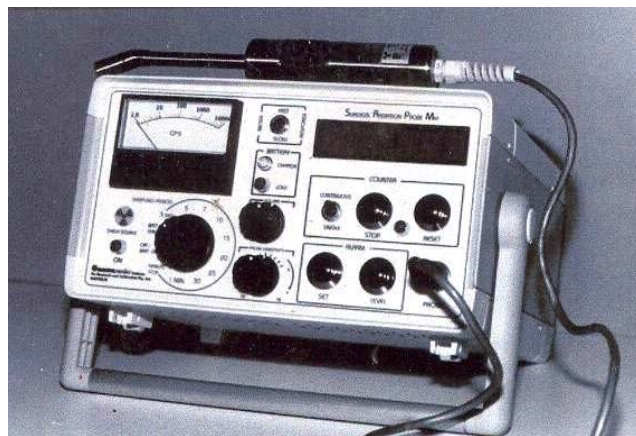

Figure 1. Gamma ray detecting probe.

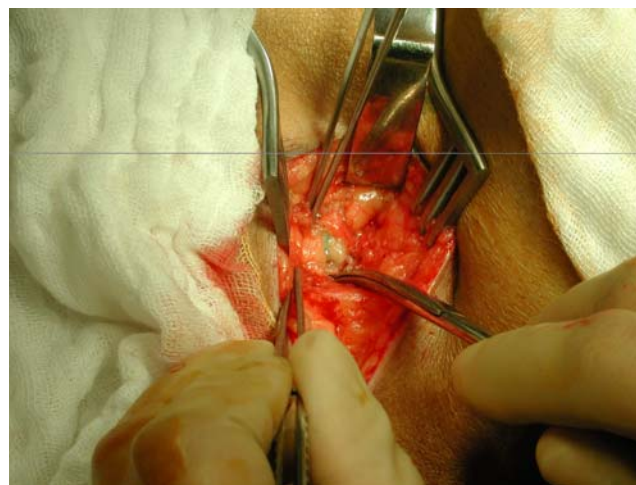


Figure 2. Sentinel lymph node containing blue dye explored per-operatively.

histopathology report was available. All removed material was checked in operating room for radioactivity before sending it for pathologic examination.

In all patients, 3 ml of blue dye was injected into the tumor bed immediately after the excision of the primary nodes using 25 gauge needle. The lymph tract revealed by the dye was dissected until the blue axillary node was located (Figure 2).

All nodes removed from the axilla (tagged SLN and from the levels of axilla) were studied using standard protocol and stained with eosin and haematoxylin.

Data is represented as mean \pm standard deviation. Statistical analysis were performed using ANOVA and Chi Square test were appropriate.

Results

The sentinel LN was identified in 31 patients (96.9% success rate) while in one patient (3.1%) SLN was not visualized on the scan (negative study) and this was a post-neo-adjuvant therapy case. In all these positive cases SLN

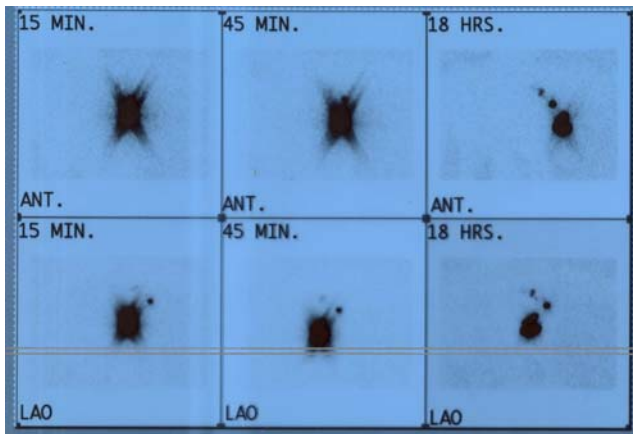


Figure 3. Sentinel lymph node scintigraphy performed with nanocolloid showing sentinel lymph node (black arrow) and secondary lymph node (white arrow).

were localized in the ipsilateral axillas. In 20 (64.5%) cases only one SLN was visualized while in 5 (16.1%) cases two and in remaining 6 (19.4%) patients three foci were seen on the scan. When lymphoscintigraphy revealed more than one node, the first node to become active always showed the highest uptake in the early and delayed images and was regarded as the sentinel LN (Figure 3).

Blue disc localization successfully localized the sentinel LNs in all 32 cases (including post-neo-adjuvant case with no tracer uptake in the axilla on the scan).

Gamma probe guided localization and removal of SLN was successful in all 31 in whom tracer uptake by axillary LN was observed by lymphoscintigraphy. In one case with post-neo-adjuvant chemotherapy no LN was detected with gamma probe, however, SNL was visible with blue dye per-operatively.

In 9 out of 32 (28.1%) cases sentinel lymph node was positive for metastasis and in 6 out of these 9 (66.6%) the sentinel LN was the only metastatic node. This includes the post-neo-adjuvant case as well. There was no case of skip metastasis, i.e. negative SNL and positive other axillary nodes (false negative rate was 0%). In remaining 23 (71.9%) cases, SLN was negative for metastasis and in all, axilla was free of disease (negative predictive value of 100%).

Discussion

Axillary lymph node dissection is an established and essential component in breast cancer staging, however, it is associated with unpleasant side effects like cost, surgical morbidity and lymphoedema. To circumvent these problems, the technique of sentinel lymph node scintigraphy and radio-guided biopsy of the sentinel LN has been introduced. Sentinel node biopsy is increasingly being used in clinically lymph node negative, early stage breast cancers.⁵ In many developed countries like USA and Europe, this has

become an essential part of the breast cancer management.

In our study, sentinel LN was successfully localized with lymphoscintigraphy in 31 patients and failed in one case with post-neo-adjuvant chemotherapy. The reason for this false negative result could be heavily embedded node with metastasis resulting in gross disruption of the lymphatic channels. However, this node was visible with blue dye per-operatively and revealed metastasis on histological examination. Therefore, this most likely represents a technique failure resulting from large size of nanocolloid particles (due to clumping) which failed to enter into lymphatic channels.

In this study blue dye successfully localized SLN in all cases (100%) as compared with lymphoscintigraphy which failed to localize in one case. However, in this procedure axilla is dissected blindly until the blue node, which may be several centimeters below the incision, is seen. In our study this procedure was not blind as the SLN was marked on the skin during scanning and also reconfirmed by the gamma probe pre-operatively. Furthermore, it is suggested that 30-50 dissections are required to reach the full competence.⁴ These limitations certainly outweigh the marginally high success rate of blue dye technique in this study.

In this study, gamma probe guided biopsy successfully identified SLN which is comparable with most of the published studies.^{2,6} The concordance between SLN and axillary LN status was 100%, a false negative rate of 0% and negative predictive value of 100%. These numbers are relatively higher than the published data and not statistically significant due to small sample size.

Two decades ago, the treatment of breast cancer was transformed by the demonstration that conservative surgery is as effective as mastectomy.¹ Today we seem to be on the threshold of a development that may allow axillary dissection to be foregone in a large percentage of patients. Our data indicate that SLN biopsy can reliably predict the state of the axilla, so that when this node is healthy, axillary dissection can be safely avoided. This is important since the removal of axillary lymph nodes deprives the patient of lymphatic tissue, which, if healthy, should be retained. Axillary dissection may have other sequelae, such as reduced arm motility, reduced skin sensitivity, pain, lymphoedema and increased susceptibility to infections.^{7,8}

We conclude that lymphoscintigraphy with gamma probe guided SLN biopsy is a safe, simple and highly reliable technique. When combined with blue dye technique it reduces the blindness of the procedure if performed independently but increases the cost. Finally, this can accurately stage the axilla, possibly allowing axillary

dissection to be foregone in patients where the SLN is clear.

References

1. Veronesi U, Salvadori B, Luini A, Greco M, Saccozzi R, del Vecchio M, et al. Breast conservation is a safe method in patients with small cancer of the breast. Long-term results of three randomised trials on 1,973 patients. *Eur J Cancer* 1995;31A:1574-9.
 2. Joseph E, Brobeil A, Glass F, Glass J, Messina J, DeConti R, et al. Results of complete lymph node dissection in 83 melanoma patients with positive sentinel nodes. *Ann Surg Oncol* 1998;5:119-25.
 3. Morton D, Wen D, Cochran A. Management of early stage melanoma by intra-operative lymphatic mapping and selective lymphadenectomy: an alternative to routine elective lymphadenectomy or "watch and wait". *Surg Oncol Clin North Am* 1992;1:247-59.
 4. Morton DL, Wen DR, Wong JH, Economou JS, Cagle LA, Storm FK, et al. Technical details of intraoperative lymphatic mapping for early stage melanoma. *Arch Surg* 1992;127:392-9.
 5. Singh Ranger G, Mokbel K. The evolving role of sentinel lymph node biopsy for breast cancer. *Eu J Surg Oncol* 2003; 29:423-5.
 6. De Cicco C, Paganelli G, Cremonesi M, Galimberti V, Bartolomei M, Viale G, et al. Gamma-probe guided resection of the sentinel node in breast cancer. *Eur J Nucl Med* 1997;24:892.
 7. Lin PP, Allison DC, Wainstock J, Miller KD, Dooley WC, Friedman N, et al. Impact of axillary lymph node dissection on the therapy of breast cancer patients. *J Clin Oncol* 1993;11:1536-44.
 8. Reynolds JV, Mercer P, McDermott EW, Cross S, Stokes M, Murphy D, et al. Audit of complete axillary dissection in early breast cancer. *Eur J Cancer* 1994;30A:148-9.
-