

Pacific University

CommonKnowledge

College of Optometry

Theses, Dissertations and Capstone Projects

12-17-2004

Retinal thickness analyzer: An online instruction manual

Jonathan Berry
Pacific University

Recommended Citation

Berry, Jonathan, "Retinal thickness analyzer: An online instruction manual" (2004). *College of Optometry*. 1467.

<https://commons.pacificu.edu/opt/1467>

This Thesis is brought to you for free and open access by the Theses, Dissertations and Capstone Projects at CommonKnowledge. It has been accepted for inclusion in College of Optometry by an authorized administrator of CommonKnowledge. For more information, please contact CommonKnowledge@pacificu.edu.

Retinal thickness analyzer: An online instruction manual

Abstract

Optometry has recently started using powerful computer driven diagnostic tools. The Talia Retinal Thickness Analyzer (RTA) is such a machine. This online instruction manual was created to give students easy access to information regarding the use of the RTA and interpretation of RTA reports. It provides information about the different uses of the RTA, in-depth instructions on how to perform a scan, examples of scan reports with a focus on their clinical use, and includes an abbreviated instruction guide for quick reference. The manual will offer a convenient way for student and faculty RTA users to learn about this technology. The online format will allow access to the instruction manual from school, clinic, home, or preceptorship sites.

Degree Type

Thesis

Degree Name

Master of Science in Vision Science

Committee Chair

Denise Goodwin

Subject Categories

Optometry

Copyright and terms of use

If you have downloaded this document directly from the web or from CommonKnowledge, see the "Rights" section on the previous page for the terms of use.

If you have received this document through an interlibrary loan/document delivery service, the following terms of use apply:

Copyright in this work is held by the author(s). You may download or print any portion of this document for personal use only, or for any use that is allowed by fair use (Title 17, §107 U.S.C.). Except for personal or fair use, you or your borrowing library may not reproduce, remix, republish, post, transmit, or distribute this document, or any portion thereof, without the permission of the copyright owner. [Note: If this document is licensed under a Creative Commons license (see "Rights" on the previous page) which allows broader usage rights, your use is governed by the terms of that license.]

Inquiries regarding further use of these materials should be addressed to: CommonKnowledge Rights, Pacific University Library, 2043 College Way, Forest Grove, OR 97116, (503) 352-7209. Email inquiries may be directed to: copyright@pacificu.edu

Retinal Thickness Analyzer: An Online Instruction Manual

By


Jonathan Berry

A thesis submitted **to the faculty of the**
College of Optometry
Pacific University
Forest Grove, Oregon
For the **degree of**
Doctor of Optometry
December 17, 2004

Advisor:
Denise Goodwin, O.D.


Retinal Thickness **Analyzer**: An Online Instruction Manual

Author



Jonathan Berry

Advisor



Denise Goodwin, O.D.

Date: December 17, 2004

Jonathan Berry

Jonathan Berry is from Albany, Oregon. He graduated from the University of Oregon in Eugene, Oregon with a Bachelor of Arts in English Literature. He is currently a fourth year intern at Pacific University College of Optometry. After graduation he will return to Albany, Oregon where he will join a group practice.

Abstract

Optometry has recently started using **powerful** computer driven diagnostic tools. The **Talia** Retinal Thickness Analyzer (**RTA**) is such a machine. This online instruction manual was created to give students easy access to information regarding the use of the RTA and interpretation of RTA reports. It provides information about the different uses of the RTA, in-depth instructions on how to perform a scan, examples of scan reports with a focus on their clinical use, and includes **an** abbreviated instruction guide for quick reference. The manual will offer a convenient way for student and faculty RTA users to learn about this technology. The online format will **allow** access to the instruction **manual** from school, clinic, home, or **preceptorship** sites.

Retinal Thickness Analyzer: An Online Instruction Manual

Introduction:

Computer driven diagnostic tools are becoming commonplace in optometry. The Talia Retinal Thickness Analyzer (RTA) is a powerful tool to aid the optometrist in the diagnosis and monitoring of various ocular pathologies. In order to make the most of this equipment students and faculty must have convenient access to information regarding the technical use of the RTA and interpretation of its reports. This online instruction manual provides a clear and readily available format for students and faculty to learn about the RTA. It will be specifically used in the Ophthalmic Imaging course (Optometry 757).

Discussion:

This project involved creating an instruction manual that made ample use of graphics so that the reader could become familiar with the layout of the RTA and its use. The manual was first created in Microsoft Word. This created a challenge when I attempted to place the manual on WebCT. It was necessary to change the Word document to a hypertext markup language (HTML) in order for it to be available on WebCT. I first tried using Netscape Composer to convert the Word document to HTML but was unsuccessful. I then recreated the document in Macromedia's Dreamweaver and was able to upload it to WebCT. I now realize it would have been much easier and more efficient to originally write the manual using a program that saves documents in a HTML format.

The final manual is approximately 24 pages and includes numerous graphics that appear exactly as they do on the RTA (see Appendix A). The manual begins with a brief introduction regarding the different uses of the RTA and how it works. It then gives detailed instructions on how to perform a scan. Finally, the manual concludes with examples of actual reports and clinically practical interpretations. Also included is an abridged version of the manual for easy reference (see Appendix B).

The manual is published as a **website** at the following address:
http://webct.pacificu.edu:8900/SCRIPT/OPT757/scripts/serve_home

Conclusion

It is imperative that students have the opportunity to learn about and use new technologies in optometry. This online instruction manual will provide a convenient avenue for students and faculty to learn to use the RTA in a clinically relevant manner.

Appendix A

Retinal Thickness Analyzer (RTA)



Uses of the RTA

Glaucoma- The RTA can be used to measure the nerve fiber layer and assist in the diagnosis of glaucoma. It is advertised as the only imaging device to assess all three of the following areas: macula, peripapillary region, and the disc. The thickness of the NFL can be viewed as a 2-D or 3-D color coded map. The measured thickness can then be compared to normative data. The RTA also measures the disc area, cup area, and calculates a C/D area ratio and compares this information in each of six quadrants to a normative data base.

Age Related Macular Degeneration- The RTA can be utilized to monitor changes in retinal thickness at the macula and also at the juncture of the retina and choroid.

Diabetic Retinopathy- The RTA is helpful in diagnosing macular edema associated with diabetic retinopathy.

Fundus Photography - The RTA provides a wide angle image capturing a 70 degree X 60 degree area of the retina. The image can then be viewed as a red-free photo or a color photo. A scale borders the photo providing the actual size in microns

Other uses- A few other conditions which the RTA can assist in diagnosis of are:

- Macular cyst
- Cystoid macular edema
- Macular holes

How does it Work?


A thin HeNe laser is projected at an angle onto the retina. The scattered and reflected light is detected and recorded by a camera. The scattered light is then analyzed to identify the chorioretinal interface and the vitreoretinal interface. The distance between these two junctures is equal to the thickness of the retina. From there the thickness can be color coded and presented as a topographical map, graph and/or compared to normative data. If this explanation doesn't satisfy your curiosity then please refer to the following reference: Asrani S, Zou S, d'Anna S, Vitale S, Zeimer R. Noninvasive mapping of the normal retinal thickness at the posterior pole. *Ophthalmology*. 1999 Feb; 106(2); 269-273. PMID: 9951475

Entering Patient Data

1. Turn on the computer, monitor, and printer. You will be asked for a password.

DO NOT ENTER A PASSWORD. SIMPLY CLICK OK.

2. The RTA desktop will appear.



3. Scanning icon: Click here if you want to perform a scan on a new patient or do an additional scan on a patient who has previously had a RTA scan.

4. Review icon: Click here if you ONLY want to examine a previous scan.

5. After clicking on either icon you will see the patient registration screen:

Patients/Sessions	Name/Type	Details
NORMAL	Patient Demo	
IRREGULAR DECENTRATION	Patient Demo	
IRREGULAR HOLES	Patient Demo	
IRREGULAR	Patient Demo	POAG suspect (ID: 4)
IRREGULAR	Patient Demo	
IRREGULAR	Patient Demo	
IRREGULAR	Patient Demo	
IRREGULAR	Patient Demo	
IRREGULAR	Patient Demo	
IRREGULAR	Patient Demo	
IRREGULAR	Patient Demo	
IRREGULAR	Patient Demo	

5. If you are doing a scan for the first time on a patient, enter the following information: Name, Date of Birth, Gender, Ethnic Origin and ID. The diagnosis or potential diagnosis can be entered in the Patient's Details field.

ID NUMBER IS THE ACCOUNT # ON THE PATIENT'S ROUTE SLIP. IF YOU DON'T KNOW WHAT IT IS, 4SK AT THE FRONT DESK. IT IS MANDATORY THAT YOU ENTER THE ID # FOR EVERY SCAN PERFORMED.

Enter Corneal Radius (CR) values if the patient's keratometry readings are below 41.00 D or above 45.00 D. Enter the corneal radius in millimeters. If the keratometry readings are between 41.00 D and 45.00 D, ignore this field.

7. If you are adding a scan to a patient already in the database then you need to select the patient's file from the 'Patients/Sessions' list. It is possible to search by entering any portion of the following: ID, first name, last name, or patient details.

For example, typing the first name "Molly" will bring up a list of all patients with the first name Molly. The correct "Molly" can then be selected from the list. If you can't remember a patient's name but you know they were diagnosed with primary open angle glaucoma. You can enter "primary open angle glaucoma" into the "Patient's Details" field, and all the patients diagnosed with primary open angle glaucoma will appear.

8. After entering the patient information, click on "New Patient" if there are no previous scans or click on "New Session" if you are adding a scan to a previously scanned patient.

If you have clicked the Review Icon on the desktop and would like to view a previous scan then click "Load Session" after selecting the desired patient file.

HINTS:

2. If you are searching for a previously scanned patient then any information in the ID field will reset all other information.

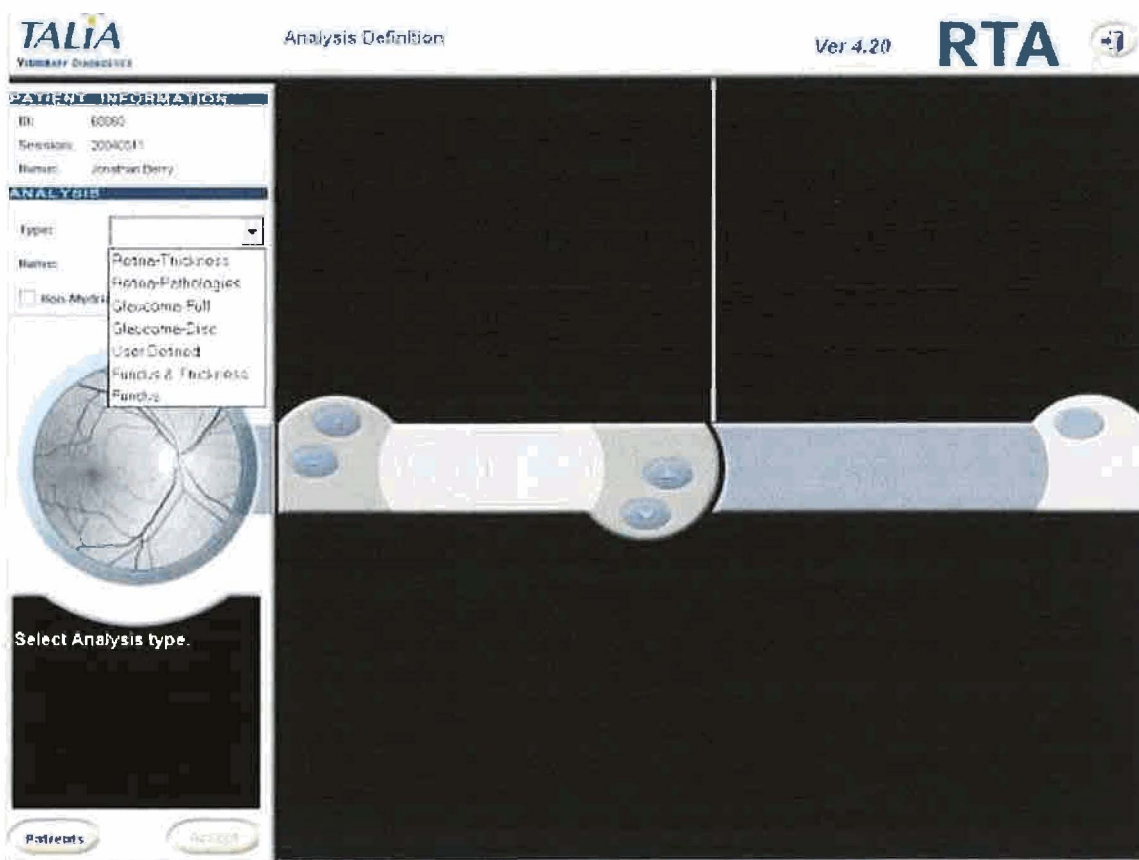
3. If you have entered an ID # and want to return to the complete list of patients in the database then you must delete the ID #.

3. A space in any of the fields is registered and searched for and will usually cause the entire patient list to disappear. For example, if a patient's ID is "1230" and you type

' 1230" the correct patient will not be found.

Acquiring the RTA scan

1. After the Patient Registration screen is complete and either "New Patient" or "New Session" has been clicked then the screen below will appear.



2. Select a type of scan from the drop down menu.

There is a choice of seven different scans.

1) Retina-Thickness: five scans of the posterior pole with the option of an additional six scans of the peripapillary area.

2) Retina-Pathologies: five scans of the posterior pole and six scans of the peripapillary area. This scan doesn't provide my normative comparison or topographical map. Therefore, this scan is rarely used.

1) Glaucoma-Full: thirteen scans of the posterior pole, peripapillary area and the disc.

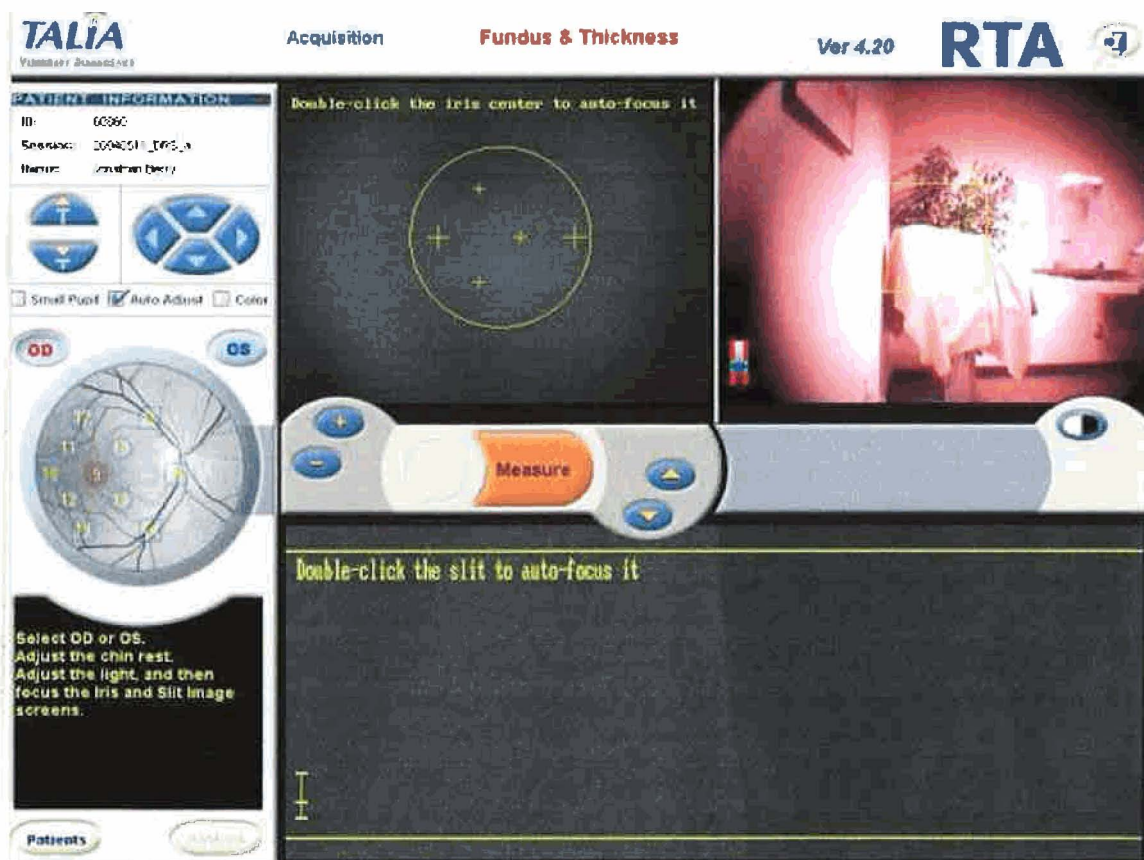
4) Glaucoma-Disc: four scans of the disc. This is the only scan that can be done on an undilated patient. **CLICK ON THE "NON-MYDRIATIC" BUTTON IF YOU PLAN TO DO THIS SCAN UNDILATED.**

5) Fundus & Thickness: five scans of the posterior pole and six surrounding images. Scans 11 degrees surrounding the oeva and provides normative comparisons.

5) Fundus: scans posterior pole and surrounding areas. Eleven scans in total. This scan provides a fundus montage.

7) User Defined: five scans of the posterior pole and six of the peripapillary area with the option to manually select an area outside of the normal scanning area.

3. After a scan type has been selected click "Accept". Now the Acquisition screen will appear.



Numbers appear overlaid on a fundus image on the left side of the screen. These numbers indicate the area of the retina where the scans will occur. The scans are represented by either a colored circle or square. A circle means the scan will include both thickness measurements and a fundus photo. A square tells you that only a fundus image will be taken

The different colors represent the following scans:

Blue bordered circle or square: this area has yet to be scanned.

Solid blue circle or square: this area has been scanned and can be re-scanned if desired.

Red bordered circle or square: this area is currently being scanned.

Solid red circle or square: this area has been scanned and is currently being displayed.

TIP:

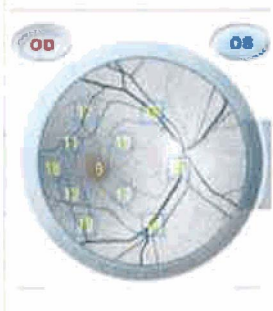At any time you want to return to the Patient Registration screen click "Patients" at the bottom left of the screen. You will be asked if you want to ignore the empty session, click Yes and the Patient Registration screen will reappear.

4. Position the patient so that they are comfortable, their forehead is touching the head-rest and their lateral canthus is lined up with the mark on the head-rest. The chin rest can be adjusted using the following icon in the upper left of the screen.



The entire RTA unit can be adjusted up and down for patient comfort by pushing the up and down buttons under the keyboard.


5. Click on the eye that you want to scan.




The RTA will move to the selected eye. You can now make small position adjustments to center the eye using the arrow icons in the upper left of the screen—just to the right of the chin rest adjustment.



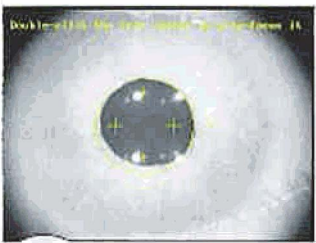
5. Instruct the patient to watch the center of the doughnut shaped target. This target will move with each scan and the patient needs to follow it. It may be helpful to show the patient the fixation card (pictured below) so they know what to expect. Also, remind the patient not to watch the green line that is moving during the scan.



The fixation target for a non-mydriatic, Glaucoma-Disk scan is different. It has a green target on a black background.

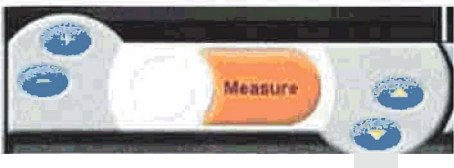

7. After the patient's pupil is in view, single-click on the center of the pupil to bring it to the middle of the yellow circle. The four yellow "+" signs must be within the pupil. These "+" signs represent the entrance and exit points of the laser beam and the camera light.



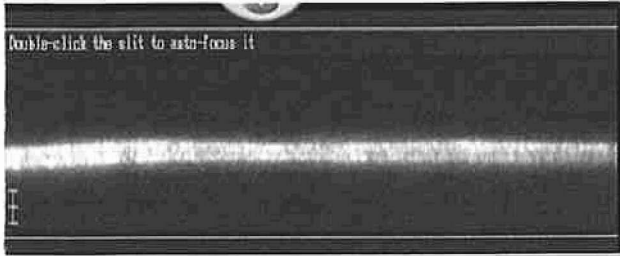
HINT: If the patient has a non-uniform media opacity or irregular corneal topography it may help to move the yellow circle to different areas of the pupil to allow the laser beams to enter and exit through clear media and uniform optics.

3. Now focus the iris image as well as possible by clicking on the "+" and "-" buttons shown below. You can also double click in the center of the pupil to auto-focus the iris.



Next, select the **Small Pupil** box.

9. Adjust the slit image (the horizontal white line in the lower portion of the screen) so that it is midway between the two yellow lines. This is done by either clicking and dragging the slit image to the center or by using the up and down arrow buttons (shown above). Double click on the slit image to auto-focus it if necessary. **THE SLIT IMAGE ISN'T VISIBLE IN THE NON-MYDRIATIC SCAN.**



10. Remind the patient to look at the target. Check to see that the iris image is centered and focused and the slit image is centered. Finally, click the orange "Measure" button to scan the retina.

The RTA provides you with quality control. After a scan, a green check, yellow question mark, or red "X" will appear below the fundus image. A green check indicates an adequate scan. A yellow question mark indicates a scan of questionable quality and a red "X" means the scan is of poor quality. The RTA will also give you feedback messages in the lower left of the screen. If necessary click on the "Rescan" button to the left of the "Measure/Next Scan" button to repeat the scan.

If the patient has a media opacity such as a cataract, this will affect the quality of the scan. In these cases the best scan possible may be one with a yellow question mark.

11. When you are satisfied with a scan then hit "Next Scan". Obtain the remainder of the scans by assuring that the pupil is centered, the iris is in focus, and the retinal slit is centered. Then click "Measure". Continue until all scans are complete and then click "Analysis".

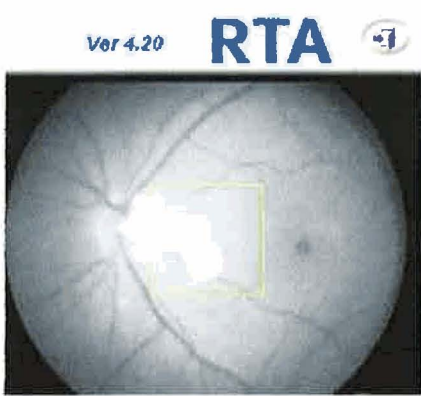
HINTS

4. You can return to the Patient Registration screen by clicking the "Patients" button. The session will be saved even if it is unfinished. From the Patient Registration screen you can return to scanning by clicking the "Back" button.

B. The RTA will go to sleep if there is a period of inactivity. To wake it up click the "Live" button.

Variations for Particular Scans

Disc Scan (Mydriatic)



If you are doing either a Glaucoma-Disc or Glaucoma-Full scan then follow the directions above but pay special attention to the quality of the fundus image because it is used as the basis for the subsequent scans. After you have captured the first scan adequately, click and drag the yellow square so that the disc is centered in it. Then click "Next Scan". Continue scanning, making sure that the disc is inside the yellow square before each scan.

HINT: When scanning the disc the slit image will be distorted and not be as sharp as it is when scanning the retina.

Disc Scan (Non-Mydriatic)

Choose "Glaucoma-Disc" from the drop down menu on the Analysis Definition screen and click the "Non-mydriatic" box. Center yellow circle inside the pupil as described above. Focus the iris and slit image as previously described and click "Measure". After acquiring the first scan drag the yellow box so that the disc is centered in it and click "Next Scan". Continue scanning, making sure that the disc is inside the yellow square before each scan.

HINTS:

4. The initial fundus image needs to be of high quality. If it is not then click the "Pupil" button to see if the pupil was aligned properly while the image was being captured. If the alignment was off then rescan. If the alignment was correct but you still got a poor image then click the "Adjust" button.

3. If the yellow square frame is dragged beyond its range you will hear a beep.

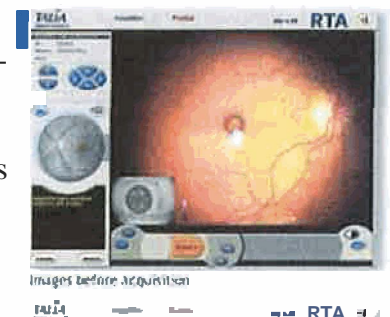2. In the first scan the quality of the fundus image is more important than the quality of the slit images. In scans 2-4 the slit image quality is more important than the fundus image.

Digital Fundus Image

If you choose "Fundus and Thickness" at the Analysis Definition screen then there is a combination of regular scans and fundus photos with the latter lacking the laser slit cross-sections. At the start of scan 14 the screen appears as to the right.

Starting with scan 14 it is only necessary to focus the iris before clicking "Measure". This can be done either by using the plus/minus buttons or by double-clicking the iris image.

While performing scan 19 the patient will see the black circle until you click measure. At



At this point the circle will move out of the view of the patient. Before scan 19 the RTA will remind you that the target will move. Instruct the patient not to follow the target but stay fixated in the original spot.

User-Defined Scan

Click the “U” button under the fundus map to set a user-defined area. This sets the area as the center of the scan. Scan number 9 is mandatory in this analysis type. After the scan is completed a box appears allowing you to enter written details about the particular scan.

Error Messages

Scan areas 1, 2, and 9 are used as references for all other scans. If the quality is poor for one of these scans the RTA will let you know with an error message. Also, if you select an area manually it may tell you to first scan one of these areas so it can be used as a reference point.

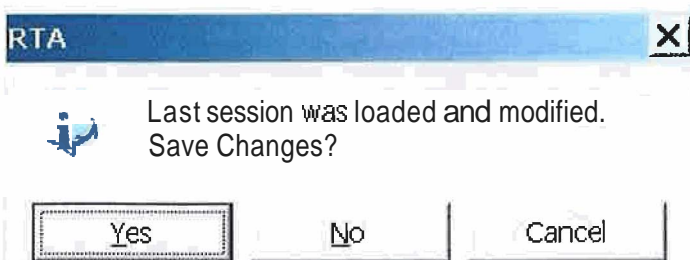
Shutting Down the RTA

Close all sessions and click the Exit button. 

All scans are automatically saved when you close the session. You do not need to click on a button to save the scans.

Click OK to close RTA and shut down windows.

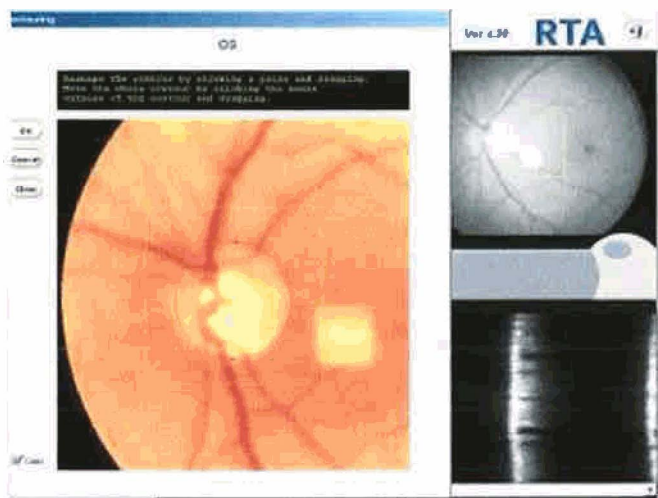
Note: If you go back to review a previous scan the following dialog box will appear when you try to exit the session. You will be asked to save changes. ALWAYS ANSWER NO.



Retinal Thickness Analyzer Reports

After a scan is completed, click the Analysis button (found in the bottom left corner of the Acquisition screen). A Talia mascot appears while the report is being formed.

A Contouring window will appear if you did a Glaucoma-Full scan or a Glaucoma-Disk scan.



Drawing the contour line:

Place the cursor at the edge of the disc and click. Next, click on the opposite side of the disc. This forms a circle. You can add points to the circle to match the edge of the disc.

You can adjust the size and shape of the contour line by clicking on a previously added point. The circle will turn red. Now you can drag any point to a different location to better match the disk contour.

When you are satisfied that the contour lines match the edge of the disk, click "OK" to begin analysis.

The "Cancel" button will delete any changes made to the contour line, and it will revert to the previously defined contour. "Clear" will delete the contour. "Color" will give you a color image of the disc.

HINTS:

4. When trying to contour the disc pay attention to the following:

color

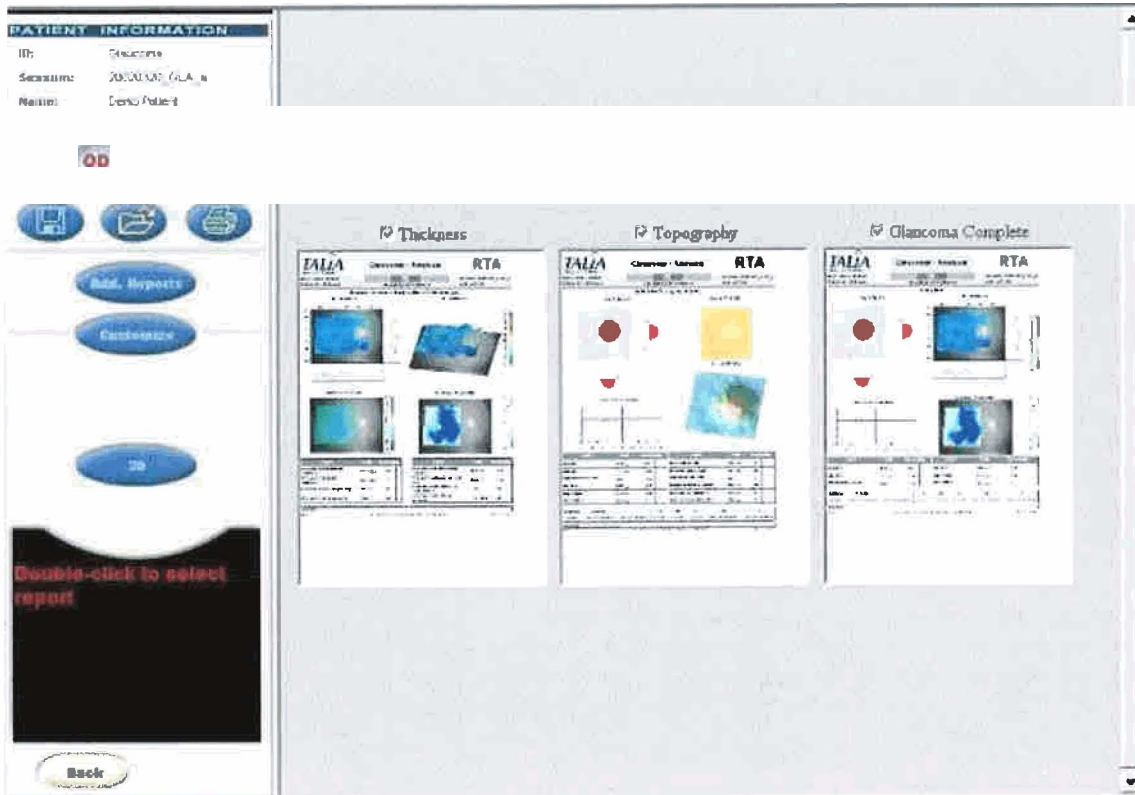
deflection of vessels

place the contour line at the inner edge of the scleral crescent

don't include peripapillary atrophy in the contour

.Viewing and Analyzing Reports

After the analysis is complete a screen appears showing the reports that have been generated.



'Save' button stores all reports as an HTML file. You do not need to click on this in order to save the information. The reports will save automatically.

'Open' button goes back to the Patients Registration screen.


'Print' button prints all selected reports.

After the reports have been generated it is possible to view a 3-D image of the disc as shown below. Click on the "3D" button.

Left click to rotate the image.

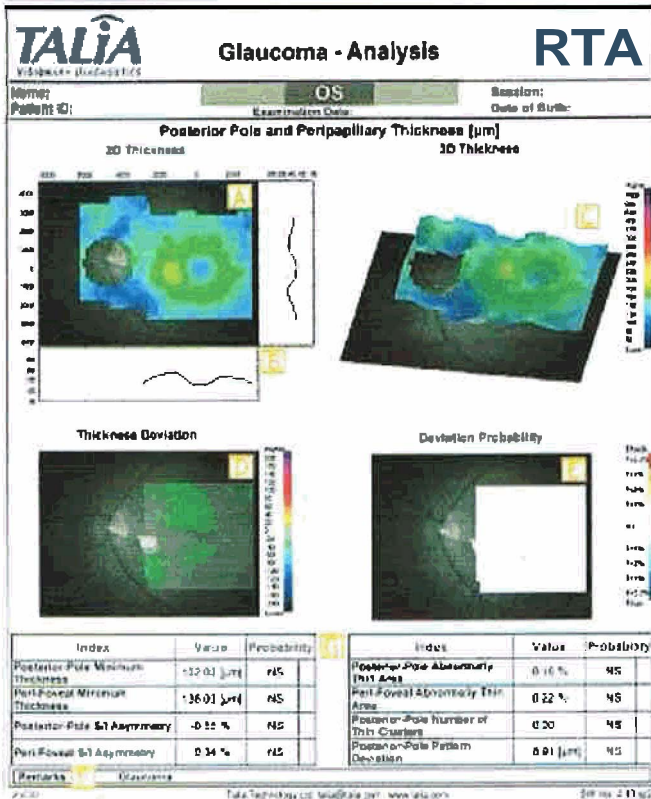
Pressing the "shift" key while left clicking allows you to pan image.

Pressing the "Ctrl" key while left clicking allows you to zoom in and out.



Report Interpretation

GLAUCOMA ANALYSIS



Posterior Pole and Peripapillary Thickness Report

The Posterior Pole and Peripapillary Thickness Report includes:

• **2D Thickness Map:** a color coded thickness map with actual thickness in microns surrounding the map (marked A above).

• **Graphs:** show the average thickness of a swath through the fovea. The thick gray line is the normal range. The thin black line is the patient's thickness (marked B above).

• **3D Thickness Map:** a color coded 3D thickness map (marked C above).

• **Thickness Deviation Map:** a color coded map that shows how the thickness of the scan compares to other age-matched people in Talia's database (marked D above).

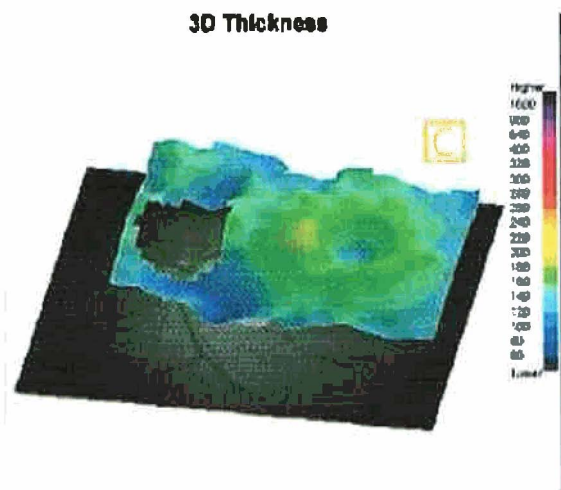
• **Deviation Probability Map:** a color coded map that shows the probability that someone in that age range would have

the same retinal thickness (marked E above).

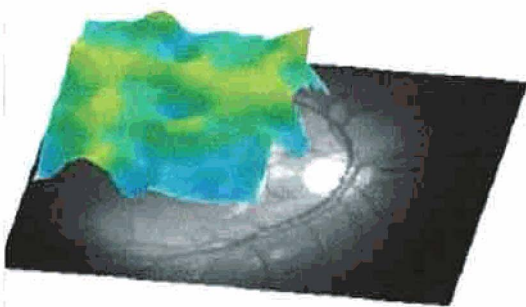
The gray area in the two deviation maps indicate areas that are within a 95% confidence interval of normals. Blue and green colors indicate retinal **thinning**. Red and yellow colors indicate retinal thickening. As with the pattern deviation on a Humphrey visual field report there may be one or two isolated abnormal points but this isn't always indicative of glaucoma.

The table at the bottom of the report (marked G above) contains indices formulated from Talia's database. A "+" sign indicates the probability is greater than in normals and a "-" sign lower than in normals. "NS" stands for **non-significant** and means that it is within the normal range of the database. It is important to note that the indices provided in the Retina Analysis demonstrate thickening of the retina while indices in the Glaucoma Analysis demonstrate thinning.

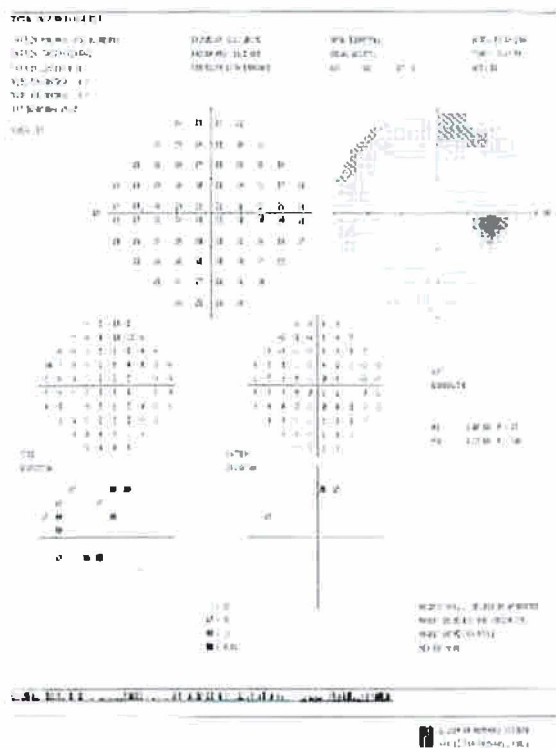
When analyzing the report one of the more useful tools is the 3D Map (marked C above). A normal fovea will appear as a volcano or horseshoe shape as shown below.




Look for thinning of the "volcano/horseshoe" rim. This indicates an increased risk of glaucoma. Thinner areas will appear more blue. The map below shows thinning of the inferior edge of the patient's right eye.



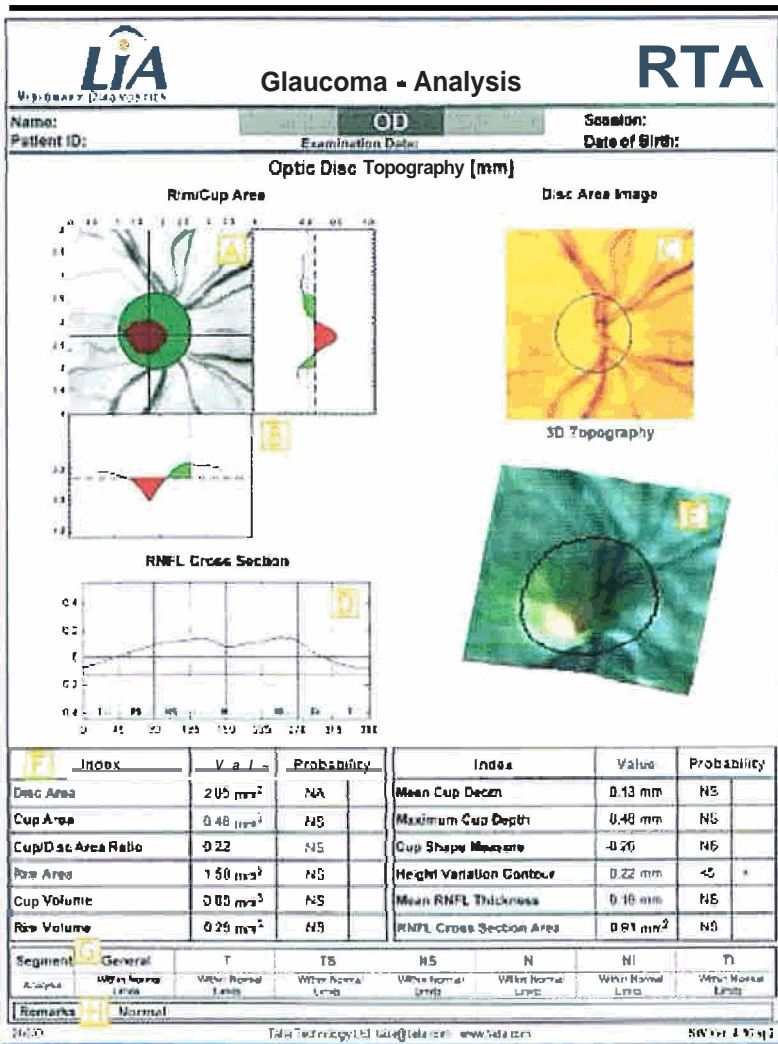
The existence of this thinning is supported by the following Humphrey 30-2 Visual Field report which shows superior defects corresponding to inferior nerve loss.



Below is another example of a patient showing glaucomatous nerve fiber layer thinning. Again, notice the thinning of the rim of the "volcano" which appears blue on the 3D map on the left. To the right is the corresponding deviation probability map. This map gives the deviation from Talia's normative database in p values. The dark blue areas on the map below have a p value of $p < 0.5\%$. In other words, there is less than a .5% chance that a patient with this amount of thinning is normal. Therefore, it is very likely that a disease process is causing the thinning.



Optic Disc Topography Report

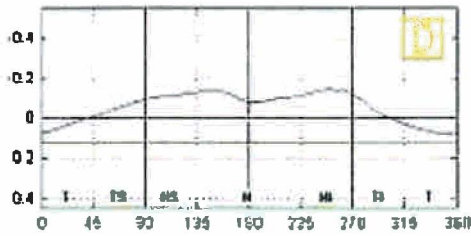


The report includes:

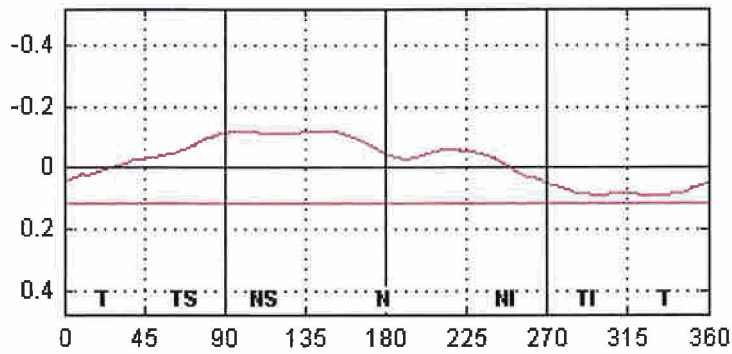
- Rim/Cup Area Map (marked A above): 2D map of rim and cup. The red represents the cup and the green the rim. Surrounded by the actual size in microns.
- Graphs (marked B above): cross-section graphs
- Disc Area Image (marked C above): fundus image of disc area with the defined contour line
- RNFL Cross-sections (marked D above): RNFL thickness along the defined contour line
- 3D Disc Topography Map (marked E above): color-coded, 3D map of the disc
- Table of Indices (marked F above)
- Segment Analysis (marked G above): six segments of rim area are compared to normative values and are reported as "Within Normal Limits", "Borderline", or "Outside Normal Limits".

When examining the Optic Disc Topography report, one of the more useful pieces of information is the RNFL Cross Section. A normal disc will have two "humps" with a slight depression between them as shown below. The two high points correspond to superior and inferior retinal nerve fiber layer.

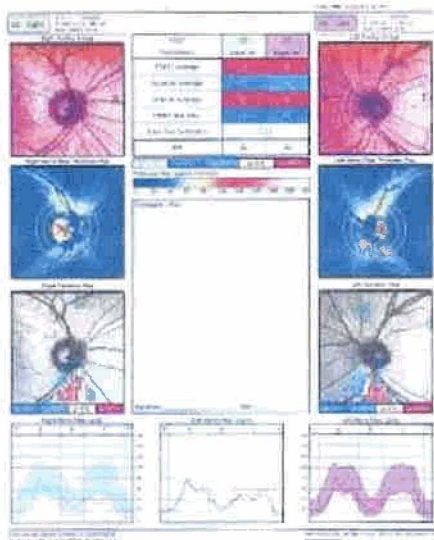
RNFL Cross Section




The patient discussed previously as having a thinning of the inferior area around the fovea also demonstrates a thinning in the RNFL Cross Section.



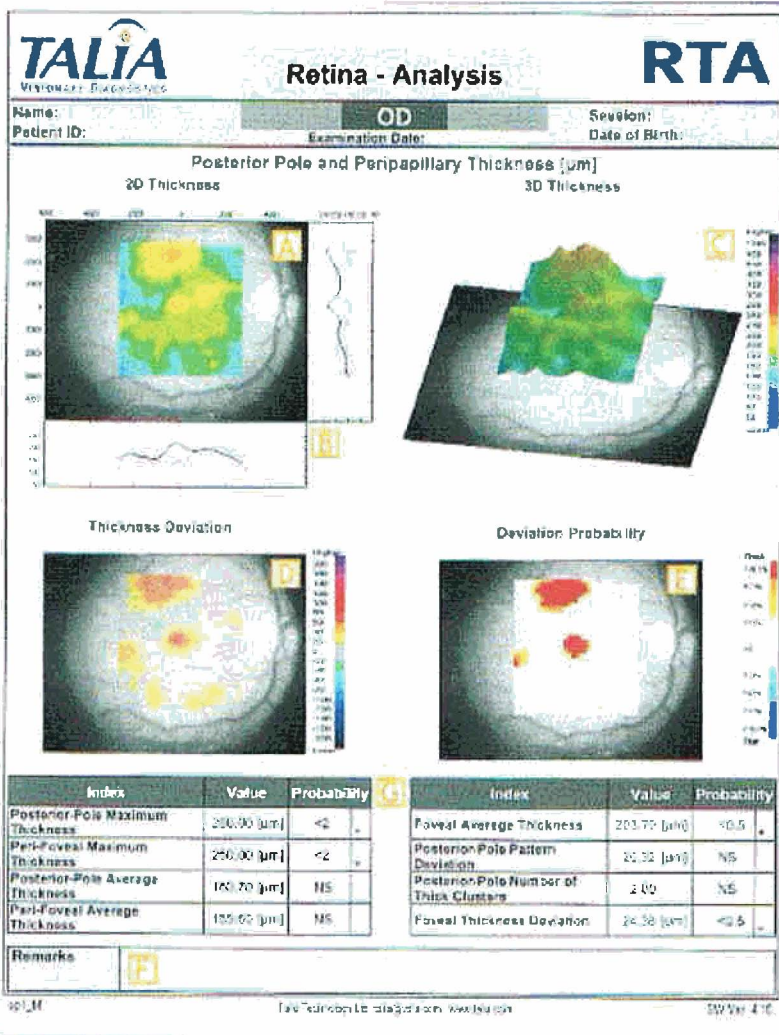
A GDX report for the same patient shows a very similar thinning of the inferior RNFL.





If a patient is scanned more than once using the same analysis then a follow up report can be generated. This allows for easy comparison over time and is one of the RTA's nicer features. There is a 2D thickness map for each scan (marked B above) and a 2D deviation map (marked C above) shown for every scan after the first. Each subsequent scan is compared to the baseline scan. A follow-up report can also be created using Optic Disc Topography reports.

RETINA ANALYSIS

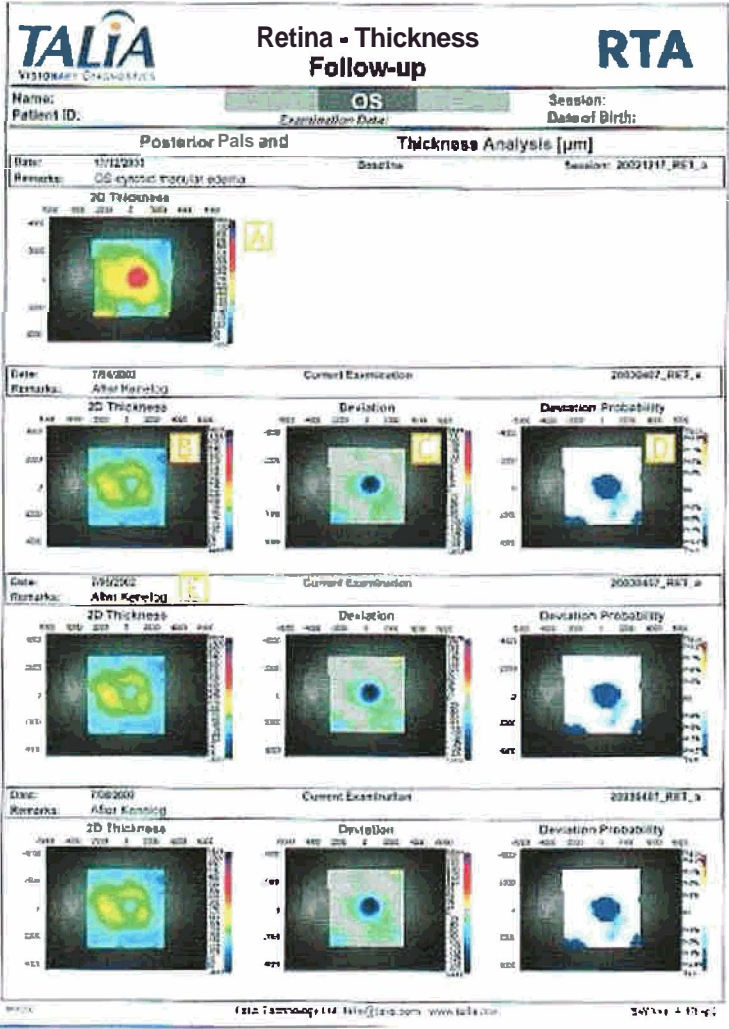


The Posterior Pole and Peripapillary Thickness report in retinal analysis offers the same maps and indices as in the glaucoma analysis except there is no reading of the optic disc. Here again, the 3D map is assessed to see if it is a smooth volcano or horseshoe shape. In the example above the volcano shape is not present, and the thickened areas are shown in yellow and red.

Maps and Visual Effects

It is possible to add visual effects to an individual map by double-clicking the map of interest. The map will enlarge and you will see an "Effects" button. Of the options available the Intensity slider bar is one of the more useful. This allows the user to look at a color coded map and then slide the intensity bar down so that it is possible to see what is under abnormal colors on the map. Only maps in the Posterior Pole and Peripapillary thickness reports can have effects added.

Retina Thickness Follow-Up Report



This feature is identical to the Glaucoma Follow-up Report. In the example above the first scan shows a patient with cystoid macular edema where the edematous area is colored red. After a kenolog injection additional scans were taken and show a decrease in thickening compared to the baseline.

Fundus and Thickness Report

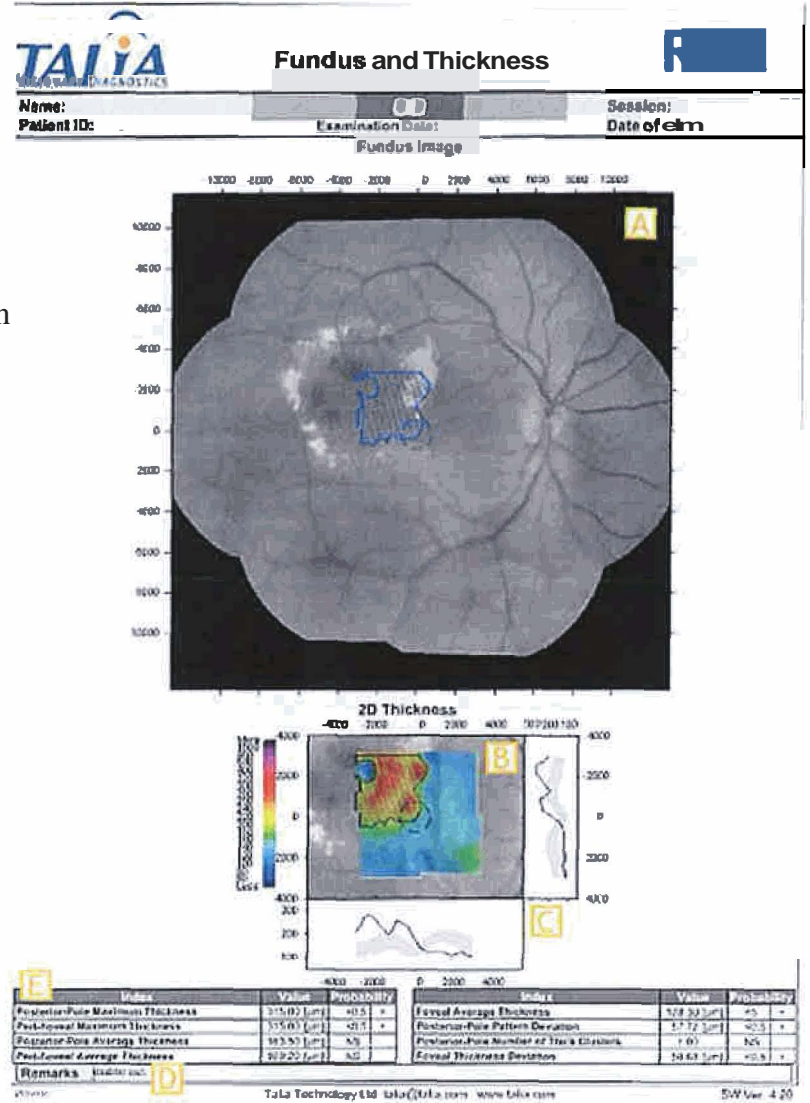
The Fundus and Thickness report includes:

2D Thickness Map: color-coded, 2D thickness map of the Posterior Pole

Graphs: show the average thickness of a swath through the fovea. The thick gray line is normal range and the thin black line is the patient.

Fundus Image: colored, wide-angle image of all the fundus images scanned

- Areas greater than 1.6 standard deviations above the normal are outlined on the fundus image.



Fundus Image Report

A full page color, wide-angle fundus image which is a montage of all the areas scanned.

Name:

OD

Session:

Patient ID:

Examination Date:

Date of Birth:

16

-10000 -8000 -6000 -4000 -2000 0 2000 4000 6000 8000 10000

10000

-8000

-6000

-4000

-2000

0

2000

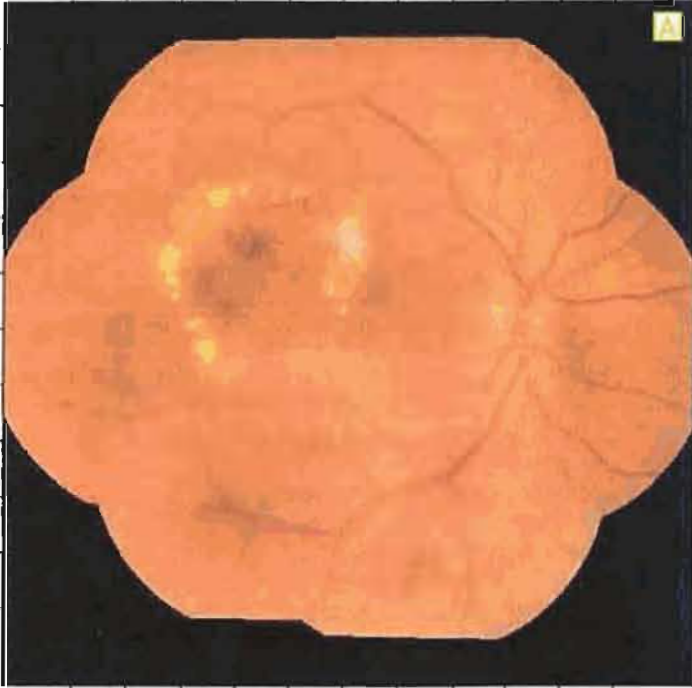
4000

6000

8000

10000

16



Appendix B

RTA Quick Guide

- . Turn on RTA computer and monitor.
- . When prompted for a password click "OK". Do not enter a password.
- . Click "Scanning" on desktop. "Review" only allows you to look at previous scans.
- . Type in patient information and click "New Patient". If you are doing a scan on a previous patient then click on their name and click "New Session".
- . Click on the pull down menu under "Analysis Type". Choose the type of scan you want from the following seven choices:

-Retina-Thickness

-Retina-Pathologies

-Glaucoma-Full

-Glaucoma-Disc: This is the only scan possible if the patient is undilated. You must also click on "Non-Mydriatic" if the patient is undilated.

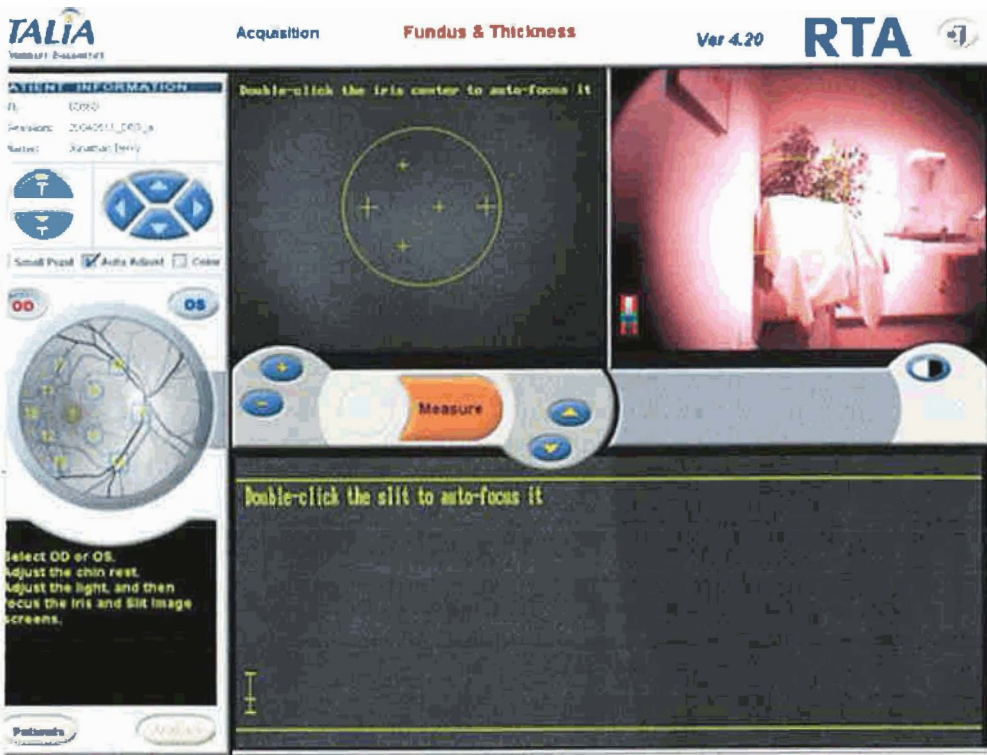
-User Defined

-Fundus and Thickness

-Fundus

5. After choosing a scan type click "Accept".

7. Click OD or OS.



9. Use the controls below the keyboard to move the height of the machine so that the patient is comfortable. Then align the patient's canthus with the canthal mark using the following icons:



10. Instruct the patient to look at the black circle. It will move and the patient must follow the target. If you are doing a non-mydriatic scan the target will be a green circle.

10. Center the yellow circle inside of the pupil using the four blue arrows.

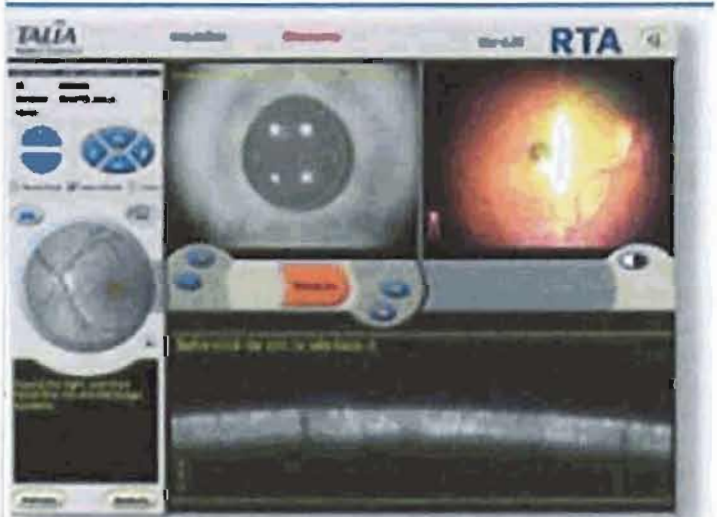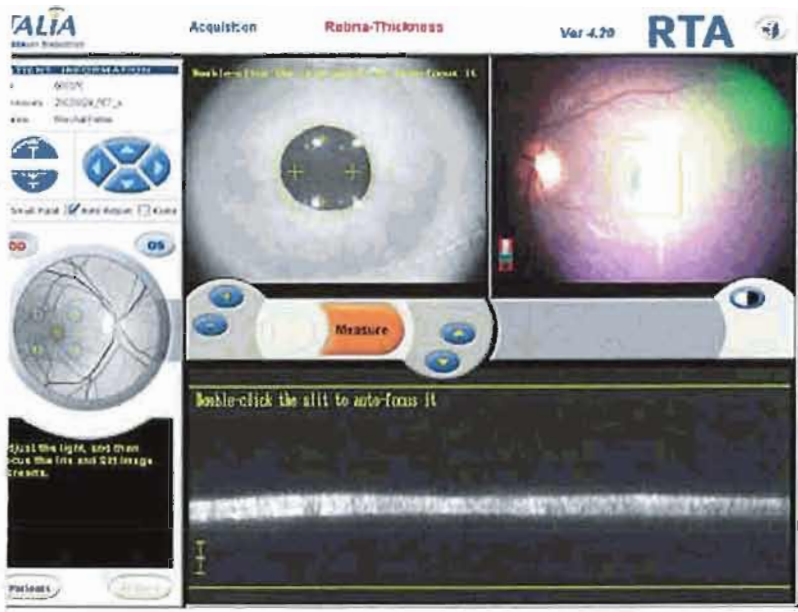


You can also center the pupil by single-clicking in the middle of the pupil.

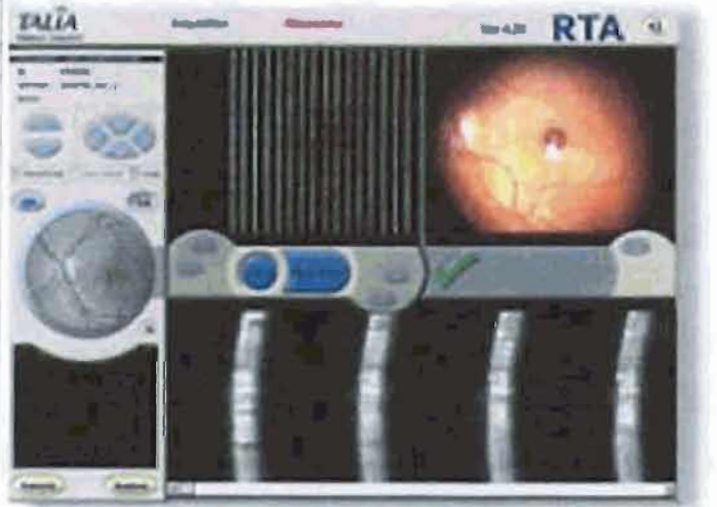
11. Focus the iris using the yellow and blue "+" and "-" buttons. It is also possible to focus the iris by double-clicking in the center of the pupil.



12. Center the slit image in the lower right of the screen by clicking and dragging it.



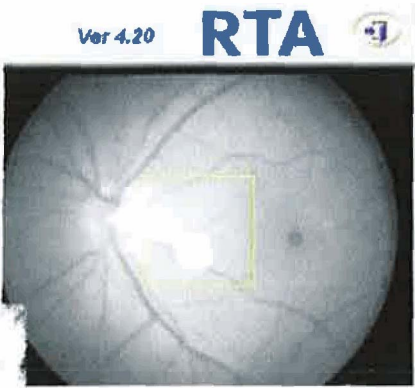
Images before acquisition



Images after acquisition

3. Click "Measure".

4. If you are doing an optic disc scan you must click and drag the yellow square so that the disc is centered in it.



If you want to repeat a scan click "Rescan" otherwise click "Next Scan".

Continue focusing the iris, centering the pupil, making sure that the slit image is centered, and clicking "Measure" until all the scans have been completed.

After all the scans have been performed, click "Analysis".