

Pacific University

CommonKnowledge

College of Optometry

Theses, Dissertations and Capstone Projects

5-1993

Atlas of common complications associated with R.G.P. and S.C.L wear

Nancy A. Selinger
Pacific University

Recommended Citation

Selinger, Nancy A., "Atlas of common complications associated with R.G.P. and S.C.L wear" (1993).
College of Optometry. 1077.
<https://commons.pacificu.edu/opt/1077>

This Thesis is brought to you for free and open access by the Theses, Dissertations and Capstone Projects at CommonKnowledge. It has been accepted for inclusion in College of Optometry by an authorized administrator of CommonKnowledge. For more information, please contact CommonKnowledge@pacificu.edu.

Atlas of common complications associated with R.G.P. and S.C.L wear

Abstract

Contact lenses are a popular and frequently used mode of correcting refractive error and are occasionally used to treat diseased and degenerative processes. As both Rigid Gas Permeable (RGP) and Soft Contact Lenses (SCL) lie directly on the cornea buffered only by the tear layer, it is the cornea that shows the first signs of adverse effects of contact lens wear. Contact lenses can affect the cornea both mechanically, due to their physical presence on the eye, as well as indirectly through interference with the normal physiology of the cornea. As the mode of contact lens wear increases through new materials and designs, so too do the needs of the patient. The population trend is moving toward the older patient and this group of patients are less tolerant to mild corneal hypoxia and mechanical trauma than the younger population. At the same time, as their corneal topography and physiology is more fragile, there is an increased need for thicker contact lenses (e.g. bifocal lenses). With this situation, the early detection of contact lens complications is critical in order to preserve a healthy visual system. A good patient evaluation assessing the ocular health, combined with strong patient motivation is the first step in successful contact lens wear. Secondly, a thorough knowledge of materials, lens design, fits and care solutions also contribute to successful long term contact lens wear. Once a patient has been fitted with their lenses, the recognition of early contact lens complications is essential. The earlier the identification and correct treatment is undertaken, the better the prognosis for continued success in contact lens wear. Optometry students and new practitioners (who may have had little experience with contact lens complications), often find it difficult to correctly identify the problems and implement the correct treatment. This thesis was developed to provide a pictorial reference guide with an accompanying written identification and treatment guideline for eight of the most common contact lens complications. The early identification, and implementation of appropriate treatment will usually stop the progression of the corneal/lid problem, preserving and/ or re-establishing a healthy ocular system, while still maintaining good visual acuity. Successful treatment of contact lens associated ocular problems can lead to continued healthy contact lens wear by the patient.

Degree Type

Thesis

Degree Name

Master of Science in Vision Science

Committee Chair

Cristina M. Schneider

Subject Categories

Optometry

Copyright and terms of use

If you have downloaded this document directly from the web or from CommonKnowledge, see the "Rights" section on the previous page for the terms of use.

If you have received this document through an interlibrary loan/document delivery service, the following terms of use apply:

Copyright in this work is held by the author(s). You may download or print any portion of this document for personal use only, or for any use that is allowed by fair use (Title 17, §107 U.S.C.). Except for personal or fair use, you or your borrowing library may not reproduce, remix, republish, post, transmit, or distribute this document, or any portion thereof, without the permission of the copyright owner. [Note: If this document is licensed under a Creative Commons license (see "Rights" on the previous page) which allows broader usage rights, your use is governed by the terms of that license.]

Inquiries regarding further use of these materials should be addressed to: CommonKnowledge Rights, Pacific University Library, 2043 College Way, Forest Grove, OR 97116, (503) 352-7209. Email inquiries may be directed to: copyright@pacificu.edu

ATLAS OF COMMON
COMPLICATIONS ASSOCIATED WITH
R.G.P. AND S.C.L. WEAR

by

Nancy A. Selinger

A thesis submitted to the faculty
of the
College of Optometry
PACIFIC UNIVERSITY
FOREST GROVE, OREGON
for the degree of

Doctor of Optometry

MAY, 1993

Advisor:

Cristina M. Schnider, O.D.

SIGNATURE PAGE

Nancy A. Selinger

NANCY A. SELINGER

January 1993

JANUARY 1993

Christina M. Schnider

CHRISTINA M. SCHNIDER O.D.
(Advisor)

1/93

JANUARY 1993

ACKNOWLEDGEMENT

I wish to extend my sincerest thanks and appreciation to my advisor, Dr. Christina Schnider, for her unlimited knowledge, encouragement and guidance in the preparation of this thesis. I also wish to express my appreciation to Beta Sigma Kappa for their generous financial support which allowed me to use color photographs.

I would like to thank Claudine Kawabata for her assistance in doing a computer search, as well as Dr. Bonnie Gauer and Dr. Kent Wise for their expert help on the computer.

A very special thank you to my husband John for his ideas, computer expertise, encouragement and patience during the preparation and completion of this thesis.

To my children Meghan, Adam and Caitlyn, I would like to say thank you for your love and patience in allowing me the time to successfully complete this thesis.

AUTOBIOGRAPHY

Nancy Selinger was born and raised in Vancouver, B.C., Canada. After receiving her R.N. degree, she worked in the operating room for several years, primarily in Neurosurgery and E.E.N.T. During her nursing career Nancy lived in Regina, Saskatchewan, where she married John Selinger and had their three children Meghan, Adam and Caitlyn.

Upon returning to school she attended the University of Regina and Pacific University, where she received her B.Sc. degree in 1991 and is currently a fourth year student in the Doctor of Optometry program at Pacific. Upon graduation, Mrs. Selinger anticipates working in a full scope practice with an emphasis on contact lenses.

ABSTRACT

Contact lenses are a popular and frequently used mode of correcting refractive error and are occasionally used to treat diseased and degenerative processes. As both Rigid Gas Permeable (RGP) and Soft Contact Lenses (SCL) lie directly on the cornea buffered only by the tear layer, it is the cornea that shows the first signs of adverse effects of contact lens wear.

Contact lenses can affect the cornea both mechanically, due to their physical presence on the eye, as well as indirectly through interference with the normal physiology of the cornea.

As the mode of contact lens wear increases through new materials and designs, so too do the needs of the patient. The population trend is moving toward the older patient and this group of patients are less tolerant to mild corneal hypoxia and mechanical trauma than the younger population. At the same time, as their corneal topography and physiology is more fragile, there is an increased need for thicker contact lenses (e.g. bifocal lenses). With this situation, the early detection of contact lens complications is critical in order to preserve a healthy visual system.

A good patient evaluation assessing the ocular health, combined with strong patient motivation is the first step in successful contact lens wear. Secondly, a thorough knowledge of materials, lens design, fits and care solutions also contribute to successful long term contact lens wear. Once a patient has been fitted with their lenses, the recognition of early contact lens complications is essential. The earlier the identification and correct treatment is undertaken, the better the prognosis for continued success in contact lens wear.

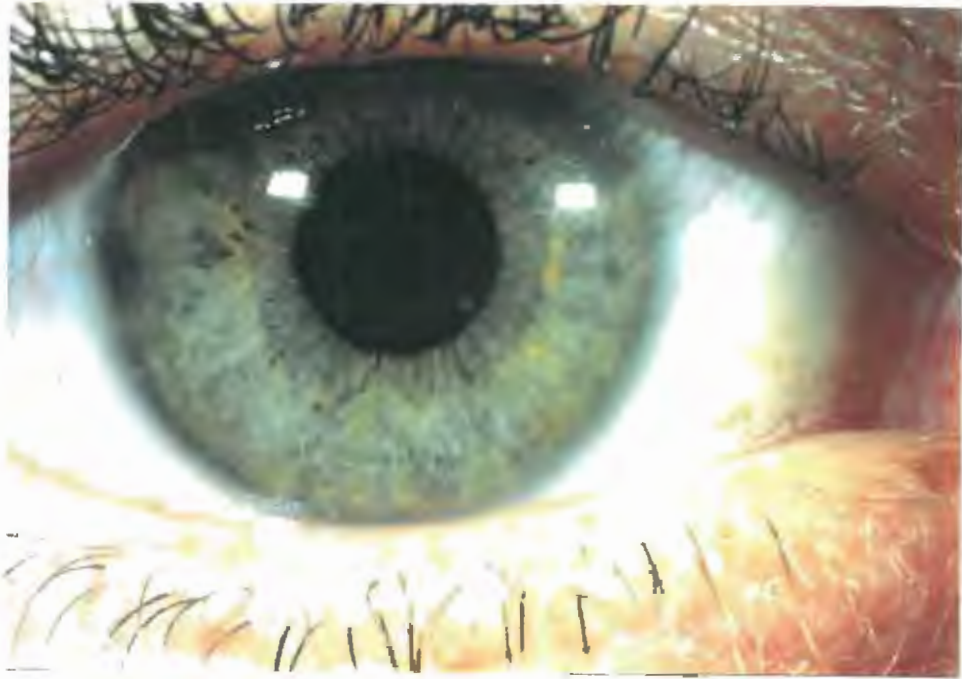
Optometry students and new practitioners (who may have had little experience with contact lens complications), often find it difficult to correctly identify the problems and implement the correct treatment. This thesis was developed to provide a pictorial reference guide with an accompanying written identification and treatment guideline for eight of the most common contact lens complications.

The early identification, and implementation of appropriate treatment will usually stop the progression of the corneal/lid problem, preserving and/or re-establishing a healthy ocular system, while still maintaining good visual acuity. Successful treatment of contact lens associated ocular problems can lead to continued healthy contact lens wear by the patient.

TABLE OF CONTENTS

1. VASCULARIZATION
Pages 1-4
2. CONTACT LENS - SUPERIOR LIMBIC KERATOCONJUNCTIVITIS
Pages 5-8
3. EPITHELIAL MICROCYSTS
Pages 9-11
4. CORNEAL INFILTRATES
Pages 12-15
5. CONJUNCTIVAL HYPEREMIA
Pages 16-18
6. EDEMA
Pages 19-22
7. CONTACT LENS PAPILLARY CONJUNCTIVITIS
Pages 23-27
8. EPITHELIAL STAINING INTRODUCTION
Page 28
 1. Mechanical Trauma
Pages 29-32
 2. Toxicity
Pages 33-34
 3. Physiological
Page 35
 4. Dessication
Pages 36-39
9. BIBLIOGRAPHY
Pages 40-43

HEALTHY EYE



CONDITION - "VASCULARIZATION"

VASCULARIZATION - the formation and extension of vascular capillaries within and into a normally avascular cornea.¹

NEOVASCULARIZATION - the formation and extension of new vascular capillaries within and into a previously vascularized cornea.¹

GHOST VESSELS - empty blood vessels where only the vessel wall remains. Seen as faint white lines.⁴ May persist indefinitely and will refill with blood at the slightest provocation.⁴

VASCULAR RESPONSE to CL wear occurs in three stages:³

- Stage 1 - the terminal capillaries that are normally empty now fill with blood
- Stage 2 - active stage where there is actual new vessel outgrowth from the limbal arcade
- Stage 3 - unless treated, the new vessels continue to grow into all layers of the cornea (may be straight or tortuous):
 - a) possibly form new limbal arcades or
 - b) possibly grow into cornea & approach or cross pupil zone jeopardizing V/A

Associated with:

1. tight fitting contact lens
2. EW SCL³⁹ > DW SCL³⁹ > RGP > 0 lens¹

ETIOLOGY

- A. Hypoxia - decreased O₂ interferes with normal aerobic metabolism. Anaerobic metabolism takes place producing excessive lactic acid => cornea vascularization.^{1,4}
- B. Edema - due to chronic low grade hypoxia .
 1. causes softening of the stroma thus allowing vessel growth into the stroma.^{1,3,4,39}
- C. Mechanical Injury - chronic irritation of the C.L. to the cornea epithelium induces release of vaso-stimulating agent in the area leading to new vessel growth.^{1,3,39}

VASCULARIZATION

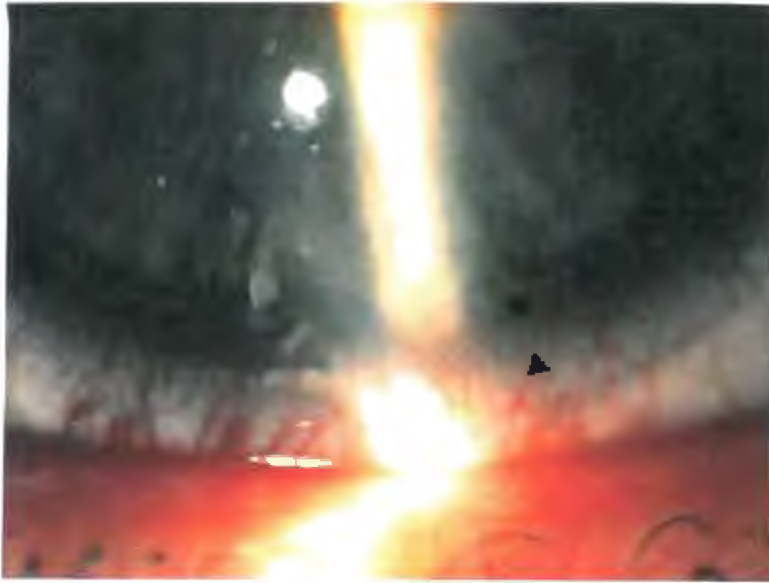


Fig. 1
Vascularization
Limbal Grey
Zone

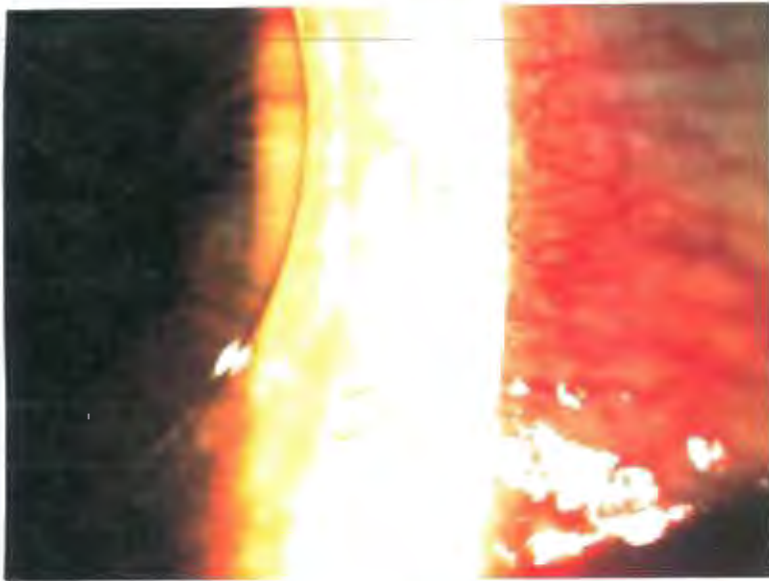


Fig. 2
Vascularization
Grade 1



Fig. 3
Vascularization
▶ Ghost Vessels
Grade 2

VASCULARIZATION (continued)

GRADES AND TREATMENT

A. Grading

A. All grading is done from the limit of the limbal grey zone under normal lighting conditions.

B. Applicable for DW and EW RGP and SCL

C. 5 level grading scale - may add (superficial) S or (deep) D as determined by SLE using parallelepiped illumination.

<u>Grade</u>	<u>Distance from limit of visible limbal grey zone to stroma</u>	<u>Treatment</u>
0	0.0 mm vascular response	None
1	0.5 mm vascular response	1. Monitor limbal vessels at regular intervals.
2	1.0 mm vascular response	1. Increase Dk/L ^{1,4} 2. New lens and/or material (SCL => RGP) ¹ 3. Reduce wear time (EW => DW) ^{1,4} 4. Change solution (reduce allergic response) ^{1,4}
3	1.5 mm vascular response - Serious ¹ - Beyond 1.5mm indicates accelerated growth rate of vessels into stroma	1. Discontinue lens ¹ wear for extended time/permanently 2. If CL wear resumed, change parameters as per Grade 2
4	2.0 mm vascular response - Vessels are approaching pupil zone at rapid rate and vision is threatened.	1. Discontinue wear ⁴ permanently 2. Medical referral laser/diatherapy /keratoplasty ¹

VASCULARIZATION (continued)

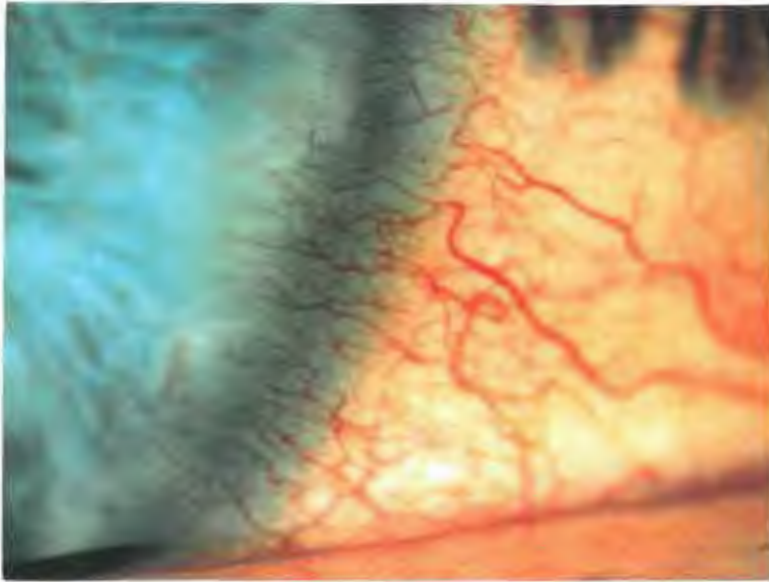


Fig. 4
Vascularization
Grade 3

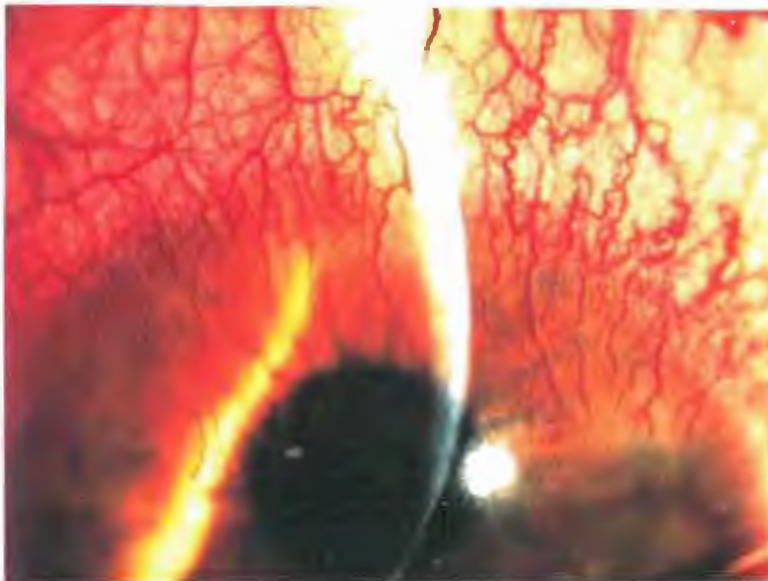


Fig. 5
Vascularization
Grade 4

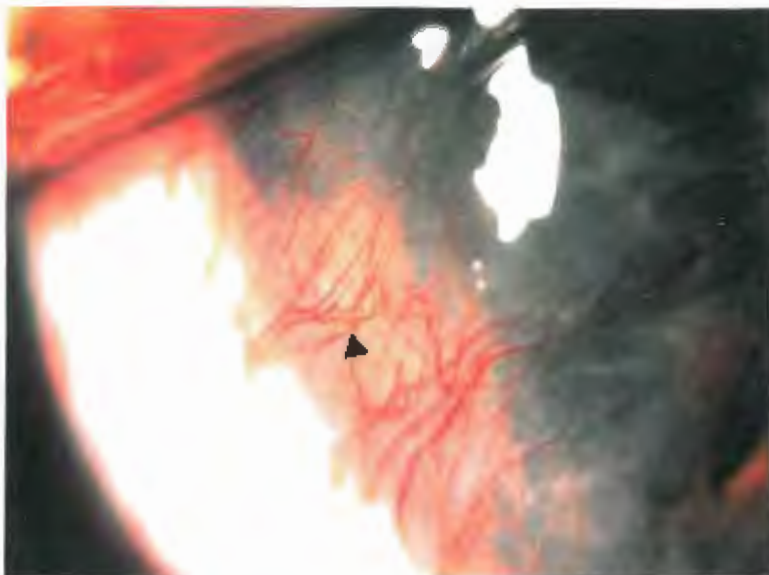


Fig. 6
Vascularization
▶ Pannus with
underlying
infiltrates
Grade 4

VASCULARIZATION (continued)

PREVENTION

- A. High Dk/L => reduced hypoxia
- B. Reduced mechanical irritation => increased patient comfort
- C. Good movement => less limbal vessel compression
- D. Good care system => reduces toxic/allergic responses
- E. Regular evaluation of lens.

PROGNOSIS

- A. Grade 1 may undergo some regression of new blood vessels when contact lens wear is discontinued.¹
- B. Grade 2 established corneal vessels do not fully regress and can persist indefinitely as ghost vessels.⁴
- C. Cessation of lens wear will usually halt the progression of vessel growth into the cornea and resumption of contact lens wear must proceed with caution.
- D. If there is subsequent injury or if inflammation occurs in the same area as old neovascularization, the ghost vessels will quickly refill with blood.

CONDITION - "CONTACT LENS- SUPERIOR LIMBIC KERATOCONJUNCTIVITIS"

- CL- SLKC - is usually a bilateral chronic inflammation of the superior tarsal and bulbar conjunctiva, the superior limbus and superior peripheral cornea.^{6,11}
- Although CL-SLKC and Theodore's SLKC share many of the same diagnostic features, Theodore's SLKC is usually associated with hyperthyroid disease.^{7,12} While a history of thyroid disease predisposes patients of all ages, SLKC is usually found in older women.^{7,12} SLKC can occur independent of CL wear.
 - seen in younger patients with history of thyroid disease⁴²
 - pathological changes are:
 - a. affected tissue is chemosed
 - b. epithelial cells hypertrophy - epithelium contains lipid inclusion bodies filled with fluid vacuoles
 - c. surface epithelium has fewer microvilli and is more keratinized
 - d. inflammatory cells accumulate in underlying conjunctival stroma

Associated with:

1. abnormal corneal epithelium, altered tear film and abnormal lid posture
2. contact lens wear (SCL)¹²

ETIOLOGY

- A. Specific etiology - contact lens wear.
- B. Contributing conditions⁵
 1. tissue hypoxia^{6,11,16}
 2. mechanical irritation of the lens as it moves over the limbus^{6,11,16,41}
 3. reaction to preservatives in lens care products e.g: Thimerosal^{7,11,12,16,41,42}
 4. environmental antigens adhere to lens deposits and react with corneal tissue in an Ag- Ab reaction¹⁶

CONTACT LENS - SUPERIOR LIMBIC KERATOCONJUNCTIVITIS
(continued)

SYMPTOMS

- A. Photophobia^{7,12,16}
- B. Foreign Body sensation - increased lens awareness^{7,16}
- C. Burning^{7,16,42}
- D. Itching, Hazy vision ^{12,16,42}
- E. Pain⁷
- F. Lens intolerance^{12,42}
- G. Dryness, Filaments ⁴²

SIGNS

- A. Superior tarsal conjunctiva and bulbar conjunctiva:¹²
 - diffuse papillary hypertrophy reaction in tarsal conjunctiva^{11,16}
 - punctate stain with rose bengal and fluorescein^{6,16,41}
 - edematous

- B. Superior bulbar conjunctiva surface¹⁶
 - thickened (due to edema)
 - increased keratinization
 - decreased surface microvilli
 - hypertrophied epithelial cells
 - hyperemia²⁴
 - punctate staining²⁴

- C. Superior limbus - cornea and adjacent conjunctiva¹¹
 - hyperemic
 - epithelial haziness
 - sub-epithelial infiltrates^{12,16,42}
 - stains with rose bengal and fluorescein¹⁶
 - fibro-vascular micropannus consisting of vascularized connective tissue^{11,12,16,42}
 - superior punctate staining⁴²
 - superior corneal surface irregularities⁴²

EVALUATION

- A. Slit Lamp Evaluation
 - diffuse (low magnification) and direct focal (optic section or parallelepiped) illumination
 - moderate to high magnification
 - must raise upper lid to examine superior limbic region

- B. Culture
 - negative⁶

SUPERIOR LIMBIC KERATOCONJUNCTIVITIS (SLK)

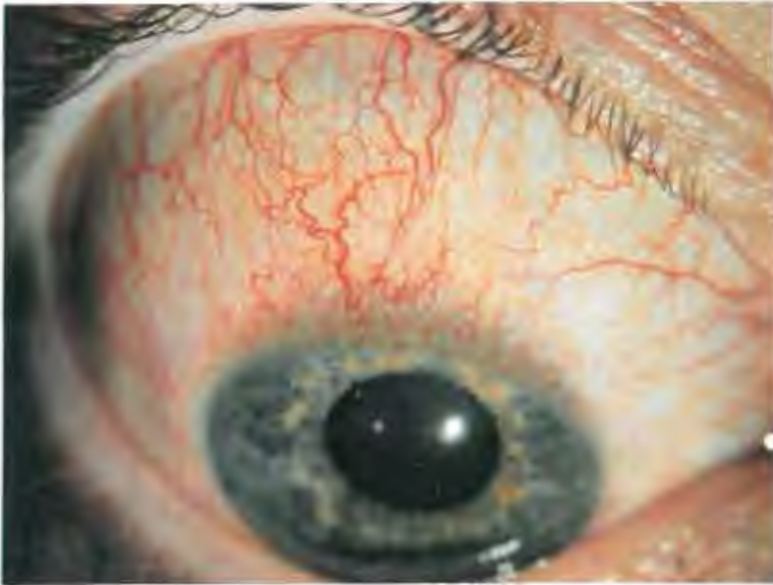

Fig. 7 SLK
Grade 2

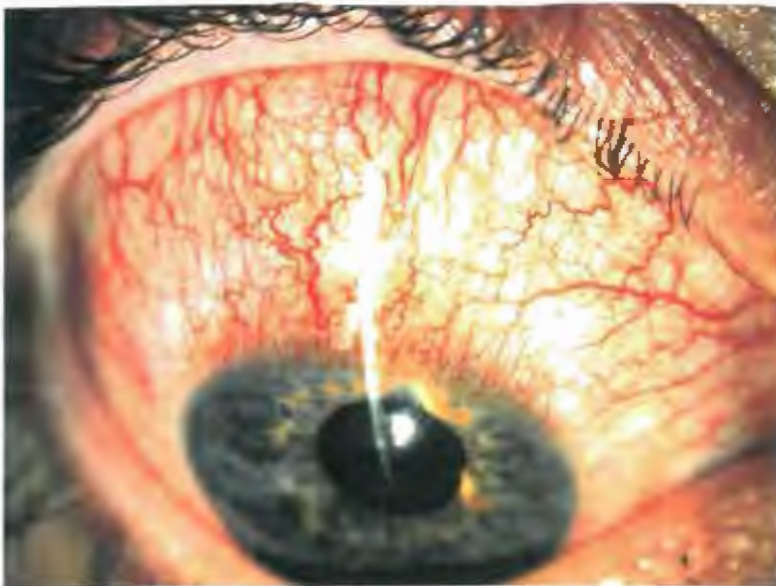

Fig. 8 SLK
Grade 3

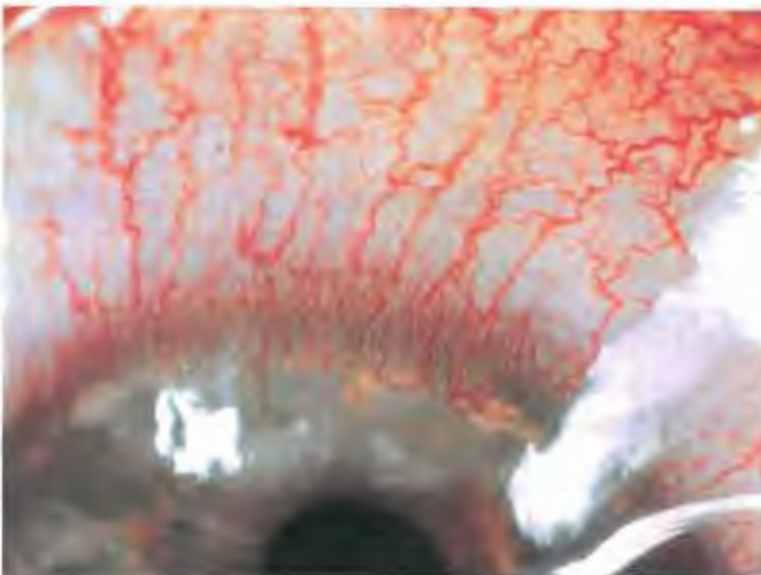


Fig. 9 SLK
Grade 3⁺

CONTACT LENS - SUPERIOR LIMBIC KERATOCONJUNCTIVITIS

(continued)

GRADES AND TREATMENT

<u>Grade</u>	<u>Signs and Symptoms</u>	<u>Treatment</u>
0	Normal tarsal and bulbar conjunctiva	No treatment
1	- Mild hyperemia - superior bulbar/tarsal conjunctiva - Mild burning/itching	1. Reduce wear time (EW => DW) 2. Ocular lubricants ^{12,16} 3. Monitor
2	- Increased conjunctiva inflammation ⁴¹ - Moderate conjunctiva stain ⁴¹ - Beginning of pannus formation on superior bulbar/tarsal conjunctiva	1. Discontinue lens wear until all inflammation subsides ^{12,16} 2. Lubricants ^{12,16} 3. Change to non-preserved solutions ^{6, 11} , use heat disinfection ¹¹
3	- Few corneal infiltrates ⁴¹ - Corneal punctate stain ⁴¹ - Conjunctiva hypertrophy - Pannus extends to and over the limbus	<u>As for Grade 2 plus:</u> 1. New lens material - use greater deposit resistant material ¹⁶ 2. SCL => RGP: this may be the best option due to low incidence of CL-SLK with this type of lens ^{6,16} 3. Looser fit 4. Redesign SCL edges 5. Cromolyn Sodium 4% qid (mast cell stabilizer) ⁷
4	- Increased corneal stain => coalesce - Increased conjunctiva hypertrophy - Superior pannus formation extends into central cornea ⁴¹ - Destruction of Bowman's membrane ⁴⁶ associated with formation of sub-epithelial opacities ⁴¹	1. Discontinue lens wear until inflammatory process is completely resolved - may take weeks to months ⁴² 2. CL wear may be permanently discontinued 3. Refit as per Grade 3

CONTACT LENS - SUPERIOR LIMBIC KERATOCONJUNCTIVITIS
(continued)

GRADES AND TREATMENT (continued)

Note: Mild CL- SKL is easy to miss unless the upper lid is elevated and a critical evaluation of the superior limbus is made.¹⁶

PREVENTION:

- A. Ensure good CL fit and design (e.g. rounded edges).
- B. Monitor superior limbus during routine examinations.
- C. Use of preservative free solutions.
- D. Use of a good care regime which will reduce deposit build-up.
- E. Use of high Dk/L lens material will reduce hypoxia.

PROGNOSIS:

- A. Good if condition is diagnosed early and treatment is undertaken.
- B. If grade 4 level is reached the prognosis is guarded as the contact lens wear may have to be permanently discontinued.

CONDITION - "EPITHELIAL MICROCYSTS"

EPITHELIAL MICROCYST - minute, scattered, irregular shaped dots that are postulated to be pockets of dead cellular matter^{4,9}

- originate in the lower epithelial layers and migrate toward the surface along with normal epithelial cell growth¹³
- usually located para-central in the mid-periphery of the cornea⁹
- can occur in normal population non contact lens wearers - may occasionally see 1 or 2 microcysts¹⁰

Associated with:

1. Chronic hypoxia - the development of microcysts is inversely related to the Dk/L ⁷
2. Chronic suppression of epithelial metabolism¹⁴
3. Mechanical irritation
4. EW SCL (and to a much lesser degree, DW SCL and EW RGP)¹⁴
5. Wearing EW SCL for 1-2 months

ETIOLOGY

- A. Etiology : believed to be due to a disorder of epithelial cellular growth^{11,4}

SYMPTONS

- A. Generally asymptomatic⁴
- B. Decreased V/A with increased number of microcysts⁴
- C. Bilateral but asymmetrical
- D. Cyclical - number may fluctuate during lens wear with microcysts disappearing periodically

SIGNS

- A. Slit lamp examination
 - irregular shaped grey-white translucent small dots (approximately 15-50 μm)^{1,11}
 - appear to be particles of debris in the tear film but remain fixed with blinking⁴
 - may observe negative stain if cysts cause small elevation at corneal surface but did not rupture⁸
 - may observe punctate corneal stain in dot like pattern if cysts have ruptured at the surface^{8,9}
 - stained areas may coalesce to produce corneal erosion⁹

EPITHELIAL MICROCYSTS (continued)

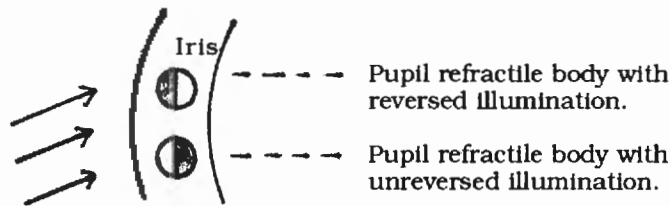
EVALUATION

Slit Lamp Evaluation

- moderate to high magnification (15-35X)
- marginal retro-illumination or direct retro-illumination

DIFFERENTIAL DIAGNOSIS:

- A. Microcysts - shows reversed illumination where the dark part of cyst is on the side of the bright background and the light portion of the cyst is on the side of the dark background^{4,8}
Reversed illumination is possibly due to the high index of refraction material inside the microcyst relative to that in the surrounding tissue. ^{4,14}



- B. Vacuoles - transparent, fluid filled, round dots that look like tiny air bubbles, varying in size from 20 => 50 μm ^{9,14}
- usually in discrete units but may be seen in clusters of 2 =>
 - do not stain with fluorescein as they are intraepithelial^{9,14}
 - shows non-reversed illumination where the dark part of the vacuole is on the side with the dark pupil and the bright side of the vacuole is on the side with the brightly lit iris^{4,8}
 - generally innocuous and require no action

EPITHELIAL MICROCYSTS




Fig. 10 Microcysts
No erupting
Grade 2




Fig. 11 Microcysts
and Vacuoles
★ Microcysts
▶ Vacuoles

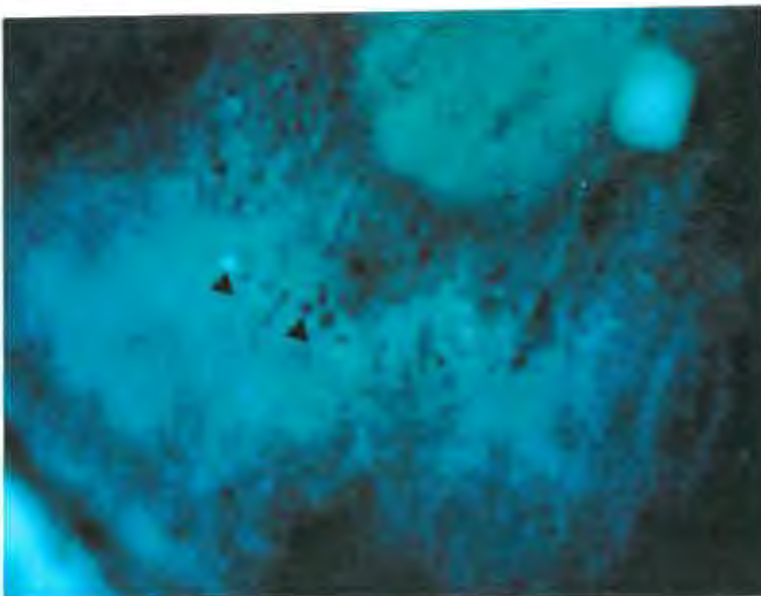


Fig. 12 Microcysts
erupting
▶ Black - Neg Stain
▶ Pool - Erupted
Grade 3

EPITHELIAL MICROCYSTS (continued)

GRADES AND TREATMENT

<u>Grade</u>	<u>Description</u>	<u>Treatment</u>
0	Acceptable - $x < 10$	No treatment
1	Acceptable - $10 < x < 20$	1. No treatment 2. Monitor patient with follow-up visits
2	$20 < x < 50$ - Break in cell layer - Stain with 2+ cysts - May become infected	1. Discontinue lens wear until number of cysts reaches a more acceptable level and no epithelial stain is present ^{4,9} 2. May reduce wear time (EW => DW) 3. Follow-up/monitor
3	$x > 50$ - Moderate to heavy number of cysts - Punctate stain is present	<u>As for Grade 2 plus:</u> 1. Refit with high Dk/L DW RGP with reduced thickness or thin, high H ₂ O DW SCL ¹⁴
4	$x > 50$ - High number of cysts - Coalesced punctate staining suggesting corneal erosion ⁹	<u>As for Grade 3</u>

PROGNOSIS

- A. Prognosis is good.⁴
- B. It takes 1 => 2 months of wearing EW lenses for microcysts to form.
- C. It may take from 1 => 3 months for microcysts to resolve.
- D. When initially discontinuing EW len wear, the number of microcysts typically increase for the first week and slowly decrease thereafter.^{4,9}

CONDITION - "CORNEAL INFILTRATES"

CORNEAL INFILTRATES - aggregations of inflammatory cells such as monocytes and polymorphonuclearphils (PMN's)^{4,14,15}.

They may be located near an area of necrotic tissue:²⁷

1. sub epithelial¹¹
2. deep epithelium^{11,14}
3. anywhere in the stroma between the collagen fibers¹⁴

Associated with:

1. contact lens hypersensitivity (Thimerosal)^{11,15}
2. preserved solutions^{4,14,15}
3. infections^{4,15}
 - a. bacterial exotoxins¹⁴
 - b. virus
 - c. chlamydia¹⁴
 - d. staph immune complexes¹⁴
 - e. corneal hypoxia
 - f. (adenovirus - patient aware of associated cold/flu like symptoms)
4. prolonged hypoxia^{4,15}
5. immune response^{4,15}
6. physical irritation⁴
7. tight fitting lens^{4,11,14}
8. metabolic wastes trapped under the lens⁴
9. risk - EWCL >> DWCL¹⁵

ETIOLOGY

A. Inflammatory cells are believed to have entered the cornea via the tear film or limbal blood vessels¹¹

B. DIFFERENTIAL DIAGNOSIS ;

1. Epithelial Microcysts - do not occur in discrete patches but appear more uniformly scattered.¹⁴
2. Vacuoles - do not reflect light and therefore are difficult to see with direct focal illumination¹¹
3. Scar - appears as more superficial or full thickness

SYMPTOMS

A. Condition may be symptomatic or asymptomatic

B. Usually asymptomatic with white quiet eye

C. If symptomatic, patient may present unilaterally with:¹⁴

1. red eye
2. foreign body sensation
3. lacrimation
4. discharge
5. photophobic

CORNEAL INFILTRATES (continued)

SIGNS

A. Slit lamp examination:

- may observe single or multiple translucent area(s), round grey-white, well demarcated bodies most commonly located in the superior cornea under the upper lid (10 => 2 o'clock location).¹¹
- 93% are found in the peripheral cornea¹⁵
- may occur as band-shaped forms near the limbus or discrete spots scattered throughout the cornea²⁷

B. Size

- Usually 0.5 => 2.0 mm diameter¹¹

EVALUATION

A. Slit Lamp Evaluation

- low => moderate magnification 10-20X (optic section)
- marginal retro-illumination
- indirect retro-illumination
- with high magnification (40X), epithelial infiltrates will appear as grey bodies within an infiltrative area¹⁴
- direct focal illumination - infiltrates may appear as amorphous shapes with a slightly dense center¹⁴
- look for condition of focal or diffuse translucent grey-white demarcated bodies commonly in 10 => 2 o'clock area in peripheral superior cornea under upper lid

GRADES AND TREATMENT

A. Grading

- A. Graded as for color density nebula => macula=> leukoma
- B. Limbus is the key area to evaluate infiltrates¹⁴

The appearance of infiltrates indicates that a potentially serious tissue reaction is imminent. Consider the possibility of an ulcer/infectious process.

CORNEAL INFILTRATES




Fig. 13 Infiltrates
Grade 1




Fig. 14 Infiltrates
Grade 2

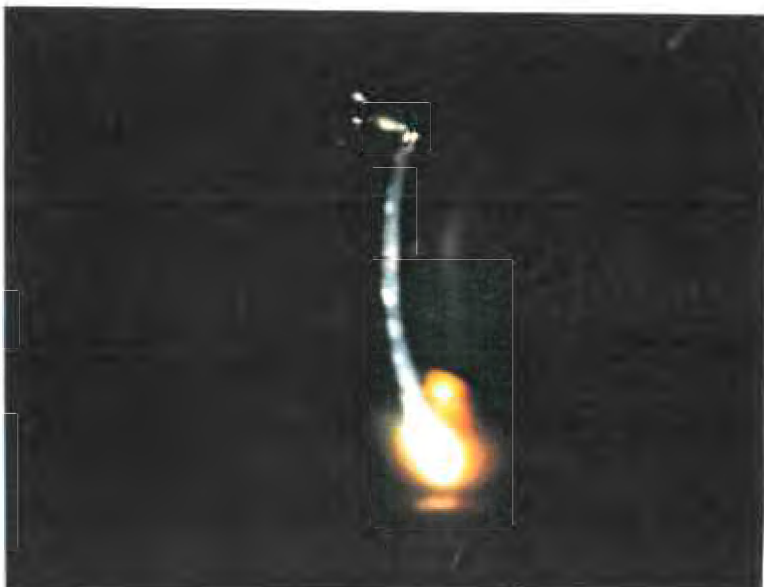


Fig. 15 Infiltrates
Grade 4

CORNEAL INFILTRATES (continued)

GRADES AND TREATMENT (continued)

<u>Grade</u>	<u>Appearance</u>	<u>Treatment</u>
0	No infiltrates	No treatment
1	Mild inflammatory process - see slight haze	1. Clean lens 2. Non-preserved solutions 3. Monitor
2	Moderate inflammatory process with increase in density of stromal haze and increased number of hazy areas	<u>As for Grade 2 plus;</u> 1. Discontinue lens wear for 2-3 weeks, symptoms will cease in 1-2 days 2. Non-preserved solution ¹⁴ 3. Refit with looser lens 4. Clean lens
3	- Severe infiltrate process - Multiple or increasing density of infiltrates - No staining present	<u>As for Grade 2 plus;-</u> 1. Discontinue lens wear until infiltrates completely resolved ¹⁵ (usually resolve in 1 to 2 months) After a quiet period with no CL wear, no meds and cornea free of infiltrates, patient may resume CL wear 2. Change material (SCL => RGP) 3. Reduce wear time (EW => DW) ⁴ 4. Steroids ¹⁴ 5. Hypertonics - prn to increase visual acuity 6. Increase Dk/L
4	EPITHELIAL DEFECT THAT STAINS - very serious	1. Discontinue lens wear with immediate medical attention ⁴

CORNEAL INFILTRATES (continued)

PROGNOSIS:

- A. Good if diagnosed and treated immediately.
- B. If condition progresses to infiltrative keratitis - severe visual consequences may occur.¹⁵
- C. CL intolerance may continue long after infiltrates have resolved.
- D. Patient may be left with residual scar.

CONDITION - "CONJUNCTIVAL HYPEREMIA"

CONJUNCTIVAL HYPEREMIA - benign response that is demonstrated as an overfilling of limbal vessels with RGP's and increased hyperemia of conjunctiva with SCL's³¹

- chronic hyperemia is common among contact lens wearers:
SCL with preserved solution > SCL with non-preserved solution > RGP > non-CL wearers³¹
- SCL solutions are often preserved with Thimerosal which is an organic mercurial product with broad spectrum anti-microbial properties.^{42,43} It is widely used in non-ocular products such as vaccines, skin testing allergens and anti-venoms as well as ocular products such as CL solutions.

The mechanism of ocular Thimerosal sensitivity reaction is believed to be type IV (delayed cell-mediated) alone or possibly some effect from type III (delayed complex-mediated) allergic reaction⁴⁵. In both type III and IV allergic reaction, there must have been previous exposure to the allergen⁴²

- may be active (inflammatory), passive (tight lens) or both³

Associated with:

1. dry eyes/ocular dryness
2. eye irritation - possibly (but not exclusively) related to lens design, wear time, environmental factors(fumes, chemicals) or foreign bodies.

ETIOLOGY

A. Conjunctival hyperemia (limbus) can be a direct response to contact lens issues such as:³¹

1. surface deposits^{3,30}
2. hypoxia
3. poor fitting (e.g. tight edges)³
4. solution preservatives (e.g. Thimerosal)³
5. damaged lenses^{3,30}
6. contaminated lenses by toxic fumes, spray, liquids, etc.³⁰
7. residual "Foreign body" response³
8. lens dehydration secondary to corneal/conjunctival dehydration of tear film

B. Response to issues not directly related to contact lens wear eg:^{3,31}

1. reduced sleep
2. hay fever/allergies
3. eyestrain

CONJUNCTIVAL HYPEREMIA

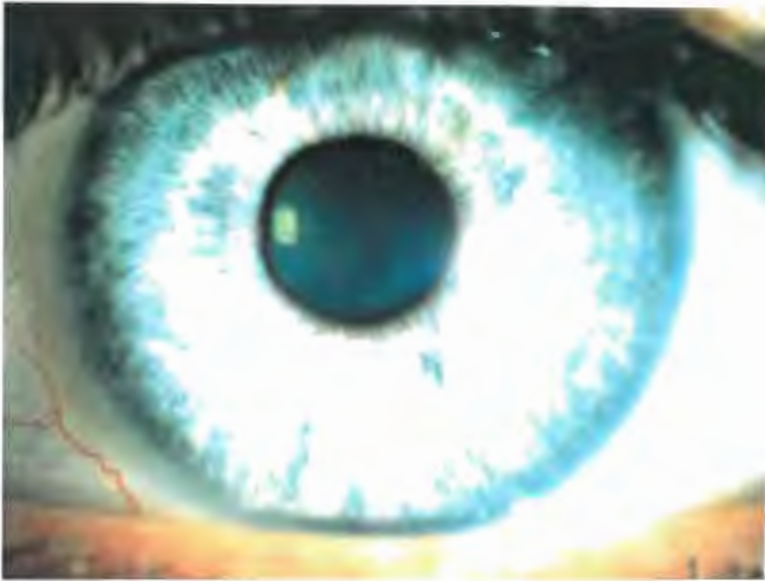

Fig. 16 Hyperemia
Grade 1

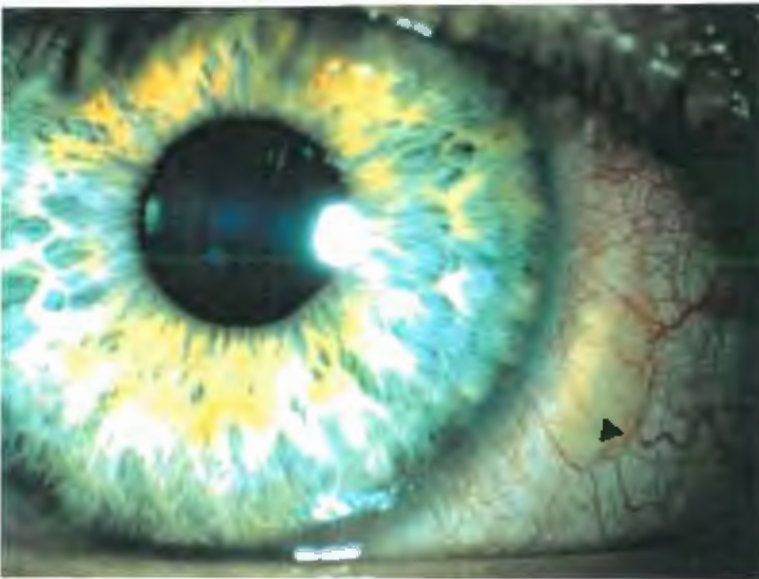


Fig. 17 Hyperemia
Note the
▶ Pinguecula
Grade 2

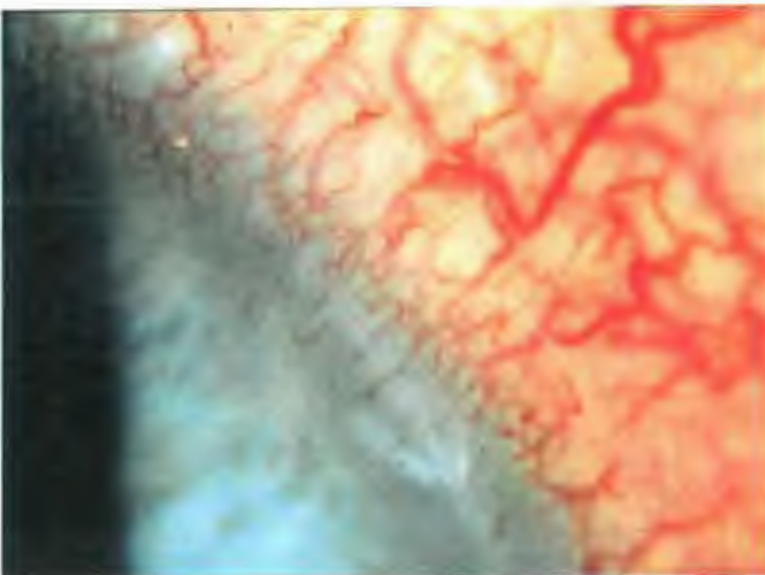


Fig. 18 Hyperemia
Grade 3

CONJUNCTIVAL HYPEREMIA (continued)

ETIOLOGY (continued)

4. wind, dust, smoke, smog, heat, etc.
5. alcohol
6. other environmental irritants to visual system
7. low ambient humidity
8. dry eyes

SYMPTOMS

- A. Patient is generally asymptomatic
- B. Foreign body sensation - stinging, burning, tearing

SIGNS

- A. Conjunctiva Hyperemia
 - SCL is 360 degrees
 - RGP is usually at 3 and 9 o'clock

EVALUATION

- A. Slit Lamp Evaluation
 - direct focal illumination
 - diffuse illumination with low magnification (10X)
- B. Direct Observation

GRADES AND TREATMENT

<u>Grade</u>	<u>Appearance</u>	<u>Treatment</u>
0	No hyperemia	No treatment (e.g. anaemia, albino)
1	Normal conjunctiva hyperemia	No treatment
2	Mild hyperemia	1. Monitor 2. Lubricants 3. Assess lens for damage/ defects
3	Moderate hyperemia	<u>As for Grade 2 plus:</u> 1. Reduce wear time 2. Increase enzyme cleaning (Surfactant) 3. Non-preserved solutions

CONJUNCTIVAL HYPEREMIA (continued)

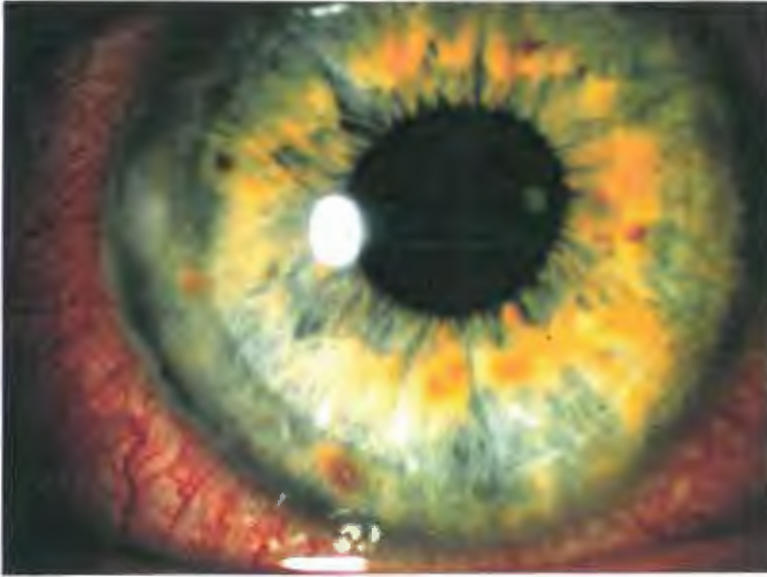

Fig. 19 Hyperemia
Note indent on
cornea due to
bound lens
Grade 4

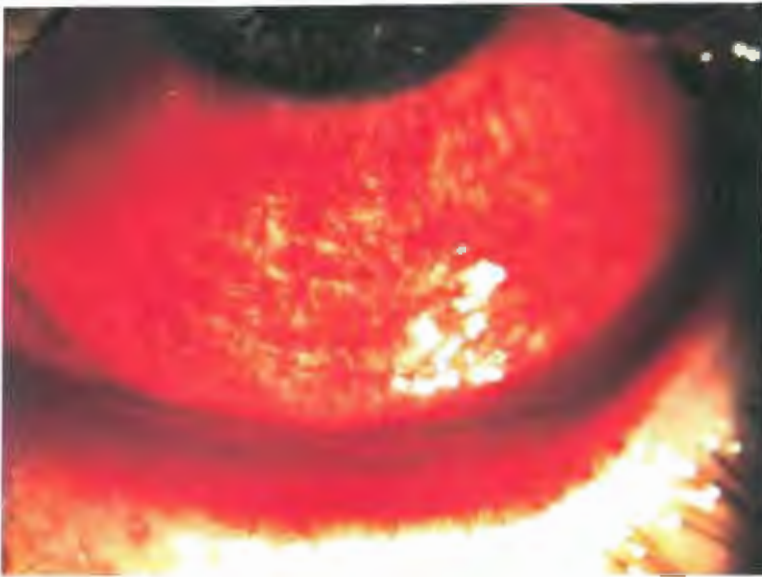


Fig. 20 Hyperemia
Grade 4⁺

CONJUNCTIVAL HYPEREMIA (continued)

GRADES AND TREATMENT (continued)

<u>Grade</u>	<u>Appearance</u>	<u>Treatment</u>
3 (cont.)		4. Punctal occlusion if dry eye problem, 5. Artificial tears 6. Improve fit - blend RGP
4	Severe hyperemia	<u>As for Grade 3 plus:</u> 1. Discontinue lens wear until Grade 1 hyperemia 2. Vasoconstrictor 3. Increase Dk/L 4. EW => DW 5. Refit with new material, well blended RGP 6. Flatter BC with SCL 7. If hyperemia does not resolve immediately with discontinuing lens wear, assess for underlying pathology.

PREVENTION:

- A. Well fitting, well wetting lens.
- B. Patients must be aware to use "full" blinks.
- C. Supplemental lubricants.
- D. Non-preserved solutions.
- E. Moist environment (humidifiers).

PROGNOSIS

- A. With well fitting lens and good lens care, hyperemia can be well maintained at a Grade 1 level.
- B. Unless appropriate treatment is initiated, may progress to neovascularization (a more serious complication).

CONDITION - "EDEMA"

EDEMA - is a local or generalized condition where there is an excess accumulation of fluid in the tissue due to decreased O₂ to the cornea. This causes the cornea epithelium to undergo anaerobic respiration to conserve energy and results in a build up of the byproduct, lactic acid. The increase in lactic acid raises the stromal osmotic pressure and there is an influx of fluid entering the stroma in order to balance the osmotic conditions.^{11,16} This influx of fluid may result in folds and/or striae.⁴

Associated with:

1. soft contact lens wear and to a much lesser extent, R.G.P. and PMMA.^{21,22}

ETIOLOGY

- A. Hypoxia^{16,18}
- B. Trauma after a perforating wound¹⁸
- C. Mechanical irritation^{4,16,18}
- D. Inflammatory states^{4,16,18}
- E. Diabetes^{18,21}
- F. Idiopathic¹⁸
- G. Tear hypotonicity^{4,11}
- H. Change in temperature and pH⁴
- I. Reduced barrier effect¹⁶

Possible Mechanism:

- Swelling occurs due to reduced O₂ equally over the entire cornea with SCL.
- Edema appears primarily in the central cornea area (as CCC) with PMMA lenses.¹¹ The sole source of the O₂ to the cornea with PMMA lenses is the tear pump. Once the O₂ exchange is restricted due to decreased tear pump activity, the cornea becomes cloudy in the central area.
- With RGP lenses, there is a more diffuse swelling as oxygen is able to pass through the lens itself unlike the PMMA lens. The cornea thickens in an anterior-posterior direction but due to the strong Bowman's membrane, the swelling is restricted primarily in the posterior direction.^{18,19} As the corneal limbus is fixed, the distance to be spanned by Descemet's and the posterior stroma is decreased which leads to a vertical buckling of the corneal endothelium and Descemet's membrane, and is seen as striae or folds.^{18,19,23}

EDEMA (continued)

SYMPTOMS

- A. Patient is generally asymptomatic.²¹
- B. Visual acuity is generally unaffected with lens on (RGP > SCL)²¹
- C. Bilateral > unilateral^{21,24,26}
- D. Increase in myopia and astigmatism with lens removal.

SIGNS

- A. If edema > 15%:
 - displaces regular structural elements^{26,38}
 - steamy cornea^{24,38}
 - decreased visual acuity
 - infiltrates
 - bullous keratopathy³⁸
 - light scattering (glare)^{11,26,38}

EVALUATION: (measure central corneal region)

- A. Pachometer (to determine corneal thickness)¹⁸
 - normal = 0.506 mm for the center cornea
 - corneal swelling of 5-6% = vertical striae are visible
 - corneal swelling 10-12% = folds are visible
- B. Retinoscope - (12") - see dark lines
- C. Ophthalmoscope - (12-15 D) - observe dark lattice-like pattern
 - folds seen against red reflex¹⁸
- D. Slit Lamp Evaluation
 - retro-illumination to see general disruption of the corneal structures
 - parallelepiped of 1-2 mm with diffuse-direct illumination at a 30° => 45° angle²³ temporal to patient's eye and microscope is 20° nasal¹⁸
 - sclerotic scatter with a 1 => 2mm beam over limbus while viewing the central cornea with or without magnification against a black pupil

DIFFERENTIAL DIAGNOSIS

- A. Striae:
 - appear as shiny grey-white vertical linear streaks on the parallelepiped posterior curve.⁴
 - the number of striae is proportional to the degree of corneal swelling
 - striae are usually of uniform diameter lying parallel to each other and more commonly located in central cornea at the posterior stroma level or Descemet's^{21,23}

EDEMA {continued}

A. Striae (continued)

- usually vertical but may be oblique or horizontal,²¹ may be branched,²¹ more sharply defined ²³, shorter and more numerous

B. Folds:

- appear as dark lines with specular reflection or white lines with direct illumination¹⁸
- appear to be a buckling of posterior cornea layer -Danger Signal!
- occur as vertical, horizontal and oblique lines¹⁸
- horizontal folds appear larger than vertical¹⁸
- folds yield to digital palpitation²¹

C. Glassy Striae:

- vertical lines will not disappear momentarily with digital pressure; with corneal edema they disappear^{18,21,24,26}
- only viewed with retro-illumination ¹⁸

D Nerve Fibers:

- more anterior and bifurcated ^{4,23}
- usually thinner, vertical pattern, shorter and more numerous
- same whitish color as striae

E. Central Corneal Clouding (CCC):

- greyish circular clouding in pupil area (see following scale):⁵⁰

Scale 0	- No CCC
Scale 1	- Just detectable corneal haze without distinct borders
Scale 2	- Distinct borders, but visible only against a dark pupil background. - Light density.
Scale 3	- Borders very distinct, area of clouding visible against iris and in dimly lighted room

- Note: - Striae always accompany folds but folds will not always accompany striae¹⁸
- Corneal swelling should not exceed 5-6%

EDEMA




Fig. 21 Edema
▶ Folds
Grade 3



Fig. 22 Edema
Folds and Striae
High Mag. used
★ Striae
▶ Folds
Grade 4

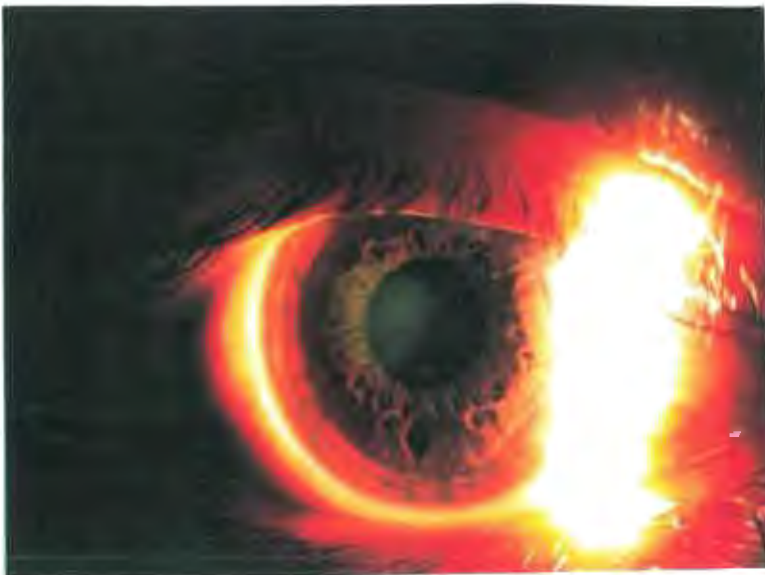

Fig. 23 Edema
CCC with RGP
lens
Grade 4

EDEMA (continued)

GRADES AND TREATMENT

<u>Grade</u>	<u>Edema</u>	<u>Treatment</u>
0	No corneal swelling	No treatment
1	1% - <5% corneal swelling	Monitor
2	5% - <10% swelling (Striae)	1. Reduce wear time ¹⁸ 2. Fit with looser lens ¹⁸ 3. Reduce center thickness (C.T.) 4. Increase Dk/L (change material) ¹⁶
3	10%-15% thickening (Folds)	<u>As for Grade 2 plus:</u> 1. Temporarily discontinue CL wear 2. Flatten base curve ^{16,22} 3. Smaller O.A.D.
4	Thickening greater than 15%	Discontinue contact lens wear permanently

PROGNOSIS:

- A. Good - following discontinued lens wear.
- B. Acute episode - resolves in 2-3 hours.^{4,16,21}
- C. Chronic episode - resolves in approximately 1 week.^{4,16}
- D. May result in stroma thinning.¹⁶
- E. Condition is reversible with discontinuing of lens wear - vertical lines disappear in 2-4 day.^{21,24,26}

CONDITION - "CONTACT LENS PAPILLARY CONJUNCTIVITIS" (CLPC)

- CLPC
- is a reversible ocular inflammatory syndrome that is usually (but not exclusively) related to CL wear³⁵-occurs with SCL > RGP
 - papillae located on the upper tarsal conjunctiva¹⁷
 - Histologically - Papillae contain mast cells, eosinophil, basophil, plasma cells, PMN's and lymphocytes in the conjunctiva stroma²⁵
 - CL induced papillae are not enlarged normal papillae; they are new abnormally large papillae associated with a pathological process³⁵
 - although a common complication of contact lens wear CLPC is often overlooked/misdiagnosed due to:
 - a. lack of awareness by patient of early symptoms of increased mucous/itchy eyes
 - b. failure by attending Dr. to routinely evert the upper lid with each visit¹⁷
 - reduced CLPC with RGP as compared to SCL due to:
 - a. minimal preservative uptake
 - b. reduced adherence of deposits
 - c. smaller O.A.D. => reduced contact with lid tissue

Associated with:

1. mechanical irritation of lens edge on lid
2. in conjunction with an immune response.
3. irritation may be a product of the fitting, design, inadequate lens cleaning and/or irregular or deposited lens surfaces

ETIOLOGY

- A. Combination of mechanical, immunological and inflammatory mechanisms:^{29,37}
1. protein deposits on the CL become antigens that induce type IV allergy reaction^{25,27}
 2. fitting and/or design
 3. constant lens edge irritation of the lid combined with an immune response^{25,27}
 4. genetic susceptibility to papillary response^{13,27}
 5. inadequate lens cleaning
 6. mechanical trauma to lid combined with the antigen response constitutes the afferent limb of immune response. The efferent limb involves the accumulation of mast cells, lymphocytes and basophil in the palpebral conjunctiva³⁷

CONTACT LENS PAPILLARY CONJUNCTIVITIS - (CLPC) (continued)

SYMPTOMS

- A. Increased mucous (stringy & sheets),^{25,33} mucus in eye on awakening is first sign²⁰
- B. Itchiness (especially with lens removal)^{20,28,35,37}
- C. Discomfort with lens insertion³⁷
- D. Lens intolerance²⁸
- E. Reduced visual acuity (blur)^{17,29,35,37}
- F. Increased lens slippage^{17,33}
- G. Injection²⁸
- H. Foreign body sensation during CL wear^{29,35,37}

SIGNS

- A. Enlarged papillae
- B. Tarsal conjunctiva hyperemia

EVALUATION

Slit Lamp Evaluation

- evert upper lid and observe superior tarsal surface²⁹
- direct illumination with maximum illumination³²
- 3-5 mm wide beam³²
- low-medium magnification (10-25X)
- diffuse illumination to give best overall impression of lid surface
- fluorescein stain with cobalt blue filter^{25,29}
- inferior conjunctiva is normal

DIFFERENTIAL DIAGNOSIS

1. Follicles^{35,36}
 - non vascular with no central blood vessel
 - usually in inferior tarsal conjunctiva
 - have pyramidal edges with respect to the tarsal plane
2. Papillae^{20,35}
 - vascular base with a central blood vessel
 - usually in upper tarsal conjunctiva
 - have perpendicular edges with respect to the tarsal plate
 - have white heads that look like scars
3. Allansmith et al. developed a mechanism to predict the development of papilla on the upper tarsal conjunctiva. The upper tarsal lid was divided in three zones:³³
 - Zone 1 most superior;
 - Zone 2 middle tarsal area;
 - Zone 3 closest to the lid margin

CONTACT LENS PAPILLARY CONJUNCTIVITIS

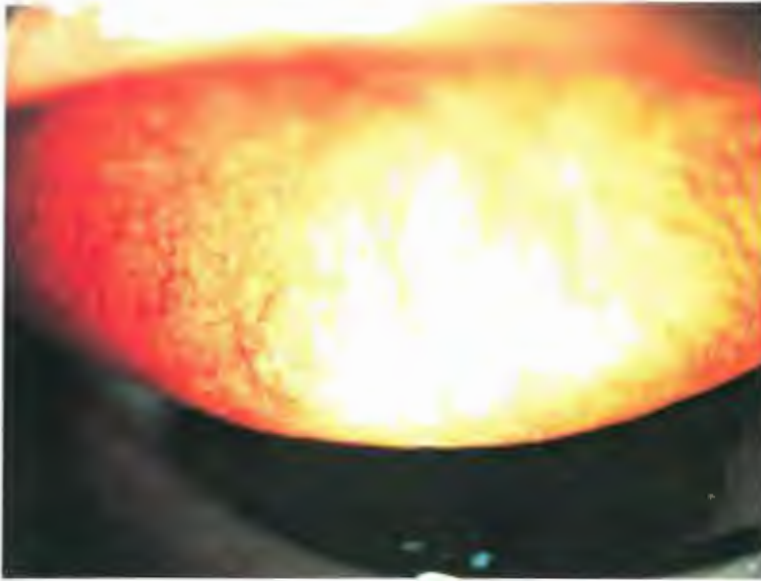


Fig. 24 CLPC
Grade 1
Hyperemia
Grade 2

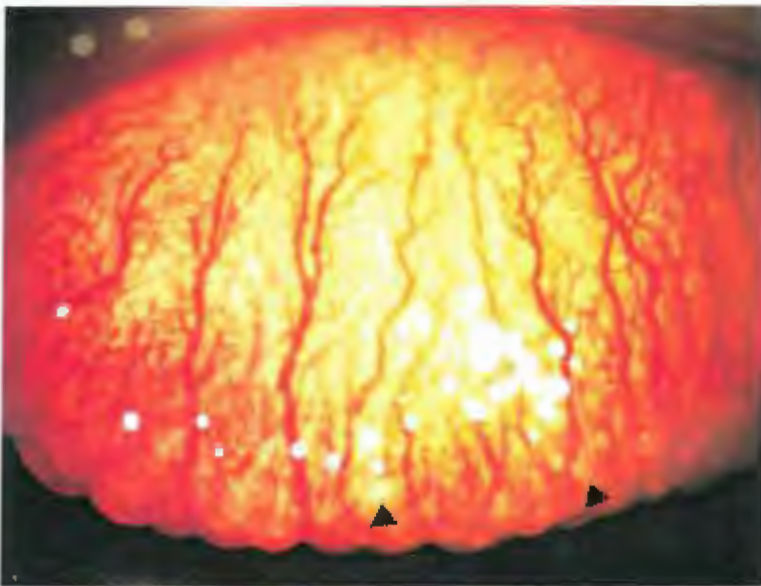

Fig. 25 CLPC
Grade 2
Note large
▶ follicles at fold
Hyperemia
Grade 2- Zone 2
Hyperemia
Grade 3 in
lateral area

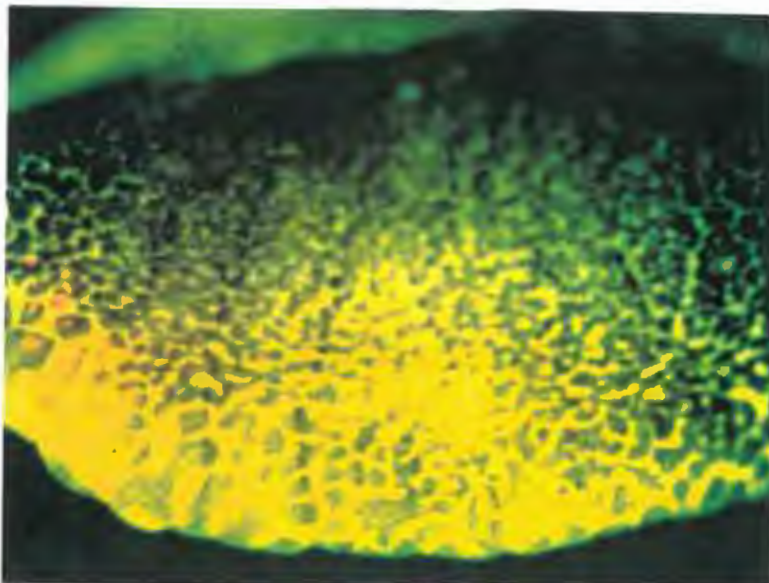
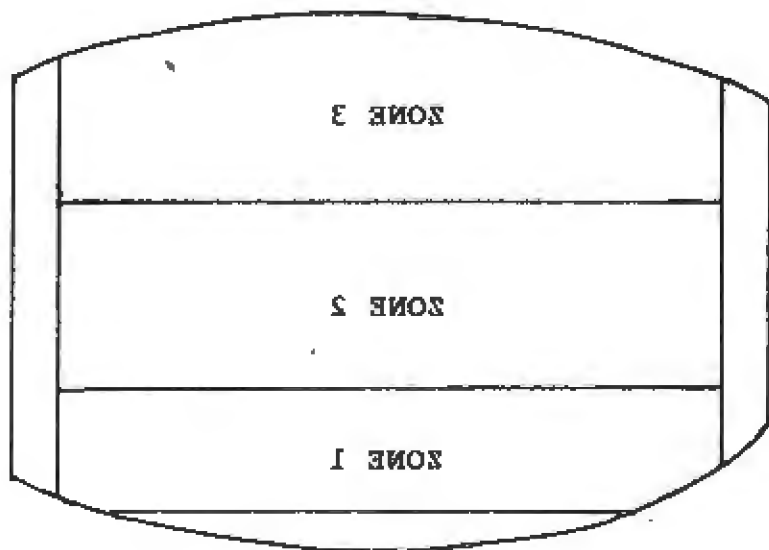
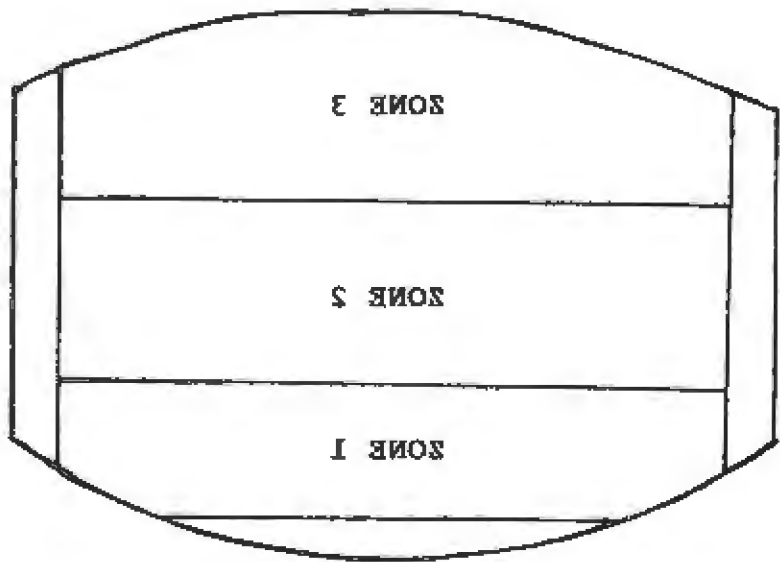
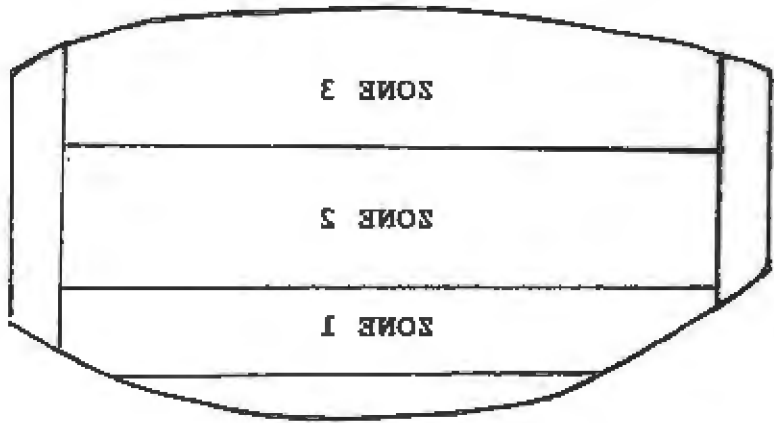


Fig. 26 CLPC
+ fluorescein
stain
Grade 2
Same patient as
in Fig. 25



CONTACT LENS PAPILLARY CONJUNCTIVITS - (CLPC) (continued)

DIFFERENTIAL DIAGNOSIS (continued)

SCL induced CLPC first appear in Zone 3 and progresses to Zone 1, whereas RGP induced CLPC generally appears in Zone 1 first and then progresses to Zone 3³⁵

4. CLPC related to RGP^{25,26}
 - a) less numerous papillae than with SCL
 - b) tops appear crater-like
5. CLPC related to SCL^{25,26}
 - a) greater number than with RGP
 - b) tops appear flatter or more round

GRADES AND TREATMENT

- Adapted from Allansmith et al.'s Stages of GPC Development

<u>Grade</u>	<u>Signs and Symptoms</u>	<u>Treatment</u>
0	<ul style="list-style-type: none">- No papillae on tarsal plate- No tarsal conjunctiva hyperemia- Asymptomatic	<ol style="list-style-type: none">1. No treatment2. Continue wearing lens
1 ²⁵ (Mild)	<ul style="list-style-type: none">- Mild conjunctiva hyperemia- No edema or increased swelling- Uniform microscopic papillae- Mild itch with lens removal²⁵- Minimal increase of mucus^{25,37}	<ol style="list-style-type: none">1. Use non-preserved care system²⁰2. Increase care regime^{17,34}3. Decrease wear time (EW => DW)^{17,34}4. Weekly enzyme clean¹⁷ (with papain)^{25,29,35}5. Monitor and evert lid with every visit³⁴
2 ²⁵ (Moderate)	<ul style="list-style-type: none">- Tarsal conjunctiva-thickened, edematous with moderate hyperemia- Papillae x<0.5mm- Increased lens awareness³⁷- Moderate itch with CL	<p><u>As for Grade 1 plus:</u></p> <ol style="list-style-type: none">1. Discontinue lens wear until symptoms are resolved^{25,28,34,37}2. Hydrogen peroxide for disinfecting (daily) SCL^{20,29,32,36}

CONTACT LENS PAPILLARY CONJUNCTIVITIS (continued)

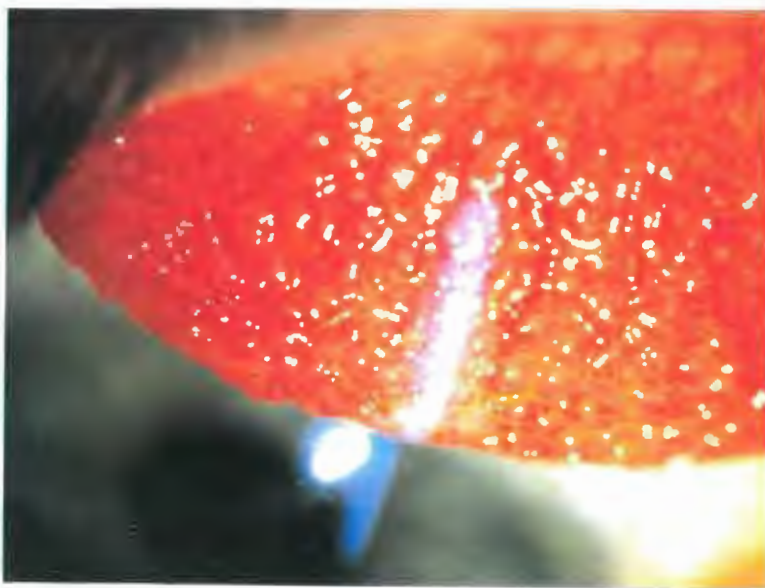


Fig. 27 CLPC
Grade 3
Hyperemia
Grade 2

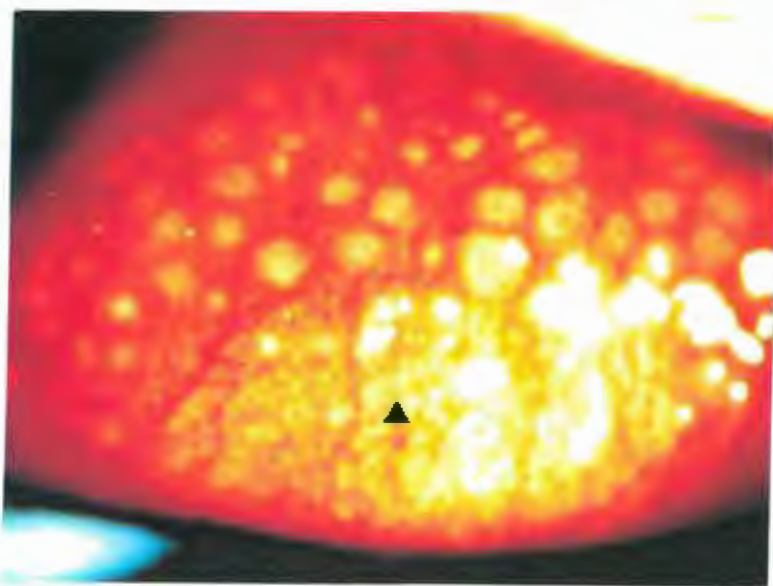
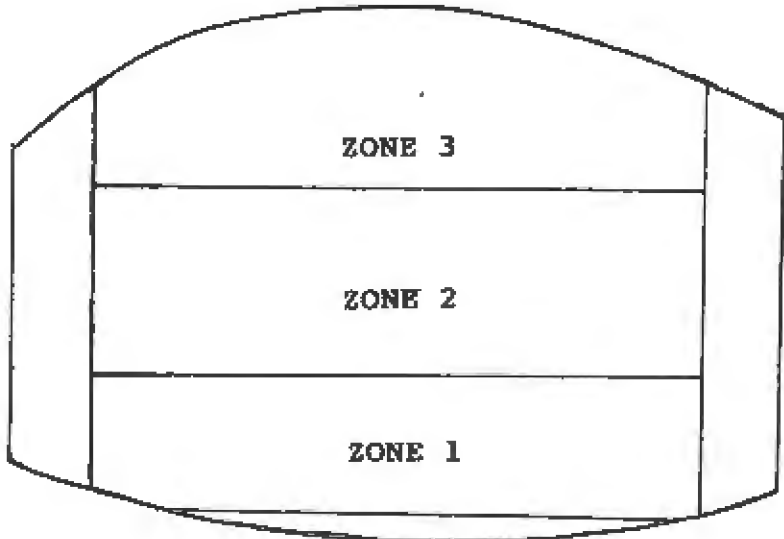
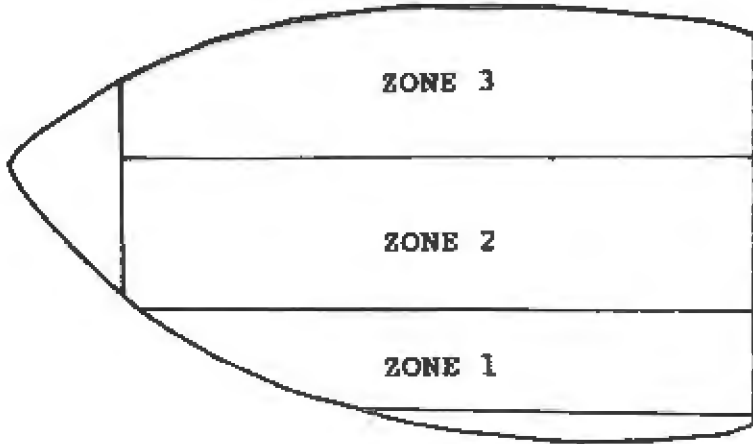


Fig. 28 CLPC
Note the
GPC and the
▶ scarring
Grade 4
Hyperemia
Grade 2



CONTACT LENS PAPILLARY CONJUNCTIVITIS (CLPC) (continued)

GRADES AND TREATMENT (continued)

<u>Grade</u>	<u>Signs and Symptoms</u>	<u>Treatment</u>
2 (cont.)	<ul style="list-style-type: none">- Slight increase in number/elevation of papillae- In late stage, can observe papillae with fluorescein & cobalt filter with SLE	<ol style="list-style-type: none">3. No heat as the protein bakes on the lens4. No cold system as too irritating to eye^{20,35}5. Alter lens fit, edge, design,^{20,37} material³⁶6. Chromylon 4% qid³⁴ with and without lens
³²⁵ Mod/severe	<ul style="list-style-type: none">- Tarsal conjunctiva is more edematous-- moderate => severe hyperedema- Papillae no longer uniform in size- may vary from 0.5 => < 1.0 mm- Pupillae increased in # and elevation²⁵- Heavy mucus secretion/ observed lens coating- Papillae tops stain with fluorescein²⁵- Increased lens movement²⁵	<p><u>As for Grade 2 plus:</u></p> <ol style="list-style-type: none">1. Enzyme clean to 3X/wk2. Replace lens q.6-12 months^{20,35}3. Refit SCL => RGP^{17,28}4. RGP - smaller OAD5. Good lenticular fit6. SCL - change to 13.8 mm CSI - small pore size<ul style="list-style-type: none">- smooth surface- round edge7. Optichrom (Chromolyn) 4% indefinitely8. Monitor every 2 wks until CLPC is resolved9. Topical steroids eg.FML
⁴²⁵	<ul style="list-style-type: none">- Severe tarsal conjunctiva hyperedema- Papillae are x >1.0mm- Tops of papillae flatten => deep clefts between papillae²⁵- Total CL intolerance³⁷- Coated lens => decentering²⁵- Cornea may show:<ol style="list-style-type: none">a. cornea punctate stainb. white arcuate infiltrate superior²⁵	<p><u>As for Grade 3 plus:</u></p> <ol style="list-style-type: none">1. Discontinue lens wear may be intolerant to future lens wear

CONTACT LENS PAPILLARY CONJUNCTIVITIS - (CLPC) (continued)

PREVENTION

- A. Educate patients of symptoms of CLPC. Itching, increased mucus or both are not normal to CL wear.²⁰

PROGNOSIS

- A. CLPC may persist for weeks or months but eventually will flatten out and leave a flat discoid scar.¹⁷
- B. There is a good prognosis gained with the most simple changes such as:
 - 1. temporary discontinuance of CL.
 - 2. increased care regimes.
 - 3. use of non-preserved solutions for the control of CLPC during continued CL wear.³⁴
 - 4. regular replacement of CL.

CONDITION - "EPITHELIAL STAINING"

EPITHELIAL STAINING - is a common occurrence among contact lens wearers.⁴⁷ Corneal staining can occur from a variety of sources and have been grouped into the following broad categories according to cause;⁴

1. Mechanical/ Trauma
2. Chemical Toxicity
3. Physiological
4. Desiccation

Staining occurs when fluorescein fills the gaps in damaged or displaced epithelium. Fluid is able to enter the damaged cells.⁴³

Staining indicates:⁴³

- a. damaged epithelial cells
- b. missing epithelial cells
- c. breakdown of the epithelial barrier resulting in stroma edema

Corneal healing time:

- a. mild (superficial) => 12-24 hours^{4,40}
- c. moderate => 24-48 hours⁴
- d. severe (deep) => 3-14 days⁴⁰

EVALUATION

A. Slit Lamp Evaluation

- with fluorescein stain using Kodak Wratten #12 or #15,
- Tiffen #2 yellow photographic filter and cobalt blue
- Kodak #47 or #47A filter over white light source^{40,47}
- diffuse direct illumination - low to medium magnification (10-20X)
- parallelepiped - low to high magnification (10-45X)

B. Fluorescein with Burton Lamp

DIFFERENTIAL DIAGNOSIS OF EPITHELIAL STAINING²

- Observe:
1. extent,⁴⁷ depth,⁴⁰ location⁴⁷
 2. recurrence with old lens/new lens
 3. appearance of stain - symmetrical, circular, linear, punctate, circumcorneal or arcuate⁴¹
 4. time of onset - immediate or delayed
 5. condition of lids/lashes (e.g. marginal staph bleph.)
 6. lens material, design, condition (jelly bumps, defects, edges, etc.)⁴⁴
 7. association with insertion and removal technique
 8. lens fit and relationship to staining (movement, bearing areas)
 9. lid position

1. EPITHELIAL STAINING - MECHANICAL/TRAUMA: Damage to the soft pliable corneal epithelial tissue can result in corneal abrasion ranging from superficial to deep and can occur from wearing both RGP's and SCL's.¹¹ Superficial abrasions generally have little surrounding epithelial edema unlike deep abrasions. The superficial injury involves the external one to three layers of epithelial cells.⁴⁰ Deep abrasion causes a full thickness of the epithelium to be lost over a small or large area.⁴⁰

Associated with:

1. contact lens wear
2. poor insertion and removal techniques

ETIOLOGY

A. Specific Etiology

1. lens defect or poor lens finish^{40,44}
2. SCL posterior surface defects due to jelly bumps embedded in the lens⁴⁴
3. foreign body^{4,40} - airborne material becomes trapped under the lens¹¹ - seen as;
 - a. thin spiral tracks¹¹ (snail tracks)⁴⁰
 - b. linear streaks ending in indented abrasion¹¹
 - c. usually vertically linear in appearance (RGP > SCL)
4. poor insertion or removal of a contact lens e.g: fingernail gouges with RGP's^{11,40,47} - visible as an arcuate gouge in superior or inferior corneal epithelium. Finger print inferior para-central cornea (SCL's)
5. mascara brush abrasion^{2,11,47} - multiple fine linear superficial abrasions usually vertical
6. damaged lens, eg:
 - a. nicks, tears, rough edges⁴¹
 - b. poorly polished surface
7. tight fitting lens^{40,41} Tight adherence and distortion of the epithelial cells at lens bearing area (e.g. RGP)¹¹
 - a. seen as circumcorneal dent that disappears with lens removal¹¹
 - b. increased with aphakic, bandage EW lens or tight SCL; signs and symptoms may appear after 1-2 days wear and appear as circumcorneal punctate stain⁴¹
8. trapped air bubbles - seen as discrete small round indents, but do not break through corneal epithelium if lens is removed immediately¹¹

EPITHELIAL STAINING / MECHANICAL TRAUMA

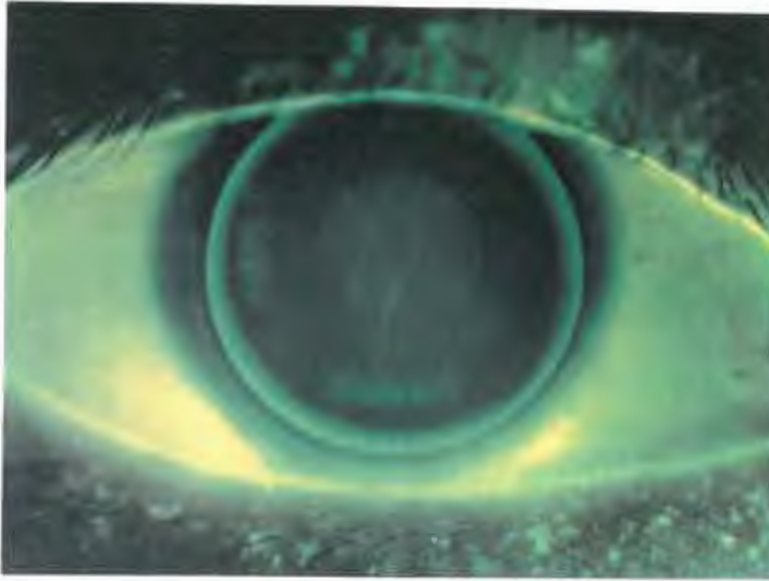

Fig. 29 Vertical
Abrasion

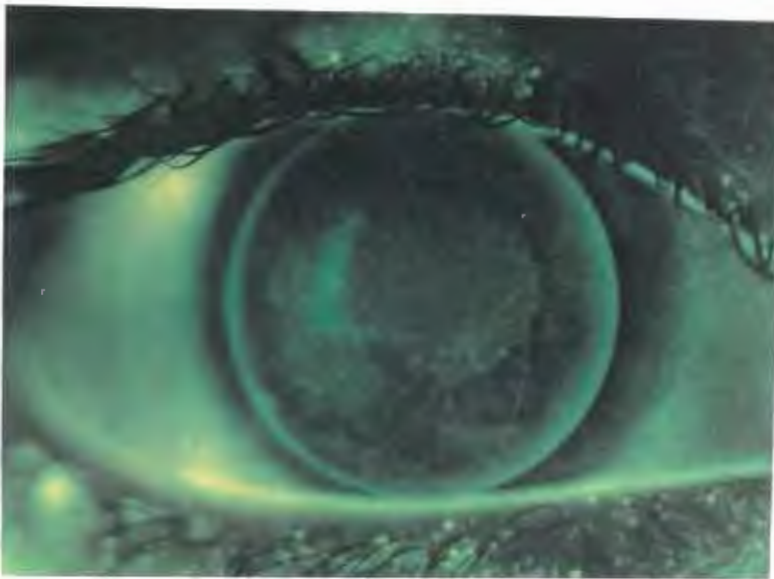


Fig 30 Linear
abrasion due
to foreign
body

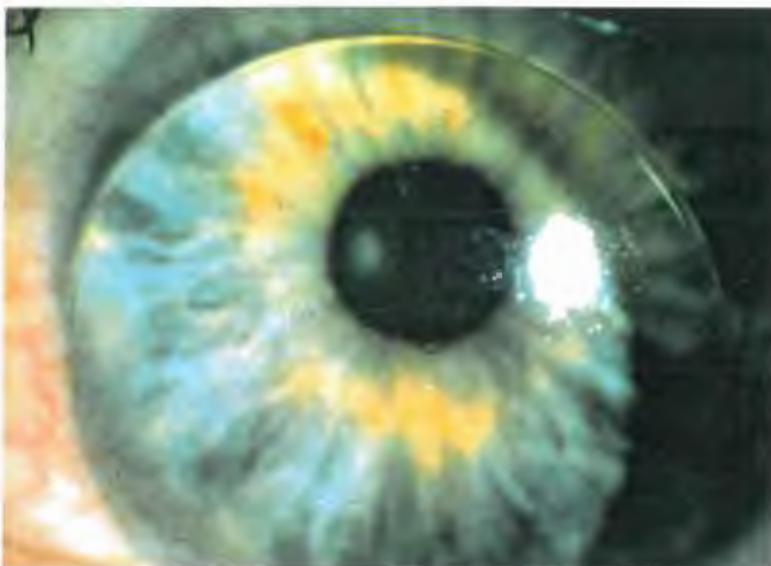


Fig 31 D.W. Bound
lens (lens is in
place)

EPITHELIAL STAINING MECHANICAL/TRAUMA (continued)

SYMPTOMS

- A. Asymptomatic - Possibly due to the corneal threshold injury being lower than that of corneal sensitivity
- B. Symptoms
1. Foreign body sensation
 2. Blepharospasm⁴⁰
 3. Lacrimation⁴⁰
 4. Mild discomfort⁴⁴ => severe pain⁴⁰
 5. Reduced vision

SIGNS

- A. Signs:⁴¹
1. Injection
 2. Corneal edema
 3. Staining with rose bengal or fluorescein.

GRADES AND TREATMENT

<u>Grade</u>	<u>Signs and Symptoms</u>	<u>Treatment</u>
0	Asymptomatic/ no staining	No treatment
1	None to mild discomfort	<ol style="list-style-type: none">1. Evert upper lid: remove foreign body if present via rinse, manual and/or surgical removal2. Discontinue lens wear until staining has resolved^{4,40,41}3. Check lens for defect/tear⁴4. Blend/modify lens if rough edges are present5. Reorder new lens if defect is present
2	Moderate discomfort + staining	<u>As for Grade 1 plus:</u> <ol style="list-style-type: none">1. Refit with:<ol style="list-style-type: none">a. flatter B.C.(looser fit)¹¹b. smaller OAD¹¹ (e.g. RGP)c. different lens material⁴¹d. re-teach,correct insertion /removal techniques

EPITHELIAL STAINING / MECHANICAL TRAUMA (continued)

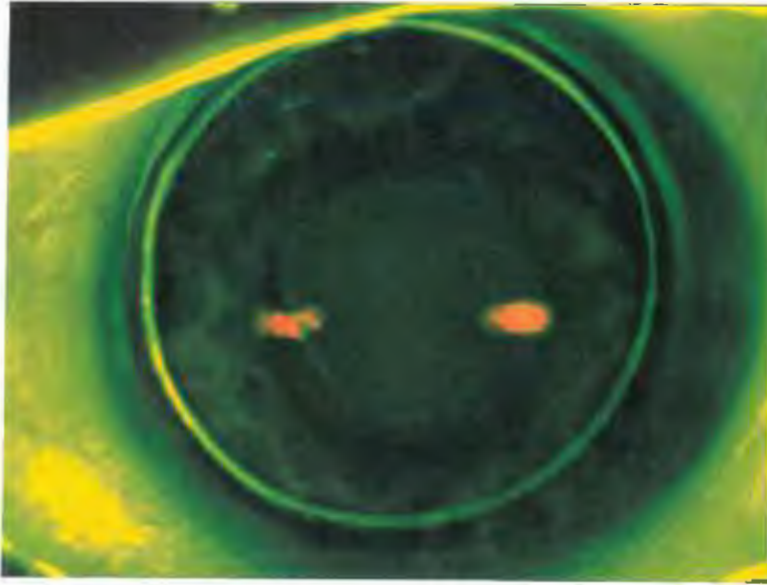


Fig. 32 E.W. bound lens
No lens in place
- imprint




Fig. 33 Rose bengal staining due to low riding RGP

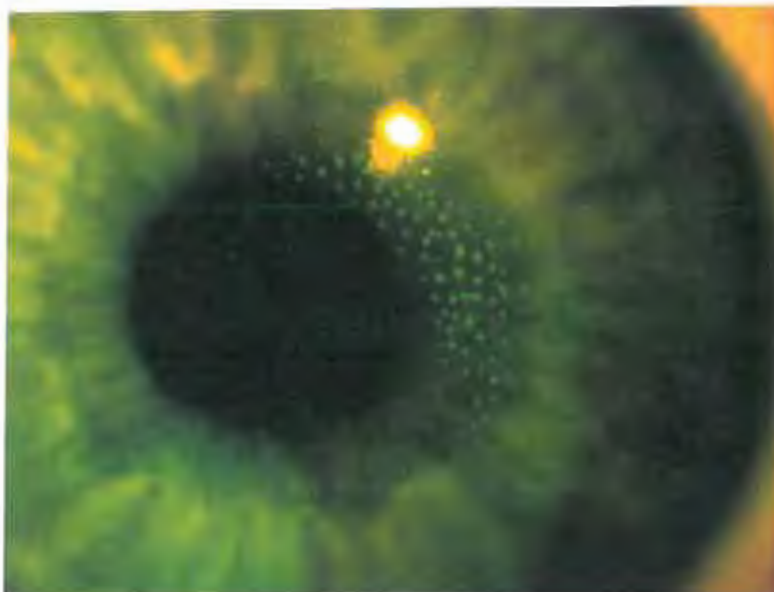


Fig. 34 Dimple veil staining due to aerosol sterile saline solution.

EPITHELIAL STAINING - MECHANICAL / TRAUMA (continued)

GRADES AND TREATMENT (continued)

<u>Grade</u>	<u>Signs and Symptoms</u>	<u>Treatment</u>
2 (cont.)		2. Advise regarding applying mascara and possibility of corneal abrasion
3	Moderate to severe discomfort; + staining	<u>As for Grade 2 plus:</u> 1. Discontinue lens wear until eye is quiet and no stain observed for several days ⁴⁰ 2. Antibiotics ⁴⁷ (gtts/ung) broad spectrum e.g: a. tobramycin ⁴¹ b. Gentamycin 3. Lubricants 4. Observe for signs/symptoms of recurrent corneal erosion (RCE): ⁴⁷ a. blurred vision 2-3 days b. increased pain upon wakening in a.m. 5. Oral analgesic prn ⁴⁰ 6. RTC 24 hours
4	Severe discomfort; + staining	<u>As for Grade 3 plus:</u> 1. RTC, 24 hrs, 3 days, 1 week post injury/deep abrasion ⁴⁰ 2. Patching contraindicated unless adult patient with: ⁴⁰ a. increased lacrimation b. increase blepharospasm c. large defect/abrasion 3. Usually no steroids ⁴⁰ 4. May cycloplege if large abrasion => decrease risk of possible uveal response ⁴⁰ 5. Discontinue. lens wear permanently ⁴¹

EPITHELIAL STAINING / MECHANICAL TRAUMA (continued)

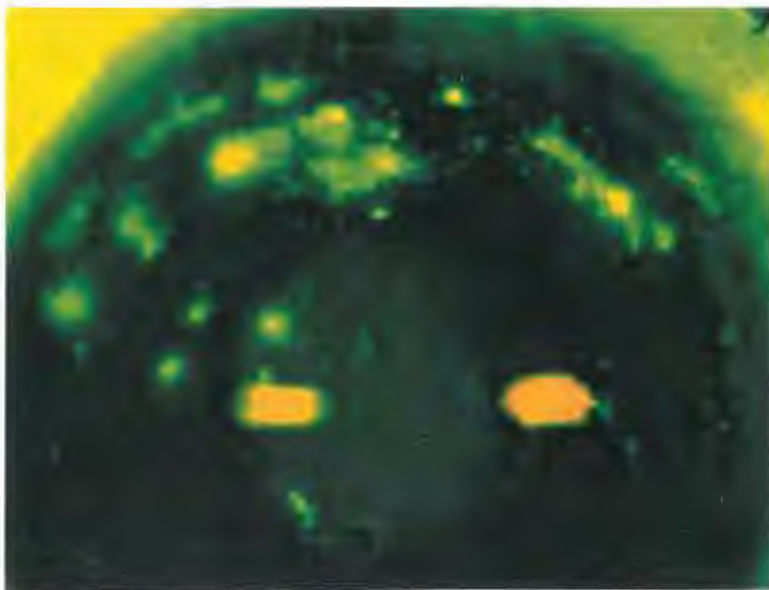


Fig. 35 Back surface debris => corneal staining Grade 3




Fig. 36 Scratched and Protein deposited lens.

EPITHELIAL STAINING - MECHANICAL /TRAUMA (continued)

PREVENTION:

- A. Educate patient re: symptoms.
- B. Immediate lens removal for the previously described signs and symptoms; seek professional care as necessary.⁴¹
- C. Good insertion and removal techniques (short nails).
- D. Good cleaning regimen to prevent build up of protein or formation of jelly bumps (SCL).⁴¹
- E. Careful application of mascara.
- F. Proper lens handling (prevent damage to the lens).⁴¹
- G. RTC - with continued pain.
- with blurred vision 2-3 days.⁴⁷
- H. Evaluate cornea prior to CL fit.⁴¹

PROGNOSIS:

- A. Good if staining resolves quickly.
- B. Moderate to poor if abrasion is deep and staining continues.
- C. Risk of recurrent corneal erosion.⁴⁷
- D. Healing power greater with younger patients than older.⁴⁷

2. EPITHELIAL STAINING - TOXICITY: Toxicity is a form of chemical trauma that causes a diffuse pattern keratopathy.^{11,41}
The main chemical involved in most CL related chemical toxicity is benzalchonium chloride (BAK)

Associated with

1. use of contact lens solutions
2. use of antibiotics
3. poor technique in cleaning regime

ETIOLOGY

A. Contributing Factors

1. improperly neutralized hydrogen peroxide (H₂O₂)
2. primarily (BAK) found in CL solutions and eye lubricants⁴¹ but other cationic preservatives such as chlorhexidene gluconate (CHG) and alkyltriethanol ammonium chloride (ATAC)
3. SCL > RGP
4. topical antibiotics⁴⁶ - e.g. sulfa, neomycin
5. SCL stored in cationic preserved solution:
 - a) becomes impregnated with the solution and acts as a reservoir so when the lens is placed on the eye, it results in prolonged chemical contact⁴³
 - b) binds to protein deposits on the lens as well as to the lens material itself
6. failure to rinse or neutralize CL prior to insertion¹¹
7. increased protein on lens => increased binding of chemicals to CL¹¹

SYMPTOMS

- A. Sting/burning with lens insertion¹¹
- B. Bilateral Conjunctival hyperemia^{11,43}
- C. Foreign body sensation, lacrimation⁴³

SIGNS

- A. Superficial punctate keratitis:¹¹
 1. central cornea - mild keratitis
 2. whole cornea - moderate keratitis
 3. confluent - severe keratitis
- B. Onset - few hours => weeks => several months¹¹
- C. Pseudodendritic epithelial lesions (usually bilateral)⁴¹

EPITHELIAL STAINING / TOXICITY

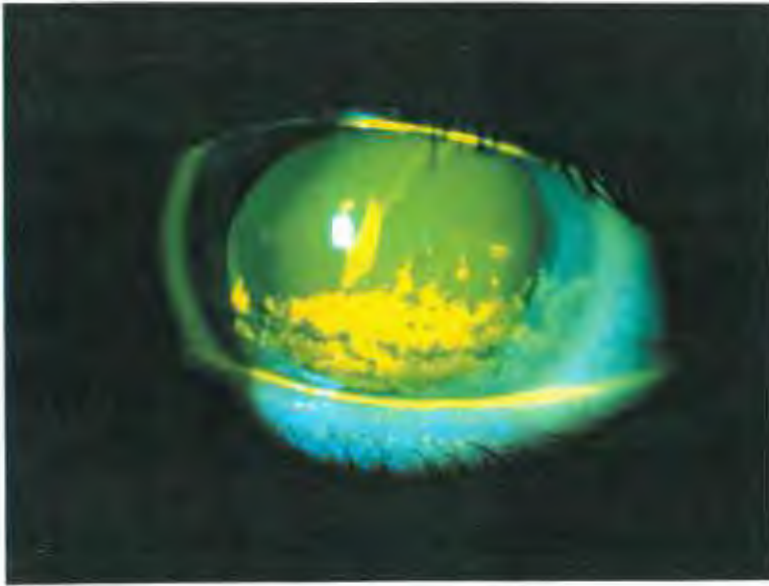


Fig. 37 BAK toxicity
Grade 3

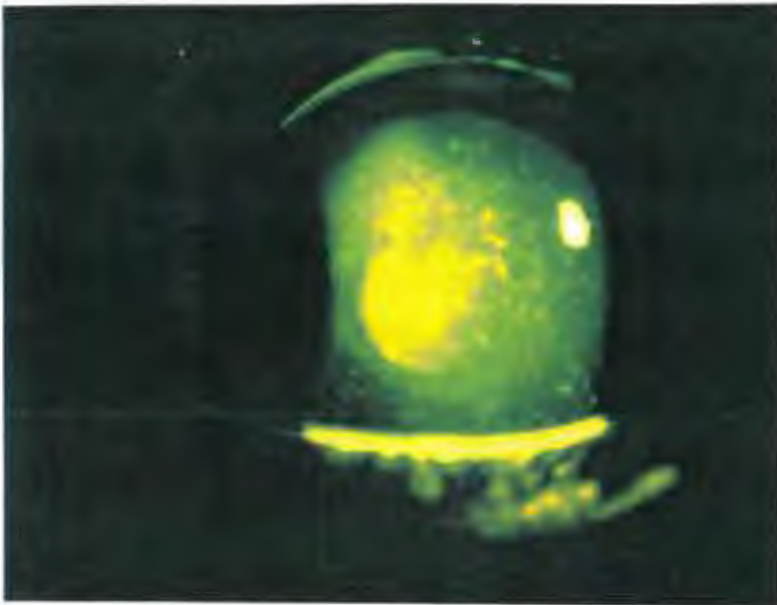


Fig. 38 BAK toxicity
Grade 4

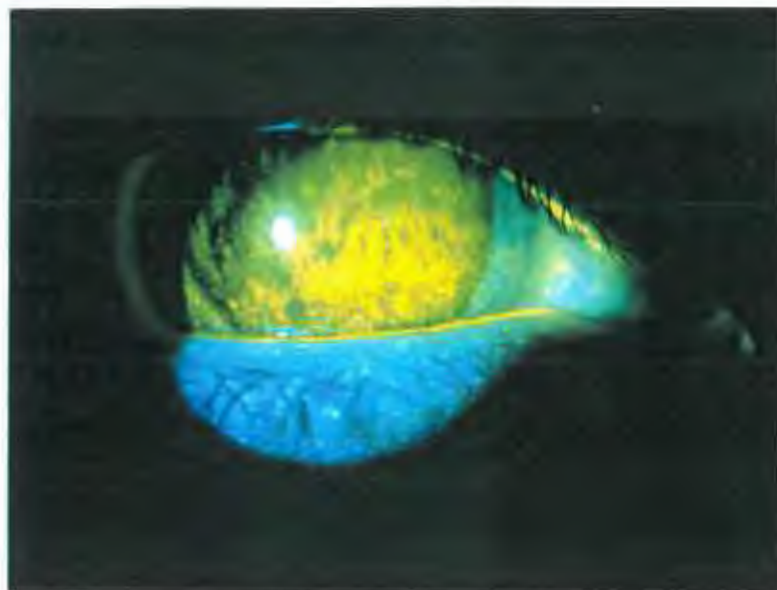


Fig. 39 toxicity
SPK
RGP in place
Grade 4 (area)

EPITHELIAL STAINING - TOXICITY (continued)

GRADES AND TREATMENT

<u>Grade</u>	<u>Signs and Symptoms</u>	<u>Treatment</u>
0	Normal conjunctiva with no corneal staining	No treatment
1	- Mild hyperemia (bilateral), - Stinging with lens insertion	1. Monitor 2. Rinse lens well prior to lens insertion ⁴³
2	- Sting/burn with lens insertion - Superficial punctate keratitis in central cornea area - Mild chemosis	1. Identify and remove toxin ⁴³ 2. Rinse lens well prior to lens insertion 3. Change to preservative free solutions
3	- Follicles - Foreign body sensation /lacrimation - Possible pseudo dendrites - Superficial keratitis	<u>As for Grade 2 plus:</u> 1. Discontinue lens wear until stain resolves ^{43,45} 2. New uncontaminated lens (SCL) ^{4,45}
4	Confluent superficial keratitis	<u>As for Grade 3 plus:</u> 1. Topical antibiotics

PREVENTION:

- A. Educate patient re: rinsing SCL well before insertion.
- B. Educate to early signs and symptoms of toxicity.
- C. Prescribe preservative free care system.

PROGNOSIS:

- A. Good - fast recovery following removal of causative agents.⁴³
- B. If lens worn during recovery period - slower recovery.⁴³
- C. Grade 1-2 will resolve in few days.

EPITHELIAL STAINING / PHYSIOLOGICAL

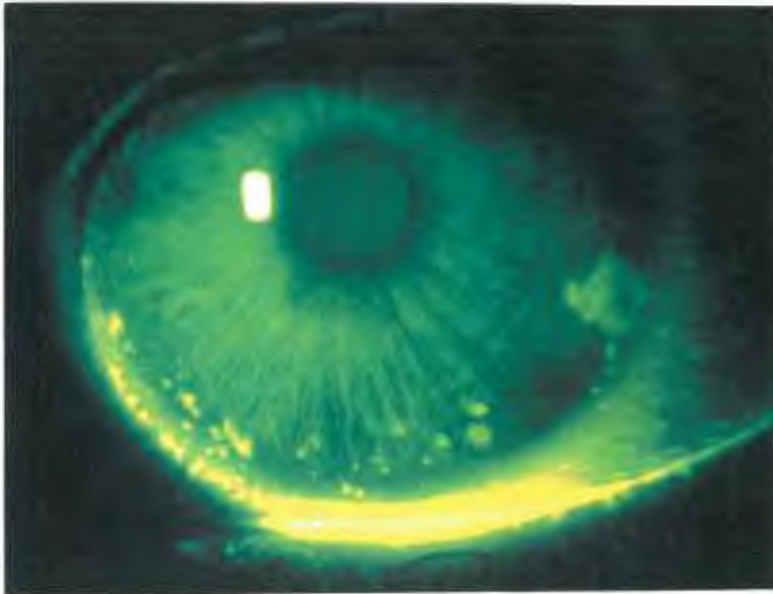


Fig. 40 Exposure 3
and 9 o'clock
staining
Grade 2 Inferior
Grade 3 Nasal
Grade 3 Overall

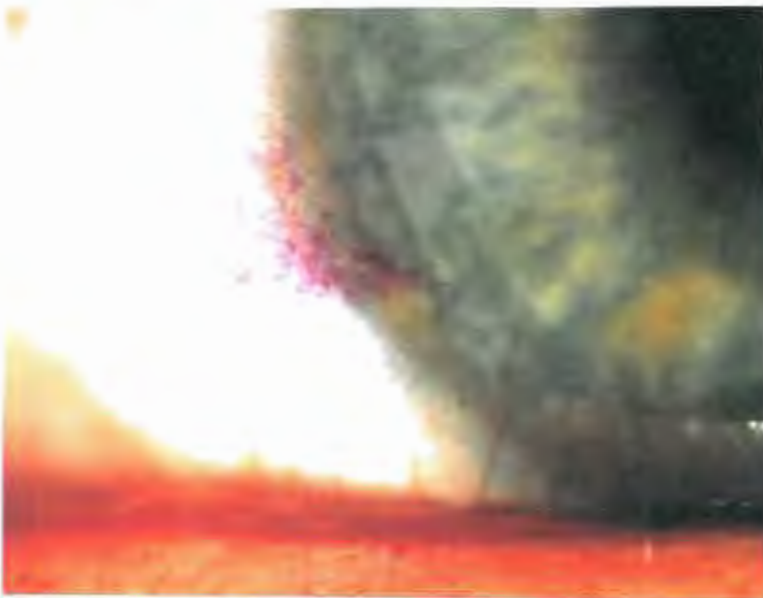


Fig. 41 Exposure
rose bengal
staining at 3
o'clock

3. EPITHELIAL STAINING - PHYSIOLOGICAL: the anterior surface of the corneal epithelium becomes disrupted due to chronic metabolic stress^{4,11,40}
- two examples of physiological trauma leading to epithelial stain are:
1. Epithelial Microcysts (see section titled "Epithelial Microcysts")
 2. Soft lens anterior chronic hypoxia (SLACH) syndrome - hallmark of this syndrome is microcystic corneal edema⁴⁸
 - associated with;
 - a. daily wear soft contact lens
 - b. corneal hypoxia^{11,48}

SYMPTOMS

- A. Earliest sign - blurred vision⁴⁸
- B. Mild foreign body sensation with lens on
- C. Tearing, moderate to severe pain upon lens removal and photophobia
- D. Bilateral/asymmetrical

SIGNS

- A. Circular epithelial defect with surrounding microcystic edema⁴⁸
- B. Fluorescein staining seen as irregular shaped defects⁴

GRADING - none

TREATMENT

- A. Discontinue lens wear until there is no longer any staining⁴¹ and epithelium shows uniform wetting.
- B. Dilate⁴⁸ (to decrease risk of iritis occurring).
- C. Prophylactic antibiotics.
- D. Analgesics - oral.
- E. Pressure patch is contraindicated⁴⁸ - due to decreased oxygen to the cornea when it is already hypoxic.
- F. Refit with new lens with increased Dk/L.⁴⁰
- G. Refit with RGP.⁴⁰

PROGNOSIS:

- A. Fast recovery with immediate and appropriate treatment.
- B. Early diagnosis will:⁴⁸
 1. Decrease length of time patient experiences discomfort.
 2. Decrease risk of corneal infection.
 3. Recurrence of SLACH is common even when refit with high water content lenses.⁴⁸

4. EPITHELIAL STAINING - DESICCATION: - Desiccation is the drying out of the corneal epithelium cells leading to the disruption and or death of these cells. The focal depletion of the tear layer causes corneal epithelial cell desiccation as these cells are no longer protected by the tears¹¹. This allows fluorescein to enter the damaged epithelial cells and penetrate deeper into the stromal cells allowing observation of punctate staining⁴

Associated with:

1. RGP wear
2. dehydration with SCL
3. dry eye
4. exposure

SYMPTOMS

- A. Asymptomatic⁴
- B. Mild discomfort, burning, stinging
- C. Moderate conjunctival injection - associated with 3 and 9 o'clock staining

SIGNS

- A. If condition persists;
 1. pseudopterygia
 2. limbal inflammation
- B. Mild superficial => coalesced stain with fluorescein in specific patterns as indicated below.¹¹

RGP:

- A. Large, base-in triangles diffuse stain due to the incomplete wetting of the cornea adjacent to the lens edge, nasal and temporal area⁴
- B. Characteristic in form and known as "3 and 9 o'clock" stain^{4,11,41}
- C. Stain may vary from mild diffuse punctate spots to coalesced lesions
- D. Occurs with PMMA and other RGP lenses including silicone¹¹
- E. May progress to hyperplasia, infiltration, vascularization (vascularized limbal keratitis (VLK))⁴⁹

SCL

- A. Commonly associated with thin, high water contact lens¹¹ as the lens dries out, it pulls the fluid out of the cornea to osmotically maintain a balance
- B. Seen almost 100% of the time with ultra thin, high water contact lens with moderate minus Rx¹¹

EPITHELIAL STAINING - DESSICATION (continued)

SIGNS (continued)

SCL (continued)

- C. Seen with other designs of contact lens although less frequently¹¹
 - 1. thin, high water content, parallel sided contact lens
 - 2. ultra thin, low water contact lens
 - 3. thick, high water contact lens
- D. Characteristically, the epithelial erosions have a coarse punctate appearance and may be referred to as "flake-like", or "crumb-like"¹¹ They are usually localized and appear to be mild and superficial no with fluorescein staining, but there are cases where they have penetrated the full thickness of the epithelium and stroma and staining is seen¹¹
- E. Staining may appear anywhere in central or para-central areas of the cornea¹¹

DRY EYE

- A. Commonly seen in patients with a poor tear layer or decreased TBUT
- B. May be seen in patients with collagen disease such as rheumatoid arthritis, arthritis, Sjorgen syndrome
- C. Seen as generalized superficial punctate staining, usually inferior⁴¹

EXPOSURE

- A. Commonly due to incomplete blink with both SCL and RGP
- B. The lower part of the lens dries out the most frequently even when there is adequate blinking
- C. Seen as coarse punctate staining in an arcuate or band staining across the inferior cornea (lower 1/3 of the cornea)

GRADES AND TREATMENT

<u>Grade</u>	<u>Signs and Symptoms</u>	<u>Treatment</u>
0	No staining	No treatment
1	Decreased TBUT x < 10 seconds - History of collagen disease	1. Monitor 2. Lubricant (Dry Eyes)

EPITHELIAL STAINING / DESSICATION




Fig. 42 SPK
Dehydration
Grade 2
(central)




Fig. 43
Conjunctival
staining
Grade 4

EPITHELIAL STAINING - DESSICATION (continued)

GRADES AND TREATMENT (continued)

<u>Grade</u>	<u>Signs and Symptoms</u>	<u>Treatment</u>
2 (cont.)-	Mild punctate stain superficial epithelium	<ol style="list-style-type: none">1. Discontinue lens wear until there is no staining^{41,4}=> resume wear2. Artificial tears3. Modify edge of RGP^{11,41}4. Lenticulate high minus⁴5. Blend to increase tear exchange6. Educate patient regarding full blink7. Lubricants⁴¹
3	<ul style="list-style-type: none">- Moderate, full thickness punctate stain- Mild discomfort- Moderate conjunctiva infection- Grade 1-2 limbal infection	<p><u>As for Grade 2 plus:</u></p> <ol style="list-style-type: none">1. Refit with smaller OAD2. RGP lens for 3and9 o'clock stain¹¹3. Discontinue ultra thin, CL and refit with thicker, high Dk/L lens4. Refit with low water content lens (LWC) thinner edge (RGP)
4	<ul style="list-style-type: none">- Severe punctate stain =>coalesced => +/- ulcer⁴- Moderate discomfort +/- pseudopterygium- Grade 2-3+ limbal infection with RGP	<p><u>As for Grade 3 plus</u></p> <ol style="list-style-type: none">1. Discontinue CL wear until staining is resolved.⁴¹ Then resume wear and refit with;<ol style="list-style-type: none">a. thinner edges (RGP)b. smaller OAD (RGP)c. thicker, high Dk/L (SCL)d. LWC (SCL)2. Artificial tears/ Lubricants3 Educate pt. re: full blink⁴4. If ulcer refer out5. Do culture and sensitivity6. Prophylactic antibiotics monitor daily until ulcer resolves7. Permanently discontinue. CL wear

EPITHELIAL STAINING DESSICATION (continued)

PREVENTION:

A. Routinely stain patients who wear contact lens at each visit/a.m. and p.m. visits regardless of the type of lens they are wearing.

B. Prior to fitting CL - assess:

- | | | |
|-----------------------------|---|-----------------------------|
| 1. tear layer ⁴¹ | \ | |
| 2. TBUT ⁴¹ | \ | -----to ensure that all are |
| 3. blink rate ⁴¹ | / | within normal ranges |
| 4. lid action ⁴¹ | / | |

C. Also Assess:

1. history of collagen diseases (arthritis)
2. history of dry eye, allergies, current medications
3. previous successful/unsuccessful contact lens wear

A CAREFUL ASSESSMENT OF PATIENTS OCULAR AND SYSTEMIC HEALTH MAY ALLOW YOU TO RULE OUT UNSUCCESSFUL CL WEARERS PRIOR TO PRESCRIPTION AND SUBSEQUENT DIFFICULTIES.

PROGNOSIS:

A. With RGP:

1. Good with refit with thinner edges, moderate edge lift and smaller OAD.

B. With SCL:

1. Good with thicker or low water content (LWC) lenses.

C. With Dry Eye:

1. Fair.
2. Slow recovery.
3. May reoccur with high water contact (HWC), low water content (LWC) or no lenses.

D. With Exposure:

1. Fair.
2. Slow recovery.
3. Teach patient to make frequent full blinks lubricants/artificial tears.

BIBLIOGRAPHY

1. Efron N. Vascular response of the cornea to contact lens wear. *J Am Optom Assoc* 1987;58(10):836-846.
2. Jantzi JD, Jackson WE, Smith KM. Corneal vascularization in a group of soft contact lens wearers: prevalence, magnitude, type and related factors. *C.J.O Winter* 1987;(49):4 ;174-184
3. McMonnies CW. Corneal vascularization, In: Bennett E, Weissman B, eds. *Clinical contact lens practice*, JB Lippincott, Philadelphia, 1991: pp 1-9.
4. Efron N, Holden BA. A review of some common contact lens complications part 1- The corneal epithelium and stroma. *Optician* 1986 Aug:21-26.
5. Holden BA, Sweeney, Swarbrick HA, Vannas, Antti, Nilsson KT, Efron N. The vascular response to long term extended contact lens wear. *Clin and Exper Optom*, 1986 May: 69 (3):112-119.
6. Robin JF, Schanzlin DJ, Verity SM, Barron BA, Arfa RC, Suarez E. Peripheral corneal disorders. *Surv Ophthalmol* 1986 69(1):20-21.
7. Schnider CM. Keratitis. In: Tomlinson A, ed. *Complications of contact lens wear*. Mosby Year Book, St. Louis, 1992: pp 105-122.
8. Bergmanson J. Contact lens-induced epithelial pathology. In: Bennett E, Weissman B, eds. *Clinical contact lens practice*, JB Lippincott, Philadelphia, 1991:1-15.
9. Zantos SG. Ocular debris and corneal microcysts associated with extended wear of contact lenses. *New Engl J of Optom* 1984 34(4):1-5.
10. Grant T, Kotow M, Holden B. Hydrogel extended wear: current performance and future options. *Contax* 1987 May:5-8.
11. Bruce A, Brennan N. Corneal pathophysiology with contact lens wear. *Surv of Ophthalmol* 1990 July/Aug;35(1):25-51.
12. Sibert JA. Contact lens related inflammatory reaction. In: Bennett E, Weissman B, eds. *Clinical contact lens practice*, JB Lippincott, Philadelphia, 1991:1-9.
13. Leiblein JS. Benefits and risks of extended wear. *Contactlens forum* 1986:45-48.
14. Josephson J, Zantos S, Caffery B, Herman J. Differentiation of corneal complications observed in contact lens wearers. *J Am Optom Assoc* 1988 Sept;59(9):679-685.

BIBLIOGRAPHY (continued)

15. Gordon A, Kracher GP. Corneal infiltrates and extended wear contact lenses. *J Am Optom Assoc* 1985;56(3):198-201.
16. Efron N, Holden BA. A review of some common contact lens complications part 2- The corneal endothelium and conjunctiva. *Optician* 1986:Sept:17-29.
17. Dart JKG. Contact lens associated giant papillary conjunctivitis. *Contax* 1986 Nov:6-11.
18. Kame RT. Clinical management of hydrogel induced edema. *Amer J Optom Physiol Optics* 1976;53(9):468-473.
19. Katz HH. A hypothesis of the formation of vertical corneal striae as observed in the wearing of softlens contact lenses and keratoconus. *Amer J Optom Physiol Optics* 1976;53(8):420-421.
20. Korb DR, Allansmith MR, Greiner JV, Henriquez AS, Richmond P, Preston P, Finnemore VM. Prevalence of conjunctival changes in wearers of hard contact lenses. *Amer J Ophthalmology* 1980;90(3):336-341.
21. Kerns RL. A study of striae observed in the cornea from contact lens wear. *Am J Optom Physiol Optics* 1974;51(12):998-1004.
22. Polse KA, Sarver MD, Harris M. Corneal edema and vertical striae accompanying the wearing of hydrogel lenses. *Am J Optom Physiol Optics* 1975;52(3):185-191.
23. Wechsler S. Striate corneal lines. *Am J Optom Physiol Optics* 1974;51(11):852-856.
24. Wechsler S. Striate corneal lines among patients wearing conventional contact lenses. *Am J Optom Arch Amer Acad Optom* 1972;49(2):177.
25. Richmond PR. Giant papillary conjunctivitis: an overview. *J Am Optom Assoc* 1979;50(3):343-347.
26. Sarver M. Striate corneal lines among patients wearing hydrophilic contact lenses. *Am J Optom and Archives of Amer AcadOptom* 1971;48(9):762-763.
27. Henriquez AS. New information on giant papillary conjunctivitis and corneal infiltrates. *Contact Lens journal* 1987;15(3):3-14.
28. Koetting RA, Castellano CR, Keating M. Control of GPC: a retrospective study. *Contact lens forum* 1986:Volume 11: March:45-47.

BIBLIGRAPHY (continued)

29. Farkas P, Kassalow TW, Farkas B. Clinical management and control of giant papillary conjunctivitis secondary to contact lens wear. *J of Am Optom Assoc.* 986:57(3):197-200.
30. McMonnies CW, Chapman-Davis A. Assessment of conjunctival hyperemia in contact lens wearers- part 1. *Am J Optom Physiol Optics* 1987:64(4):246-250.
31. McMonnies CW, Chapman-Davies A. Assessment of conjunctival hyperemia in contact lens wearers- part 2. *Am J Optom Physiol Optics* 1987:64(4):251-255.
32. Herman JP. Clinical management of GPC - Part II. Contact lens spectrum 1987:2(12):41-43.
33. Allansmith M, Korb DR, Greiner JV, Henriques A, Simon MA, Finnemore VM. Giant papillary conjunctivitis in contact lens wearers. *Amer J Ophthalmol* 1977:83(5):697-708.
34. McGeehon M. Guidelines to handling problem patients. *Contact lens forum* 1988:13(4):23-28.
35. Allansmith M. Giant papillary conjunctivitis. *J Am Optom Assoc* 1990:61(6):S42-S46.
36. Weissman BA, Pearson TR. Clinical management of cosmetic extended wear contact lens failure. *J Am Optom Assoc* 1986:57(6):448-450.
37. Lustine T, Bouchard CS, Cavanagh HD. Continued contact lens wear in patients with giant papillary conjunctivitis. *CLAO journal* 1991:17(2):104-107.
38. Waring G, Rodriques M. Patterns of pathological response in the cornea. *Surv of ophthalmol* 1987 Jan/Feb: 58(1):262-266.
39. Klein P, Solomon J, Snyder. Non infectious corneal vascularization. *J Am Optom Assoc* 1987:58(1):47-49.
40. Bergmanson J. Contact lens-induced epithelial pathology. In: Bennett E, Weissman B, eds. *Clinical contact lens practice*, JB Lippincott, Philadelphia, 1991:1-15.
41. Lohman L. Corneal epithelial response to contact lens wear. *CLAO Journal*, July, 1986:12(3):153-156.

BIBLIOGRAPHY (continued)

42. Dunn J, Mondino B, Weissman B. Immunologic complications of contact lens wear. In: Bennett E, Weissman B, eds. Clinical contact lens practice, JB Lippincott, Philadelphia, 1991:1-9.
43. Mondino B, Salamon S, Zaidman G. Allergic and toxic reactions in soft contact lens wearers. *Surv of ophthalmol* 1982 May/June:26(6):337-344.
44. Schwaderer KN. Corneal trauma caused by posterior surface soft contact defects. *Inter Eye Care* 1986:2:233.
45. Gordon A. Prospective screening for thimerosal hypersensitivity: a pilot study. *Amer J. Optom Physiol Optics* 1988:65(3):147-150.
46. Wallace W. Ocular allergy. *Inter Eye Care* 1986 2(8)444-445.
47. Voke J. Complications of corneal trauma. *Optician* 1987 Apr 17:22-24.
48. Wallace W. The SLACH syndrome. *Intern Eye Care* :1(3):220.
49. Grohe R, Lebow K. Vascularized limbal keratitis. *ICLI* July/August 1989 7&8(16):197-207.
50. Mandell R. Contact lens practice. C. Thomas, Springfield, Illinois, 1988:400.