

## CASE OF BONE TRANSFERENCE.

USE OF A SEGMENT OF FIBULA TO SUPPLY A DEFECT IN THE TIBIA.

BY THOMAS W. HUNTINGTON, M.D.,

OF SAN FRANCISCO,

Professor of Surgery in the University of California.

THE following case illustrates the possibility of supplying a tibial defect amounting to absence of nearly the entire diaphysis by the appropriation of a corresponding portion of its companion, the fibula.

In a paper published in the *Journal of the American Medical Association*, February 3, 1904, Nichols, of Boston, discussed this subject very ably and at great length. In this paper the author reported eleven cases, showing that in many instances, particularly where the defects were of minor dimensions, by preserving the periosteum, there was complete reproduction of bones with the attainment of satisfactory results so far as weight-bearing and function were concerned. Two of Nichols's cases were similar to my own, in that there was almost entire loss of the diaphysis of the tibia. In the first of these cases, after four months, a radiogram showed nearly complete regeneration of the shaft, but with a conspicuous deformity due to marked anterior bowing. At this time the patient disappeared, and there was no record as to functional end result. The second case was reported as a functional failure after the lapse of several years.

In entering upon this undertaking, I recognized that a central segment of the fibula firmly fixed to the tibia at both ends by bony union would carry with it its own nutrient supply, and that this would be largely increased by the more generous nutrition of the host. Assuming this to be true, I reasoned that the bridge of fibula so formed would rapidly expand, and in reasonable time approximate the dimensions of the larger bone,

thereby insuring a satisfactory condition as regards weight-bearing.

Furthermore, I believed that, as the important relations of the lower extremity of the fibula were to remain undisturbed, the integrity of the ankle-joint would be preserved and locomotion be unimpeded.

The early history of the case is that of an acute, infectious, osteomyelitis of the left tibia. The patient was a lad of seven years, who entered the City and County Hospital of San Francisco in May, 1902. Family history was unimportant. The trouble began a few days before entrance. At that time, while at play, he sustained a slight injury to the left leg just below the knee. Leg became swollen, tense, and acutely tender. There was high temperature succeeding a chill. The attending physician made a small incision about three inches below the knee, from which, at time of admission, there flowed a small amount of clear yellow fluid. Tibia was extensively denuded, and near the ankle there were two red fluctuating areas. An incision along the spine of the tibia from the tubercle to one inch above the ankle-joint revealed the fact that nearly the entire shaft was disintegrated. Pus oozed through several sinuses leading to the medullary cavity. On stripping the periosteum, the cortical portion of the bone was readily scooped out with a eurette, leaving a trough of periosteum. Having in mind the possibility of bone reproduction, the periosteum after being carefully cleansed was stitched into a tube of small caliber. The wound was drained, partly closed, and the leg laid upon a posterior splint. For three months there was gradual and satisfactory progress and the wound was fully healed. Six months later, despite an apparent effort on the part of nature to reproduce the tibia, there was still an interval of about five inches between the upper and lower fragments, and progress in this direction seemed to be practically suspended. At this time the leg could not be extended upon the thigh, but hung loose, flail-like, and utterly useless. (This is shown in the small photograph, Fig. 1.)

On January 27, 1903, I finally determined to supply the defect by sawing the fibula at a point opposite the lower end of the upper tibial fragment and attaching it thereto. This was done without difficulty, and the divided end of the fibula was firmly




FIG. 1.—Condition on admission.

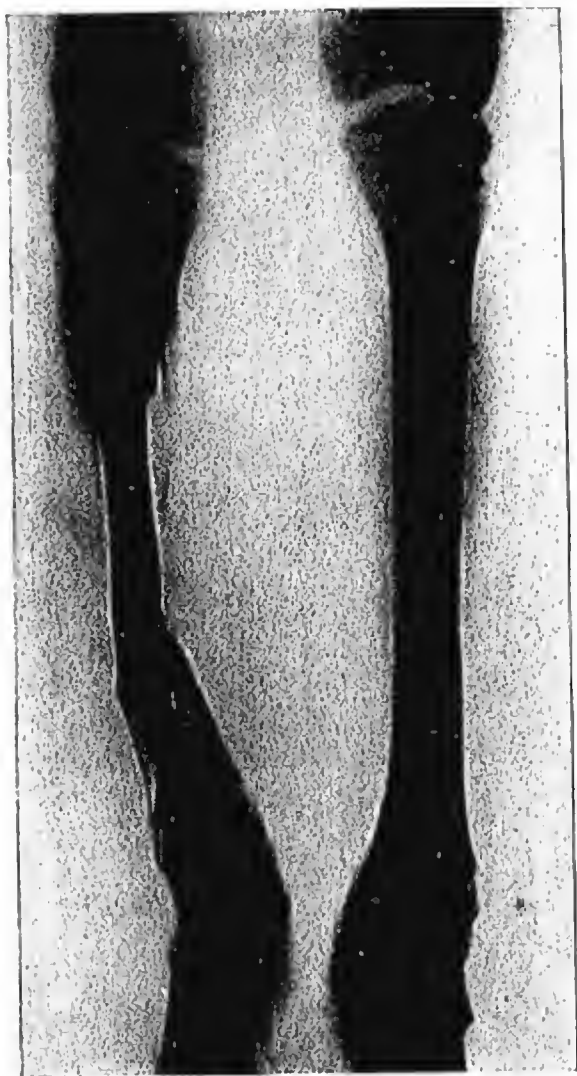


FIG. 2.—Radiogram showing condition of bone eight months after operation.



FIG. 3.—Radiogram showing condition thirteen months after operation.

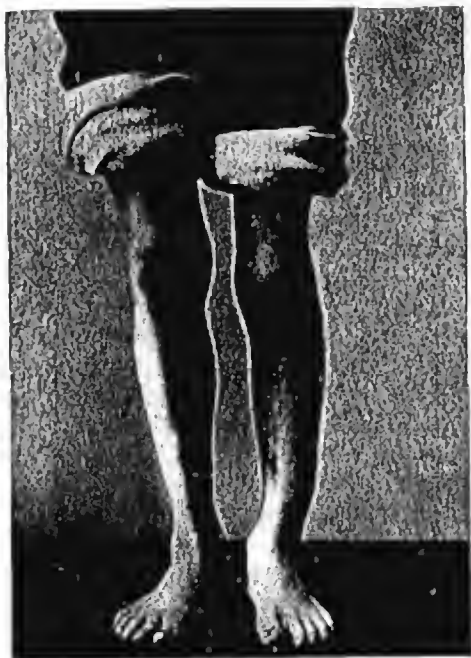

FIG. 4.—Condition on discharge.

planted in a cup-shaped depression in the tibia, as above described. At this time the diameter of the fibula was about that of an ordinary lead-pencil, or approximately one-third of the diameter of the normal tibia at a corresponding point. Union was tolerably slow, but solidification was finally noted six months later, July, 1903.)

The following note was made September 20, 1903: "The lad walks with the limb encased in two lateral splints as a support to the ankle-joint, there being a tendency for the foot to evert when the patient stands upon the affected member." (The then condition is shown by the radiogram, Fig. 2.)

Not satisfied with the weight-bearing condition at that time, I concluded to transfer the lower end of the fibula to the lower fragment of the tibia, which was done October 6, 1903. At this time it was noted that, during the six months when the lad walked with slight foot eversion, there was effected a permanent change in the conformation of the tarsus, resulting in an outward alignment of the axis of the lower fragment of the tibia. It was impossible to correct this condition, and a noticeable deformity in the present contour of the limb finds its explanation in this fact. The operative wound healed kindly, and on February 15, 1904, perfect bony union was secured. (See radiogram, Fig. 3.)

Since that time the patient has progressed admirably. The limb, though three-quarters of an inch short, has assumed the dimensions and in a general way the contour of the normal member (Fig. 4). Careful measurement of the transferred portion of the fibula shows that its diameter is now three-quarters of an inch, or practically the same as the opposite tibia. The lad goes to school, plays ball, and joins in the ordinary sports of other boys, and, despite the lateral deformity and slight shortening, he walks without support and with only the suggestion of a limp.

In a similar case I should certainly insist upon the affected member being kept at rest until the second transposition could be effected, thereby avoiding the deformity, which is the only serious defect in this case. Considering the extensive destruction of the tibia which occurred prior to his admittance to my service, I can conceive of no other method which would have offered a result in any sense so satisfactory as the one adopted.