

The Journal of the American Medical Association

Vol. XXI.

CHICAGO, JULY 29, 1893.

No. 5.

ORIGINAL ARTICLES.

BRAIN SURGERY, WITH REPORT OF NINE CASES.

Read in the Section on Surgery and Anatomy, at the Forty-fourth Annual Meeting of the American Medical Association.

BY F. C. SCHAEFER, M.D.

Prof. of Clinical Surgery, Northwestern University Medical School;
Prof. of Surgery, Woman's Medical College; Surgeon
to Wesley Hospital, Chicago.

My subject might perhaps have been named more appropriately cranial surgery, as I wish to report nine cases of injury to the head; all of them, however, interfered with the function of the brain, and in three of them there was actual destruction of brain tissue. Of these nine cases, four recovered completely, one improved so much, that we have reason to believe that he will in the course of time, recover sufficiently to be of some use to his family. Four died. As we have yet much to learn concerning the diagnosis and management of injuries to the head, and as all of them have their own peculiarities to a certain extent, it seems to me an accurate report of such cases will be of advantage to us; and undoubtedly we will have to depend largely upon clinical experience for the advancement of this work in the future. This, then, is my apology for occupying your valuable time:

Case 1.—Boy aged 10 years, fell during February, 1880, from a depot platform, striking his head against the corner of a fire-box of the wheel of a freight car. I saw him an hour later; he was in a comatose condition, motionless with a large, full, slow pulse, and stertorous breathing. There was an extensive contused and lacerated wound of the scalp, over the middle portion of the right parietal bone exposing the skull. After thoroughly cleansing the wound, having shaved the hair from the scalp, I enlarged the opening and found a depressed, stellate fracture. The skull was unusually thick for a boy of his age, 3-16 inch. The fracture presented five points at its center, all coming together, converging like the spokes of a wheel, at the center of an irregular circle two and a half inches in diameter. There were therefore five irregular triangular pieces of bone. Each triangular segment was attached at its base, but all of them had their outer table cracked where they joined the body of the bone. Their apices were depressed fully a third of an inch. In order to elevate the pieces I trephined through the base of one of them, then succeeded readily in replacing all. The dura mater was contused, cerebral pulsation absent before the operation. Restoration of the bone to position was followed by immediate return of functional action. The little fellow talked freely and told how he fell. The scalp was stitched with silk, dressed antiseptically; the patient was left in bed, in a quiet room for about ten days. The wound healed by first intention. The button of the bone was not replaced. The boy is well.

Case 2.—Boy 7 years old, October, 1889, fell from a loft in a livery stable, striking upon a heavy plank floor with the back of his head. Was carried home in an uncon-

scious condition; saw him an hour and a half later. His pulse was full and large, 68. Breathing stertorous; pupils dilated. There was a large swelling over the occipital bone, above the superior curved line, extending two inches to the right and one inch to the left of the occipital protuberance. The scalp was severely bruised and raised by a hematoma. Anæsthesia was unnecessary. I cut through the scalp and periosteum making a curved incision two inches long with its convexity downwards. The blood immediately rushed out; the patient moved his limbs at once, gave a cry and waked up as from a dream. I quickly examined the skull and found a transverse crack two inches long, about half an inch above and running parallel with the deep curved line of the occipital bone, extending more to the right than left side of the median line. The thin bone had been depressed by the blood between it and the periosteum, and had sprung back into position when that pressure was removed.

Ten minutes after the operation the boy related how the accident occurred. Within a week he was again playing upon the street.

Case 3.—Wm. — aged 11 years, while visiting in the country a hundred miles from Chicago, July, 1887, fell from an apple tree a distance of twelve to fourteen feet. His father having been telegraphed for, came to have me accompany him to see his boy. Not finding me at home, he took another surgeon with him. The city surgeon arrived at the patient's bedside ten hours after the accident occurred. In the meantime, the mother who was with the boy, called a local doctor who found a large oval swelling in the left temporal region, together with contusion of the scalp here. The boy was unconscious. The physician said he was suffering from concussion of the brain; did not think there was a fracture. The Chicago surgeon agreed with the attendant, concluded that there was nothing to do except to let him rest and applying a liniment to the wound, returned home. The patient remained unconscious for forty-eight hours, then becomes semi-conscious; at the end of a week he "woke up" as his mother said. During this week his bowels were constipated, and urine had to be drawn. After six weeks the child was brought home and I was called to treat him for a headache. At this time a ridge could be plainly felt in the middle of the fossa of the squamous division of the temporal bone, running parallel with the zygomatic process. What a chance the surgeon missed here of making a brilliant cure with one stroke of the knife! Undoubtedly the large swelling in the region was caused by a rupture of one of the deep temporal arteries or from the bone. The blood was boxed in by the unyielding temporal fascia and pressed the cracked bone against the dura mater and brain. The pressure symptoms disappeared with the absorption of the clot, the bone retaining sufficient elasticity to spring out. At the time of my visit, the child was afflicted with a slight frontal headache and enteritis; the parents imagined that the injury might have had some relation to this condition, which fortunately proved not to be the case, as he made a prompt recovery.

Case 4.—A gentleman aged 45 years, engineer, was

found lying on his back on the floor, in close apposition to the cube-shaped stone supporting a portion of a stationary engine, with a step ladder standing near. He was unconscious when a homeopathic physician came to see him. He was placed upon a stretcher, and examined by the doctor who found a scalp wound one and a half inches in length over the right half of the occipital bone, which he washed, stitched and dressed. The patient was taken home and looked after by this physician. It happened that this man carried an accident insurance policy, and in the natural course of events the insurance company sent their surgeon to look after the interests of the patient, or more properly stated, their interests. The company's surgeon called twenty-four hours after the man was sent home. Not knowing who or where the attending physician was at that time, he asked permission of the man's wife in behalf of the company to see the patient. The permission was granted. The doctor quickly examined the case. Found pulse 48 large, full, laborious. Pupils dilated widely. Stertorous breathing. The bladder filled to distention. He did not stop to open the bandages, but at once drew off a quart of urine from the bladder, and went in search of the doctor. Did not find him until the next day. On the fourth day the company's surgeon suggested a consultation be held with a regular surgeon, promising that the company would bear the expense. The attendant was willing to have a homeopathic surgeon. In order to pacify him the company's physician said, you may have your homeopath, but let me bring a "regular surgeon" and the company will pay both. He finally consented to let the company's doctor bring a surgeon to see the case with him. The doctor called me on the sixth day; I found a pin head opening in one end of the scalp wound, through which my probe entered readily, and I felt the rough outlines of a fracture. Gave it as my opinion that there was either a clot or depressed bone causing the symptoms. The homeopath's attention was called to it, but he claimed that there was no fracture and held a consultation with one of his guild, who agreed with him. The man's wife said she wanted her husband let alone with her homeopathic doctor and wanted no more physicians to trouble him. Of course I advised operation, but at the same time was guarded as to the prognosis, saying the clot might be absorbed, or possibly the bone might spring back into position and the patient make a recovery. If it was a clot there would be more hope, but it would take considerable time. In the meantime, however, I felt he was being permitted to take too great a chance. Be that as it may, two weeks later Dr. J. R. Corbus (who represented the company) said that the patient seemed to be gradually improving, although his urine still had to be drawn. Six weeks later was able to sit up. His right eye was much weaker than the other. In fact he could not see clearly with it. Motion in one leg was somewhat impaired. After six months he began to walk about, toes of one foot dropped, causing a stumbling motion. The case came to court within a year, as the company refused to pay the homeopathic attendant, claiming that an operation would have resulted in a more rapid cure and that they had been compelled to assume a greater risk than was necessary by the refusal to have proper surgical aid. The attendant made his speech claiming to have cured the patient medically, while Surgeon Schaefer wanted to use the knife. Dr. J. R. Corbus being called to witness stand, was asked what he thought about the case. His reply was: "By the grace of God the patient got well, homeopathy notwithstanding."

Case 5.—A Mr. T. aged 50 years, manager of railroad car shops at the city limits of Chicago, rode home in the baggage car of an express train, as was his wont, at six o'clock one July evening of 1890. The rails spread while the train

was in motion. The gentleman had been sitting in an arm chair, facing the corner of a safe, perhaps a yard distant. As the car left the track he was thrown forward from the chair and struck the corner of the safe with his forehead. The accident occurred about seven blocks from the man's home. He was momentarily stunned, but soon picked himself up and walked home unattended. I saw him an hour later in emergency. His left eyelid was black and swollen. It was seen that the frontal bone was fractured vertically in its left half, from near the inner end of the orbital arch upwards. The left side of the forehead was flattened. He had an unusually large frontal sinus, which made the wound look as if the anterior wall of the left sinus was pressed in. As the man was perfectly rational, showing no symptoms whatever of brain disturbance, it seemed altogether probable that the outer table only was broken. Still I was in favor of cutting down immediately to examine the bone and do what might be necessary. The family were opposed to such action. It was therefore deferred. The next morning a consultation of surgeons was held. The patient was still rational, clear headed, having use of all of his functions, with no indication of compression. Six days later I was invited by the surgeon in charge, my friend Dr. L. McArthur (by whose consent I report this case), to assist in elevating the bone. A change had occurred on this day. His speech was faltering, deglutition difficult, pulse weakening. He was somnolent. An incision revealed the following:

There was a vertical fracture towards the inner end of the left orbital arch extending towards the coronal suture. The external angle of the frontal bone was broken loose from the malar articulation, while this angle had been driven inwards two-thirds of an inch or more. With great difficulty Dr. McArthur pried the angle back into position. Of course this depression implied a fracture of the orbital plate of that side. Two days later I made the autopsy and found what the illustration shows. A transverse fracture extending from the external process of one side to the other, *across the base of the skull*, passing through the orbital plates near the lesser wings of the sphenoid and through the back part of the cribriform plate of the ethmoid. Connecting the ends of the fracture there was a complete fracture of the vertical portion of the frontal bone running parallel with the coronal suture. In addition to these, there were the vertical fracture alluded to connecting with the transverse fracture on the forehead; and three fractures through the left orbital plate, two extending from orbital arch to the transverse fracture within the skull, the other half way back. The triangular shell thus produced at the outer angle of the frontal bone was driven almost an inch into the left frontal lobe. Here the autopsy revealed a large cavity in the brain which had been occupied by the bone. There was a clot in the channel of the cavernous sinus. With this extensive traumatism there were no symptoms of brain injury present until the sixth day.

Case 6.—Boy, W. L., aged 17 months. While playing upon the porch at the back end of a flat, sixteen feet above the ground, suddenly fell down stairs, probably rolled two or three steps, fell seven feet striking the top of a fence with the crown of his head, and dropped from the fence to the ground below five feet which was covered with ice. There he was found a half minute later, lying flat upon his back and head. He was carried to his bed, and a messenger sent for me. A physician happened to be in the building at the time. He was at once called; after looking the child over concluded he was suffering from concussion of the brain. A half hour later I came to him. Examined the child critically. Found he could move his limbs. His pupils responded to the light slowly. For one instant only his left eye was thrown off of parallelism with the other. It quickly moved

into line, however. This at once made me suspicious of brain injury. I then ran my hand over the top and back of the head. The occiput was flattened, while in front of it there was a prominence. The child was drowsy, still could be easily awakened, and had control of its functions. I next walked out to the porch to see how far and where the boy fell. The extent of the fall was so great, that I felt convinced that the skull must be badly fractured. In the absence of grave pressure symptoms, it seemed unnecessary to operate at once. I therefore advised warm fomentation and sedative treatment. Gave it as my opinion that the skull was extensively fractured and said that at the first instant when severe brain symptoms appeared, such as convulsions or paralysis, I would cut through the scalp and do what seemed best. Twenty-four hours later there occurred clonic spasms at the left angle of the mouth. I at once ordered a barber to shave off the hair preparatory to operation. Chloroformed patient; scrubbed head with soap and water; washed with bichloride and ether. Cut through the scalp at a point corresponding to the upper portion of right fissure of Rolando; found an irregular fracture extending to the right and left; followed it up in both directions. It extended to within one-half inch of the right ear, and to within one inch of the left ear running across the back part of both parietal bones. A peculiarity which interested me greatly was the fact that the borders of the broken bone were separated *one-eighth of an inch* which explained to my mind the absence of pressure symptoms from the beginning; the open seam of necessity increased the intracranial area. At the back part and middle the bone was considerably depressed for distance of two inches; at the right side in front of the location for the fissure of Rolando I trephined and found a tablespoonful of clotted blood beneath the dura mater, which membrane was lacerated here. The dura mater was torn in several places and at the middle of the wound, brain tissue lay loose on the seam of fracture. After thoroughly cleaning the entire wound I lifted up the depressed bone, stitched the dura mater, brought the edges together through the entire length of the wound, placed a small drainage tube in two places which were carried through small trephined openings of the skull. Dressed antiseptically. Boy's eyes brightened, responded quickly to light. Improved for twenty-four hours, when his pulse and temperature rapidly crept up and he died on the fourth day, of meningitis.

Case 7.—Wm. N., aged 22 months. Was called to treat this child for a headache in the evening of the fifteenth day. His parents said that he had been sick for about two weeks; the headache came every afternoon at about 2 o'clock, and left him towards midnight. The pulse was small and rapid, 120; temperature 100° F. Eyes responded to the light. The head ached all over the frontal region. Tongue heavily coated. Nothing was said about traumatism. Bowels were constipated. Prescribed bromides, cathartics and quinine. Called the next day at 7 o'clock P. M., found the patient feeling better, pulse a little stronger. Temperature 99° F. Continued bromide of potassium. Third visit, fourth day, 9 A. M. He was slumbering; every now and then he cried out in his sleep. The cry was shrill, as if caused by sharp pain. This set me to thinking. I at once asked the parents if their son had met with an accident recently. They thought not. I asked the question again, saying little ones frequently stumble and fall. The mother then spoke up saying that she remembered that he fell about two weeks ago, but there was no bruise upon him. My next question was who saw him fall? "Freddie, his 12-year old brother." The brother was called. In reply to my question he said that he played with the patient two weeks before, his brother clinging to his

neck and back while he sat on the edge of a lounge; he ducked his head pretending to throw him over his head; did this once too often when the latter slid to the floor head first, striking heavily upon the cranium. This was sufficient. I examined the skull carefully, found a very slight unevenness over the coronal suture of the left side of the head, scarcely perceptible; pressure upon the point caused him to cry the same shrill cry as heard before. Pressed upon a corresponding point of the opposite side but elicited no response. There was no longer any doubt in my mind as to the cause of the origin of the headache.

I immediately informed the father that an incision through the scalp was indicated, to explore the skull and possibly to lift a depressed bone. The father at once repelled the idea, claiming that the child had the headache nearly a week before the accident occurred. Having no time to waste, I advised him to call in another surgeon, and if the latter should agree with me I would go on with the operation; if there was a disagreement he could let the other surgeon take the case. Two surgeons were called, Dr. I. N. Danforth and Dr. McDonald. After hearing the full history of the case and having examined the head, they concurred with me. By this time the boy was very weak; pulse 130, small, temperature 101°. In the meantime the head had been shaved by a barber. I cleaned the scalp and cut down to the bone, making an oval flap. Found a slight fossa at coronal suture, an inch to the right of the median line; the teeth of the suture could be seen obliquely placed. Removed a $\frac{3}{4}$ -inch button. The cerebral pulse was absent. The dura mater looked black. Aspiration drew off a teaspoonful of serum. Opened the dura mater; a tablespoonful of cerebral fluid escaped, with considerable lymph and clotted blood; pulsation was now normal. There was a circumscribed leptomeningitis present. It was thought advisable by all of us to leave a small gauze drain in the wound. I stitched the dura mater and scalp with fine silk; applied usual antiseptic dressings. The headache was relieved; patient's eyes grew clearer, responded promptly to the light. After thirty-six hours his temperature ran up to 102° F.; two days later he died. There was no pus in the wound. He died of leptomeningitis.

Case 9.—Wesley Hospital Record.—Mr. K., aged 47 years. Father died of apoplexy. Mother lived to old age. Lost a sister aged 30 years from consumption. He enjoyed good health up to two years ago. During the fall of 1887 he was sand-bagged and robbed on the street while going home in the evening. Was struck on the head with some metallic instrument. The scalp was torn open to the extent of about an inch, over the upper and middle part of the right parietal bone, extending outwards from near the median line. He was stunned for a few minutes only. The wound was dressed by his wife; it healed in a few days. The patient went to work the morning after the accident and felt as well as usual, barring a little tenderness about the wound. He had forgotten all about this important incident until reminded of the presence of a scar upon the scalp. Two years ago his limbs swelled and a physician said he had Bright's disease. At the same time his head troubled him. Was afflicted with vertigo. There was a constant headache and tenderness on the right side of the skull. After a few weeks of suffering he was suddenly seized with "spasms" of the left side of his face and of the left arm and leg. These spasms began in the left fingers, extended up the arm to his shoulder, next over the entire left leg. His head turned to the left side, and there was a constant twitching at the left angle of the mouth. Lost the use of his limbs for several days after the attack. Could not talk well afterwards; his memory became impaired and sensations were dull on the entire left side from that time on. The convulsions came five times—several months apart—within two

years. Each successive paroxysm was longer and more severe than the preceding one. Had the last attack of the five before entering the hospital a few days before Thanksgiving, 1892, at which time he was almost comatose for thirty-six hours. Since coming here, December 21, 1892, the convulsive seizures have occurred on an average about once in twelve days.

Symptoms during the Seizure.—Clonic convulsions beginning in the second finger of the left hand. Immediately after the "initial" symptom appeared in the finger the convulsions extended to the other fingers, wrist, arm and shoulder in rapid succession, also to the muscles of the face and leg. Teeth came firmly together, causing a "gritting" movement; several times the tongue was bitten. These symptoms of irritation were followed by a period of unconsciousness and hemiplegia, the unconscious state lasting from a few hours to a day. The paralysis only partially disappeared. The limbs could be moved, although he had little use of them. The left hand was closed most of the time; with a little effort he could open it. Hand pressure was very weak compared with the right one. Upon waking he looked dazed. There was almost complete hemianæsthesia, and a constant twitching at the left angle of the mouth; also ataxic and amnesic aphasia. Memory greatly impaired.

Status Presens.—Before operation made the following notes: Is in fair flesh. Presents a "nervous look." Has partial hemiplegia of the left side. Drags the left leg while walking. Carries his left hand closed. Muscular power greatly diminished. Pressure with left hand very feeble. There is limited motion of the left arm. Can lift it to the horizontal with shoulder, slowly; left hand opens halfway slowly. There is almost complete loss of general and tactile sensation. Hemianæsthesia may be said to be almost complete. Is unable to tell which finger or toe is being pricked with a pin. Does not feel it about the face. Our interne, Dr. Boomer, stuck a pin almost through the lobe of the left ear and the patient gave no evidence of having felt it. Touch any portion of the left half of the body and extremities with bottles of hot water, he takes no notice of the heat. A snowball was placed against his left arm, leg and face without his knowledge; he remained ignorant of its presence. Can not add a column of six simple numerals. Does not know the value of the figures. Does not know when he had the last convulsion. Can not remember when his wife called to see him last, although she was here yesterday. His vocabulary is limited. Is afflicted with both amnesic and ataxic aphasia. Speaks a word hesitatingly; seems too tired to speak another; shakes his head; evidently can not think the word. Can not write a connected sentence of five words. Drops one or two words in the effort. L. E.—fundus very much congested; V. 20-60. R. E.—V. 20-20.

On presenting this patient before the class I said the localization symptoms of irritation and of partial destruction are well-marked. There are the local headache, tenderness and pain; the "signal" symptoms as first noticed by his wife, in the left middle finger, followed by clonic convulsions of successive groups of muscles; the hemianæsthesia; tremors at the left angle of the mouth; tetanic contracture of the left levator orbicularis and of the platysma muscles; also the hemiplegia of the left side pointing directly to the right side of the brain as the location of the *fons et origo* of the man's condition. Reading these symptoms in the light of modern pathological knowledge we may feel absolutely sure that there is a lesion about the cortex of the brain corresponding to the right motor area, as mapped out by Ferrier and Horsley.

The history of the case points to traumatism as the origin—causing inflammation, infection, or both, with their sequelæ. There may have resulted thickening of the bone;

possibly a splinter was driven into the brain from the inner table and has led to the formation of a local abscess. There is the possibility of a blood clot alone, or as a complication of the conditions already mentioned.

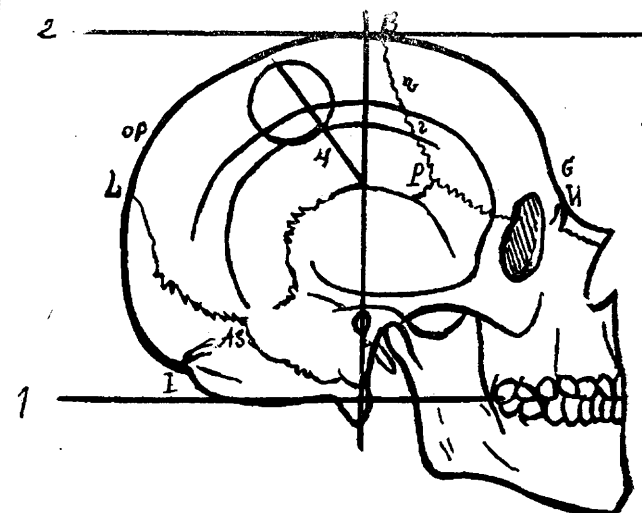


Fig. I.

- | | |
|--------------------------------------|----------------------------------|
| 1. Base line. | I. Inion. |
| 2. Parallel tangent line. | B. Bregma. |
| 3. Bi-auricular. | S. Stephanion Superior. |
| 4. Fissure of Rolando. | S. " Inferior. |
| The circle represents trephine ring, | P. Pteryon, |
| button within. | O. P. Occipito Parietal fissure. |
| N. Nasion. | L. Lambdoid suture. |
| G. Glabella. | |

The patient's head had been shaved and thoroughly scrubbed with soap and water and washed with a bichloride of mercury solution, 1 to 2000. I now took the measurements for locating the fissure of Rolando. My method is to project a base line from the crown of the teeth of the upper jaw backwards, which will cross below the mastoid process on a line with the condyles of the occipital bone. Next a vertical line was carried at right angles with the base line (see Illustration 1,) upwards through the middle of the auditory meatus to the top of the head and parallel with the base line. At a point 6 cm. above the middle of the auditory meatus made a dot with tincture of iodine;

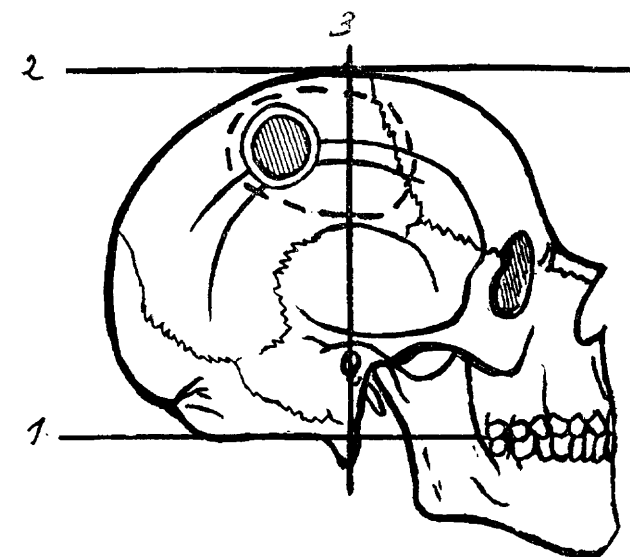


Fig. II.

- | | |
|---------------------------|---------------------------------------|
| 1. Base line. | Broken line of the oval indicates the |
| 2. Parallel tangent line. | area of adhesions, and bounds the |
| 3. Bi-auricular line. | space occupied by the blood clot, |
| | Circle indicates opening into skull. |

from this dot carried a line obliquely backwards and upwards at an angle of 33 degrees with the bi-auricular line

thus. Marked out, *approximately*, the course of the fissure of Rolando. Having mapped out the fissure we again washed the scalp thoroughly. Before cutting through the scalp I pierced it with a drill and marked the line for the central pivot of the trephine. To prevent hemorrhage the lock stitch devised by my friend, Dr. Frank, was used. With the stitch I cut off from the circulation an elliptical area measuring $12\frac{1}{2}$ by 10 cm. (5 by 4 inches). Within the area I cut down through the scalp and periosteum, making an oval flap 6 cm. wide, and lifted it up from behind forward to the extent of 7 cm., (2 4-5 inches), leaving the base of the flap in front; thus the opening in the scalp was placed at the most dependent portion. The flap was held back with warm sterilized gauze by Dr. Cullen, our interne. I now placed the trephine upon the skull so as to cover the fissure of Rolando, but had it extend further back of the fissure than forward, so as to get nearest the point in the skull covered by the scar in the scalp. The trephine was one and one-half inches in diameter. The bone was quite dense, five-sixteenths of an inch thick. The sclerosed condition of the bone was evidently due to osteitis. The dura mater was crossed by several large veins, and bled readily on being touched. After passing the needle through the dura mater, a half teaspoonful of blood entered the syringe. Finding nothing between the dura mater and calvarium to account for the man's condition I tied the veins and cut the dura mater one-fourth of an inch from the margin of the opening, and carried the incision around three-fifths of the circumference of the ring. The membrane was very thick and cut like leather, presented a yellowish appearance. A blood clot now came into view—it was semi-liquid.

By inclining the head to the right side, we caused the clot to glide out; the quantity was about two table-spoonfuls. There was considerable lymph in the arachnoid membrane all over the exposed surface. My index finger passed readily under the cranial vault and was swept about its circumference two inches forward and downward, an inch backward and half an inch inward to the longitudinal sinus. Around the entire area there were adhesions present showing that there had been at least a localized meningitis here and probably a leptomeningitis. The arachnoid could not be separated from the pia mater. Looking closely at the exposed surface the membranes were as one, thickened by lymph deposits. I tore the adhesions asunder between the arachnoid and dura mater by *very gently pressing* against them, the force of the pressure being directed towards the outer membrane. No hemorrhage worth mentioning followed this procedure in the present instance. My fingers were a little blood-stained. I explored the brain farther with the needle. It descended into the ascending frontal convolution towards Broca's speech center. Only a little brain substance entered it. Pierced the posterior portion of the ascending parietal convolution, behind the fissure of Rolando and above it. Noticed the patient's left leg jerk as the needle entered the cortex. The needle next entered directly behind (or as nearly as one could compute) the Rolandic fissure near the hand and finger centers. There was no evidence of abscess in any of these points; hardly felt justified in exploring farther in the presence of the pathological conditions already found. Washed the exposed parts with sterilized water, using very little pressure with the syringe, having first surrounded the tissues involved with sterilized gauze sponges to prevent the water from pouring into the subdural space beyond the limit of disease. There was a dark appearance of the deep membranes in spots, probably due to deep congestion of the pia mater, and the brain seemed to yield more readily to pressure here as if it was a little softer than in other parts.

As the vessels of the pia mater dip into the brain, the presence of softening of the brain would not be surprising. Leptomeningitis is said to be a cause of such a pathological condition. Had I been confident that the brain tissue had undergone degeneration it would not have seemed justifiable, in the face of what had already been done, to extirpate it. Removal of it would have produced permanent monoplegia. Not knowing what nature might accomplish by the regenerative process it seemed wise not to disturb it. I proceeded to close the wound, by first stitching the dura mater with catgut, in continuous suture, leaving a small opening at the lowest part for drain and insert a small drainage tube, having chiseled a groove in the margin of the button and taken out a few chips of the parietal bone directly opposite to prevent pressure on the tube. The button of bone was replaced. The scalp was stitched with silkworm gut, an opening being left at the lowest portion for the drainage tube. I now removed the lock stitch. Next dusted iodiform over the scalp wound, covered the head with two layers of iodoform gauze, four layers of sublimate gauze, placed a thick layer of cotton around the entire head and a Moorish bandage or cap over all.

NOTE:—Feb. 21. The patient lifts his left leg and bends the knee while walking. Before the operation he dragged the leg. The twitching at the left angle of the mouth ceased three weeks ago. General and tactile sense partially restored. Says he feels his left arm and leg, as if there was life in them; they seemed dead before. Can recognize which finger is touched with a point of a pin, without seeing it. The ear is sensitive to the touch. Headache has left him. Talks better, frequently speaks a sentence of a dozen words. Sometimes the words come smoothly and rapidly, at other times somewhat hesitatingly. Brain tires easily. An hour and a half after the operation was completed he said, "Doctor, can't you shut off that man's whistle?" referring to a patient in an adjoining room whose whistling annoyed him. The words were spoken distinctly and with little hesitation. Two weeks ago he could not open the left hand or lift the fingers. Now he opens the hand widely and extends the fingers. Has had no convulsions. Is improving daily. I omitted mentioning that our patient took iodid of potassium up to two weeks preceding the operation to make sure that no error should occur in operating. There was no indication of syphilis and the history of traumatism had not been ascertained. As already mentioned, the gentleman said nothing about the injury to the scalp until it was discovered by ocular and digital examination, and his attention was called to it.

Feb. 29. Had bone ache; bone was tender. There was evidence of necrosis. I opened the wound, removed the button, and chiseled away small bits of bone. March 31. Had a convulsion. Reopened the wound and removed a semicircle of dead bone about the cranial opening. There were adhesions behind the dura mater and arachnoid. For a time he seemed to improve again. April 6, while telling some of his friends that he felt better than he had for years, he was taken suddenly with epileptic seizures. They recurred daily. On the 11th of April I opened the wound once more, hoping to find a removable cause for the convulsions. Found adhesions to the dura mater and softened brain tissue, with two small abscesses of the size of pea. Died April 16.

Autopsy revealed extensive area of softened brain tissue, with two small abscess centers the size of a pea, and the dura mater re-attached. For at least one inch below and back of the trephine opening the bone was one-sixteenth of an inch thicker than that of the opposite side.

Case 10.—729. Wesley Hospital Record. Admitted March 20, 1893. Mr. W., aged 52 years. Has always been well and hearty. A locomotive engineer by profession. Eighteen months ago was badly hurt in collision of electric cars. Struck the side of his head against a door jamb. Six hours later, in the night, while drinking a little water fell to the floor unconscious and paralyzed. Next morning conscious-

ness returned, but he remained hemiplegic. Was aphasic four months. Remained in bed nine months. Has imperfect motion and loss of muscular sense in the entire left side. General sensation greatly impaired. Is troubled with insomnia. The right parietal bone feels somewhat flattened, as if it was stove in.

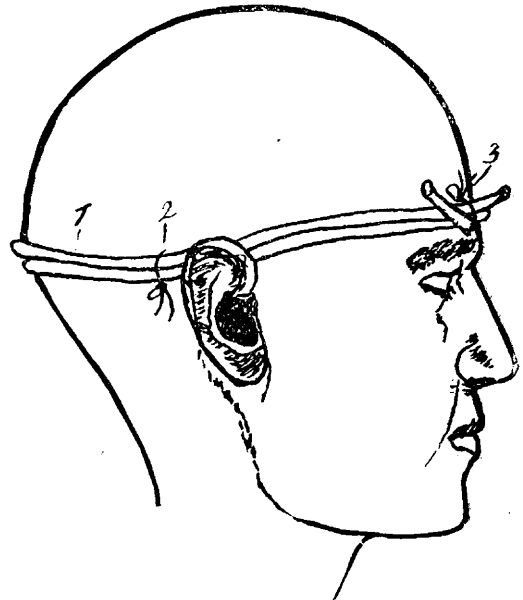
Notes taken before operation:

Left hand assumes silver fork position, with excessive extension of all the fingers. Can be about one-third way closed. Can not bring the ends of fingers within five inches of the palm of the hand. Raises the left arm to an angle of about 30° with the side of the chest. Forearm in extension forms an angle of 15° with the humerus. Rises from the chair slowly, with difficulty and trembling, using his right arm as a prop on the arm of the chair. Can not stand erect; body leans forward at the pelvis so as to form an angle of 15° with the thigh. Left shoulder droops three and one-half inches. While sitting he can with the aid of the right arm carry the left leg over the right knee by making repeated efforts. Patellar reflex is exaggerated. On closing his eyes while standing his body oscillates and he fears falling. Can not walk a step without strong support, and never has done so since receiving the stroke. He moves his leg with great difficulty, leaning upon the shoulder of an attendant. Does not bend the knee, but drags the leg. Walks on the outer side of the foot. His knees jerk occasionally when he tries to walk. Left ankle is weak and turns easily. General muscular tremors noticed after standing five minutes; more noticeable on the left side. Has imperfect control of the urine; urinates three or four times at night. Micturition variable during the day time. Experiences difficulty in passing urine; may take two minutes to start it, and can not be controlled at will. Bowels move with difficulty. Tactile sense dull; can not distinguish between two points unless they are two inches apart, and then is not certain. Distinguishes heat and cold with difficulty on the entire left side of his body, face and limbs. Pin points applied to the left foot and leg cause reflex jerking, although he hardly knows what troubles him. No cremasteric or elbow reflex elicited. Left arm and leg are stiff; they bend with difficulty, especially the arm. Nearly all of the muscles are contracted, the extensors most severely. He cries easily and is very irritable.

On the 13th of April, after having the patient most thoroughly prepared, I cut through the scalp, making an oval flap as usual, so as to raise it from behind and below; lifted the periosteum with it. Found the parietal bone depressed near its center. With Roberts' trephine modified, one and one-half inch diameter, I sawed out a button. The dura mater was quickly exposed. The skull was only a trifle over one-eighth thick and quite elastic. It was not broken, but simply bent in like the side of a battered stove pipe. There was no cerebral pulse apparent. All around the border of the opening just made the bone could be seen curving in and pressing upon the dura mater. The latter at once raised up to the level of the external surface of the surrounding bone. The elevator could not bring the edges of the bone away from the dura mater sufficiently, so I deliberately enlarged the hole in all directions, perhaps one-eighth of an inch, and again pried the bone with elevator. Was now rewarded with restoration of pulsation, which the members of the class noticed distinctly at the distance of eight feet. There was no bleeding during the operation. My plan* of constricting the head with a double circle of one-third inch solid rubber cord tied with stitches to the scalp at two places worked admirably. There was, however, free hemorrhage after the constrictor was removed, largely from the bone. The wound was stitched with silkworm gut. It healed promptly. The day after operation he closed his left hand firmly, and pressed mine with force. A few days ago the gentleman left the hospital greatly improved. Our interne, Dr. Seymour, took the following notes May 27:

Can close his left hand completely and gives a strong grip with it. Can touch both ears and top of his head with the left hand. Can straighten out the left foot and extend it. While lying in bed can flex the left leg at the thigh and knee. Walked to the front door and back (100 feet) without the assistance of even a cane; getting up and sitting down alone. Sways a little when standing with eyes closed. Stands

nearly erect. Can raise arm at the shoulder to right angle with the body. General and tactile sense greatly improved, but not perfect. Talks more fluently; his words are uttered with more force. Is less emotional and has better control of his temper. Has control of sphincters. Discharged greatly improved May 27. Advised massage treatment and electricity for the muscles, which I believe will in time enable him to go to work.



*My method of controlling hemorrhage in operations about the head is here shown. A firm solid rubber cord, one-fourth to one-fifth of an inch wide (1), is wrapped tight about the head twice. The cord is not tied into a knot, but the ends are crossed in front and tied together with a heavy silk thread placed around them (3). The thread sinks into the cord sufficiently to keep the ends from slipping. The cord is held in position by means of two or more suture threads. These are placed in position by means of a curved needle, which is passed through the scalp under the cord. They are then tied around the cord as in illustration (2). Two or more of these loops may be used at different points.

Discussion.

DR. McRAE of Atlanta, Ga.—These injuries are so frequent that we all meet them, and it is our duty to operate in every case. I recently had two cases which exemplify this. One was an injury the result of a fall from a horse, which caused a triangular depression on the top of the head. I never saw such violent hemorrhage from a fracture of the skull as occurred in that case. I immediately ran my finger into the wound in the scalp, and shortly the hemorrhage ceased. I then prepared for operating, but as soon as I tried to make an opening in order to elevate the bone the hemorrhage commenced again violently. I packed with iodoform gauze, stitched up the scalp, put on an antiseptic dressing and sent the patient home. The man made an excellent and uninterrupted recovery.

Another case was that of a boy 14 years of age who was struck over the parietal eminence. I found the bone depressed, and quite a quantity of brain substance had escaped. I operated immediately and he made a good recovery.

A third case was that of a boy who fell from a horse, but as no immediate serious symptoms developed, the family did not call in a physician. He got along all right for a while, and then a persistent headache began to manifest itself, later a progressive paralysis, and now he is only able to sit up in bed. This demonstrates what the outcome is liable to be without operation.

DR. AVERILL of Pennsylvania—About four years ago I was called to see a child 3 years old who had been kicked by a horse. The superior portion of the frontal bone was fractured, with depression of the upper edge to the extent of about one-half or three-fourths of an inch, lacerating the meninges extensively as well as the brain tissue. I removed probably two or three ounces of brain substance, excised the lacerated meninges, brought together the soft tissues of the scalp, dressed antiseptically and obtained a very satisfactory recovery. There was never any febrile condition, little pain, and the recovery was complete in about five weeks.

DR. GRIFFITH of Kansas City—These reported cases are

very interesting to me. My idea is that we can not be too careful about the prognosis in these cases, and also about insisting on going into the scalp to ascertain whether or not the skull is injured; there is nothing dangerous about this procedure, and we can promise the family that no harm will result from it. I think the method mentioned for stopping hemorrhage of the scalp unique. In our place we do it by the pressure method, opening the scalp, running a loop stitch clear around a given area going down on to the skull proper, and in this way we get a complete closure of all the vessels in this area.

DR. REYBURN, Washington, D. C.—I am more inclined to operative interference in these cases than I was in the early years of my practice. I think that where there is any suspicion of a serious injury it is best to open the scalp and ascertain positively the condition existing. I will cite in support of this a couple of cases in my own experience: One case was that of a boy who had been struck over the head by an iron bar, and shortly afterward went into violent convulsions. I immediately, upon my arrival, opened the scalp and removed the depressed bone. The improvement was immediate and the case went on to recovery.

At about the same time another boy was similarly injured, but he did not come under my hands at once, nor did he receive the attention which he should have had. On the third day I removed a spicule of bone which extended into the brain; soon after symptoms of inflammation of the brain developed and death resulted. So I repeat that my advice is, where there is any doubt in the mind of the surgeon, to invariably open the scalp and clear away any such doubts. There is no danger whatever in such a proceeding except in a child of from 2 to 5 years of age, but when the individual is older than that, in waiting there is danger of the development of inflammation of the brain.

DR. SCHAEFFER—In reply to Dr. Griffith's remarks about the loop stitch I will say that it was introduced by a Chicago surgeon, Dr. Frank, a few years ago. I followed this method in one of my cases and came to the conclusion that it was inferior to the plan described in this paper. It increases the danger of infection, as it is necessary to cover quite an area, and the needle will have to enter the tissues perhaps fifty times, while in the method illustrated only two or three, and occasionally four stitches, are required. I am pleased with the stand taken by Dr. Reyburn of Washington. I believe that more of these cases could be saved by timely operation. In all probability those who die after the operation would have died anyway.

A REPORT ON SOME CASES OF BRAIN SURGERY.

Read by title in the Section of Surgery, at the Forty-fourth Annual Meeting of the American Medical Association.

BY EMORY LANPHEAR, M.D., PH.D.

KANSAS CITY, MO.

Surgeon to All Saints Hospital and to the German Hospital; Consulting Surgeon to the Good Samaritan Hospital; Professor of Operative and Clinical Surgery in the Kansas City Medical College.

Only too often reports of cases are published before sufficient time has elapsed to determine whether or not a cure has been effected. While a rule which I attempt to follow is, to report no cases until I am satisfied as to the outcome, a few case histories have been published regarding which I wish now to make a supplemental report:

(A.) *Removal of Gasserian Ganglion.*—Something more than a year ago I sent out a report of a case of removal of the Gasserian ganglion by the method of Mr. Rose. Inasmuch as this operation is still a debatable one, its opponents claiming that the disease for which the operation is made will return inside of a few months, we who are in favor of the operation are compelled to report from time to time as to the condition of patients. The case to which reference is made has progressed satisfactorily during the past year, and has had absolutely no return of the fearful neuralgia, so I feel constrained to repeat that which I said in making my report of the operation

namely, that a complete cure has been secured. While the operation is a most formidable one, there are many cases of inveterate, incurable trigeminal neuralgia which are of sufficient severity to justify the operation, and I believe it is worthy of further trial. The method of Rose is certainly the best yet devised, though possibly further experiment along the line proposed by Frank Hartley of New York,¹ may show it to be better.

(B.) *Cerebral Hemorrhage.*—About two years ago I published a report of my first case of trephining for cerebral hemorrhage. This was a case of subcortical bleeding, and the record of it was printed only a few months after the operation. At that time a statement was made that the results were satisfactory. The subsequent history of the case is one of restoration to health with ability to work and to care for himself, although the use of the arm was not regained nor was his speech, owing to the great destruction of the cortical substance in the arm and speech centers.

Since that time I have operated upon two other cases of cerebral hemorrhage besides a number of cases of "apoplexy" due to meningeal hemorrhage. The second case of true cerebral hemorrhage was that of I. M., 54 years of age, who came under my care in June, 1892, suffering from hemiplegia and aphasia due to a hemorrhage. He was admitted to All Saints hospital and after due preparation a large flap was turned back and three one-inch buttons removed over the arm, leg and speech centers. These I joined by bone forceps. The dura was opened; no evidence of hemorrhage was to be seen except a white infiltrate over the speech and lower part of arm centers. This was opened and a considerable amount of broken-down brain removed; extending the cut upward toward the leg area, a clot a little more than one inch in length was found about half an inch below the surface pressing upon the connecting fibers of the leg and arm regions. This was removed, the cavity irrigated, and catgut drainage established, with the usual closure of dura; the pieces of skull were replaced and the scalp carefully sutured to hold them in place; usual dressings.

Convalescence was speedy and uneventful. For three days there was a little fever (100° F.) and absolutely no improvement in paralysis; then motion began to return slowly to the affected side and in a few weeks patient was walking around with a cane with but little difficulty. Motor power has not returned in the hand, but the arm and fore-arm now have some motion, slowly improving. Speech remains wholly unaffected. The bladder irritation and obstinate constipation, so prominent before operation, have entirely disappeared, and patient regards himself as vastly improved.

The third case was that of J. P. E., male, age 42 years, patient of Dr. J. R. Kistler who saw him at 4 P. M. on March 31, 1893, and found left-sided hemiplegia which came on 32 hours before while straining at stool; for some hours previously he had complained of vertigo and had spoken of a "bad feeling" in the head with heaviness of hand and foot two days before, at which time he went to bed with some vomiting. Temperature 100½; convulsion of paralyzed side occasionally; has been wildly delirious for some hours, and is becoming comatose. He was removed to the German hospital.

¹ Annals of Surgery, May, 1893.