

Czyżewski Wojciech, Litak Jakub, Kulesza Bartłomiej, Rolińska Agnieszka, Staniewicz Dominik, Grochowski Cezary, Kruk Rafał, Tyzo Bartłomiej. Long - term consequences of subdural hematoma on quality of life. Journal of Education, Health and Sport. 2018;8(9):961-965. eISSN 2391-8306. DOI <http://dx.doi.org/10.5281/zenodo.1419662>  
<http://ojs.ukw.edu.pl/index.php/johs/article/view/5990>  
<https://pbn.nauka.gov.pl/sedno-webapp/works/877650>

The journal has had 7 points in Ministry of Science and Higher Education parametric evaluation. Part b item 1223 (26/01/2017).  
1223 Journal of Education, Health and Sport eissn 2391-8306 7

© The Authors 2018;

This article is published with open access at Licensee Open Journal Systems of Kazimierz Wielki University in Bydgoszcz, Poland  
Open Access. This article is distributed under the terms of the Creative Commons Attribution Noncommercial License which permits any noncommercial use, distribution, and reproduction in any medium, provided the original author (s) and source are credited. This is an open access article licensed under the terms of the Creative Commons Attribution Non commercial license Share alike.  
(<http://creativecommons.org/licenses/by-nc-sa/4.0/>) which permits unrestricted, non commercial use, distribution and reproduction in any medium, provided the work is properly cited.

The authors declare that there is no conflict of interests regarding the publication of this paper.

Received: 02.09.2018. Revised: 12.09.2018. Accepted: 15.09.2018.

# Long - term consequences of subdural hematoma on quality of life

Wojciech Czyżewski<sup>1</sup>, Jakub Litak<sup>2</sup>, Bartłomiej Kulesza<sup>2</sup>, Agnieszka Rolińska<sup>3</sup>,  
Dominik Staniewicz<sup>4</sup>, Cezary Grochowski<sup>2</sup>, Rafał Kruk<sup>2</sup>, Bartłomiej Tyzo<sup>2</sup>

<sup>1</sup> Department of Didactics and Medical Simulation Medical University of Lublin.

<sup>2</sup> Department of Neurosurgery and Pediatric Neurosurgery SPSK-4 in Lublin.

<sup>3</sup> Department of Clinical Psychology,

<sup>4</sup> Medical University of Lublin.

## Krwiak podtwardówkowy i jego długoterminowy wpływ na jakość życia

<sup>1</sup> Zakład Dydaktyki i Symulacji Medycznej Uniwersytetu Medycznego w Lublinie.

<sup>2</sup> Klinika Neurochirurgii i Neurochirurgii Dziecięcej SPSK4 w Lublinie.

<sup>3</sup> Zakład Psychologii Stosowanej Uniwersytet Medyczny w Lublinie.

<sup>4</sup> Uniwersytet Medyczny w Lublinie.

### Abstract

Subdural hematoma (SDH) could be an acute state required rapid neurosurgical decompression, could also represent chronic form; both develop after head trauma as well. Long term influence on a quality of life depend on many factors. Researchers put a lot of effort to find those which play most predictive role.

### Abstrakt

Krwiak podtwardówkowy jako stan nagły może wymagać szybkiej dekompresji neurochirurgicznej, może również mieć formę przewlekłą - oba mogą być związane z urazem głowy. Długoterminowy wpływ na jakość życia zależy od

wielu czynników. Badacze poszukują tych ,które mają największą wartość predykcyjną.

**Key words:** Subdural hematoma, bleeding.

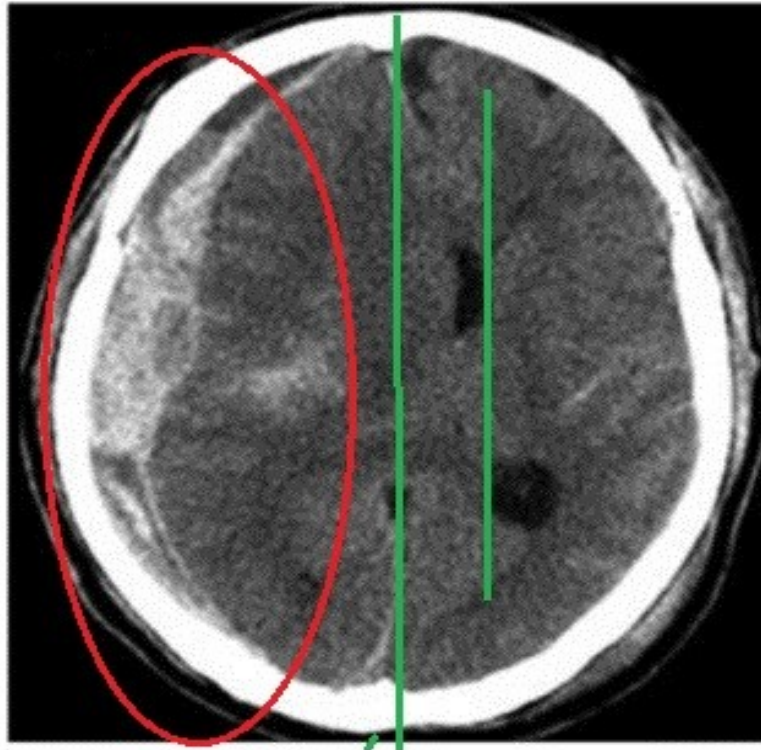
**Słowa kluczowe:** Krwiak podtwardówkowy, krwawienie.

### **Introduction**

68 y.o. male after car crash was transported to Hospital Emergency Unit. Patient was intubated during transportation but still on self breath, BP 160/90, HR 110, Sat 91%.GCS= 9 , left sided hemi paresis, Positive Babiński sign on both sides . Trauma CT was performed. (Fig. 1) Radiologist described 12- 22 mm Acute Subdural hematoma over right hemisphere with right lateral ventricle compression , shifting midline on opposite site for 15 mm. Patient getting worse GCS decreased to 7 , anisokoria appeared . Decision to urgent decompression was undertaken. Skin was incise on a right side of skull . 3 trepanation holes drilled over frontal temporal and parietal part of brain. Using craniotome large 'trauma flap 'was removed visualizing extremely tensed dura laying under. Gentle incision of dura reveal massive hematoma filling subdural space. Hematoma was removed totally giving space for compressed brain for decompression. Severe brain tissue edema startet to expand brain tissue through bone opening. Neurosurgery stuff made an decision to not restore bone flap. Duroplasty was performed , subcutaneous and skin part of opening were closed with stitches. After surgery pupils narrowed R=L. Neurological state improved in 5 days meaningfully ,strength in left body improved. Patient was conscious. Patient was discharged to rehabilitation ward , where further improvement was noted. After 6 month of intensive rehabilitation discharged home. After 8 month

patient undergo cranioplasty , bone flap was restored. Quaiity of life after 12 month returned on pre-accident level .

Fig. 1. Acute subdural hematoma over right hemisphere (red circle), midline and ventricles shifted on opposite site(green lines).



## Discussion

Subdural hematoma (SDH) represents a common form of intracranial bleeding. It occurs when venal blood extravasates between the arachnoid and the dura. Depending of the onset of bleeding subdural hematomas can be classified as acute, subacute and chronic, but the limits of each group vary. SDH as acute is defined if operation is performed within 3 days after injury, subacute-more than 3 days but within 3 weeks, and chronic-more than 3 weeks or without any history of head injury.

If a patient sustain a major brain injury the rapid accumulation of blood can

cause life-threatening symptoms. This might cause acute subdural hematoma, the most dangerous type of SDH. It is mainly caused by falling on the ground, strike to the head or a motor vehicle traffic crash. In this type of injury, the hematoma forms quickly and the onset of symptoms is usually immediate. About 50-90 percent of people who develop ASDH die from the condition or it's complications [1,2] Chronic subdural hematomas are, in contrast, most likely caused by a minor traumatic brain injury, which oftentimes happens with no loss of consciousness. There is usually an asymptomatic or oligosymptomatic (intermittent headaches, dizziness, occasional vomiting, memory and attention disorders) period. [3] Symptoms of chronic SDH are usually not noticeable at the beginning and may appear after several weeks. Among most dangerous complications of subdural hematomas are brain herniation, permanent muscle weakness or seizures.

From the other hand, severe coexistent diseases, smoking, older age and low GCS score upon admission [4] are the most important causes of the poor functional outcome. The consequences of this condition might not only cause short-term impairment. In most of the cases, persistent, life long disabilities occur. Even though the overall amount of survival patients increased over the years, most of them are forced to undergo long-term rehabilitation and might suffer permanent cognitive, physical and psychological disabilities.

Contemporary medicine mostly focuses on prevention and early, both conservative and invasive treatment of the SDH [5]. Thousands of clinical research work has been devoted to define more accurate diagnosis, management, and prognosis in the acute phase of the SDH. Not as many data is available for long - term outcome. In our opinion, bringing people to normal, healthy life after severe head injures should be an ultimate goal for the treatment.

## References:

1. Weigel R, Schmiedek P, Krauss JK. Outcome of contemporary surgery for chronic subdural haematoma: evidence based review. *J Neurol Neurosurg Psychiatry*. 2003;74(7):937–43.
2. Miranda LB, Braxton E, Hobbs J, Quigley MR. Chronic subdural hematoma in the elderly: not a benign disease. *J Neurosurg*. 2011;114(1):72–6.
3. IA Iliescu , AI Constantinescu *J Med Life*. 2015; 8(Spec Issue): 26–33.
4. Todd MM, Hindman BJ, Clarke WR, et al. Perioperative fever and outcome in surgical patients with aneurysmal subarachnoid hemorrhage. *Neurosurgery*. 2009;64(5):897–908.
5. Weimer JM, Gordon E, Frontera JA, *Neurocrit Care*. 2017 Feb;26(1):70-79.