



## Case Report

**ASCARIASIS AS A CAUSE OF ACALCULUS EOSINOPHILIC CHOLECYSTITIS - A RARE CASE REPORT**KUNDAL RAMESH<sup>1</sup>, \*SINGH HARPAL<sup>2</sup>, SWARUPA CHAKMA<sup>3</sup>, NAVPREET KAUR<sup>4</sup>, DEEPIKA<sup>5</sup>.**AUTHOR DETAILS**

<sup>1</sup>Professor, <sup>2</sup>Associate Professor, <sup>3,4,5</sup>Junior Residents, Dept. of Pathology Govt. Medical College Patiala.

**ARTICLE INFO**

Received: 20<sup>th</sup> September 2015,  
Accepted: 01<sup>st</sup> October 2015.

\*Corresponding author email:  
[drharpalseemar@gmail.com](mailto:drharpalseemar@gmail.com)

**ABSTRACT**

Acalculus eosinophilic cholecystitis is a variant of chronic cholecystitis which is an inflammation of gall bladder. Here we presents a case of female child of 10 years age with features of abdominal pain for 6 months which after investigations found to be of an eosinophilic cholecystitis caused by *Ascaris lumbricoides*- a rare entity.

**KEYWORDS**

Ascariasis, USG (ultrasonography) and ERCP (extended retrograde cholangio-pancreatography).

**INTRODUCTION**

Eosinophilic cholecystitis was first reported in 1949 as dense transmural infiltration of eosinophils within the gall bladder.<sup>[1]</sup> Especially in a tropical country like India the causative agent is *ascaris lumbricoides* or roundworm which is most prevalent human intestinal nematode.<sup>[2]</sup> Children are more vulnerable because they are more exposed. Moreover the moist climate, poor sanitation, unhygienic practices and overcrowding adds on to the fulmination of the parasite. Though round worm in gall bladder is quiet uncommon but the intrinsic anatomy of biliary system makes it not impossible.<sup>[3]</sup>

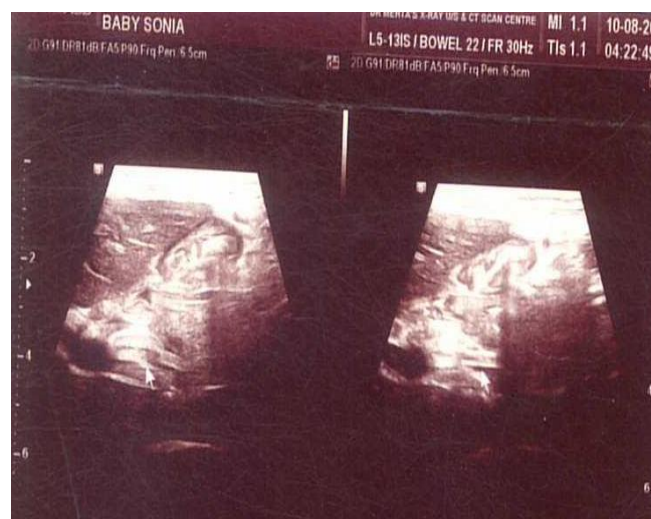Study of 500 patients with hepatobiliary and/or pancreatic disease related to infection showed 274 patients had duodenal ascariasis, 171 biliary ascariasis, 40 hepatic ascariasis, and 7 pancreatic ascariasis. Out of these 500 cases, 64 patients diagnosed as acalculus cholecystitis but with 8 of them had worms the gall bladder.<sup>[4]</sup>

**CASE REPORT**

A 10 year old female child of low socioeconomic strata presented to the emergency ward with pain in the abdomen intermittently for 6 months with history of frequent episodes of vomiting. There were complaints of fever as well.

On examination patient was of moderate built. Pulse- 60/min, BP- 110/70 mm hg, there was tenderness present in right hypochondrium and no visceromegaly was seen. Routine haematological examinations like haemoglobin, TLC, DLC were within normal limits. Liver function test SGOT-53 IU/L, SGPT- 40 IU/L, Serum Alkaline Phosphatase- 292 IU/L.

Ultrasound of abdomen revealed parasitic infestation of gall bladder along with involvement of biliary tract (Figure 1) A provisional diagnosis of ascariasis gall bladder was made and laparoscopic cholecystectomy was performed. Operative findings revealed a whitish tail like organism was visualized in the gall bladder after the scope was inserted. Specimen of extracted gall bladder was received in our pathology department measuring 4 cm in length (Figure 2). On cutting the specimen a worm measuring 8 cm in length was recovered lying within the lumen (Figure 3). The worm was identified as *Ascaris lumbricoides*.



**Figure 1. USG of abdomen showing worm like structure in lumen of gall bladder (white arrows)**



Figure 2. *Ascaris lumbricoides* in the lumen of gall bladder



Figure 3. Length of worm is 8.0 cms.

Representative sections of the gall bladder were processed. Under light microscope, eosinophilic cholecystitis was reported (Figure 4 & 5).

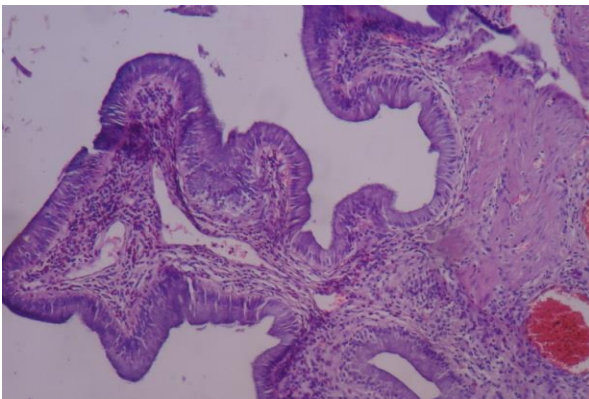


Figure 4. Microphotograph under 10X

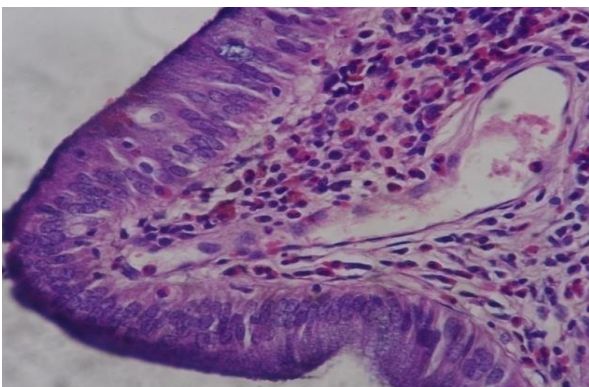


Figure 5. Microphotograph under 40X show eosinophils

Later on a complete stool examination was done but it came out negative because of the prior anti-helminthic treatment given to the patient.

## DISCUSSION

Ascariasis is the most common helminthic disease of mankind i.e more than a billion people are infected worldwide,<sup>[5]</sup> mostly in developing tropical and subtropical countries. In Kashmir, India the prevalence of ascariasis in adult population was 30% and in children 60%.<sup>[6]</sup> The wet soil Kashmir and the temperate climate are excellent conditions for the development of the larval stage of infection. Poverty, overcrowding, unhygienic living conditions, poor sanitation, and unsafe water supply contribute to the spread of infection from person to person. Use of human excreta as a fertiliser for vegetable production also has an important role in the high endemicity of ascariasis; pickling of uncooked vegetables is extremely common in Kashmir, and ascaris ova can survive in these preparations and go on to cause infection. Similar environmental, cultural, and socioeconomic reasons make ascariasis highly endemic in developing countries.

Data about morbidity and mortality due to ascariasis are difficult to obtain. Acute abdominal emergencies account for 3% of all patients in some hospitals in the tropics<sup>[7]</sup> and cause about 100000 child deaths a year.<sup>[8]</sup>

The presence of large numbers of adult ascaris worms in the small intestine can cause abdominal distension and pain. They can cause lactose intolerance and malabsorption of vitamin A and possibly essential nutrients,<sup>[9]</sup> which might partly cause the nutritional growth failure. In young children, adult worms aggregate in the ileum and cause partial obstruction because lumen is small.<sup>[4,10]</sup> Typically, a child with obstruction because of ascaris has a toxic appearance with signs and symptoms of peritonitis. In some cases, a mass can be felt in the right lower quadrant.<sup>[11]</sup> Adult ascaris worms also tend to move in children with high fever, resulting in the emergence of worms from the nasopharynx or anus. Hepatobiliary and pancreatic ascariasis results when adult worms in the duodenum enter and block the ampullary orifice of the common bile duct, leading to biliary colic, cholecystitis, cholangitis, pancreatitis, and hepatic abscess.<sup>[4]</sup> By contrast with intestinal obstruction, hepatobiliary and pancreatic ascariasis occurs more commonly in adults—especially women than in children, presumably because the adult biliary tree is large enough to accommodate an adult worm.<sup>[4]</sup> A data of 5 of the 1105 adults in a general population screened by ultrasonography had worms in the biliary tract.<sup>[6]</sup> Since ascariasis infection is more common and heavier in children, worm invasion of the biliary tree is more likely in this age group.

In most patients the worms move out of the ducts within 24 hrs of inducing biliary / and or pancreatic symptoms. Thus, hepatobiliary ascariasis is difficult to detect by biliary imaging tools( oral cholecystography, intravenous cholangiography) and surgical explorations.<sup>[12]</sup> By contrast, frequent and early use of ERCP has shown that in Kashmir hepatobiliary and pancreatic ascariasis is as common a cause of hepatobiliary

and pancreatic disease as gallstones. <sup>[12]</sup> Ultrasonography is a highly sensitive and specific method for detection worms in the biliary tree: <sup>[13]</sup> this investigation is non-invasive, it can be used in patients with symptoms, and it can be repeated frequently to monitor movements of worms in the ducts.

The clinical presentation of hepatobiliary and pancreatic ascariasis depends on the presence of worms in the lumen or ductal system. Worms in the common bile duct usually blocked the cystic duct opening and caused distension of cystic duct and gall bladder which led to episodes of acute cholecystitis. ERCP not only is an excellent diagnostic tool but also has a major therapeutic role in hepatobiliary and pancreatic ascariasis. Recurrent biliary colic that does not respond to antispasmodic analgesics is now a major emergency indication of ERCP.

But in our case ultrasonographic findings show only a worm like structure present in the gall bladder is the main causative factor for pain abdomen and frequent episodes of vomiting in the child. This finding was confirmed after removal of gall bladder through laparoscopic surgery and on later microscopic examination - eosinophilic cholecystitis. Thus, ultrasonography is a better non-invasive diagnostic tool in finding the rare such cause of pain abdomen as compared to ERCP

## REFERENCES

- 1) Albot G, Olivier C, Libaude H. Les cholecystitis eosinophils. *Presse Med.* 1949;57:558-9
- 2) Criscione CD, Anderson JD, Sudimack D. Disentangling hybridization and host colonization in parasitic roundworms of humans and pigs. *Proc Biol Sci* 2007;274:2669-77
- 3) Ahmed MN, Saleema, Shant MS. Ascariasis of the gall bladder (a case report). *J Postgrad Med* 1983;29:127-8
- 4) Khuroo MS, Zardgar SA, Mahajan R. Hepatobiliary and pancreatic ascariasis in India. *The Lancet* 1990; 335:1503-06.
- 5) Crompton DWT, Nesheim MC, Pawlowski ZS, eds. Ascariasis and its public health significance. London: Taylor and Francis, 1985
- 6) Khuroo MS, Mahajan R, Zargar SA, Javid G, Sapru S. Prevalence of biliary tract disease in India: a sonographic study in adult population in Kashmir. *Gut* 1989;30:201-05
- 7) Thein Hlaing. A profile of ascariasis morbidity in Rangoon Childrens Hospital, Burma. *J Trop Med Hyg* 1987; 90:165-69.
- 8) Editorial. Ascariasis. *The Lancet* No.8645 London Saturday 6 May 1989; Vol I For 1989:997-98.
- 9) Taren DL, Nesheim MC, Crompton DW. Contributions of ascariasis to poor nutritional status in children from Chiriqui Province, Republic of Panama. *Parasitology* 1987; 95:603-13.
- 10) Villamizar E, Mendez M, Bonilla E, Varon H, de Onatra S. *Ascaris lumbricoides* infestation as a cause of intestinal obstruction in children: experience with 87 cases. *J Pediatr Surg* 1996; 31; 201-04; discussion 204-05.
- 11) Khuroo MS. Ascariasis. *Gastroenterol Clin North Am* 1996;25:553-77.
- 12) Khuroo MS, Zargar SA. Biliary ascariasis: a common cause of biliary and pancreatic disease in an endemic area. *Gastroenterology* 1985; 88:418-23.
- 13) Khuroo MS, Zargar SA, Mahajan R, Bhat RL, Javid G. Sonographic appearances in biliary ascariasis. *Gastroenterology* 1987;93:267-72.