



## FINGER ENUCLEATION OF THE TONSIL.

A METHOD FOR THE REMOVAL OF WHOLE TONSILS IN CHILDREN.

BY FRANK S. MATHEWS, M.D.,

OF NEW YORK,

Associate Surgeon to St. Mary's Free Hospital for Children; Assistant  
Surgeon to the General Memorial Hospital.

UNTIL recently operations on the tonsils whether done by surgeons, pædiatrists, laryngologists or others have consisted in the removal of what may be called the excess of adenoid tissue. Recently, the laryngologists have attempted a more thorough operation using a variety of methods and instruments, in the endeavor to remove the entire tonsil.

In favor of the old method, tonsillotomy, is its simplicity as an operation. Moreover, in some hands the tonsillotome may remove nearly all of an elevated tonsil and a goodly portion of a buried one, though in the latter case, the anterior pillar is likely to suffer. Without doubt the vast majority of cases subjected to tonsillotomy in the past have been much benefited temporarily or permanently. On the other hand second or even third removals are not uncommon, especially if the first operation is performed in early childhood. The base, too, of a tonsil can afford a portal of entry to bacteria (including the tubercle bacillus) as well as a whole tonsil. Indeed, a child may have its first attack of follicular tonsillitis shortly after a tonsillotomy.

Some operators in their anxiety to remove the tonsil completely have replaced the exceedingly minor operation of tonsillotomy by a fairly formidable dissection requiring hours rather than minutes for its accomplishment. Tonsillectomy is desirable; but a quick easy operation is also. The operation to be described has been performed in a great many cases at St. Mary's Hospital for Children with perfect satisfaction, with all kinds of tonsils, elevated, flat, buried and irregular. Many of the flat and soft tonsils have come out whole by this

method where we could not succeed at all by the old tonsil-lotome or newer snare methods. Before settling upon the method to be described we had experimented with several varieties of pillar separators with bistoury, long handled scissors, snare and punch and with a number of different positions for operating. These instruments have largely proved disappointing though they may have a distinct field of usefulness when the patient is an adult and no general anæsthetic is used.

We use ether as the anæsthetic of choice—under no circumstances chloroform, considering it more dangerous in these cases with their tendency to cyanosis than in the common run of surgical cases. Recall the fact that minor anæsthesia and childhood are no safeguards against the dangers of chloroform. Ether is given with paper cone and without preceding it with nitrous oxide. A child is etherized so quickly that the latter affords no advantages. Etherization is continued two to four minutes, depending on the child's age until a stage of primary anæsthesia is reached, but not to the stage of obliteration of pharyngeal or corneal reflexes. The danger of inspiring blood though slight is less when reflexes are not impaired. The patient is placed horizontally on a low table with the head at the end of the table but not hanging over. The operator takes the place of the anæsthetist at the head of the table. A gag is inserted and held by the anæsthetist who controls the head and presses upon the tonsil from without if desired. If the tonsil is thoroughly enucleated this is of small moment.

The jaws are gagged just widely enough to admit one or two fingers; wide gagging interferes with the child's breathing. No effort is made to control the movements of the fingers by sight. The whole operation is done by the sense of touch.

We describe first the removal of the right tonsil. The gag is placed in the left side of the mouth; the index or index and middle fingers of the right hand inserted and their palmar surface applied to the right anterior tonsillar pillar. By several strokes of the finger along the pillar from above downward a plane of cleavage is found and the tips of the fingers

felt to enter between the outer fibrous tissue-covered surface of the tonsil and the inner surface of the pharyngeal wall.

If, as is less frequently the case, the tonsil adheres to the posterior pillar, the palmar surfaces of the fingers are then brought in contact with the exposed surface of the tonsil and the tonsil forcibly pulled forward, or rotated on its vertical axis, toward the mouth. The adhesions to the posterior pillar separate easily. Next one inserts the finger into the space made by separating the anterior pillar from the tonsil, turns the palmar surface toward the tonsil and brings it in contact with its upper pole. With the finger above the tonsil and the pillars thoroughly separated from it the tonsil is pushed inward toward the pharynx and downward toward the epiglottis, thus stripping it laterally from the pharyngeal wall. The tonsil, now out of its natural bed between the pillars, remains attached only by a band of mucosa at its lower pole. One can now, if he desires and as we have repeatedly done, tear away this remaining attachment with the fingers; but it is more difficult and time-consuming than the preceding steps of the operation and consequently we complete the removal by using a Mackenzie tonsillotome of small size and small aperture. The blade is drawn back, the instrument inserted with the finger over the aperture and the blade pushed home only when the finger feels that the tonsil has engaged.

The gag is then as a rule shifted to the right side of the mouth and the left tonsil enucleated with the fingers of the left hand. Inspection of the tonsil after removal shows a whole tonsil in a capsule of connective tissue. Rarely are any muscle-fibres of the pharyngeal wall found attached to it.

After the tonsils are out the finger explores the vault of the pharynx and if adenoids are present they are removed with the curette. We never use the finger or gauze covered finger to remove growths from Rosenmüller's fossa because of the certainty of thereby producing traumatism to the lateral pharyngeal wall in the vicinity of the Eustachian prominence and thereby favoring middle ear complications. The mouth

is more widely gagged for the removal of adenoids than for tonsils.

This operation requires but a couple of minutes and the child is out from the anæsthetic almost immediately.

We have performed the finger enucleation now many hundreds of times and believe it to be a method superior to ordinary tonsillotomy in that it is a complete removal of all tonsillar tissue. As in all other methods of removal so in this, the larger the tonsil the easier the removal. But the writer is convinced that he can remove many tonsils too flat or buried for success with the simple tonsillotome method, and others too soft for a tenaculum forceps to maintain its hold. In all cases after using the various pillar separators a further enucleation has been found possible with the finger.

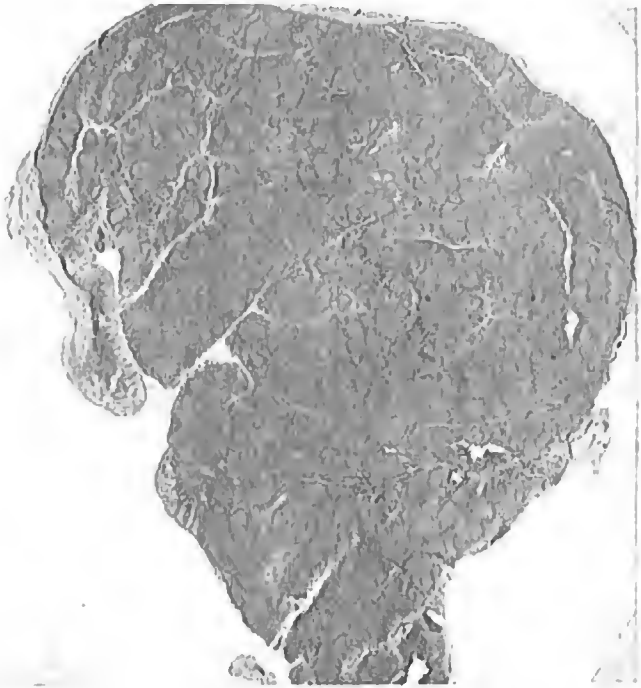After thorough enucleation with the finger it is not of great consequence what instrument one uses to detach the small remaining pedicle. It can be done with tonsillotome, blunt scissors or snare. The thing of first importance is the thorough enucleation of the tonsil from its bed between the pillars. We prefer the Maekenzie tonsillotome simply because one can use it by touch alone and avoid consuming time in sponging away blood to get a view of the parts.

There has been no case of bleeding requiring treatment after finger enucleation though we have had two fairly severe cases after tonsillotomy. The amount of bleeding during the operation is rather greater than with tonsillotomy. In the finger enucleation vessels are torn rather than cut and can readily retract into the normal tissues of the pharyngeal wall. No case of injury to the pharyngeal wall has occurred. It is avoided by keeping the fingers in contact with the tonsil and never directing them against the pharyngeal wall.<sup>1</sup>

---

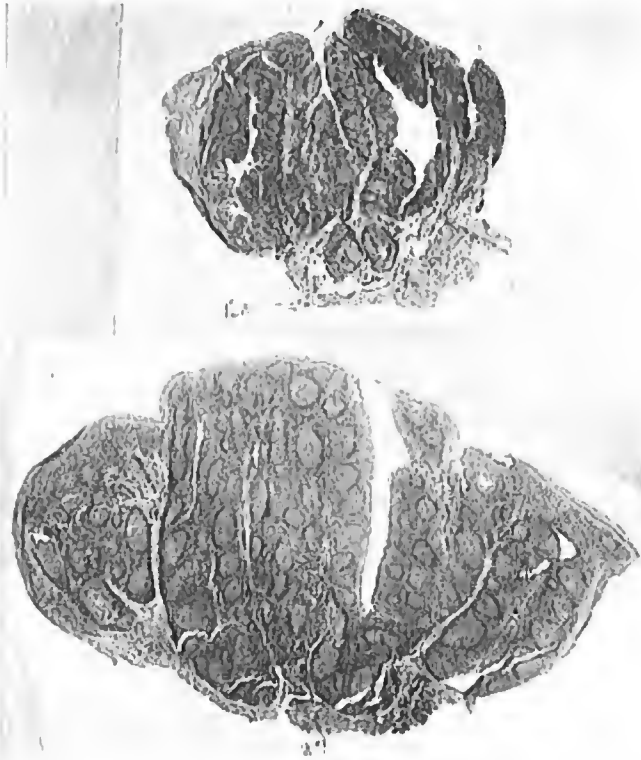<sup>1</sup> Some fear injury to the carotid in tonsillotomy. The tonsil is separated from the carotid by the superior constrictor, styloglossus and stylopharyngeus muscles. Moreover it lies posterior to the muscles, *i.e.*, nearer the vertebral column. The carotid will not be injured by finger dissection or the tonsillotome but may be by tonsil punches if pressure is being exerted from without. If pressure is to be made from without it should be applied in front of the vessels.

**FIG. 1.**



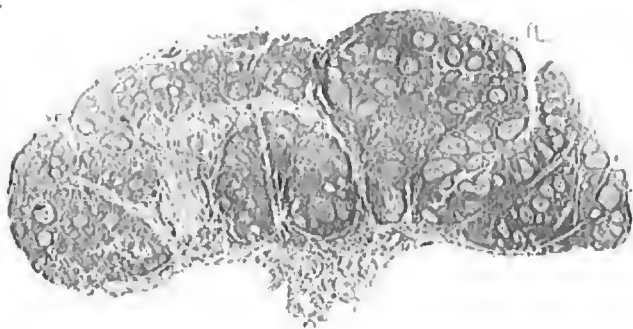**Section of a deeply buried tonsil. The flat surface is the one directed toward the mouth.**

**FIGS. 2 and 3.**



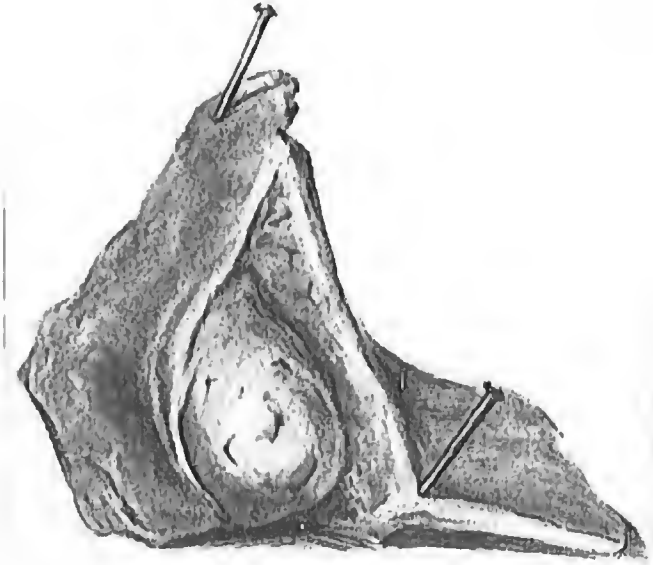
**Small soft, ragged tonsil, with deep crypts, base deeply buried.  
Section of a large partially elevated tonsil, only partially removable by a tonsillotome.**

FIG. 4.



An elevated large and flat tonsil.

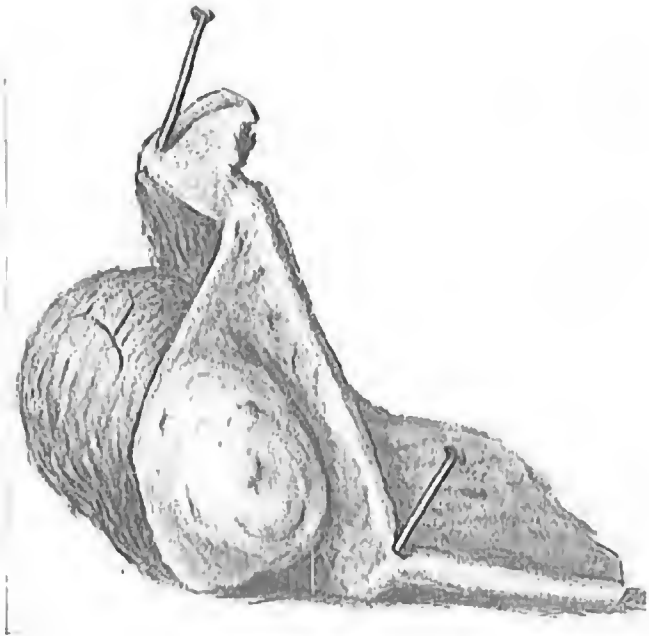
FIG. 5.



Portion of lateral wall of pharynx removed to show superficial portion of tonsil projecting to a moderate degree into fauces.

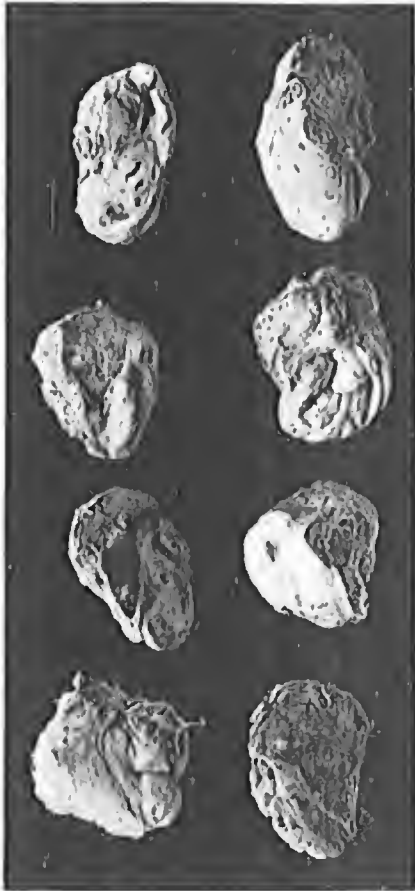

FIG. 6.



Same specimen as in Fig. 5 with anterior pillar of fauces dissected away so as to reveal the buried portion of the tonsil.

FIG. 7.



Deeply buried tonsils after enucleation.

The microphotographs shown illustrate different forms of tonsils removed by the method. Fig. 1 is a deeply buried one: The flat surface is the one directed toward the mouth. This tonsil was removed by fingers alone with no help from the tonsillotome. Fig. 2 shows the small, soft, ragged tonsil with deep crypts from which a volsellum would easily tear out. A good portion of this tonsil was buried from view. Fig. 3 is a large, partially elevated one, part of the base of which would surely have remained *in situ* if the tonsillotome alone had been employed for its removal. Fig. 4 illustrates an elevated large and flat tonsil. All these are whole tonsils as is shown by their capsule of connective tissue.

The two companion drawings (Figs. 5 and 6) were made from a portion of a lateral pharyngeal wall removed at autopsy. The first shows very well an apparently small elevated tonsil easily removable with the tonsillotome. The second of these drawings shows the same specimen from which the anterior pillar has been dissected away, revealing the much larger buried portion of the tonsil. This is a common condition and very favorable to finger enucleation. The buried portion of a tonsil usually lies above and external to the visible one. There is usually a deep crypt leading from the upper part of the visible portion into the buried tonsil. The eight tonsils photographed (Fig. 7) are good illustrations of deeply buried tonsils all removed entire. The view of them presented is that which one would have had by looking into the mouth, with the exception of the fact that the larger buried portion was covered by the anterior pillar. In most of them one can readily differentiate in the photograph the smooth mucosa-covered surface from the rougher connective-tissue capsule.

The advantages claimed for the finger enucleation of tonsils as above described are:

1. Whole tonsils are removed—a tonsillectomy.
2. The anæsthesia is primary and of short duration.
3. The operation requires but a couple of minutes even when adenectomy is added.

4. The armamentarium is simple and cheap; but three instruments are used, a mouth gag, a Maekenzie tonsillotome, and an adenoid eurette.

5. Only one assistant is needed, either physician or nurse: in the latter case one can give the anæsthetic himself.

6. Skill in enucleating tonsils with the fingers is easily acquired by any one familiar with the anatomy of the parts. Our resident physicians learn to do it perfectly well after a few trials.

7. As it is done entirely by feeling one is not interfered with by the presence of blood and mucus in the throat.

8. Convalescence is no longer or more painful than after tonsillotomy.

In brief, we have found the operation a quick, safe, simple and thorough one.