



Journal Homepage: -www.journalijar.com
**INTERNATIONAL JOURNAL OF
 ADVANCED RESEARCH (IJAR)**

Article DOI:10.21474/IJAR01/8533
 DOI URL: <http://dx.doi.org/10.21474/IJAR01/8533>



RESEARCH ARTICLE

RECURRENT LARYNGEAL NERVE AND PARATHYROID GLAND SAVING BY SPRAYING METHYLENE BLUE DURING THYROIDECTOMY.

Hany Mohamed, Ashraf Goda and Hatem Mohammed.

General Surgery Departments, Faculty of Medicine, Zagazig University.

Manuscript Info

Manuscript History

Received: 11 December 2018

Final Accepted: 13 January 2019

Published: February 2019

Key words:-

Spraying Methylene blue,
 Thyroidectomy, Recurrent laryngeal
 nerve.

Abstract

Background: Visualization and saving of the recurrent laryngeal nerve (RLN) and parathyroid glands (PGs) are the most important two points during thyroid surgery.

The aim of the study is evaluation of the use of intra operative methylene blue spraying during thyroidectomy in saving RLN and PGs.

Patient and methods: Our study was done in general surgery department of Zagazig University hospital from March 2017 to September 2018 and follow up for about 6 months, included (53) patients with different types of goiter operated by total thyroidectomy with intra operative methylene blue spraying. Patients with recurrent thyroid surgery, preoperative vocal cords paresis, or retrosternal goiter were excluded. The patients underwent complete history taking, clinical examination, laboratory investigations including serum calcium level, TSH, free T3, T4, neck US, C.T neck in some cases and indirect laryngoscopy pre and post operatively to assess the vocal cords mobility pre-and postoperatively. Informed consent was taken from all patients.

Results: the study involved (53) cases, 43 females (81.1%) and 10 males (18.9%); age ranged from 27 to 61 years (mean: 41,5 year), the patients had; 35 (66.04%) simple nodular goiters, 9(16.98%) solitary thyroid adenoma, 5 (9.43%) papillary thyroid carcinoma and 4 (7.55%) Graves' disease. Patients mean discharged were 1.6 days (1-4 days) with no cases of wound complications or operative mortality. 4 cases (7.55%) suffered from transient hypocalcaemia, for a maximum of four days. the RLN can be visualized in 47 cases (88.7%) after spraying the MB firstly but in the remaining six cases (11.3%) the RLN was present in deeper level and need more dissection until it is detected and saved. No cases were encountered of RLN injury with vocal cords paralysis or hypoparathyroidism

Copy Right, IJAR, 2019,. All rights reserved.

Introduction:-

Total thyroidectomy and thyroid lobectomy were considered the current surgical treatment for both benign and malignant thyroid diseases^{1,2}. The excellent prognosis of well-differentiated cancer thyroid requires prevention or

Corresponding Author:-Hany Mohamed.

Address:-General Surgery Departments, Faculty of Medicine, Zagazig University.

decreasing the post-operative complications such as injury to recurrent laryngeal nerve (RLN) and hypo-function of parathyroid glands (PGs) which still challenges for surgeons^{3,4}.

The major concerns in thyroid operations are exposure and protection of RLN. Staining of the nerve fiber by the methylene blue (MB) is old procedure⁵, It was used to visualize the branches of the vagus nerve⁶ facial nerve trunk⁷, stumps of the nerves⁸ and fibres of autonomic nerves⁹ in many surgeries. The procedure of surgery represent the main factor alters the results of the operation¹⁰.

Vocal cords Paralysis may cause serious complications in phonation, respiration and psychological disturbances which affect the patient's life style¹¹.

Basically, the important step to protect the PGs and prevent its hypofunction is good identification. However, the very small size of the PGs that located in the paratracheal fatty Tissues which have a color like to the PGs. It is not easy to identify the all PGs by the naked eye during operation even by the experienced surgeons^{12,13}. Formerly, many surgeons didn't dissect near to RLN to avoid its injury. Now a days, the endocrine surgeons reported that is not accepted. The visualization and protection of RLN are very important to prevent its injury¹⁴. In our present study, we aimed to evaluate the using MB spraying technique for safe identification of RLN and PGs during total thyroidectomy.

Patient and methods:-

Our prospective study was approved by Research Ethics Committee of Zagazig University hospital and was done in general surgery department from March 2017 to September 2018 and follow up for about 6 months, included (53) cases with benign and malignant thyroid swelling operated by total thyroidectomy. Patients with recurrent thyroid surgery, preoperative vocal cords paresis, or retrosternal goiter were excluded. The patients underwent complete history taking, clinical examination, laboratory investigations including TSH, freeT3, T4, serum calcium level, neck US, C.T neck in some cases and indirect laryngoscopy pre and post operatively to assess the vocal cords mobility pre-and postoperatively. Informed consent was taken from all cases.

Operations were done under general anesthesia, neck Kocher collar incision followed by strap muscles separation in midline, ligation of middle thyroid veins, thyroid lobe dissection, ligation of superior thyroid artery then cutting within the upper pole of thyroid. When we reach area where the RLN was suspected to enter the tracheo-oesophageal groove and the parathyroid gland can't be identified, the thyroid lobe retracted medially (**fig. 1**) and 0.5 ml of MB was sprayed on the retracted lobe and the surrounded tissues including the PGs, inferior thyroid artery, veins, RLN and surrounding muscles, fatty tissues. The arteries and RLN were not stained and still relatively white (**fig. 2**). PGs had washed out the stain within three minutes and return to their original yellow color, after identification of the RLN and PG washing by saline to clear the field from the stain to make the dissection easier, wash-out time of thyroid gland not less than 15 minutes and 25 minutes for surrounding structures. The thyroid dissected from the trachea and operation is completed by anatomical closure with drain.

Follow up:

All patients were followed up postoperatively by serum calcium, wound complications and laryngoscopy before discharge then in outpatient clinic weekly for one month then monthly for six months.

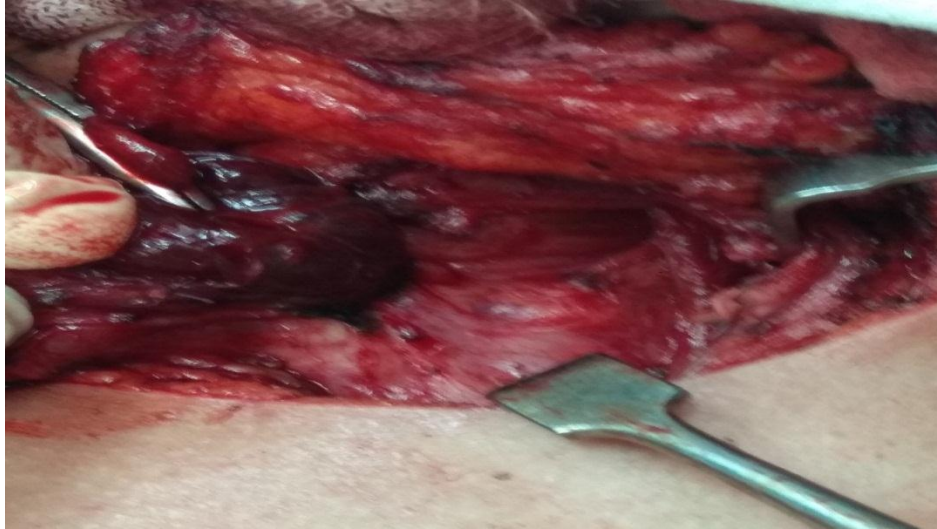

Fig 1:-show thyroid field before MB spraying with no visualization of RLN.

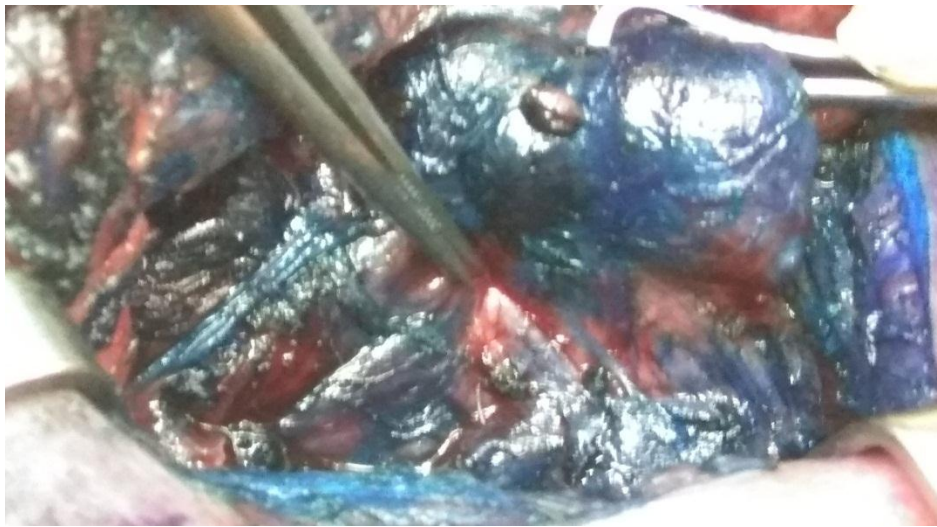


Fig 2:-show the RLN is visualized as white cord not taking MB dye

Results:-

This study was conducted on (53) patients operated by total thyroidectomy, 43 females (81.1%) and 10 males (18.9%); age ranged from 27 to 61 years (mean: 41.5 year), the patients had different thyroid diseases; 35(66.04%) simple nodular goitres, 9(16.98%) solitary thyroid adenoma, 5(9.43%) cancer thyroid and 4(7.55%) Graves' disease. The mean of cases discharge was 1.6 days (1–4 days), no cases of wound seroma, infection dehiscence or other complications. No cases of operative mortality. Only 4 cases (7.55%) suffered from transient hypocalcaemia, for a maximum of four days (calcium level <8 mg/dL. and clinical picture of hypocalcaemia) which improved by oral calcium and vitamin D supply. In our study the RLN can be visualized in 47 cases (88.7%) after spraying the MB In firstly but in the remaining six cases (11.3%) the RLN was present in deeper level and need more dissection until it is detected and saved. No cases were encountered of vocal cord paralysis or hypoparathyroidism.

Table 1:-Demographic data and outcome of the study

	N=53
Age (years)	
Range	27-61
Mean	41.5
Sex	
Male	10 (18.9%)

Female	43 (81.9%)
Type of goiter	
Simple nodular	35 (66.04%)
Thyroid adenoma	9 (16.98%)
Graves' disease	4 (7.55%)
Papillary carcinoma	5 (9.43%)
RLN visualization	47 (88.7%)
None visualization	6 (11.3%)
Parathyroid visualization	49(92.45%)
None visualization	4 (7.55%)
Hospital stay (days)	
Range	1-4
Mean	1.6
Complications	
Transient hypoparathyroidism	4 (7.54%)
Permanent hypoparathyroidism	0
RLN injury	0
Wound infection	0
Mortality	0

Discussion:-

Thyroidectomy rarely associated with morbidity and mortality. However the postoperative complications may be serious to cause a devastating handicaps for life. Now a days the two important complications are injury to the RLN and hypoparathyroidism. The extensive dissection, reoperation on the thyroid, and the lack of experienced surgeons are important factors for morbid thyroidectomy. Careful dissection represent the main factor in minimizing the complications^{15,16}.

Good exposure, visualization and identification of RLN along the course are very critical to protect it from injury. The method of prevention of RLN injury during thyroidectomy was explained in some old studies¹⁷ Although Bergamaschi et al.¹⁸ concluded that identification of RLN failed to decrease the rate of injury, on the other side other studies showed a notable decrease in the ratio of RLN injury through visualization of the nerve¹⁹.

Mattig et al.²⁰ concluded that routine identification of RLN minimize the rate of injury from 5.99% to 0.88%. Erbil et al. concluded that 1.8% of their cases had RLN palsy²¹. Which lead to significant impairment of life style²² and negatively affect the job performance²³. Multiple recent studies of 16,448 thyroidectomies; reported that visual RLN identification, in comparison to RLN treatment, is "gold standard" of care²⁴.

According to previous studies, our study reveal that RLN injury can be inhibited by nerve visualization by intra-operative Methylene Blue spraying where the RLN can be identified in all cases where the RLN is visualized in 47 cases(88.7%) after first spraying and the remaining six cases(11.3%) needed more dissection as they were present in deeper level.

hypoparathyroidism is an important Postoperative complication that lead to prolonged hospital stay and more cost. Many studies, showed incidence of transient hypoparathyroidism ranged between 6.9% and 46% while the ratio 0.4% to 3.3% of permanent hypoparathyroidism was reported. Falk et al. concluded that 27.8% of their study suffered from transient hypoparathyroidism which manifested by transient hypocalcaemia, that managed by supplementation of oral vitamin D and Ca²⁵. The rate of hypocalcemia reported post thyroidectomy ranged between 1% to more than 50%^{26,27}. Although most cases of post thyroidectomy hypocalcemia are transient, the rate of permanent hypoparathyroidism is unusual and must be less than 1%²⁸. In our study, Only 4 cases (7.54%) suffered from transient hypocalcaemia, four days maximally which treated by oral calcium supply and normal parathyroid hormone, this result agree with the results of previous studies.

We noted that the time needed for wash-out of the PGs (3 minute) was less than that of the thyroid (15 minute). This may be due to the differences in the lympho-vascular tissues. The lympho-vascular tissue of PGs is highly dense.

This quality is vital for rapid wash out of MB staining. Unstaining of RLN in the procedure is due to the nerve has a schwann sheath covering and avascular structure²⁹.

The unstaining of the artery is due to the thickness of wall and reverse blood flow (from the heart to the gland not from the gland to the heart) and. As the veins carry methylene dye from the gland, they rapidly changed into blue color. There were no complications reported from MB spraying in our study ensuring the safety of using MB staining²⁹.

Traditionally, we preserve RLN through detection of its relation to the inferior thyroid artery, ligament of Berry and trachea-esophageal groove, as a land-marks. But, due to presence of many variations in the neurovascular relationship and different thyroid diseases, detection of the artery not confirm accurate identification and protection of RLN²⁹.

So by spraying MB over the perithyroidal tissues, the surgeon can detect and visualize RLN, PGs and the inferior thyroid artery. when they be visualized, the nerve and its branches is followed up safely along the whole course up to the larynx. After identification of the PGs, great care is considered to protect their blood supply²⁹.in our study no cases of wound complication or operative mortality.

Conclusion:-

Intraoperative spraying of the Methylene blue is good, simple and safe technique during thyroidectomy which enables the surgeon to visualize and protect both the RLN and PGs from potential complications. Thus safe the patients from troublesome complications which may affect their life style.

References:-

1. Bron, L.P., O'Brien, C.J., 2004. Total thyroidectomy for clinically benign disease of the thyroid gland. *Br. J. Surg.*,91(5):569-574. [doi:10.1002/bjs.4507]
2. Rosato, L., Avenia, N., Bernante, P., De Palma, M., Gulino, G.,Nasi, P.G., Pelizzo, M.R., Pezzullo, L., 2004. Complications of thyroid surgery: analysis of a multicentric study on 14934 patients operated on in Italy over 5 years. *World J. Surg.*, 28(3):271-276. [doi:10.1007/s00268-003-6903-1]
3. Hundahl SA, Fleming ID, Fremgen AM, et al. A National Cancer Data Base report on 53,856 cases of thyroid carcinoma treated in the US, 1985-1995. *Cancer* 1998; 83:2638-2648.
4. Suh YJ, Choi JY, Chai YJ, et al. Indocyanine green as a near-infrared fluorescent agent for identifying parathyroid glands during thyroid surgery in dogs. *Surg Endosc* 2015; 29:2811-2817.
5. Coers C.D.&Woolf A.L. (1959) *The Innervations of Muscles: A Biopsy Study*. Blackwell, Oxford
6. Wille-Jorgensen P. & Jensen H.E. (1981) Leucomethylene blue staining during vagotomy. *Br. J. Surg.* 68, 81–82.
7. Nahlieli O. & Levy Y. (2001) Intravital staining with methylene blue as an aid to facial nerve identification in parotid gland surgery. *J. Oral Maxillofac. Surg.* 59, 355–356.
8. Yazicia I., Kasimcanb M.O., Karakayaa E.I. et al. (2011) Methylene blue vital staining of nerve stumps in secondary peripheral nerve repair; Letter to the Editor.. *Injury* 42, 1387–1391.
9. Seif C., Martinez Portillo F.J., Osmonov D.K. et al. (2004) Methylene blue staining for nerve-sparing operative procedures: an animal model. *Urology* 63, 1205–1208.
10. Wagner, H.E., Seiler, C., 1994. Recurrent laryngeal nerve injury after thyroid gland surgery. *Br. J. Surg.*, 81(2):226-228. [doi:10.1002/bjs.1800810222]
11. Sturniolo, G., D'Alia, C., Tonante, A., Gagliano, E., Taranto,F., Lo Schiavo, M.G., 1999. The recurrent laryngeal nerve related to thyroid surgery. *Am. J. Surg.*, 177(6):485-488. [doi:10.1016/S0002-9610(99)00101-4].
12. Lee NJ, Blakey JD, Bhuta S, et al. Unintentional parathyroidectomy during thyroidectomy. *Laryngoscope* 1999;109:1238-1240.
13. Sasson AR, Pingpank Jr JF, Wetherington RW, et al. Incidental parathyroidectomy during thyroid surgery does not cause transient symptomatic hypocalcemia. *Arch Otolaryngol Head Neck Surg* 2001;127:304-308.
14. Hisham, A.N., Lukman, M.R., 2002. Recurrent laryngeal nerve in thyroid surgery: a critical appraisal. *ANZ J. Surg*72(12):887-889. [doi:10.1046/j.1445-2197.2002.02578.x].

15. Rios-Zambudio A, Rodr0iguez J, Riquelme J, Soria T, Canteras M, Parrilla P: Prospective study of postoperative complications after total thyroidectomy for multinodular goiters by surgeons with experience in endocrine surgery. *Ann Surg* 2004, 240:18–25.
16. Bergenfelz A, Jansson S, Kristoffersson A, et al: Complications to thyroid surgery: results as reported in a database from a multicenter audit comprising 3,660 patients. *Langenbeck Arch Surg* 2008, 393:667–673.
17. Ardito, G., Revelli, L., D'Alatri, L., Lerro, V., Guidi, M.L., Ardito, F., 2004. Revisited anatomy of the recurrent laryngeal nerves. *Am. J. Surg.*, 187(2):249-253.
18. Bergamaschi, R., Becouarn, G., Ronceray, J., 1998. Morbidity of thyroid surgery. *Am. J. Surg.*, 176(1):71-75.
19. Thomusch, O., Sekulla, C., Dralle, H., 2003. Is primary total thyroidectomy justified in benign multinodular goiter? Results of a prospective quality assurance study of 45 hospitals offering different levels of care. *Der Chirurg*, 74(5):437-443 (In German).
20. Mattig, H., Bildat, D., Metzger, B., 1998. Reducing the rate of recurrent nerve paralysis by routine exposure of the nerves in thyroid gland operations. *Zentralbl. Chir.*, 123(1):17-20.
21. Erbil Y, Barbaros U, Issever H, et al: Predictive factors for recurrent laryngeal nerve palsy and hypo parathyroidism after thyroid surgery. *Clin Otolaryngol* 2007, 32:32–37.
22. Smith E, Verdolini K, Gray S, Nichols S, Lemke J, Barkmeier J: Effect of voice disorders on quality of life. *J Med Speech-Language Pathol* 1996, 4:223–244.
23. Fang TJ, Li HY, Gliklich RE, Chen YH, Wang PC, Chuang HF: Quality of life measures and predictors for adults with unilateral vocal cord paralysis. *Laryngoscope* 2008, 118(10):1837–1841.
24. Dralle H, Sekulla C, Haerting J, et al: Risk factors of paralysis and functional outcome after recurrent laryngeal nerve monitoring in thyroid surgery. *Surgery* 2004, 136:1310–1322.
25. Falk SA, Birken EA, Baran DT: Temporary post thyroidectomy hypocalcemia. *Arch Otolaryngol Head Neck Surg* 1998, 114:168–174.
26. Reeve T, Thompson NW (2000) Complications of thyroid surgery: how to avoid them, how to manage them, and observations of their possible effect on the whole patient. *World J Surg* 24:971–975.
27. Ozbas S, et al (2005) Comparison of the complications of subtotal, near total and total thyroidectomy in the surgical management of multinodular goitre. *Endocr J* 52:199–205.
28. McHenry CR, et al (1994) Risk factors for post thyroidectomy hypocalcemia. *Surgery* 116:641–648.
29. Sari, S., Aysan, E., Muslumanoglu, M., Ersoy, Y. E., Bektasoglu, H., & Yardimci, E. (2012). Safe thyroidectomy with intraoperative methylene blue spraying. *Thyroid research*, 5(1), 15.